

Hydatid disease: Long term, single centre experience

Abstract

The origin of hydatid disease can often be attributed to the echinococcus granulosus tapeworm. While pulmonary hydatids have been linked to Echinococcus multilocularis. This type of infection has been extensively documented in various regions, including South Africa, South America, Iran, Australia, and New Zealand. Within India, cases of this disease have been reported in locations such as Punjab, Varanasi, Lucknow, Kashmir, Pondicherry, Madurai, and Himachal Pradesh.

The liver is the most common site for hydatid disease in 75% of cases, followed by the lung in 50% and 10% being reported in the kidney, spleen, peritoneal cavity, ovary, bones, brain and muscles. Diagnosis of hydatid disease is based on clinical signs and symptoms and radiological imaging studies.

Keywords: Hydatid disease, AIR technique, Scolicidal Agents

AIM - The objective of this study is to establish the diagnosis of hydatid disease and outline its surgical treatment approach

Introduction

The retrospective investigation was carried out at Jatal Hospital and Research Centre, a private medical facility located in Latur, Maharashtra, India. The study involved a comprehensive review of records from a total of 90 patients who underwent surgical intervention for hydatid cysts between January 1990 and January 2020. [2,5,6]

The diagnostic process involved multiple steps, including ultrasonography, CT scans, and chest X-rays, all of which confirmed the primary diagnosis of a hydatid cyst. The ultimate confirmation was achieved through histopathological examination. Various essential pieces of information were collected, encompassing aspects like patients' ages, genders, presenting signs, and symptoms related to the hydatid cyst. Additionally, the location of the cysts, their unilocular or multilocular nature, the presence of hydatid sand and daughter cysts, as well as any history of disease recurrence were recorded. [3,5,6]

Methodology

The surgical interventions performed for treating hydatid disease included the following approaches:

1. **Radical Surgery:** This approach involves the resection of parts or entire affected organs.
2. **Conservative Surgery:** Employing traditional methods, this approach encompassed open cystectomy, omentoplasty, or capitonnage using the conservative "AIR technique" (Aspiration, Injection, Re-aspiration). This technique involved the use of 10% povidone-iodine (Betadine) and hydrogen peroxide as a scolicidal agent. It was followed by pre and post-operative Albendazole therapy for six months. [2,5]

The AIR Technique

Using a substantial 16-gauge lumbar puncture needle, a lengthy one, we connected it to a 20 cc syringe, which was further attached to a Luer Lock three-way stopcock. After meticulously saturating the surgical field with sponges soaked in a sporicidal agent, we proceeded with the procedure. Beginning at the most accessible part of the cyst cavity, we introduced the needle assembly. By utilizing the stopcock, we initially aspirated the hydatid fluid, following which we injected the scolicidal agent. Subsequently, we re-aspirated and discarded the cyst contents. [5,7]

The next step involved the opening of the pericyst using Babcock clamps, and then we diligently extracted the endocyst of the hydatid cyst in its entirety. The cyst wall underwent meticulous examination to detect any biliary connections. To ensure proper cavity disinfection, we filled the cyst cavity with a mixture of normal saline and Betadine solution. For larger cavities, we opted for additional measures like omentoplasty or capitonnage. After meticulously suturing the cavity closed with 2.0 vicryl sutures, we successfully obliterated any residual space within the cavity. [1,5,6]

In our study involving 20 patients, an extrahepatic drain was maintained in selected cases, and this drain was subsequently removed on the 4th to 5th day after the operation. All patients received Albendazole therapy for a duration of six months, and their progress was closely monitored for one to two years. Encouragingly, our series revealed no instances of recurrence, and fortunately, no mortality occurred. It is important to note that only five patients experienced anaphylaxis, an allergic reaction, which was expertly managed by our anaesthetic team. [5,6]

Results

Between January 1990 and January 2020, a total of 90 cases underwent surgery for hydatid cysts. Among these cases, 50 were female and 40 were male. The incidence of hydatid cysts was found to be higher in females than in males. The predominant age group affected ranged from 30 to 45 years old. Clinical manifestations included abdominal pain in 40 patients and the presence of an abdominal lump at the right hypochondrium in 25 cases. Radiological assessments revealed that 70 patients had liver hydatid cysts detected through ultrasonography, while abdominal CT scans identified the condition in 20 patients. Additionally, plain chest X-rays identified lung hydatid cysts in 10 cases. In terms of cyst location, the right lobe of the liver was involved in 70 cases, the left lobe in only 4 cases, and both the right and left lobes were affected in a single case.

Based on hospital records, out of the total 90 patients, information regarding the distribution of hydatid cysts across sexes and organs, as well as their corresponding surgical treatments, is as follows

Organs	Male	Female
Liver	32	42
Lung	5	5

	Male	Female
Spleen	0	1
Breast	0	1
Thigh	1	0
Ovary	0	1
Mesentery	1	0

Total number of extra hepatic hydatid 5 cases - Total Number of patients 90.

Treatment	Number of cases
1. Radical surgery	10 cases
2. Conservative surgery - AIR technique	78 cases
3. Laparoscopic surgery	2 cases

Our centre recently treated 90 cases, including one instance of intra-abdominal secondary hydatidosis that required surgery. Among these cases, anaphylaxis was observed in five patients, but they were effectively managed by our anaesthetic team, and fortunately, no fatalities occurred. In 70 cases where hydatid surgery was performed, intra-abdominal drainage tubes were not deemed necessary. However, in the remaining 20 cases, drainage tubes were utilized due to factors like the presence of a large hydatid cyst cavity or significant biliary leakage.

The majority of patients fell within the 30-50 age range, and interestingly, female patients outnumbered males in our observations. We found that 60% of cases had a history of exposure to pet dogs or sheep, suggesting a potential source of infection. To prevent recurrence, a post-operative Albendazole therapy was administered for six months, yielding positive results as no instances of recurrence were noted in our series. Fortunately, we did not encounter cases with hydatid cysts affecting multiple organs; instead, single hydatid cysts per organ were more prevalent than multiple cysts in the same organ. Specifically, 80% of hydatid cysts occurred as solitary formations within organs, with only 20% presenting as multiple cysts within a larger mother cyst. Notably, one patient with a huge right lobe of the liver exhibited 40-50 multiple cysts in our series. Additionally, we encountered a patient with hydatid cysts in both the right and left liver lobes, with a single cyst identified in each lobe. (Fig 1-14)

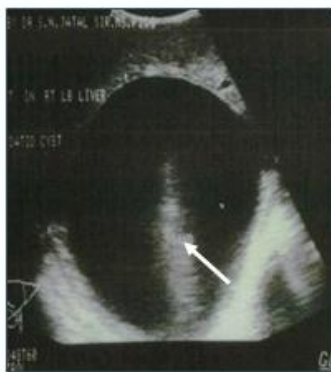

Fig-1 Ultrasonography showing anechoic, well defined Cyst Containing hydatid sand

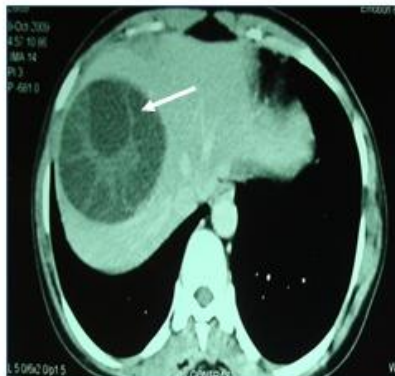


Fig-2 CT abdomen showing multi cystic hydatid cyst in right lobe of liver

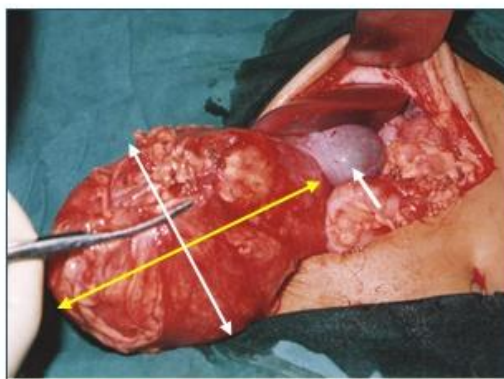
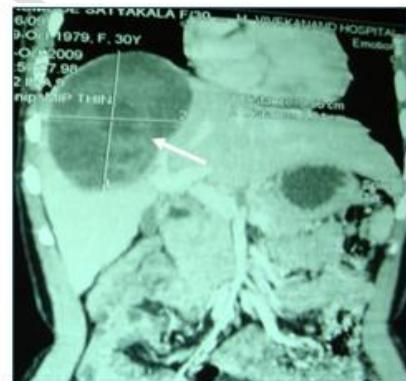

Fig-3 Intra operative photograph showing a hydatid cystic swelling at lower border of right lobe of liver

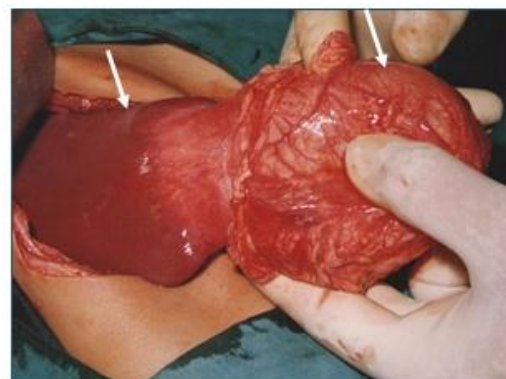


Fig-4 Intra operative photograph showing a hydatid cystic at inferior surface of right lobe of liver

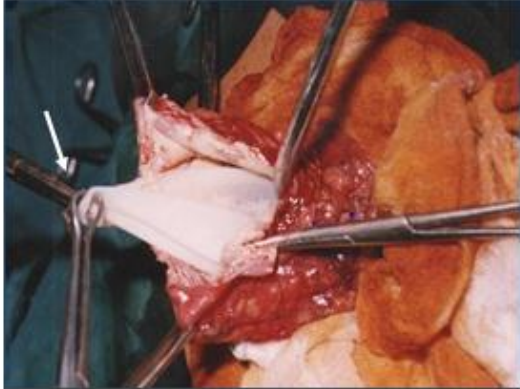


Fig-5 Intra operative photograph showing radical surgery of hydatid cyst with pericystectomy

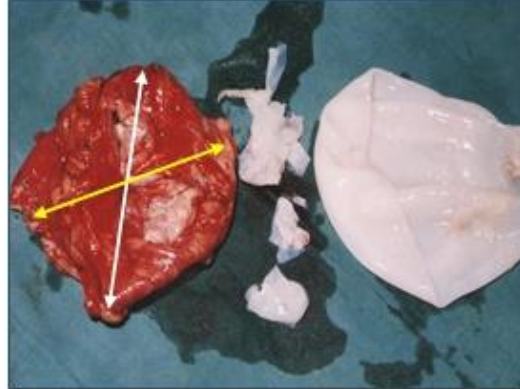


Fig-6 Photograph showing total excision of hydatid cyst of size 7x5 cm with white laminated endocyst

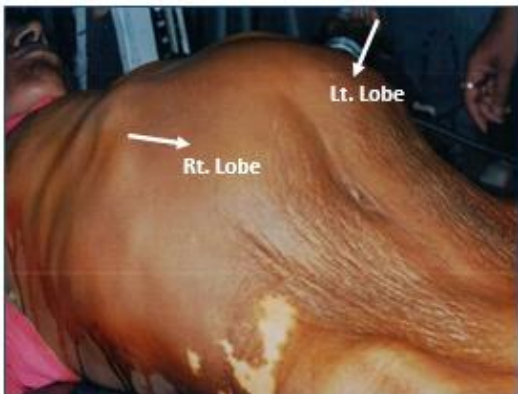

Fig-7 Clinical photograph showing huge lump at epigastrium (Hepatomegaly)

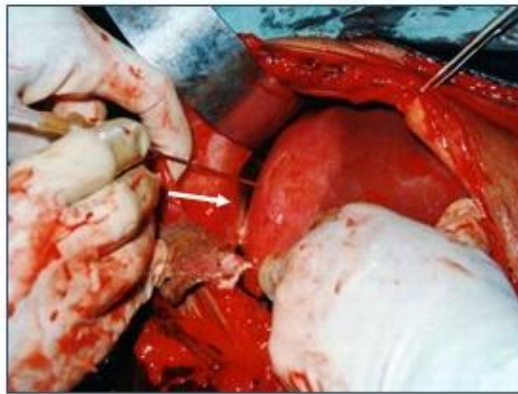


Fig-8 Intra operative photograph showing "AIR technique" Conservative surgery

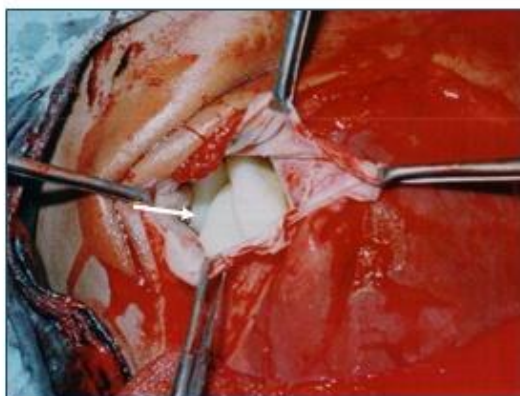


Fig-9 Intra operative photograph showing right liver lobe hydatid cyst

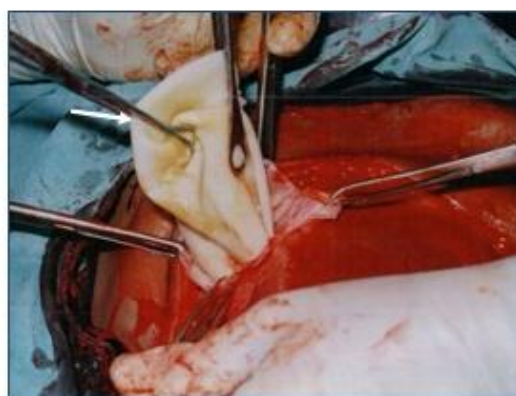


Fig-10 Intra operative photograph showing right liver lobe hydatid cyst with unilocular endocyst

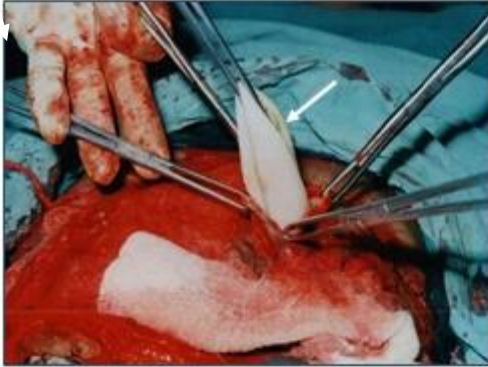

Fig-11 Intra operative photograph showing left liver lobe hydatid cyst with unilocular endocyst

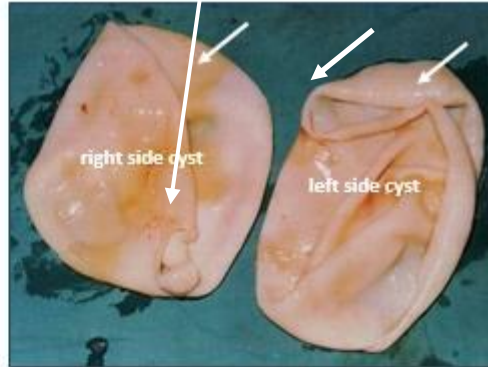


Fig-12 Photograph showing both side hydatid cyst white gelatinous membrane of endocyst

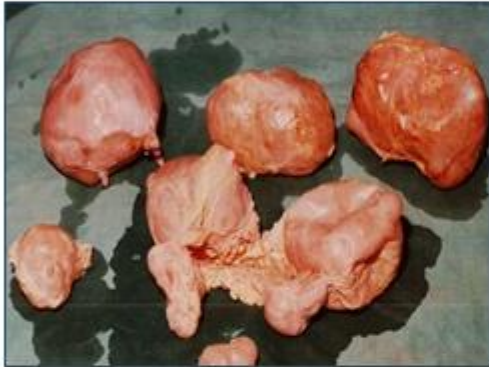

Fig-13 Photograph showing secondary intra-abdominal peritoneal multiple hydatid cysts.



Fig-14 Photograph showing multiple 40-50 hydatid cyst with white laminated membrane endocysts

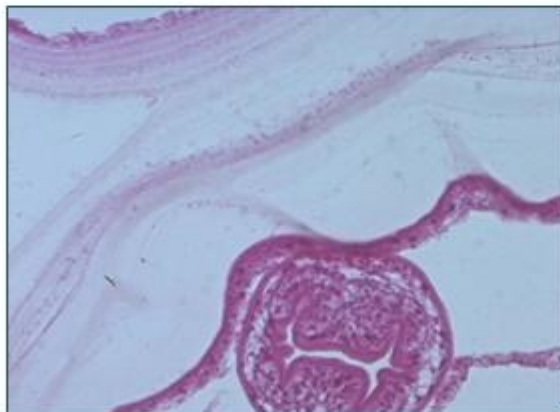


Fig-15 Histopathological examination showing hydatid cyst with daughter cyst

Discussion

Hydatid disease diagnosis often presents with symptoms like right upper quadrant or epigastric pain and a palpable mass during physical examination. Lung hydatidosis may manifest as low-grade fever and cough. Definitive diagnosis of liver hydatid disease involves a combination of imaging, serologic, and immunologic studies. Ultrasonography is the primary diagnostic method with a 90% accuracy. It identifies a well-defined, anechoic cyst with debris, freely moving hydatid sand and calcification. CT and MRI are even more sensitive, with 100% imaging accuracy. [2,5,6]

The Elisa test demonstrates high sensitivity at around 90%, while the Casoni test shows lower sensitivity. The Indirect Immunofluorescence test is the most sensitive at 95% for liver hydatid cysts. Surgical treatment remains the gold standard, successful in about 90% of cases. Key principles include: [5,6,7]

1. Complete removal of infective cyst components.
2. Prevention of cyst content spillage.
3. Managing the residual cavity.
4. Addressing biliary communication within the cyst. [5,6,7]

Types of Surgical Procedures

Radical Surgery - cystectomy, pericystectomy, lobectomy, hepatectomy.

Conservative Surgery - AIR technique (Aspiration, Injection, Re-aspiration).

PAIR technique- (Puncture, Aspirate, Inject, Re-aspirate)

laparoscopic Surgery - Laparoscopic surgery suits peripheral liver involvement, and it's useful for extrahepatic cysts in the spleen and ovaries.

Albendazole therapy is administered preoperatively for four weeks to lower recurrence risk and postoperatively for six months to prevent recurrence. The recurrence rate for open surgery ranges from 0-4%, but in our study, it was 0%. Both radical and conservative (AIR Technique) surgeries are vital for liver hydatid cysts and serve as the gold standard treatment. [2,5,6,7]

Conclusion

Liver hydatid disease is diagnosed using ultrasonography and a CT scan. The gold standard treatment involves conservative surgery using the "AIR Technique," supplemented by Albendazole therapy to prevent local recurrence.

Ethical Approval

As per international standard or university standard written ethical approval has been collected and preserved by the author(s).

Consent

As per international standard or university standard, patient(s) written consent has been collected and preserved by the author(s).

References

1. Moradi M, Rampisheh Z, Roozbehani M, Razmjou E. A retrospective study of hydatid cysts in patients undergoing liver and lung surgery in Tehran, Iran. *Heliyon*. 2019 Jun 11;5(6):e01897. doi: 10.1016/j.heliyon.2019.e01897. PMID: 31211265; PMCID: PMC6562322.
2. Alexander PV, Rajkumar D. The pattern of hydatid disease-a retrospective study from Himachal Pradesh, India. *Indian J Surg*. 2010 Aug;72(4):331-5. doi: 10.1007/s12262-010-0120-6. Epub 2010 Nov 23. PMID: 21938198; PMCID: PMC300278
3. Al-Radaideh Ali , Hijjawi Nawal , Abdelfattah Ali , Al-Khreisat Mutaz and Bani-Hani Kamal, 10-Year Retrospective Study on Hydatid Disease in Jordan with Emphasis on the Role of Imaging in Its Diagnosis, *International Journal of Medical Research & Health Sciences*, 2017, 6(1): 32-41
4. Patel S, Soni H., Bhadkariya A, Bhagwat G, A Retrospective Descriptive Study of Hydatid Disease in Unusual Location Carried Out in Tertiary Care Hospital, *Indian Journal of Pathology: Research and Practice* Volume 6 Number 1, January - March 2017 DOI: <http://dx.doi.org/10.21088/ijprp.2278.148X.6117.10>
5. Derbel F, Ben M, Hadj Hamida MB, Mazhoud J, Youssef S, Ben A, et al. Hydatid Cysts of the Liver - Diagnosis, Complications and Treatment [Internet]. *Abdominal Surgery*. InTech; 2012. Available from: <http://dx.doi.org/10.5772/48433>
6. Amirhossein Erfani, Reza Shahriarirad, Mehrdad Eskandarisani, Mohammad Rastegarian, Bahador Sarkari, "Management of Liver Hydatid Cysts: A Retrospective Analysis of 293 Surgical Cases from Southern Iran", *Journal of Tropical Medicine*, vol. 2023, Article ID 9998739, 8 pages, 2023. <https://doi.org/10.1155/2023/9998739>
7. Eckert J, Deplazes P. Biological, epidemiological, and clinical aspects of echinococcosis, a zoonosis of increasing concern. *Clin Microbiol Rev* 2004; 17: 107-135
8. Kand eel, A., Ahmed, E.S., Helmy, H., El Setouhy, M., Craig, P.S. et al. (2004). A retrospective hospital study of human cystic echinococcosis in Egypt. *EMHJ - Eastern Mediterranean Health Journal*, 10 (3), 349-357, 2004 <https://apps.who.int/iris/handle/10665/119420>
9. Khan, H.; Casulli, A.; Harandi, M.F.; Afzal, M.S.; Saqib, M.A.N.; Ahmed, H. A Retrospective Cohort Study on Human Cystic Echinococcosis in Khyber Pakhtunkhwa Province (Pakistan) Based on 16 Years of Hospital Discharge Records. *Pathogens* 2022, 11, 194. <https://doi.org/10.3390/pathogens11020194>
10. Dr. Ram Dayal , Dr.S.S.Rathore, Dr.Deepak Verma, Dr. Sonu Parmar, Dr.Ram Ratan Yadav , Dr.Mukteshwar Kumar Gupta, The Study of Hydatid Disease –A Retrospective Study of Last 10 Years In Western Rajasthan India, *IOSR Journal of Dental and Medical Sciences (IOSR-JDMS)* e-ISSN: 2279-0853, p-ISSN: 2279-0861. Volume 15, Issue 2 Ver. IX (Feb. 2016), PP 45-47 www.iosrjournals.org