

Triple atresia involving Esophageal atresia, duodenal atresia and imperforated anus: An Uncommon presentation

Abstract

Triple atresia a rare entity comprises of esophageal atresia(EA), duodenal atresia(DA) and anorectal malformation(ARM).The association of esophageal atresia with tracho-esophageal fistula and anorectal malformation is relatively common while association with duodenal atresia is uncommon with the reported incidence is less than 1% to 2%.Here we report a case of triple atresia involving the esophagus, duodenum and anorectum, where all three entities were diagnosed at the time of admission and surgical correction of esophageal atresia, duodenal atresia along with sigmoid colostomy for high ano-rectal malformation, was carried out as the first stage.A high index of suspicion for the detection of coexisting gastrointestinal anomalies is mandatory in the management EA patients, to avoid undue morbidity and mortality.

Keywords: Triple atresia, Esophageal atresia, Duodenal atresia, Anorectal malformation (ARM), Tracheoesophageal fistula (TEF)

Introduction

Triple atresia a rare entity of VACTERL association comprises of esophageal atresia(EA), duodenal atresia(DA) and anorectal malformation(ARM).[1]The association of esophageal atresia with tracho-esophageal fistula and anorectal malformation is relatively common and is seen in 10% of cases while its association with duodenal atresia is uncommon.[2]Here we report a case of triple atresia involving the esophagus, duodenum and anorectum, where all three entities were diagnosed at the time of admission and surgical correction of esophageal atresia, duodenal atresia along with sigmoid colostomy for high ano-rectal malformation, was carried out as the first stage.

Case Report

A term 24hrs old male neonate presented to the emergency with mild abdominal distension, absent anal opening along with drooling of saliva. Examination revealed a 2.5 kg baby with soft and mildly distended abdomen along with absent anal opening.[Figure 1]The neonate was dehydrated and tachypnoeic. There was no history of meconuria. The

neonate was stabilized initially and echocardiography was done to check for congenital heart diseases. The red rubber catheter was not going beyond 8 cm orally. A chest X-ray showed the red rubber catheter in the upper part of esophagus [Figure 2] and an abdominal X-ray revealed distension of the stomach and first portion of the duodenum with air giving the characteristic appearance of “double-bubble”. No intestinal air was seen beyond the duodenum suggesting the diagnosis of TEF with DA [Figure 3]. Final diagnosis of triple atresia (esophageal, duodenal and imperforated anus) was made. Post stabilisation, Right-sided thoracotomy with ligation of the fistula, and primary repair of TEF was done followed by High sigmoid colostomy and duodenoduodenostomy (for type 1 DA) with a transanastomotic tube along with gastrostomy. Postoperatively, after the thoracotomy, the neonate was put on ventilatory support for 72 h. However, baby developed sepsis, features of pneumonia with chest infiltrates, therefore, the baby could not be extubated. No anastomotic leak was apparent in intercostal drainage tube. Child started deteriorating which was managed by ventilatory support, parenteral nutrition and broad-spectrum antibiotics. The patient's course, however was steadily downhill and he expired on 5th post operative day. The child died due to pulmonary complications and sepsis.

Discussion

Esophageal atresia with TEF is a common congenital abnormality, affecting 1 in 2500-4000 newborns.[3] The reported incidence of associated abnormalities varies from 30% to 50% most commonly as part of the vertebral, anorectal, cardiac, tracheoesophageal, renal, and limb defects spectrum.[4] The reported incidence of duodenal atresia along with ano-rectal malformations is 1% to 2%.[5] In the presence of triple atresia the diagnosis becomes difficult and challenging because apart from obvious ano-rectal anomalies, the other associated anomalies of gastrointestinal tract may go unnoticed. The presence of duodenal atresia obviates x-ray invertogram in assessing the level of the ano rectal malformation, because gas does not reach the rectum. The management of triple atresia is challenging. Conventionally, several studies have demonstrated that TEF should be repaired primarily, along with other surgeries.[6] In contrast, other investigators have demonstrated that TEF repair should be done as the second surgery after colostomy and gastrostomy.[7,8] However, with advances in neonatal surgery, anaesthesia, and intensive care, it becomes feasible for early and primary repair of these anomalies. High index of suspicion for the detection of coexisting gastrointestinal anomalies is mandatory in the management EA patients especially in patients with pure esophageal

atresia as chances of missing duodenal atresia or other gastrointestinal anomalies are very high. The survival of these anomalies have been improved over the years and reported to be 50% to 75% due to advances in neonatal care.[9]

Conclusion

Triple Atresia is a rare condition and surgical approach remains challenging. There are many studies supporting staged repair of these complex anomalies while others in favour of primary TEF repair along with repair of other anomalies. However, with advances in neonatal care and neonatal ventilation primary repair has become the optimal approach.

Consent:

Taken from parents for data collection and submission of related information.

References

1. Jackson, Raef et al. "Triple Atresia, Triple Threat? An Unusual Constellation of Primary Surgical Abnormalities." *Pediatric Reports* 13 (2021): 189 - 196.
2. Harjai MM. CONGENITAL TRIPLE ATRESIA OF THE ESOPHAGUS, DUODENUM AND RECTUM—A DIAGNOSTIC DILEMMA. *Medical Journal Armed Forces India*. 2000 Oct 1;56(4):334-5.
3. McCook TA, Felman AH. Esophageal atresia, duodenal atresia, and gastric distention: Report of two cases. *AJR Am J Roentgenol*1978;131:167-8.
4. Quan L, Smith DW. The VATER association. Vertebral defects, Anal atresia, T-E fistula with esophageal atresia, Radial and Renal dysplasia: A spectrum of associated defects. *J Pediatr*1973;82:104-7.
5. Smith ED, Saeki M. Associated anomalies in ano-rectal malformation in children: update 1988. *Birth defects*. 1988:501–549.
6. Spitz L, Ali M, Brereton RJ. Combined esophageal and duodenal atresia: Experience of 18 patients. *J PediatrSurg*1981;16:4-7.
7. Downard CD, Kim HB, Laningham F, Fishman SJ. Esophageal atresia, duodenal atresia, and unilateral lung agenesis: A case report. *J PediatrSurg*2004;39:1283-5.

8. Mollitt DL, Golladay ES. Management of the newborn with gastrointestinal anomalies and tracheoesophageal fistula. *Am J Surg*1983;146:792-5.
9. Ein SH, Palder SB, Filler RM. Babies with esophageal and duodenal atresia: A 30-year review of a multifaceted problem. *J PediatrSurg*2006;41:530-2.

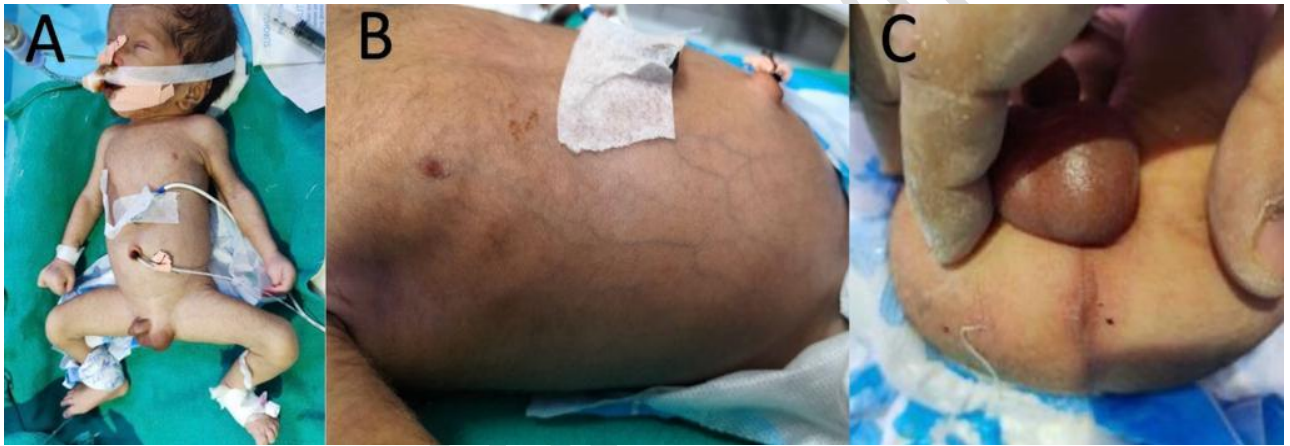

Figure 1. A-C showing soft, mildly distended abdomen with absent anal opening

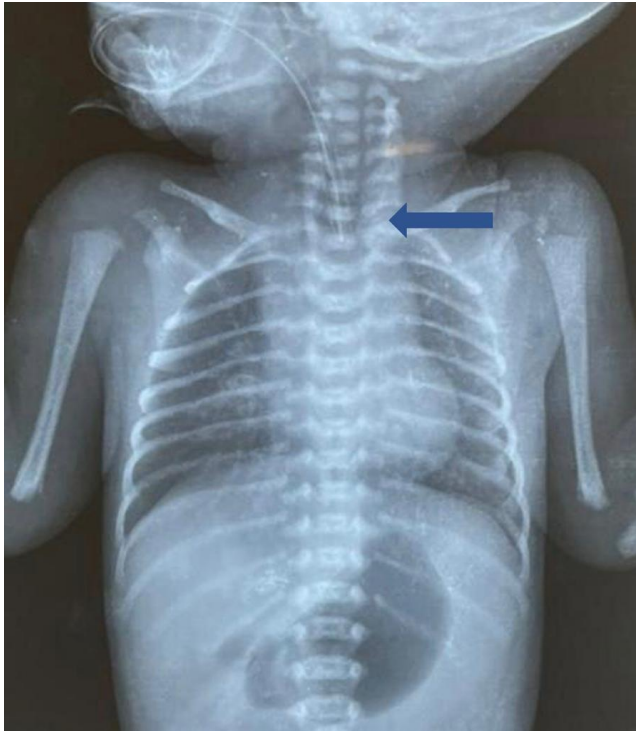


Figure 2. A chest X-ray showed the red rubber catheter in the upper part of esophagus (Marked by an arrow)

UNDER PEER REVIEW

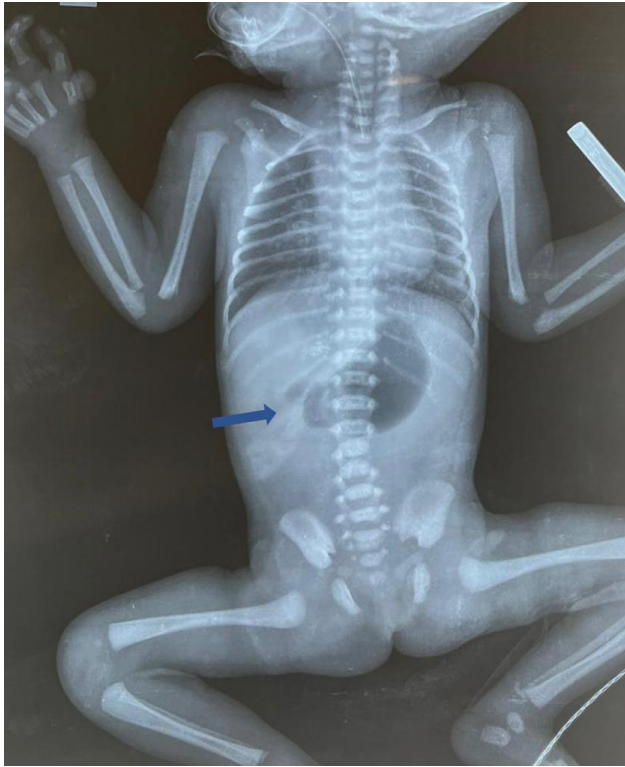

Figure 3. X-ray depicting characteristic appearance of “double-bubble” with no intestinal air beyond the duodenum suggesting duodenal atresia

UNDER PEER REVIEW