

Primary Ovarian Hydatid Cyst – An Extremely Rare Case

Abstract

Primary Ovarian hydatid disease is rare entity, produced by larval stage of echinococcus granulosus. Hydatid disease commonly involves Liver, Lung, abdominal cavity, spleen and infrequently in pelvic organs, ovary and uterus. Primary hydatid cyst of the ovary is an extremely rare presentation. Many cases are not symptomatic and may be discovered accidentally. In 80 % of cases reported with a cyst in this location, the ovary is the most common affected organ followed by uterus. Primary ovarian hydatid cysts are very rare and can be primary as well as secondary in nature. This condition is misdiagnosed in the majority of cases and may be mistaken for ovarian cysts or cystic tumour of the ovary and the symptoms are usually non-specific.

We are reporting an extremely rare case of primary ovarian hydatid cyst in a 35 years old lady, complaining of pain in abdomen and abdominal lump. Ultrasonography revealed a left side large ovarian cyst and after laparotomy revealed an ovarian hydatid cyst in the left ovary, which was confirmed by histopathology examination.

Keywords

Hydatid cyst, ovarian hydatid cyst, Laparotomy.

Introduction

“The recent review of 27 literature reports of ovarian hydatid disease, diagnosed during last 20 years. Hydatid cyst of the ovary is an extremely rare presentation and accounting for only 0.2 to 1% of diagnosed cases. It may be mistaken for ovarian cyst or cystic tumours of the ovary. The diagnosis is mostly radiological by ultrasonography, CT and MRI. Ultrasonography is very informative in locating the site and size of the cyst. On ultrasonography, a hydatid cyst appears as well defined double wall, anechoic lesion with daughter cyst inside the mother cyst, with scolices appears as hydatid sand and cyst contains clear fluid”. [1,4,5]

“The organ commonly involved in hydatid disease are the liver 75%, Lungs 15%, muscles 5%, bones 3%, kidney 2%, spleen 1% and brain 1%. It too rare to diagnosed on hydatid cyst in the pelvis. The incidence being given as 0.2 to 2.25%. The ovary is the most common affected organs followed by the uterus”. [4,5,6]

“Ovarian hydatidosis is usually secondary due to rupture of primary hydatid cyst of the liver and other intra-abdominal hydatid cysts. However, primary ovarian hydatid cyst has been reported and dissemination via the systemic or lymphatic circulation is the possible route of transmission. Ovarian hydatid cysts may mimic on ovarian neoplasm because of non-specific clinical symptoms and radiological appearance”. [4,6,7,]

Case Presentation

A 35 years old female lady was admitted to our centre on 07/10/2013 with complaining of progressive increase in abdominal girth, last one years and pain in lower abdomen. Her Menses were regular, and complaining difficulty in micturition. Her physical examination revealed a palpable firm irregular mass arising from the pelvis and lump was extending up to umbilicus. The routine blood chemistry, urine examination and x-ray chest was normal. CA 125 antigen test was normal. Her ultrasonography abdomen showed evidence of a cystic left adrenal lesion measuring 15x12x8 cm, which was unilocular, double walled cyst containing fluid. No abdominal and pelvic CT and MRI was done. Ultrasonography suggestive of primary hydatid cyst of left ovary.

She was started Albendazole therapy for one month. Explorative laparotomy was performed and showed a large cystic mass measuring 15x12x8 cm was seen arising from left ovary. Total surgical excision of cystic mass was done. Right ovary and pouch of Douglas was normal. Omentum was adherent to the cystic mass, separated and excision done. Peritoneal lavage with Betadine as a scolicidal agent and drainage tube was placed before abdominal closure.

On gross examination of cystic ovarian mass measuring 15x12x8 cm, white in colour weighing 1.5 kg. Cut section of specimen showed a big unilocular, egg white gelatinous, laminated hydatid cyst and histopathological examination showed typical laminated germinal layer with scolices of hydatid cyst. Postoperative recovery was uneventful and postoperative she was started Albendazole therapy for 6 months. After one year follow up, she was healthy and no recurrence of the hydatid disease. (Fig 1-7)

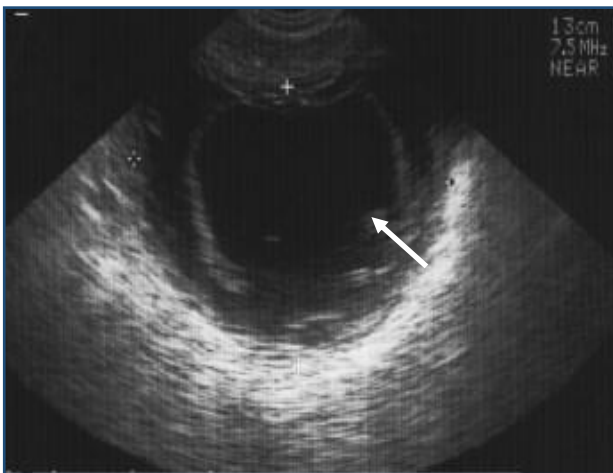


Fig-1 Ultrasonography of left ovarian hydatid cyst of size 15x12x8 cm

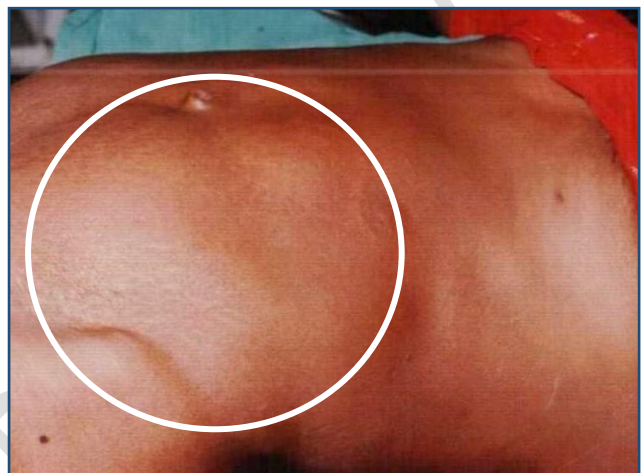

Fig-2 photograph showing lump in abdomen from pelvis to umbilicus

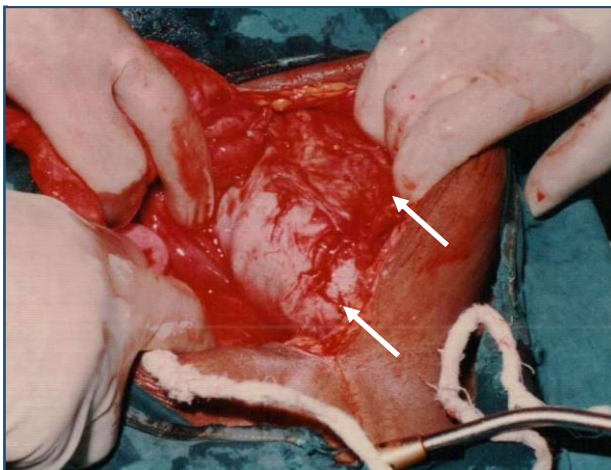


Fig-3 Intraoperative photograph showing left ovarian mass with omental adhesions

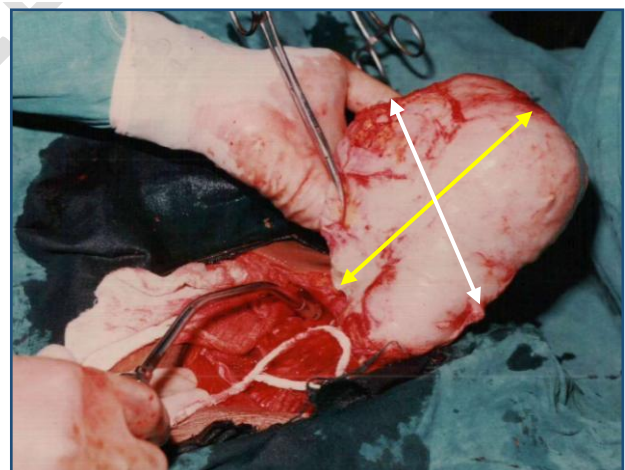


Fig-4 Intraoperative photograph showing left ovarian mass of size 15x12x8 cm

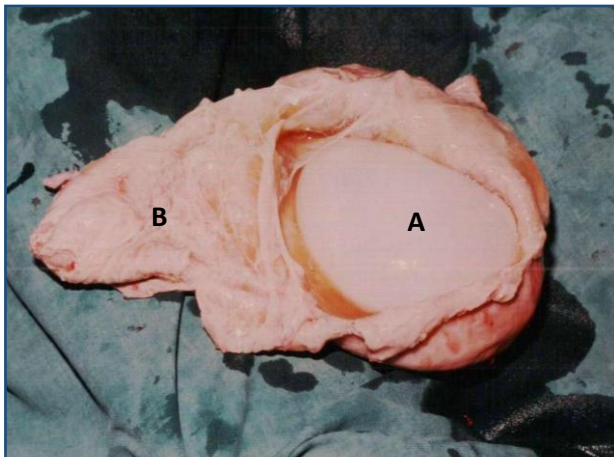


Fig-5 Cut section photograph showing A- egg white laminated endo cyst B- ovarian cyst wall

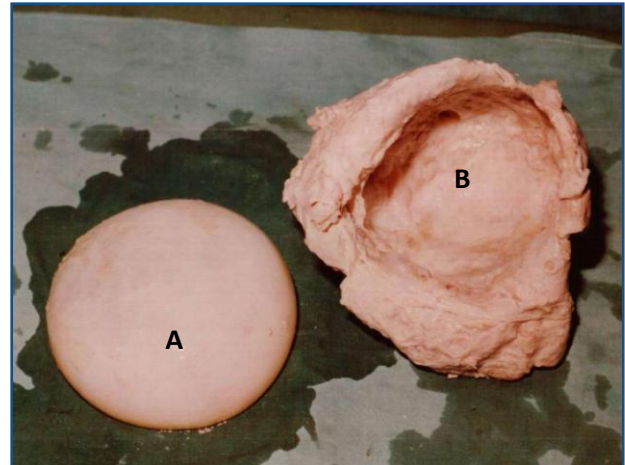


Fig-6 Cut section photograph showing A- Unilocular Endo cyst of hydatid B- ovary and Pericyst of hydatid

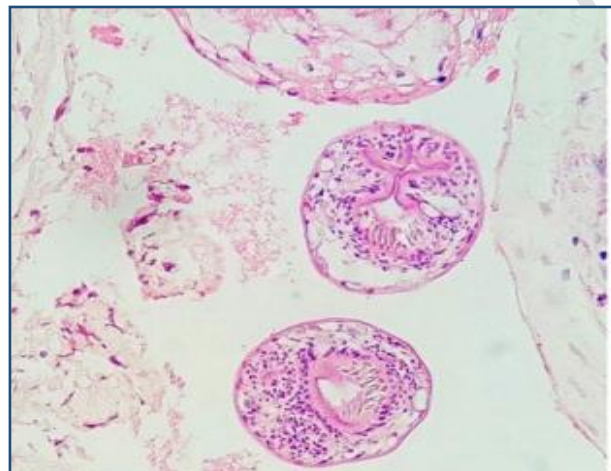


Fig-7 Photomicrographs of the brood capsules with scolices within the cyst lumen (H&E,400X)

Discussion

“Primary ovarian hydatid cyst is extremely rare entity. Most of the cases of ovarian hydatidosis are diagnosed preoperatively. Multilocular hydatid cyst of the ovary may not be differentiated from ovarian cystadenoma or cystic ovarian teratoma. Hydatid cyst has three layers, pericyst, germinal layer and laminated membrane”. [2,4]

“The primary ovarian hydatid cyst is very rare, with the incidence of 0.2 to 2.5% and only 20-27 cases are reported in the literature. Ovarian hydatid cyst may mimic an ovarian neoplasm because of non-specific clinical symptoms and radiological appearance. Ovarian hydatidosis usually presents with non-specific symptoms such as abdominal pain, abdominal lump, infertility and pressure symptoms on the pelvic organs”. [4,5]

The diagnosis of a hydatid cyst is based on clinical findings, serology and imaging techniques. On ultrasonography, a hydatid cyst appears as a well-defined anechoic lesion with daughter cysts, hydatid sand, and crystal clear fluid inside the hydatid cyst. The cyst wall also appears as a double echogenic line. Ultrasonography is a cost-effective imaging modality, but CT scan is superior owing to its higher sensitivity. Serological tests are useful for confirmation of a diagnosis of hydatid cyst, as the screening test and sensitivity varies from 60-80%.

“In the literature, ovarian hydatid cysts account for 0.4% to 0.6% by Arora et al, and 0.2 to 1% by Mohammad and Arif, which are extremely rare presentations. Surgery can be done by the open or laparoscopic technique. Ovarian cystectomy represents the gold standard treatment. Care must be

taken to reduce the risk of possible cystic rupture. Albendazole may be given both preoperatively and postoperatively". [3,4,5]

The other alternative is PAIR therapy (Puncture, Aspiration, Injection, Re-Aspiration). In PAIR therapy, ultrasound guided percutaneous aspiration of cystic is carried out, followed by injection of scolicidal substances such as 20% sodium chloride, 95% ethanol or betadine solution. The solution is left on for 15 minutes and then re-aspiration of cyst content is performed. The indication of PAIR therapy is.

1. Large, multiple cysts of liver, spleen, kidney and bones.
2. Inoperable cases
3. Relapses after surgery. [6,7]

Conclusion

Primary ovarian hydatid is on extremely rare disease. The ideal treatment for ovarian hydatid cyst is surgical excision either open or laparoscopic surgery. Care must be taken to avoid perioperative rupture of the cyst to avoid the recurrence of disease.

Ethical Approval:

As per international standard or university standard written ethical approval has been collected and preserved by the author(s).

Consent

As per international standard or university standard, patient(s) written consent has been collected and preserved by the author(s).

References

1. Ayad Ahmad Mohammed, Sardar Hassan Arif, Hydatid cyst of the ovary – a very rare type of cystic ovarian lesion: A case report, Case Reports in Women's Health, Volume 31, 2021, e00330, ISSN 2214-9112, <https://doi.org/10.1016/j.crwh.2021.e00330>.
2. Ray S, Gangopadhyay M. Hydatid cyst of ovary- a rare entity. J Turk Ger Gynecol Assoc. 2010 Mar 1;11(1):63-4. PMID: 24591898; PMCID: PMC3939309.
3. Cattorini L, Trastulli S, Milani D, Ciocchi R, Giovannelli G, Avenia N, Sciannameo F. Ovarian hydatid cyst: A case report. Int J Surg Case Rep. 2011;2(6):100-2. doi: 10.1016/j.ijscr.2010.12.005. Epub 2011 Mar 24. PMID: 22096695; PMCID: PMC3199687.
4. Shangpliang D, Baishya P, Dey B, Raphael V, Wankhar B. Ovarian hydatid cyst mimicking an ovarian neoplasm. Autops Case Rep [Internet]. 2020;10(3):e2020177. <https://doi.org/https://doi.org/10.4322/acr.2020.177>
5. Badge SA, Kujur MA, Meshram AT, Ovhal AG. Primary ovarian hydatid cyst. Med J DY Patil Univ [serial online] 2016 [cited 2023 Aug 22];9:661-2. Available from: <https://journals.lww.com/mjdy/pages/default.aspx/text.asp?2016/9/5/661/192158>

6. Shradha Mehta, Bhavana Mehta, Sandip Shah, Sanjay Vyas Primary ovarian hydatid cysts: A case series of two cases. (2022). *Indian Journal of Case Reports*, 8(3), 55-57. <https://doi.org/10.32677/ijcr.v8i3.3310>
7. Wangden T, Tshering S, Dorji N, et al. Pelvic Hydatid Cyst Mimicking Ovarian Cyst. *J South Asian Feder Obst Gynae* 2022;14(3):317–319
8. seifi S, Shadman A, Mardi A, Moradi asl E. Pelvic hydatid cyst presentation as an ovarian torsion: A rare case report. *SAGE Open Medical Case Reports*. 2022;10. doi:10.1177/2050313X221136997
9. Adewunmi OA, Basalingappa HM. Primary ovarian hydatid disease in the Kingdom of Saudi Arabia. *Saudi Med J*. 2004;25: 1697-700
10. Sharma A, Sengupta P, Mondal S, Raychaudhuri G. Hydatid cyst of ovary mimicking ovarian neoplasm with its imprint cytology. *The American Journal of Case Reports*. 2012 ;13:276-278. DOI: 10.12659/ajcr.883639. PMID: 23569548; PMCID: PMC3614337.

UNDER PEER REVIEW