

## **Preventive and healing effects of the total aqueous extract of the trunk bark of *Zanthoxylum gilletii* (De Wild.) P.G. Waterman (Rutaceae) on gastric acid reflux and non-reflux induced esophagitis in rats**

### **Abstract**

*Zanthoxylum gilletii* is a medicinal plant well known for its richness in phytochemicals and its use in Côte d'Ivoire in the traditional treatment of burns in esophagus. However, its bioactive anti-reflux and non-reflux oesophagitis potential has not yet been scientifically proven. This work aims at evaluating the preventive and curative anti-esophagitis potential of a total aqueous extract of *Z. gilletii* trunk bark (TAEZg) in rats. Thirty-six rats fasted for 24 h and divided into six groups of six rats each were used for each model of esophagitis induction, in particular the preventive model (acute, chronic, chronic exposure to naproxen followed by forced swimming test) and the healing model. Rats received as a pretreatment (preventive model) and treatment (healing model), TAEZg at 125, 250 and 500 mg / kg of body weight (b.w.) as well as omeprazole (preventive model) and misoprostol (healing model) at 30 and 0.012 mg / kg b.w respectively. As for the control groups, they received distilled water at 1 mL / 100 g b.w. The animals were sacrificed by over dose of ether and then the ulcer macroscopic parameters (ulceration surface, ulceration index, scores and inhibition percentages) and gastric secretion parameters (gastric volume, gastric acidity and gastric pH) were assessed. Biochemical parameters such as total proteins and some oxidative stress parameters (Malondialdehyde (MDA) and catalase (CAT)) were assessed. The results showed that pretreatment and treatment of rats with TAEZg at doses ranging from 125 to 500 mg / kg b.w significantly ( $P < 0.001$ ) and dose dependently reduced ulceration surface, ulceration index, gastric volume, gastric acidity, score and significantly ( $P < 0.001$ ) increase pH and inhibition percentage compared to control group 2. The inhibition percentages such as 93.71; 95.89; 91.03 and 98.20 % were recorded at 500 mg / kg in preventive model (acute, chronic and chronic exposure to naproxen followed by forced swimming test) and healing model respectively. Biochemical analysis showed a significant ( $P < 0.001$ ) increase in total protein, CAT levels and a significant decrease ( $P < 0.001$ ) in MDA level of the treated groups compared to the control group 2. In conclusion, TAEZg possessed a real preventive and healing anti-esophagitis effects in rats.

**Key words:** *Zanthoxylum gilletii*, esophagitis, naproxen, gastroesophageal acid reflux, rat

## INTRODUCTION

Esophagitis is an esophageal inflammation lining that can be caused either by gastroesophageal reflux disease [1,2] or by prolonged use of nonsteroidal anti-inflammatory drugs (NSAIDs) [3]. It is a major public health problem that affects both adults and children [4]. Approximately 8 to 33 % people worldwide suffer from reflux esophagitis [5]. In Côte d'Ivoire, according to a study conducted in hospitals, reflux esophagitis represents 37.30 % [6]. As for esophagitis caused by NSAIDs, it is no less well known. Many modern treatments such as antacids, anti secretories, anti histaminergics H<sub>2</sub> and proton pump inhibitors exist [7]. However, a large majority of the African population, especially the Ivorian, still turns to medicinal plants. Faced to this report, WHO [8] recommend verifying the effectiveness of these medicinal plants. It is accordingly that this study was interested in *Zanthoxylum gillettii*, a plant with anti-inflammatory and analgesic activity used traditionally to treat burns in esophagus [9,10]. However, no scientific studies were undertaken to explain *Z. gillettii* actions on gastroesophageal acid reflux and NSAIDs-induced esophagitis in rats. Therefore, this work was aimed to assess the preventive and healing effects of the total aqueous extract of *Z. gillettii* trunk bark (TAEZg) against esophagitis induced by gastroesophageal acid reflux and chronic exposure to NSAIDs in rats.

### 1-Material and methods

#### 1.1- Plant material

Fresh trunk bark of *Z. gillettii* (Rutaceae) was collected in Grand Yapo in the department of Agboville (Côte d'Ivoire). Taxonomic identification and authentication were established by the National Floristic Center of Felix Houphouët Boigny University (Abidjan, Côte d'Ivoire) with voucher number of 1332 and 1294 in Côte d'Ivoire National Herbarium.

#### 1.2- Animals

Adult albino *Wistar* rats of either sex of *Rattus norvegicus* species aged approximately 12 to 16 weeks old and weighting between 150 and 215 g were used. They were bred in the Animal house of Physiology, Pharmacology and Pharmacopeia Laboratory of the Nangui Abrogoua University (Abidjan, Côte d'Ivoire) according to the principles for the care and use of laboratory animals of the Ethical Committee of the University (Nangui Abrogoua University, Abidjan, Côte d'Ivoire). They were exposed to 12 h dark/light cycle and fed with FACI<sup>®</sup> pellets and water *ad libitum*. The various experimental protocols were followed in accordance with the protocols for the protection of laboratory animals of the European Council of Legislation 2012/707 / EU [11].

### **1.3- Chemicals**

The following references drugs were used: Ether (VWR International-Geldenaakfebaan464-B-3001 Leuven-Belgium), Omeprazole (Sanofi Aventis, France), Misoprostol (Cytotec<sup>R</sup>, Sanofi Aventis, France), Naproxen (Sanofi Aventis, France).

## **2- Methods**

### **2.1- Preparation of the total aqueous extract of *Zanthoxylum gillettii* trunk bark**

Fresh trunk barks of *Z. gillettii* was washed with distilled water, cut into small pieces and dried in desiccators (Mark Fruicell, France) at 45°C for one week. They were finely powdered with a machine (Mark RETSCH, type SM 100, Germany). One hundred grams of the powder of *Z. gillettii* trunk bark were infused in 1 L of distilled water for 15 min and filtered (Whatman no. 3). A Half liter distilled water at 100 ° C was added to the residue for a second 10 min infusion. This solution was also filtered and the filtrates were stored in desiccators (Mark Fruicell, France) at 45°C for 48 hours.

### **2.2- Preventive effect of the total aqueous extract of *Zanthoxylum gillettii* trunk bark**

#### **2.2.1- Acute reflux esophagitis induction in rats**

The method described by [12] with a slight modification was used to evaluate the anti-acid and/or antisecretory effects of the total aqueous extract of *Z. gillettii* trunk bark (TAEZg). Thirty-six rats fasted for 24 hours prior to reflux esophagitis were randomly divided into six groups of six rats each, including three males and three females. Groups 1 and 2 served as controls, received orally distilled water at 1 ml/100g b.w while Group 3, received omeprazole (30 mg/kg b.w) by oral route. Groups 4, 5 and 6, were orally pretreated with TAEZg at 125, 250 and 500 mg / kg b.w. respectively. One hour and thirty minutes after the administration of the solutions, a 3 cm incision was made under ether anesthesia in order to ligate the pylorus as well as the forestomach in all groups except Group 1. A longitudinal cardiomyotomy approximately 1 cm across the gastroesophageal junction was performed to increase gastroesophageal reflux. Six hours later, the rats were sacrificed by over dose of ether. The stomachs of each rat were removed, and the contents were drained into tubes after opening the pylorus in order to determine the volume of gastric juices and the pH. The gastric contents were centrifuged at 3000 rpm for 10 minutes. One milliliter of the total centrifuged gastric contents from each doubly-ligated rat was analyzed for titratable acidity against 0.01 mol/l NaOH at pH 7 using a pH meter (HANNA instruments HI 9025). The acidity was calculated according to [13]. The removed stomach-esophagus block was opened along the greater curvature for the stomach and longitudinally for the esophagus. The inner surface was examined for ulceration and the mucosal erosion was determined and scored by measuring the

lesions area. The sum of the areas was expressed as ulcer index ( $\text{mm}^2$ ). The scoring of esophagus lesions was established according to the method described by [12] (Table 1). The inhibition percentage (I) was calculated using the following formula:

$$\% I = \frac{(US_C - US_T)}{US_C} \times 100$$

Where  $US_C$  = ulcer surface area in control rats and  $US_T$  = ulcer surface area in pretreated rats.

**Table 1: Classification scale (“score”) for ulcerative lesions according to Nakamura *et al.***

(1982)	“score”	Ulcer form
	0	No ulcerations
	1	Presence of some ulcerations
	2	Total ulceration surface < $30 \text{ mm}^2$
	3	Total ulceration surface of > $30 \text{ mm}^2$
	4	Perforation

### 2.2.2- Chronic reflux esophagitis induction in rats

The method described by [14] with slight modification was used.

Thirty-six rats were fasted for 24 h. They were divided into six groups of six rats (three males and three females) each and were orally pretreated with distilled water, omeprazole and extract for 14 days. Groups 1 and 2 served as controls, received orally distilled water, at 1 ml/100 g b.w. Group 3, was pretreated with omeprazole (30 mg/kg b.w.) by oral route while groups 4, 5 and 6, were orally pretreated with TAEZg at 125, 250 and 500 mg/kg b.w respectively. The ligation of the pylorus as well as the forestomach was made under ether anesthesia one hour and thirty minutes after the last administration (day 14) of the solutions except group 1. A 1 cm longitudinal cardiomyotomy across the gastroesophageal junction was made to increase gastroesophageal reflux. Six hours later, rats were sacrificed using ether. The rest of the protocol was similar to acute reflux esophagitis induction in rats.

### 2.2.3-Chronic exposure to non-steroid anti-inflammatory drugs (NSAIDs) combined with forced swimming test in rats

The method described by [15] with slight modification was used. Thirty-six rats were fasted for 24 h. They were divided into six groups of six rats each, including three males and three females. Group 1 served as control 1, received orally distilled water at 1 ml/100 g b.w. for 10 days while groups 2 (control 2) to 6, received daily by oral route naproxen (30 mg/kg bw;) for 10 days. On the 10th day of the chronic exposure to naproxen, half an hour before being subjected to forced swimming test, groups 3, 4, 5 and 6, corresponding to the pretreated

groups, received orally and respectively, misoprostol (0.012 mg / kg) and TAEZg at 125, 250 and 500 mg / kg b.w. while group 2 received only distilled water at 1 ml/100 g b.w. After the last administration of the substances, all the animals except those of group 1 were subjected to forced swimming test for 3.5 hours according to the method described by [16] in order to induce more severe damages in rats. The rats were thereafter sacrificed using ether. The removed stomach-esophagus block was opened along the greater curvature for the stomach and longitudinally for the esophagus. The inner surface was examined for ulceration. The rest of the protocol is similar to acute reflux esophagitis induction in rats.

### **2.3- Healing effect of the total aqueous extract of *Zanthoxylum gillettii* trunk bark**

The method described by [13] with a slight modification was used.

Thirty-six rats, fasted for 24 h, were divided into six groups of six rats each, including three males and three females. A double ligation (Pylorus and forestomach) was made under ether anesthesia in groups 2 (control 2), 3, 4, 5 and 6 except control group 1. A 1 cm longitudinal cardiomyotomy across the gastroesophageal junction was performed in order to increase gastroesophageal reflux. Ten minutes after this double ligation, the rats received orally and respectively in first treatment, omeprazole (30 mg/kg bw) (group 3) and TAEZg at 125 (group 4), 250 (group 5) and 500 mg / kg b.w. (group 6). The control groups 1 and 2 received orally distilled water at 1 ml/100 g b.w. Three hours and thirty minutes later, a second treatment was carried out under the same conditions as the previous one. Thirty minutes after the last administration of the various oral solutions, i.e. 4 hours after the double ligation, before sacrificing rats, a blood samples from all of rats group were collected by ocular puncture in dried tubes, using Pastor pipettes in order to assay total proteins according to the method of [17]. All the animals were sacrificed by over dose of ether. The rest of the protocol is similar to acute reflux esophagitis induction in rats. 500 mg of esophageal tissues were further subjected to estimations of some oxidative stress parameters such as Malondialdehyde and catalase according to the methods described by [18] and [19] respectively.

### **2.4-Statistical analysis**

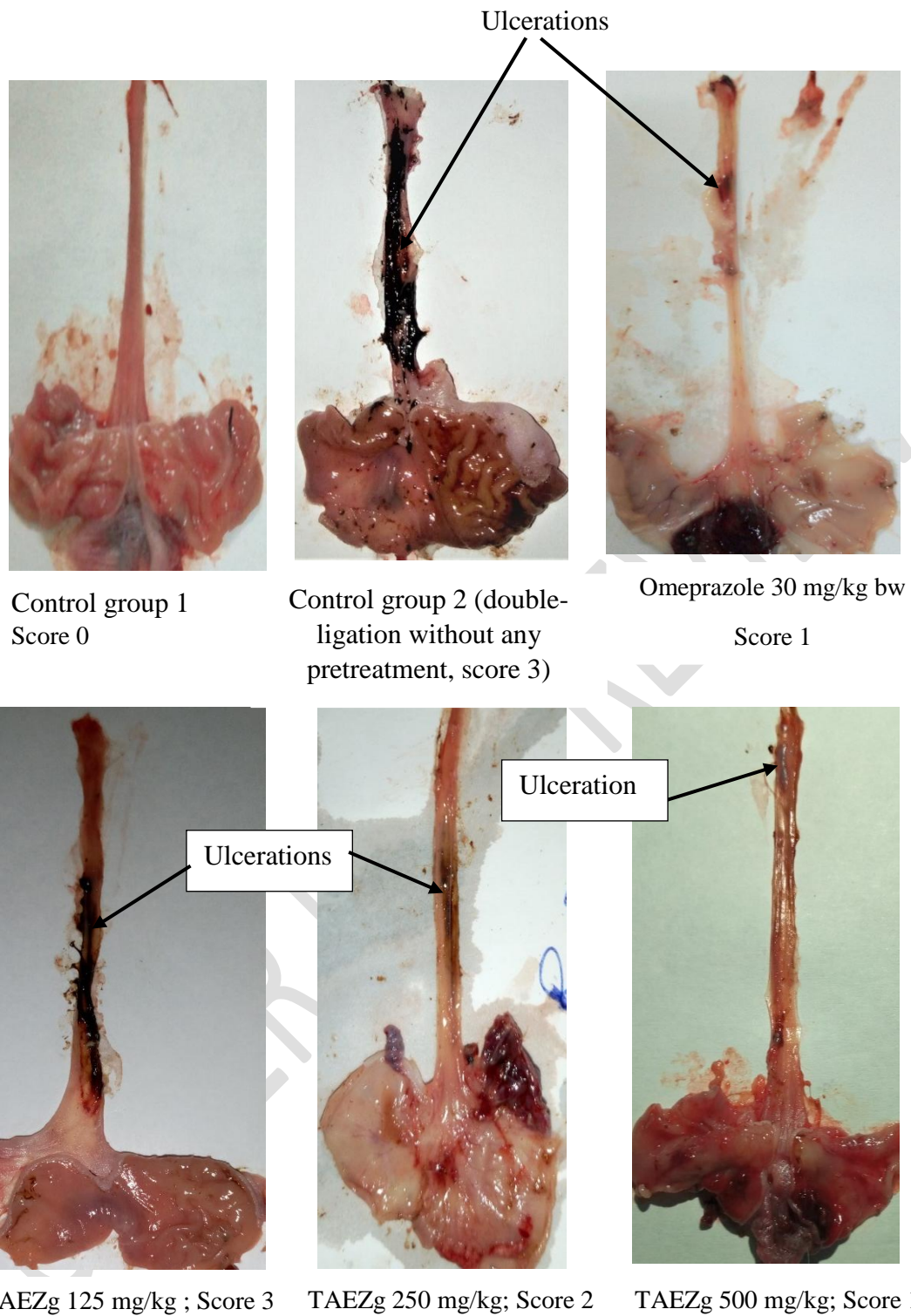
Data were analyzed using Graph Pad Prism 7.0 software (San Diego, California, USA) and presented as mean  $\pm$  standard error on mean (M  $\pm$  SEM). Comparisons between treated groups and controls were made using Student's t test and one-way analysis of variance (ANOVA). Tukey–Kramer was used as post-hoc test. Values were considered statistically significant when  $P < 0.05$ .

## **3- Results**

### **3.1- Preventive effect of the total aqueous extract of *Zanthoxylum gillettii* trunk bark**

#### **3.1.1- Acute reflux esophagitis induction in rats**

In group 1, no lesions were observed in the esophageal mucosa. The score obtained is 0 (figure 1). On the other hand, in the control group 2, the esophageal tissue showed various longitudinal erosions and ulcers compared to the control group 1 (figure 1). Severe hemorrhage induced by inflammation compared to the control group 1 was also observed (figure 1). An ulceration index of  $3.76 \pm 0,38$  and an ulceration surface of  $101 \pm 15.9 \text{ mm}^2$  were recorded respectively, corresponding to  $3.33 \pm 0.21$  (score) and  $6.67 \pm 0.71 \text{ ml}$  (gastric juice),  $1.92 \pm 0.32$  (pH) and  $103 \pm 4.22 \text{ mEq / l}$  (gastric acidity) (Table 2). Pretreatment with omeprazole (30 mg/kg b.w.) and TAEZg at doses ranging from 125 to 500 mg / kg b.w., significantly ( $P < 0.001$ ) and dose- dependently induced a decrease in gastric juice, gastric acidity, ulceration surface, ulceration index, scores and significantly ( $P < 0.001$ ) increased the pH and percentage of inhibition recorded in the pretreated group compared to control group 2. The severity of esophageal lesions induced was also significantly ( $P < 0.001$ ) reduced in a dose-dependent manner compared to control group 2. These decrease and increase are significant ( $P < 0.001$ ) at 500 mg/kg b.w with the extract. The inhibition percentage recorded at this dose is 93.71 % (Table 2).



**Figure 1: Photographs of stomach-esophageal blocks after acute pretreatment of esophageal lesions induced in rats**

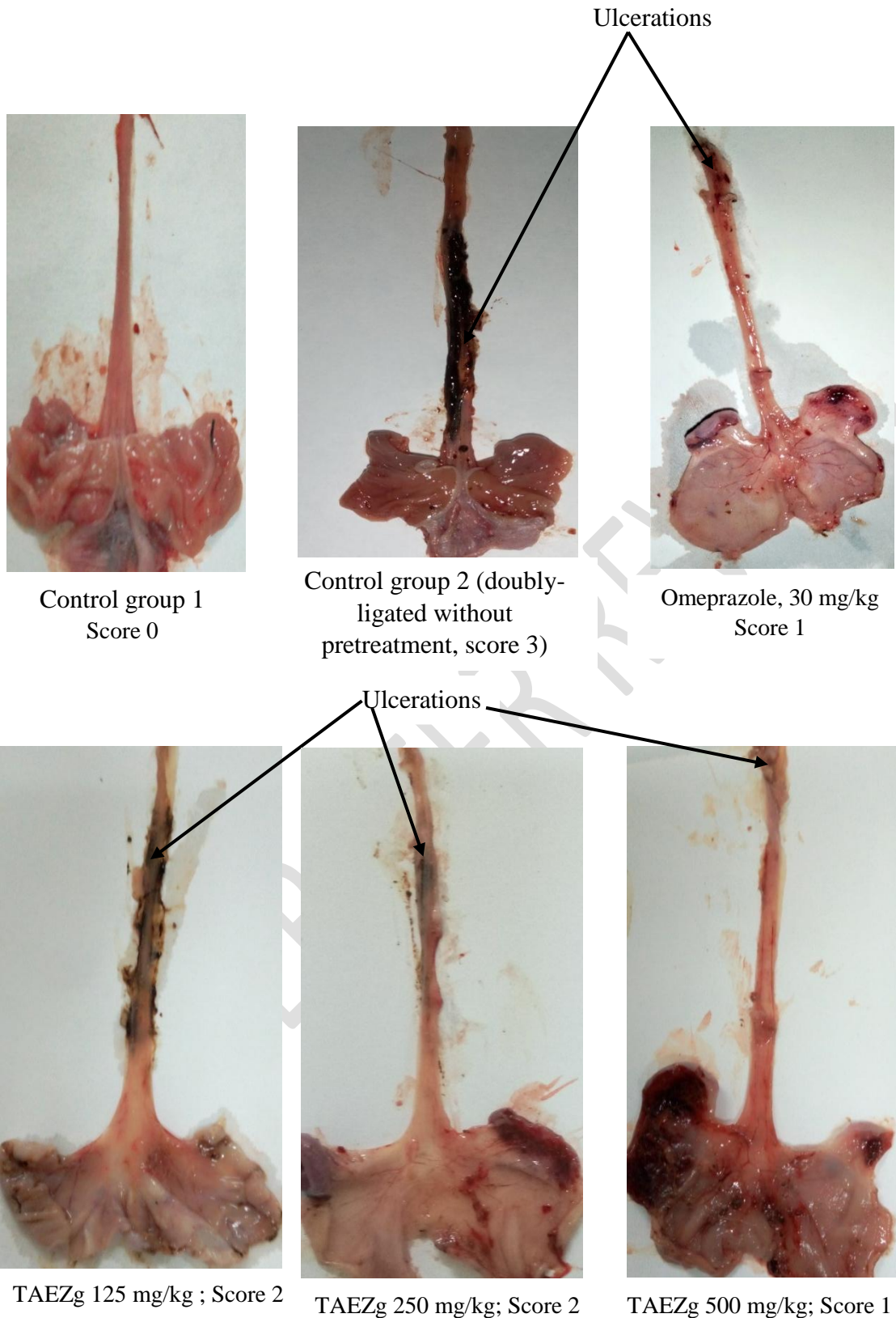
**Table 2: Some parameters after acute pretreatment of esophageal lesions induced in rats.**

Groups	Dose (mg/kg)	VG (ml)	pH	GA (mEq/l)	US (mm <sup>2</sup> )	UI	%I	Score
Control group 1	-	-	-	-	00 ±00	00 ±00	-	00 ±00
Control group 2	-	6,67±0,71	1,92±0,32	103 ±4,22	101±15,9	3,76±0,38		3,33 ±0,21
Omeprazole	30	2,67±0,42 <sup>***</sup>	2,83 ± 0,46	28,3±5,27 <sup>***</sup>	8,35 ±3,51 <sup>***</sup>	1,02±0,01 <sup>***</sup>	91,17	1,00 ± 0.36 <sup>***</sup>
	125	3,93±0,75 <sup>***</sup>	1,93±0,26	61,7±4,77 <sup>***</sup>	63,2±5,2 <sup>***</sup>	1,83±0,44 <sup>***</sup>	37,32	2,06 ±0.11 <sup>*</sup>
TAEZg	250	3,02±0,35 <sup>***</sup>	2,38 ± 0,20	29,3±8,74 <sup>***</sup>	19,6±7,4 <sup>***</sup>	1,12±0,38 <sup>***</sup>	80,56	2,00 ± 0.48 <sup>**</sup>
	500	1,92±0,32 <sup>***</sup>	3,57±0,19 <sup>**</sup>	23,3±4,22 <sup>***</sup>	6,35±3,09 <sup>***</sup>	0,4±0,03 <sup>***</sup>	93,71	1,00 ± 0.25 <sup>***</sup>

Values in the same column are statistically different from those in control group 2 at \*P < 0.05; \*\*P < 0.01; \*\*\*P < 0.001; n = 6. Control group 1: rats given only distilled water; Control group 2: rats given only distilled water and doubly ligated (pylorus and forestomach); TAEZg: Total aqueous extract of *Zanthoxylum gillettii* trunk bark, VG: Volume of gastric juice; GA: gastric acidity; US: ulceration surface; UI: Ulcer index; % I: percentage inhibition

### 3.1.2- Chronic reflux esophagitis induction in rats.

As shown in Figure 2 and Table 3 no visible esophageal mucosal lesion was observed as well as gastric juice, gastric acidity, ulceration surface, ulceration index, scores, pH and percentage of inhibition in control group 1. Oppositely, in control group 2, a gross morphological change such as severity long mucosal erosion and ulcer were observed compared to control group 1 (figure 2). Ulceration surface and ulceration index recorded, are  $71.4 \pm 4.61 \text{ mm}^2$  and  $3.19 \pm 0.82$  respectively. Score ( $3 \pm 00$ ), gastric juice ( $5.97 \pm 0.555 \text{ ml}$ ), gastric acidity ( $71.7 \pm 4.77 \text{ mEq / l}$ ) and pH ( $1.97 \pm 0.32$ ) were also recorded in this group (Table 3). Furthermore, in rats pretreated with omeprazole (30 mg/kg b.w.) and TAEZg at doses ranging from 125 to 500 mg / kg b.w. the esophageal mucosal was less damage than control group 2 and no severity of esophageal mucosal lesions was visible at 500 mg/kg b.w. A significant ( $P < 0.001$ ) and dose-dependent decrease in gastric juice, gastric acidity, ulceration surface, ulceration index, scores and significant ( $P < 0.001$ ) increased in pH and percentage of inhibition were recorded in these pretreated groups compared to the control group 2. These decrease and increase are significant ( $P < 0.001$ ) at 500 mg/kg b.w. with inhibition percentage of 93.71 % (Table 3).



**Figure 2: Photographs of stomach-esophageal blocks after chronic pretreatment of esophageal lesions induced in rats**

**Table 3: Some parameters after chronic pretreatment of esophageal lesions induced in rats**

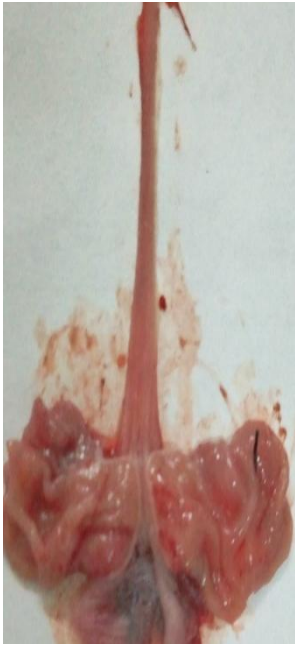Groups	Dose (mg/kg)	VG (ml)	pH	GA (mEq/l)	US (mm <sup>2</sup> )	UI	%I	Score
Control group 1	-	-	-	-	00 ±00	00 ±00	-	00 ±00
Control group 2	-	5,97 ± 0,55	1,97±0,32	71,7 ±4,77	71,4±4,61	3,19±0,82	-	3,00 ± 0,00
Omeprazole	30	2,13±0,36***	4,30±0,43**	23,3±3,33***	3,65 ±1,78***	1,01±0,05 ***	94,89	1,10±0,41***
TAEZg	125	4,90±0,81	2,88±0,5 *	28,3±6,01***	38,1±11,8*	1,81±0,04***	46,64	2,00 ± 0,04
	250	2,15±0,54***	3,12±0,47 **	21,7 ±4,77***	9,51±3,81***	1,1±0,1***	86,65	1,07±0,08***
	500	2,08±0,56***	4,70±0,27***	15,8±5,23***	2,94±1,32***	0,4±0,03***	95,89	1,00 ±0,02***

Values in the same column are statistically different from those in control group 2 at \*P < 0.05; \*\*P < 0.01; \*\*\*P < 0.001; n = 6. Control group 1: rats given only distilled water; Control group 2: rats given only distilled water and doubly ligated (pylorus and forestomach); TAEZg: Total aqueous extract of *Zanthoxylum gillettii* trunk bark, VG: Volume of gastric juice; GA: gastric acidity; US: ulceration surface; UI: Ulcer index; % I: percentage inhibition

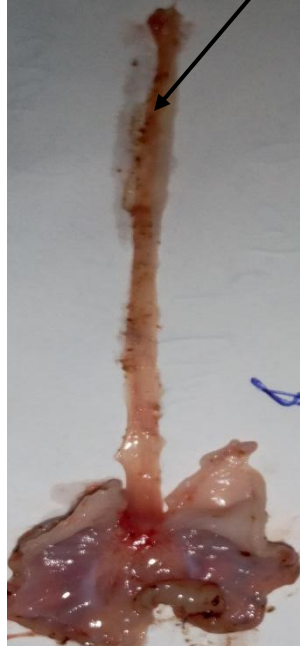### 3.3-Chronic exposure to naproxen followed by forced swimming test in rats

In control group 1, no lesions were observed in the esophageal mucosa (Figure 3). This results in an absence of ulceration surface, score, ulceration index (Table 4). On the other hand, in the control group 2 receiving naproxen (30mg / kg) orally for 10 days and carried out the forced swimming test, severe gross esophageal mucosal lesions were observed compared to the control group 1 (Figure 3). The ulceration surface, ulceration index and score recorded are  $58.1 \pm 12 \text{ mm}^2$ ,  $2.6 \pm 0.71$  and  $3.1 \pm 0.28$  respectively (Table 4). In addition, oral administration of TAEZg at doses ranging from 125 to 500 mg / kg to rats pretreated with naproxen for 10 days, induced a significant decrease ( $P < 0.01$ ) and dose dependently the severity of esophageal lesion compared to control group 2. A significant decrease ( $P < 0.01$ ) corresponding to  $13.5 \pm 5$  and  $5.5 \pm 2.82 \text{ mm}^2$  (surface ulcerations),  $0.9 \pm 0.21$  and  $0.45 \pm 0.05$  (ulcer index);  $1 \pm 0.58$  and  $1 \pm 0.01$  (score) were recorded at 250 and 500 mg / kg respectively (Table 4). An increase in the inhibition percentage from 24.18 % (125 mg / kg) to 90.56 % (500 mg / kg) was recorded (Table 4). As for misoprostol, its administration to rats pretreated with naproxen for 10 days induced a significant ( $P < 0.01$ ) reduction in the ulceration surface and score, compared to control group 2. The values recorded are  $25.8 \pm 5.56 \text{ mm}^2$ ,  $1.02 \pm 0.01$  respectively. However, the ulceration index decreased significantly ( $P < 0.05$ ) compared to control group 2 and was  $1.02 \pm 0.01$  with 55.75 % as percentage inhibition (Table 4).

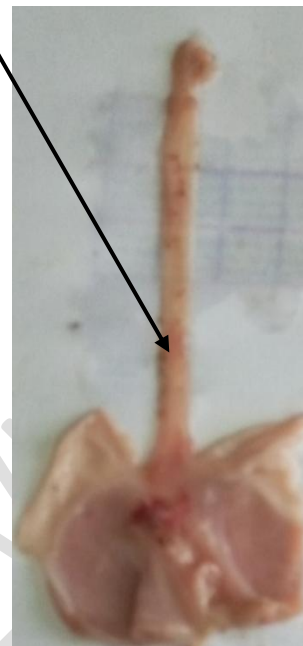
Ulcerations



Control group 1  
Score 0

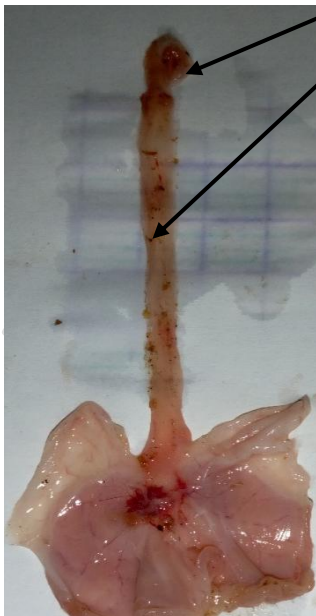


Naproxen control group 2 (Score 3)

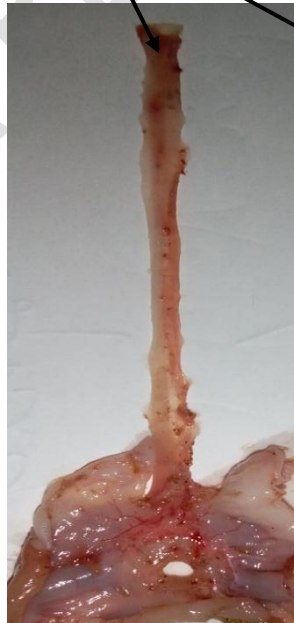

Misoprostol 0,012 mg/kg  
(Score 1)

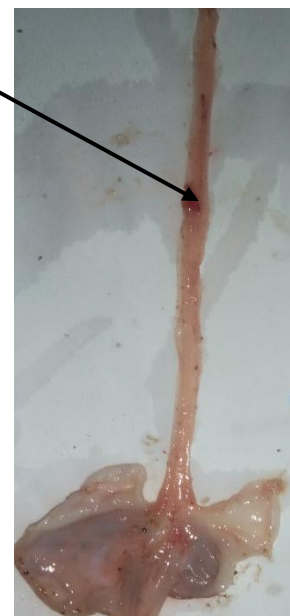Ulcerations



TAEZg 125 mg/kg ; Score 3



TAEZg 250 mg/kg; Score 2



TAEZg 500 mg/kg; Score 1

**Figure 3: Photographs of the pretreatments on lesions induced by naproxen followed by the forced swimming test in rats**

Groups	Dose (mg/kg)	US (mm <sup>2</sup> )	UI	% I	Score
Control group 1	-	00 ±00	00 ±00	-	00 ±00
Control group 2	-	58,3±12,0	2,8±0,71	-	3,1 ± 0,28
Misoprostol	0,012	25,8±5,56*	1,02±0,01*	55,75	1,88±0,03 **
TAEZg	125	44,2±12,4	1,4±0,31	24,18	2±0,01
	250	13,5±5,18**	0,9±0,21*	76,84	1,00 ± 0,58 **
	500	5,50±2,85**	0,45±0,05**	90,56	1±0,01 ***

**Table 4: Some parameters after pretreatment of esophageal lesions induced by naproxen followed by forced swimming test in rats**

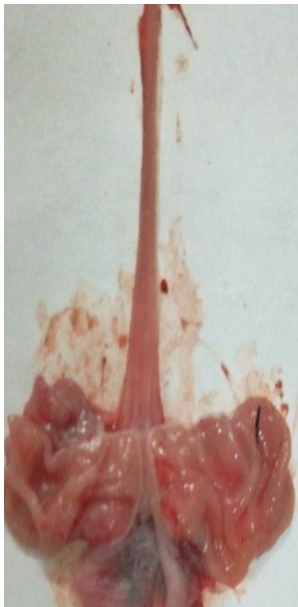Values in the same column are statistically different from those in control group 2 at \*P < 0.05; \*\*P < 0.01; \*\*\*P < 0.001; n = 6. Control group 1: rats given only distilled water; Control group 2: rats given only naproxen; TAEZg: Total aqueous extract of *Zanthoxylum gillettii* trunk bark, US: ulceration surface; UI: Ulcer index; % I: percentage inhibition.

### **3.4-Healing effect of the total aqueous extract of *Zanthoxylum gillettii* trunk bark on esophageal lesions induced by double ligation in rats**

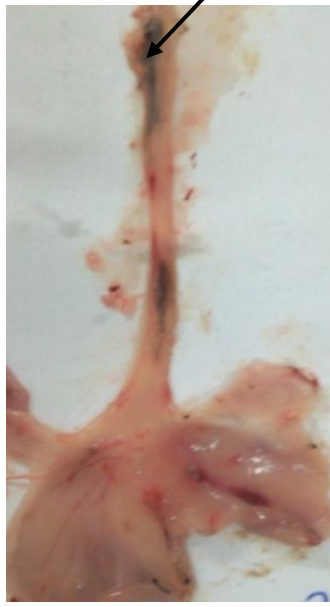In the absence of healing treatment, no lesions of the esophageal mucosa were observed in the rats of control group 1 (Figure 4). However, in the control group 2, the volume of gastric juice produced was 5.50 ± 0.42 ml with 2.27 ± 0.47 and 46.7 ± 7.15 (mEq / l) as gastric pH and gastric acidity respectively. The ulceration surface, ulceration index and score recorded, are 32.4 ± 10.5 mm<sup>2</sup>, 2.01 ± 0.04. and 3.00 ± 0.62 respectively (Table 5).

In rats treated with omeprazole at 30 mg / kg b.w., a significant reduction (P <0.001) in gastric acidity (11.7 ± 3.33 mEq / l), gastric juice (2.23 ± 0.48 ml), ulceration surface (0.67 ± 0.28 mm<sup>2</sup>), ulceration index (0.95 ± 0.01) and score (1.01 ± 0.03) as well as a significant increase (P <0.001) in gastric pH (4.25 ± 0.30) was observed compared to control group 2. The percentage of cure recorded is 97.93 %. (Table 5). Treatment of rats with TAEZg at doses

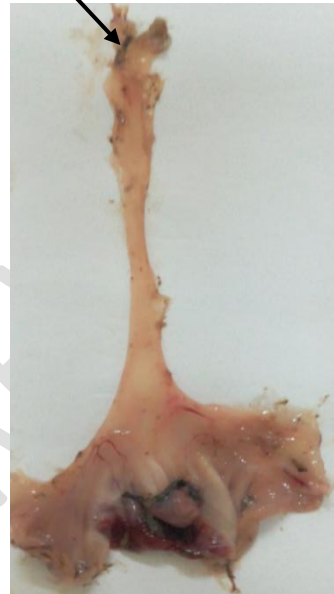
ranging from 125 to 500 mg / kg b.w. induced a significant ( $P < 0.001$ ) and dose dependent decrease in ulceration surface, gastric acidity, gastric juice, ulceration index and scores compared to the control group 2. Gastric juice at doses of TAEZg ranging from 125 to 500 mg / kg b.w decreases from  $4.00 \pm 0.86$  ml (125 mg / kg b.w) to  $2.20 \pm 0.46$  ml (500 mg / kg b.w). Gastric acidity reaches  $10.8 \pm 1.89$  (mEq / l) at 500mg / kg bw. The ulceration surface and ulceration index, vary from  $12.8 \pm 5.2$  to  $0.58 \pm 0.49$  mm<sup>2</sup> and from  $1.5 \pm 0.07$  to  $0.55 \pm 0.04$  when TAEZg was orally administered to rats at doses ranging from 125 to 500 mg / kg b.w. respectively, inducing an increase in percentage inhibition from 60.49 (TAEZg, 125 mg / kg b.w) to 98.20 % (TAEZg, 500 mg / kg b.w). However, TAEZg induced a significant increase ( $P < 0.001$ ) in gastric pH from  $3.5 \pm 0.43$  to  $4.42 \pm 0.42$  at 250 and 500 mg / kg bw. The scores recorded are between  $2.03 \pm 0.40$  (TAEZg, 125mg / kg) and  $1.00 \pm 0.04$  (TAEZg, 500 mg / Kg).



Control group 1  
Score 0



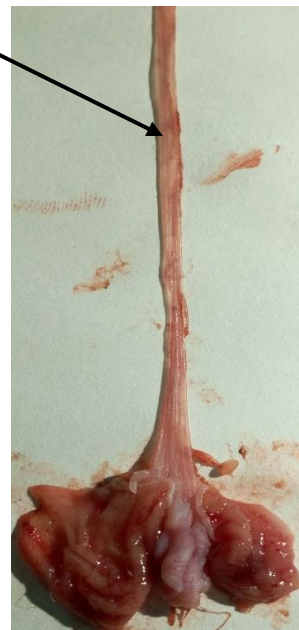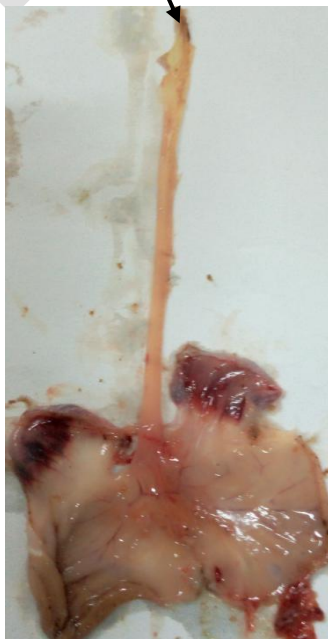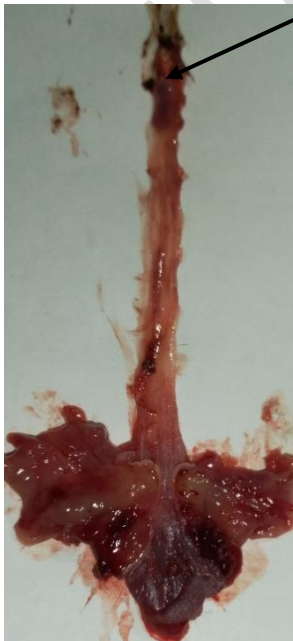Control group 2 (doubly-ligated without treatment, score 3)



Omeprazole 30 mg/kg b.w.  
(Score 1)

Ulcerations

Ulcerations



TAEZg 125 mg/kg

Score 2

TAEZg 250 mg/kg

Score 1

TAEZg 250 mg/kg

Score 1

**Figure 4: Photographs of stomach-esophageal blocks after curative treatments on esophageal lesions induced by pyloric and forestomach ligation in rats**

UNDER PEER REVIEW

Table 5: Some parameters after curative treatments of esophageal lesions induced by pyloric and forestomach ligation in rats.

Values in the same column are statistically different from those in control group 2 at \*P < 0.05; \*\*P < 0.01; \*\*\*P < 0.001; n = 6. Control group 1: rats given only distilled water; Control group 2: rats given only distilled water and doubly ligated (pylorus and forestomachs); TAEZg: Total aqueous extract of the trunk bark of *Zanthoxylum gillettii*, VG: Volume of gastric juice; GA: gastric acidity; US: ulceration surface; UI: Ulcer index; % I: percentage inhibition

Groups	Dose (mg/kg)	VG (ml)	pH	GA (mEq/l)	US (mm <sup>2</sup> )	UI	%I	Score
--------	-----------------	---------	----	------------	-----------------------	----	----	-------

Control group 1	-	-	-	-	00 ±00	00 ±00	-	00 ±00
Control group 2	-	5,50 ± 0,42	2,27± 0,47	46,7±7,15	32,40 ±10,5	2,01±0,04	-	3,00±0,62
Omeprazole	30	2,23±0,48***	4,25±0,30***	11,7±3,33***	0,67±0,28***	0,95±0,01***	97,93	1,01±0,03*
TAEZg	125	4,00±0,86**	2,83±0,60	23,3±5,58***	12,8±5,2***	1,5±0,7***	60,49	2,03 ± 0,40
	250	2,80±0,48***	3,5±0,43***	18,3±3,07***	1,22±0,78***	0,8±0,01***	96,23	1,02± 0,01*
	500	2,20 ± 0,46***	4,42±0,45***	10,8±1,89***	0,58±0,49***	0,55±0,04***	98,20	1,00±0,04*

UNDER PEER REVIEW

### 3.5-Effect of the total aqueous extract of *Zanthoxylum gillettii* trunk bark on some biochemical parameters in rats

As shown in Table 6, the total proteins (TP) level in the control group 1 is  $8.10 \pm 0.38$  mg / dl. However, in the control group 2, a significant decrease ( $P < 0.001$ ) in TP level was observed compared to the control group 1 and was  $3.90 \pm 0.67$  mg / dl. Treatment of rats with TAEZg at 250 and 500 mg / kg bw, and omeprazole at 30 mg / kg b.w induced significant ( $P < 0.001$ ) increase in TP levels compared to the control group 2. This TP level is  $6.70 \pm 0.10$  (omeprazole 30 mg / kg b.w), and  $7.15 \pm 0.12$  mg / dl for TAEZg at 500 mg / kg b.w. Malondialdehyde (MDA) level in the control group 1 is  $9.62 \pm 0.69$  nM / g proteins. This level increased significantly ( $P < 0.001$ ) in the control group 2 to  $23.3 \pm 1.45$  nM / g protein compared to the control group 1. However, treatment of rats with omeprazole at 30 mg / kg b.w and TAEZg at doses ranging from 125 to 500 mg / kg b.w, significantly ( $P < 0.001$ ) decreased MDA level compared to the control group 2. The level of MDA is  $10.8 \pm 1.66$  (omeprazole 30 mg / kg) and ranges from  $16.9 \pm 2.36$  (125mg / kg) to  $11.00 \pm 3.03$  (TAEZg 500 mg / kg bw). On the other hand, the level of catalase (CAT) which was  $28.3 \pm 4.42$   $\mu\text{M H}_2\text{O}_2 / \text{min} / \text{ml}$  in the control group 1, decreased significantly ( $p < 0.001$ ) in the control group 2 and was  $13.0 \pm 4.24$   $\mu\text{M H}_2\text{O}_2 / \text{min} / \text{ml}$ . In addition, treatment of rats with omeprazole at 30 mg / kg and TAEZg (from 125 to 500 mg / kg bw), induced significant increase ( $P < 0.001$ ) in CAT level compared to the control group 2. This level varies from  $20.9 \pm 3.01$  (TAEZg, 125 mg / kg of bw) to  $25.6 \pm 5.03$  (TAEZg, 500 mg / kg of bw)  $\mu\text{MH}_2\text{O}_2 / \text{min} / \text{ml}$  and was  $25.4 \pm 4.56$   $\mu\text{mol H}_2\text{O}_2 / \text{min} / \text{ml}$  for omeprazole at 30 mg / kg.

**Table 6: Serum total protein, Malondialdehyde and Catalase levels in rats**

Groups	Dose (mg/kg)	TP (mg/dl)	MDA (nM / g proteins)	CAT ( $\mu\text{M}$ $\text{H}_2\text{O}_2/\text{min}/\text{mg protein}$ )
Control group 1	-	$8,10 \pm 0,38$	$9,62 \pm 0,69$	$28,3 \pm 4,42$
Control group 2	-	$3,90 \pm 0,44^{###}$	$23,3 \pm 1,45^{###}$	$13,0 \pm 4,24^{###}$
Omeprazole	30	$6,70 \pm 0,10^{***}$	$10,8 \pm 1,66^{***}$	$25,4 \pm 4,56^{***}$
TAEZg	125	$4,35 \pm 0,54$	$16,9 \pm 2,36^{***}$	$20,9 \pm 3,01^{***}$
	250	$5,13 \pm 0,24^{***}$	$14,2 \pm 1,01^{***}$	$23,4 \pm 3,12^{***}$
	500	$7,15 \pm 0,12^{***}$	$11,00 \pm 3,03^{***}$	$25,6 \pm 5,03^{***}$

Values in the same column are statistically different from the control group 1 at  $###P < 0.001$ .

Values in the same column are statistically different from those in the control group 2 (doubly ligated) at \*\*\*  $P < 0.001$ ;  $n = 6$ . Control group 1: rats given only distilled water; Control group 2: rats given only distilled water and doubly ligated (pylorus and forestomach); TAEZg: Total aqueous extract of the trunk bark of *Zanthoxylum gillettii*; TP: Total protein, MDA: Malondialdehyde; CAT: Catalase

#### 4-Discussion

In this present work, the total aqueous extract of *Zanthoxylum gillettii* trunk bark (TAEZg) prevents and heal markedly esophageal mucosal lesion at doses ranging from 125 to 500 mg / Kg b.w. Therefore, TAEZg possessed a real anti-esophagitis potential. This protection of the esophageal mucosa is due to the cytoprotective and anti-secretory effect of this extract. These results are similar to those of [20] and [21] respectively with the aqueous extract of the seeds of *Trigonella (Foenum graecum)* and the dichloromethane fraction of *Geranium koreanum*. Indeed, these authors have shown that these medicinal plant extracts significantly reduced esophagitis induced experimentally in rats by protecting the esophageal mucosa. It is known that under normal physiological conditions, gastroesophageal reflux disease can occur immediately after the completion of a meal and this does not damage the esophageal mucosa. The esophagus in this case is protected against reflux by effective defensive systems such as anti-reflux barriers, the luminal release mechanism and the resistance of the esophageal epithelium [22]. However, if gastroesophageal reflux continues for a long time, it exposes the glandular mucosa of the esophagus to acid which causes necrosis of the superficial epithelial cells of the esophagus while causing damage [23]. This would explain the very large surface of ulceration observed in the control rats doubly ligated (pylorus and forestomach) and without treatment. However, authors have reported that the effectiveness of a substance in preventing or curing lesions is attributable to its anti-secretory and cytoprotective [24,25]. In order to verify the preventive and curative potential of TAEZg, the study of the effects of this extract was undertaken on experimental models of esophagitis induction by gastroesophageal reflux and non-reflux using naproxen (NSAIDs) followed by the forced swimming test in rats.

The analysis of the results of this study indicates that the ulceration surface, score, ulceration index, gastric volume and gastric acidity are significantly reduced by TAEZg. This extract also increases dose-dependently the pH and the percentage inhibition in the pretreated and treated groups compared to control groups 2 respectively. These results reflect the protection

and healing of the esophageal mucosa. This is believed to be due to the neutralization of gastric acidity. TAEZg would therefore have the capacity to stimulate the production of mucus. These results are similar to many medicinal plant extracts such as *Quisqualis indica* [26] and *Perilla frutescens* [27]. According to these authors, the cytoprotection of extracts from these plants is due to the production of mucus and their antisecretory activity. Omeprazole is a reference drug that shows protection against mucosal damage at doses that do not inhibit mucus secretion [28], Its oral administration to rats at 30 mg / kg during these experiments caused a significant reduction in esophageal mucosa lesions induced by reflux. This anti-secretory effect of this drug is thought to be due to the reduction in the aggressive power of acid secretion following the specific inhibition of the H<sup>+</sup> / K<sup>+</sup> ATPase pump of the parietal cell [29]. The effect of TAEZg which is almost similar to that of omeprazole shows that just like this drug, this extract could also inhibit H<sup>+</sup> / K<sup>+</sup> ATPase pumps by inducing the almost complete suppression of acid secretion in animals at except for controls. This result suggests that TAEZg would be endowed with a real anti-secretory potential. Further experiments are needed to support this hypothesis.

Naproxen, a derivative of arylpropionic acid, belongs to the therapeutic class of nonsteroidal anti-inflammatory drugs (NSAIDs). Its ulcerative activity is due to the induction of esophageal lesions by the reduction in the level of prostaglandins or by inhibition of prostaglandin synthesis or by reversible inhibition of COX-1 and COX-2 cyclo-oxygenase [30]. Repeated administration of naproxen (30 mg / kg) for ten days to rats severely weakened the esophageal mucosa. This mucous membrane becomes more fragile when animals were subjected to stress by forced swimming. In order to assess the cytoprotective effect of TAEZg, this extract was evaluated on esophageal lesions induced by naproxen followed by the forced swimming test in rats. The results of this study indicates that oral administration of misoprostol at 0.012 mg / kg b.w. and TAEZg at doses ranging from 125 to 500 mg / kg b.w. induced a significant reduction in the ulceration surface, ulceration index and score as well as an increase the percent inhibition in rats compared to the control group 2. This reflects the protection of the esophageal mucosa. This protection is explained by a stimulation by the extract prostaglandins synthesis which by improving the resistance of the mucosa, probably increased the secretion of mucus and bicarbonates which, moreover, are part of the defense factors of the integrity of the mucous membranes [31]. More elaborate experiments may help to elucidate this mechanism.

In order to understand the role of certain biochemical parameters as an indicator of protection of the esophageal mucosa in the beginning of TAEZg probable mechanism elucidation,

assessment of total proteins and certain biomarkers of oxidative stress such as CAT and MDA was performed. The results of this study showed a significant increase in TP and CAT levels and a significant decrease in MDA level in treated rats compared to control group 2. These results agree with [32] and [33] who reported that administration of *Platycodin D* (*Platycodon grandiflorum*) and aqueous extract of *Artemisia campestris* to rats significantly modified the levels of these substances. Moreover, according to [34], proteins regulate metabolism and control the transfer of information, matter and energy. The increase in proteins level observed in animals except control group 2, is due to the extract which would stimulate their synthesis in order to protect the esophageal mucosa.

CAT is considered to be the key enzyme in cellular equipment used to cope with oxidative stress [35]. It is an enzyme that breaks down hydrogen peroxide ( $H_2O_2$ ) which forms hypochlorous acid and produces highly toxic hydroxyl free radicals [36]. These free radicals will be stabilized in a reaction chain that avoids oxidative activity [37]. As for MDA, it is a commonly used biomarker to estimate lipid peroxidation. It results from the degradation of hydro peroxides formed during the peroxidation of polyunsaturated fatty acids. It can also be formed during activation of the cyclo-oxygenase pathway [38]. Thus, the high levels of MDA observed in the control group 2, clearly indicate lipid oxidative damage undergone by the esophageal mucosa as proved by [39]. Indeed, oxidative stress plays an important role in the esophageal mucosa erosion [40]. It facilitates the degradation of the esophageal mucosa by accumulation of hydrogen peroxide, an inhibitor of prostaglandin biosynthesis. This results in the production of reactive oxygen species [41]. The significant increase in CAT levels and the significant decrease in MDA levels recorded in the treated rats compared to the control group 2, would probably be due to a free radical scavenging effect of this extract. In addition, the significant reduction in the level of MDA clearly indicates that TAEZg would have inhibited lipid peroxidation with the consequence of blocking the production of free radicals and reactive oxygen species. This suggests that TAEZg prevents oxidative stress by increasing the level of antioxidant enzymes. This is evidenced by the high level of CAT observed in treated animals. This ability to scavenge free radicals therefore makes it possible to control acid secretion in order to strengthen the physiological capacities of animals. These results suggest that TAEZg probably contains phytochemicals with antioxidant activity. Experiments are needed to verify this hypothesis.

### **Conclusion**

TAEZg possessed real anti-esophagitis preventive and curative potential in rats due to its cytoprotective and anti-secretory effect. This extract prevented and cured esophageal damage

while increasing the levels of total proteins and CAT decreased in the group of the affected rats. It also lowered MDA levels which were high in the affected rats. The scientific basis for the traditional use of this plant in the treatment of esophagitis proven by this work could justify its use by traditional therapists in Côte d'Ivoire.

**Ethical approval:** The study was approved by the Ethics Committee.

**COMPETING INTERESTS DISCLAIMER:**

Authors have declared that no competing interests exist. The products used for this research are commonly and predominantly use products in our area of research and country. There is absolutely no conflict of interest between the authors and producers of the products because we do not intend to use these products as an avenue for any litigation but for the advancement of knowledge. Also, the research was not funded by the producing company rather it was funded by personal efforts of the authors.

**References**

- 1- Vaezi MF, Richter JE. Role of acid and duodenogastroesophageal reflux in gastroesophageal reflux disease. *Gastroenterology*. 1996; 111: 1192-1199.
- 2- Kahrilas PJ, Lee TJ. Pathophysiology of gastroesophageal reflux disease. *Thoracic surgery clinic*. 2005; 15: 323-333.
- 3- Kang JW, Lee SM. Protective effects of chlorogenic acid against experimental reflux esophagitis in rats. *Biomolecular. Therapy*. 2014; 22: 420–425.
- 4- Totonelli G, Maghsoudlou P, Georgiades F, Garriboli M, Kiron KK, Mark TM. Detergent enzymatic treatment for the development of a natural acellular matrix for oesophageal regeneration. *Pediatric surgery international*. 2013; 29, 87–95.
- 5- Gyawali CP, Kahrilas PJ, Savarino E, Zerbib F, Mion F, Smout AJPM. Modern diagnosis of GERD: the Lyon Consensus. *Gut*. 2018; 67(7):1351-62.
- 6- Ouattara A, Allah KE, Soro D, Assi C, Illa H, Lohoues-kouacou MJ, Camara BM. Profil étiologique des œsophagites dans l'Unité Endoscopique du Centre Hospitalier et Universitaire de Cocody-Abidjan. Côte d'Ivoire, *Revue de Médecine et de Pharmacie*. 2018 ; 20(1) :85-89.
- 7- Rubin DC. Gastroenterologic diseases. In: The Washington manual. Manual of medical therapeutics. *Little, Brown and Company, USA*. 1993; 15:293–4.

- 8- WHO, Promoting the role of traditional medicine in health: system: A strategy for the African region. World Health Organization, *AFR/RC50/9*. 2002; pp12-15.
- 9- N'Guessan K. Plantes médicinales et pratiques médicinales traditionnelles chez les peuples Abbey et Krobou du Département d'Agboville (Côte d'Ivoire). Thèse de Doctorat d'Etat ès Sciences Naturelles, Spécialité Ethnobotanique, Université de Cocody-Abidjan (Côte d'Ivoire), UFR Biosciences, Laboratoire de Botanique. 2008 ; 335 p.
- 10- Kokwaro JO. Medicinal plants of East Africa, *3rd ed. University of Nairobi Press, Nairobi*. 2009; 256–257.
- 11- EU. Commission implementing decision of 14 November 2012 establishing a common format for the submission of the information pursuant to Directive 2010/63/EU of the European parliament and of the council on the protection of animals used for scientific purposes (notified under document C (2012) 8064). Text with EEA relevance. *Special edition in Croatian*. 2012;15 (28): 163-180.
- 12- Nakamura K, Ozawa Y, Furuta Y, Miyazaki H. Effects of sodium polyacrylate (PANa) on acute esophagitis by gastric juice in rats. *Japan Journal of Pharmacology*. 1982 ; 32:445-456.
- 13- Okabe S, Takinami Y, Iwata K, Yanagawa T. Mucosal protective effect of leminoprazole on reflux esophagitis induced in rats. *Japan. Journal of Pharmacology*. 1995; 69, 317–323.
- 14- Omura N, Kashiwagi H, Chen G, Suzuki Y, Yano F, Aoki T. “Establishment of surgically induced chronic acid reflux esophagitis in rats,” *Scandinavian Journal of Gastroenterology*. 1999; 34 (10): 948–953.
- 15- Zayachkivska O, Bula N, Khyrivska D, Gavrilyuk E, John LW. Exposure to non-steroid anti-inflammatory drugs (NSAIDs) and suppressing hydrogen sulfide synthesis leads to altered structure and impaired function of the oesophagus and oesophagogastric junction. *Inflammo pharmacology*. 2015; DOI 10.1007/s10787-015-0230-7.
- 16- Takagi K, Kasuya Y, Watanabe K. Studies on the drugs for peptic ulcer. A reliable method for producing stress ulcer in rats. *Chemical Pharmacology Bulletin*. 1964; 12:465–472.
- 17- Dumas BT, Watson W A, Biggs HG. Albumin standards and the measurement of serum albumin with bromocresol green. *Clinica Chimica Acta*. 1971; 31 : 87–96.

- 18- Ohkawa H, Ohishi N, Yagi K. Assay for lipid peroxides in animal tissues by thiobarbituric acid reaction. *Anal of Biochemistry*. 1979; 95(2): 351-8.
- 19- Aebi H. Catalase *in vitro*. *Methods Enzymology*. 1984; 105: 121-6.
- 20- Kheirandish R, Azari O, Shojaepour S. Protective effect of Fenugreek (*Trigonella foenum graecum*) seed extract on experimental reflux esophagitis in rat. *Iranian journal of veterinary surgery*. 2013; 8 (2); Serial No: 19.
- 21- Hyeon HN, Li N, Byung KC. dichloromethane extracts of geranium koreanum kom. alleviates esophagus damage in acute reflux esophagitis-induced rats by anti-inflammatory activities. *International Journal of Molecular Sciences*. 2018; 19:(11) 3622.
- 22- Li Y, Martin RC. Reflux injury of esophageal mucosa: experimental studies in animal models of esophagitis, Barrett's esophagus and esophageal adenocarcinoma. *Disease Esophagus*. 2007; 20: 372-378.
- 23- Taha AS, Angerson WJ, Morran CG. Reflux and Barrett's esophagitis after gastric surgery-long-term follow-up and implications for the roles of gastric acid and bile in esophagitis. *Aliment Pharmacology Therapy*. 2003; 17: 547-52.
- 24- Tsukimi Y, Nozue C, Okabe S. Effects of leminoprazole, omeprazole and sucralfateon indomethacin-induced delayed healing of kissing gastric ulcers in rats. *Journal of Gastroenterology Hepatology*. 1996; 11: 335-340.
- 25- Ishihara M, Ito M. Influence of gastric ulcer healing activities of cimetidine and omeprazole. *European Journal of Pharmacology*. 2002; 444: 209-215.
- 26- Singh S, Rai A, Maity S, Sarkar S, Maji S, Saha S. Effect of ethanolic of *Quisquilis indica* L.flower on experimental esophagitis in albino Wistar rats. *Indian journal of experimental biology*. 2017; 55:122-126.
- 27- Ekta A, Sudipta S, Shubhini AS, Gaurav K. Effect of *Perilla frutescens* fixed oil on experimental esophagitis in Albino Wistar rats. *BioMed Research International*. 2013; ID 981372, 6 pages <http://dx.doi.org/10.1155/2013/981372>
- 28- Salama SM, Nordin N, Golbabapour S, Hajrezaie M, Hassandarvish P, Kamalidehghan BA, Majid M, Hashim MN, Omar H, Fadaienasab M, Karimian H, Taha H, M.Ali H, Abdulla AM. Anti-Ulcerogenic Effect of Methanolic Extracts from *Enicosanthellum pulchrum* (King) Heusden against Ethanol-Induced Acute Gastric Lesion in Animal Models. *Journal Plos One*. 2014; 9 : 1-13.
- 29- Calop J, Limat S, Fernandez C. Pharmacie clinique et thérapeutique. 3<sup>eme</sup> édition, *Elsevier Masson*. 2008 ; :248-68.

- 30- Brogden R N, Heel RC, Speigth MT, Avery GS. Naproxen up to: A review of its pharmacological properties and therapeutic efficacy and use in rheumatic diseases and pain states. 1979; 18 :241-277.
- 31- Hogan D L, Ainsworth MA, Isenberg JI. Gastroduodenal ulcers, secretion of bicarbonate on digestive system. *Pharmacology*. 1994; 8: 475-488.
- 32- Su-Yeon C, Chang-Hyun S, Ji-Eun L, Seong HC, Sae-Kwang K, Soo-Jin P. Effects of Platycodin D on reflux Esophagitis due to modulation of Antioxidant defense systems. *Evidence-Based Complementary and Alternative Medicine*. Article ID 7918034. 2018; 11 pages, <https://doi.org/10.1155/2018/7918034>.
- 33- Mohamed-Amine J, Haifa T, Afifa A, Lamjed M, Hichem S. Protective effects of Artemisia campestris extract against gastric acid reflux-induced esophageal mucosa injuries. *Pathophysiology*. 2018; 25: 63–69.
- 34- Beaufrere B. Métabolisme des acides aminés chez l'homme normal. *Flammarion, Médecine-Sciences*. 2002 ; pp 93-103.
- 35- Chance B, Sies H, Boveris A. Hydroperoxide metabolism in mammalian organs. Physiological perspectives. *Journal of Ethnopharmacology*. 1979; 143 :116-150.
- 36- Pincemail J, Bonjean K, Cayeux K, Defraigne JO. Mécanismes physiologiques de la défense antioxydante physiological action of antioxidant defenses. *Nutrition clinique et métabolisme*. 2002; 16: 233–239.
- 37- Boubali Z. Biomarqueurs du stress oxydatif, thèse de médecine et pharmacie. 2017; p 134.
- 38- Guichardant M, Bacot S, Molière P, Lagarde M. Les biomarqueurs de la peroxydation lipidique. *Oléagineux, Corps Gras, Lipides*. 2006 ; 13(1) :31-34.
- 39- Inayama M, Hashimoto N, Tokoro T, Shiozaki H. Involvement of oxidative stress in experimentally induced reflux esophagitis and esophageal cancer, *Hepato gastroenterology*. 2007; 54: 761-765.
- 40- Oh TY, Lee JS, Ahn BO. Oxidative damages are critical in pathogenesis of reflux esophagitis: implication of antioxidants in its treatment. *Free Radical Biology Medicine*. 2001; 30: 905-15.15.
- 41- Bandyopadhyay U, Das D, Bandyopadhyay D, Bhattacharjee M, Banerjee RK. Role of reactive oxygen species in mercapto methyl imidazole-induced gastric acid secretion and stress-induced gastric ulceration. *Current Science*. 1999 ; 76 : 55-63.

UNDER PEER REVIEW