

The vicious cycle of BRASH syndrome: A case report and a brief review of literature

ABSTRACT

BRASH syndrome is a medical condition characterized by the combination of bradycardia (a slow heart rate) and shock in individuals with renal failure, a history of taking atrioventricular (AV) nodal blocking medications, and hyperkalemia (elevated levels of potassium in the blood). This syndrome typically occurs in elderly individuals who have compromised kidney function and a history of regularly using AV nodal blocking medications (1). Major risk factors for BRASH syndrome include hypovolemia (low blood volume) and worsening kidney function. It's important to recognize that these manifestations should be considered as part of a syndrome rather than isolated findings, as they are interconnected and have synergistic effects on each other. These underlying physiological processes create a harmful cycle of bradycardia and reduced cardiac output, leading to organ dysfunction, including renal failure with hyperkalemia, which in turn exacerbates the bradycardia. BRASH syndrome is associated with significant morbidity and mortality (2). Typically, the treatment approach for BRASH syndrome involves increasing renal blood flow by enhancing cardiac output through the administration of catecholamines. In rare cases, interventions such as intralipid emulsion and continuous renal replacement therapy (CRRT) may be necessary, depending on the specific circumstances. Early recognition of BRASH syndrome is crucial, as it can help prevent diagnostic delays and reduce mortality rates. In the case presented here, the patient's medical history provided important clues that led to the early identification and aggressive treatment of BRASH syndrome. This timely intervention prevented the onset of shock, reduced morbidity, and improved overall outcomes.

Keywords: atrioventricular node blocker; bradycardia; BRASH; hyperkalemia; renal failure; shock

INTRODUCTION

The term "BRASH syndrome," abbreviated from Bradycardia, Renal failure, Atrioventricular (AV) nodal blocking agent, Shock, and Hyperkalemia, was coined in 2016 by Dr. Josh Farkas. Dr. Farkas proposed "a pathophysiologic cycle of events that sets off a vicious cycle, initiated by renal failure, leading to hyperkalemia, and the accumulation of AV nodal blocking agents like beta-blockers (BB) or calcium channel blockers (CCB)" (3). Both hyperkalemia and AV nodal blockers contribute to bradycardia and reduced perfusion, further exacerbating renal failure. Many cases of BRASH syndrome are frequently misdiagnosed and treated as isolated electrolyte abnormalities, such as hyperkalemia, which can have severe consequences if not addressed promptly. Recognizing the interconnected nature of these clinical features is essential for accurate diagnosis and timely intervention.

CASE PRESENTATION

In this case report, we describe a 66-year-old male patient who presented with generalized fatigue, vomiting, and multiple episodes of syncope. The patient had a known medical history, including coronary artery disease, heart failure with a low ejection fraction (25%), stage 3 chronic kidney disease, type-2 diabetes mellitus, and hypertension. He had been compliant with his medications, which included bisoprolol 2.5 mg once daily (OD), sacubitril/valsartan 25 mg twice daily, Furosemide 40 mg OD, and spironolactone 12.5 mg OD. Upon initial medical assessment, the patient was mildly drowsy but oriented to time, place, and person. His Glasgow Coma Scale score upon arrival was 15/15. He showed signs of dehydration. His blood pressure was 76/55, and his heart rate was 25 beats per minute. The remainder of his physical examination did not reveal any significant abnormalities. An electrocardiogram (ECG) showed bradycardia with a junctional rhythm (Figure 1). Routine biochemistry blood tests indicated severe hyperkalemia at 6 mEq/L, metabolic acidosis, and acute worsening of chronic kidney failure (creatinine at 35 g/L, GFR of 17 ml/min, deteriorating from a baseline of 40 ml/min). The other results from his biochemistry blood tests fell within the normal range. Immediate intervention included fluid resuscitation with vasopressor agents. Urgent treatment for hyperkalemia involved calcium gluconate (1 gram) administration, regular insulin (5 units) with dextrose, and salbutamol (10mg) inhalation. As the patient's condition evolved, his heart rate and blood pressure improved. Due to refractory hyperkalemia (5.4 mmol/L), urgent dialysis was arranged, and a temporary transvenous pacemaker was inserted to provide initial stabilization because bradycardia persisted.

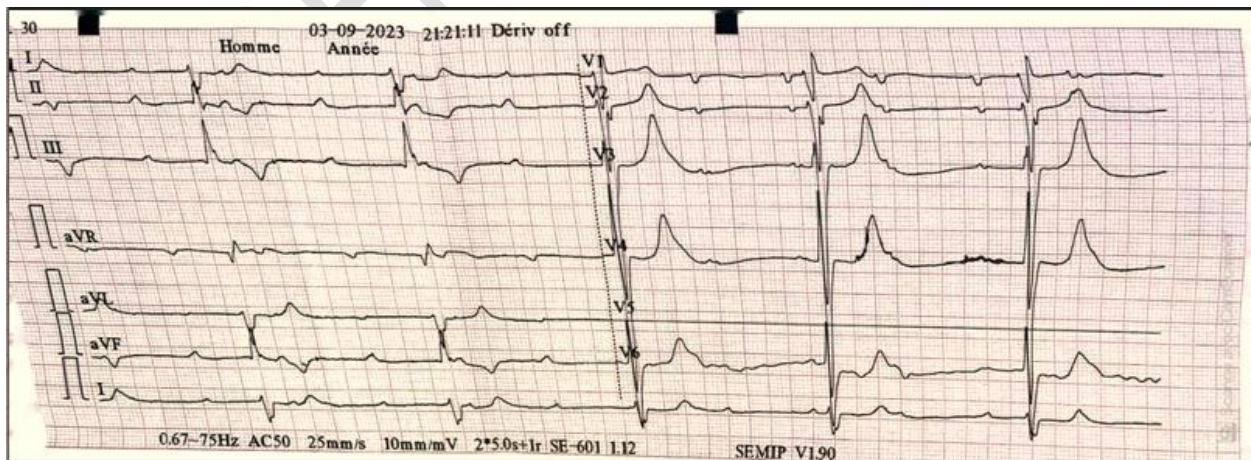


Figure1. ECG bradycardia (25bpm) with a junctional rhythm

Discussion

“Hyperkalemia and the use of atrioventricular (AV) nodal blocking agents can contribute to the development of bradycardia. However, when bradycardia occurs in the presence of underlying renal dysfunction, it can exacerbate hyperkalemia, leading to a detrimental cycle known as BRASH syndrome (Bradycardia, Renal Failure, AV-nodal blockers, Shock, Hyperkalemia)” (4).

“The key pathophysiological feature of BRASH syndrome is the synergistic effect of hyperkalemia and AV nodal blockers, resulting in bradycardia. Commonly implicated agents include beta-blockers (BB) or calcium channel blockers (CCB), as observed in the cases presented” (5). “Although these medications are generally well-tolerated, they can cause significant AV nodal blockade when patients experience precipitating events such as systemic infections. This can lead to acute kidney injury and reduced drug clearance, further compromising renal function. Therefore, caution should be exercised when prescribing AV nodal blocking agents to patients with a history of chronic kidney disease or those at risk of acute kidney injury, as this can increase the likelihood of developing BRASH syndrome” (6).

“Diagnosing BRASH syndrome primarily relies on clinical manifestations, ECG findings, and a comprehensive metabolic panel, following the exclusion of other potential causes. A high level of suspicion is crucial when encountering patients with refractory bradycardia, elevated serum potassium levels, renal failure, and a history of AV nodal blocking drugs” (7). “Early identification of the syndrome is essential to reduce mortality. Initial management aims to stabilize cell membranes with calcium gluconate, correct hyperkalemia through dextrose and insulin infusion, and administer salbutamol nebulization. Electrolyte correction and fluid replacement are crucial even if classic ECG findings of hyperkalemia are absent” (8).

“Furthermore, considering hemodialysis early can help remove excess potassium from the body. In cases of refractory hemodynamic instability, prompt transvenous pacing and careful use of inotropes can be life-saving” (9). “BRASH syndrome presents both diagnostic and therapeutic challenges, emphasizing the importance of understanding its pathophysiology and ensuring timely diagnosis for effective management and improved patient outcomes” (9).

Conclusion

BRASH syndrome is a life-threatening condition that is frequently underdiagnosed due to its nonspecific symptoms, posing challenges in both diagnosis and treatment. Heightened awareness among clinicians is critical, as early diagnosis and addressing precipitating factors can play a pivotal role in its management. The primary approach to treating BRASH syndrome involves correcting hyperkalemia, enhancing renal function by addressing underlying causes, and discontinuing the use of AV nodal blocking agents to interrupt the harmful cycle.

ETHICAL APPROVAL

As per international standard or university standard written ethical approval has been collected and preserved by the author(s)

CONSENT

In accordance with international and academic standards, written consent for publication was obtained from the patient and retained by the authors.

AUTHORS' CONTRIBUTIONS

- CHARIF Hana, Patrick M., Njie M., Jama D.: Wrote the article and inserted the references
- M. Haboub, A. Salim, Med G. Benouna, A. Drighil, L. Azzouzi and R. Habbal : corrected the article

This work was carried out in collaboration between all the authors. All authors have read and approved the final manuscript.

- ACKNOWLEDGEMENTS

- I thank the whole Department of Cardiology P37, university teaching hospital Ibn Rochd Casablanca for their outstanding collaboration in the support of this work.

REFERENCES

(1)Farkas J. PulmCrit- BRASH syndrome: Bradycardia, Renal failure, Av blocker, Shock. Hyperkalemia 2016 February 15; <https://emcrit.org/pulmcrit/brash-syndrome-bradycardia-renal-failure-av-blocker-shock-hyperkalemia/>

(2) Calvin J Tan B S. BRASH Syndrome: Profound Bradycardia in the Setting of Mild Hyperkalemia State University of New York – Downstate, College of Medicine; Kings

County Hospital Center. https://www.emra.org/siteassets/emra/be-involved/events--activities/casecon/2018-posters/group-2/calvin_tan_final_poster.pdf

(3) Farkas JD, Long B, Koyfman A, Menson K. BRASH Syndrome: Bradycardia, Renal Failure, AV Blockade, Shock, and Hyperkalemia. *J Emerg Med*. 2020 Aug;59(2):216-223. doi: 10.1016/j.jemermed.2020.05.001. Epub 2020 Jun 18. PMID: 32565167. <https://pubmed.ncbi.nlm.nih.gov/32565167/>

(4) Sattar Y, Bareeqa SB, Rauf H, Ullah W, Alraies MC. Bradycardia, Renal Failure, Atrioventricular-nodal Blocker, Shock, and Hyperkalemia Syndrome Diagnosis and Literature Review. *Cureus*. 2020 Feb 13;12(2):e6985. doi: 10.7759/cureus.6985. PMID: 32201662; PMCID: PMC7075507. <https://pubmed.ncbi.nlm.nih.gov/32201662/>

(5) Srivastava S, Kemnic T, Hildebrandt KR. BRASH syndrome. *BMJ Case Rep*. 2020 Feb 23;13(2):e233825. doi: 10.1136/bcr-2019-233825. PMID: 32094236; PMCID: PMC7046371. <https://pubmed.ncbi.nlm.nih.gov/32094236/>

(6) Zhou M and AH Khan, Bradycardia, Renal Failure, AV-Nodal Blockers, Shock, and Hyperkalemia (BRASH) - A New Clinical Syndrome, in American Thoracic Society 2018 International Conference. 2018: San Diego, CA. A3467-A3467. <https://pubmed.ncbi.nlm.nih.gov/35475060/>

(7) Nathani A, Lingamaneni P, Radigan KA. Brash Syndrome: An Emerging Clinical Entity.A43. CRITICAL CASE REPORTS: TOXICOLOGY AND POISONINGS. *American Journal of Respiratory and Critical Care Medicine*. 2020; 201A1666 https://www.atsjournals.org/doi/10.1164/ajrccm-conference.2020.201.1_MeetingAbstracts.A1666 [in A43. l.c. p. A1666-A1666]

(8) Saini T, Reny J, Hennawi HA, Cox A, Janga C, DeLiana D, McCaffrey J. The vicious cycle of BRASH syndrome: A case report. *Glob Cardiol Sci Pract*. 2023 Jan 30;2023(1):e202302. doi: 10.21542/gcsp.2023.2. PMID: 36890842; PMCID: PMC9988297. <https://pubmed.ncbi.nlm.nih.gov/36890842/>

(9) Shah P, Silangruz K, Lee E, Nishimura Y. Two Cases of BRASH Syndrome: A Diagnostic Challenge. *Eur J Case Rep Intern Med*. 2022 Apr 8;9(4):003314. doi: 10.12890/2022_003314. PMID: 35520368; PMCID: PMC9067425. <https://pubmed.ncbi.nlm.nih.gov/35520368/>