

**COMPARISON OF THE EFFICACY OF HAEMATOXYLIN & EOSIN
(H&E) AND PERIODIC ACID SCHIFF (PAS) STAINING TECHNIQUES
IN THE DIAGNOSIS OF TYPHOID INTESTINAL PERFORATION (TIP)
AMONG PATIENTS ATTENDING FEDERAL MEDICAL CENTRE,
KEFFI NASARAWA STATE, NIGERIA**

ABSTRACT

AIM OF THE STUDY: To compare the efficacy of H&E and PAS staining techniques in the demonstration of TIP among patients attending Federal Medical Centre Keffi, Nasarawa state.

| STUDY DESIGN: The study is a retrospective study, a total of 129 paraffin-embedded tissue blocks of patients who were diagnosed of TIP between January 1st 2013 and December 31st 2022 were retrieved from the archives of Histopathology laboratory and examined. Ten patients (10) with incomplete data were excluded.

METHODOLOGY: A semi structured questionnaire was used to collect demographic data. The tissue blocks were sectioned at 4um and stained using Haematoxylin and Eosin (H&E) staining technique and Periodic Acid Schiff (PAS) technique. The microscopic examination was done using x10 and x40 objectives of the Olympus light microscope.

RESULTS; The study showed that males were more affected with TIP than females with ratio 1.6: 1. Ages of patients ranged between 6 months-77 years with mean age of 24.8±1.87 years. The highest number of TIP cases was recorded in December. The ileal segment was the most perforated among the intestinal segments. The socioeconomic status of patients, availability of potable water supply as well as hygiene and sanitary practices were discovered to be key factors in typhoid fever infection and treatment outcomes.

CONCLUSION: Although, both PAS and H&E staining techniques showed favorable features, the PAS technique gave better contrast and also revealed the perforation sites better than H&E at $P < 0.001$. Hence, the PAS technique should be done alongside the H&E in the laboratory investigation of intestinal tissues.

Key words: *Typhoid intestinal perforation, Haematoxylin & Eosin, Periodic Acid Schiff*

INTRODUCTION

BACKGROUND OF THE STUDY

Typhoid fever, also known as enteric fever is a severe febrile illness caused primarily by the gram negative bacilli-*Salmonella typhi* and *Salmonella paratyphi* and has continued to be of public health concern in many developing countries [1]. The causative agent is generally transmitted by faeco-oral route and the infection may lead to an epidemic, particularly in areas of poor sanitation and limited availability of clean, potable water [2].

Clinically, typhoid fever manifest with several symptoms such as headache, abdominal pains, diarrhea, fever, nausea etc., however, typhoid fever could lead to life threatening complications if not promptly managed. According to WHO [3], common complications that may arise from typhoid fever infection include haemorrhage, pneumonia, intestinal bleeding and intestinal perforation.

The small and large intestines form a major part of the gastrointestinal tract length and are the sites of a lot of diseases where the immune system interfaces with various antigens present in food and gut microbes [4].

Perforation of the intestine due to typhoid infection is a serious form of complication which could lead to medical conditions such as abscesses, peritonitis, sepsis, internal bleeding, anaemia and sometimes death [5]. Vinay *et al*, [4] noted that typhoid intestinal perforation is common at the terminal end of the ileum which is secondary to necrotic lesions of the Peyer's patches and it often require surgical interventions.

Intestinal perforation is one of the serious complications of typhoid fever infection and remains a significant surgical problem in developing countries such as Nigeria, South Africa and Ghana where it is associated with higher morbidity and mortality, due to lack of clean, potable water, lack of access to health facilities in remote areas, poor sanitation and delay in reporting to the hospital [6].

Currently, the incidence and endemicity of typhoid fever is not known in all the local regions of Nigeria. This is due to poor infectious disease database and the poor health-seeking habit of the people, who prefer to patronize local

drug vendors and other unorthodox medical healthcare facilities as a result of poverty [7].

Ugwu *et al*, [8] noted that the high incidence of perforation in developing countries was attributable to late presentation to the hospital and the emergence of multi-drug resistant, virulent strains of the causative agent.

The prevalence of typhoid intestinal perforation, which cannot be managed at the primary and secondary healthcare level or by unorthodox means, can be taken to be a reflection of the endemicity of the disease in a geographical location [9].

AIM OF THE STUDY

- To compare the efficacy of H&E and PAS staining techniques in the diagnosis of TIP among patients attending Federal Medical Centre Keffi, Nasarawa state.

MATERIALS AND METHODS

AREA OF STUDY

This study was carried out at Federal Medical Centre, Keffi, Nasarawa State. Keffi is a local government area in Nasarawa state, in the north-central geopolitical zone of Nigeria. Its headquarters is in Keffi town.

Keffi lies on the geographical coordinates of 8° 50' 54"N, 7° 52' 24"E with population of 85,911 and has an area of 13,800km² [10].

F.M.C. Keffi serve as a referral hospital to neighboring local government areas such as Karu, Kokona, as well as general hospitals and other private clinics in Keffi environs.

STUDY POPULATION

A total of one hundred and twenty nine (129) paraffin-embedded tissue blocks of patients diagnosed of typhoid bowel perforation were retrieved from the Histopathology laboratory of Federal Medical Centre Keffi, Nasarawa state. This number (129) represents the total tissue specimens of perforated bowel received at the Histopathology laboratory between 1st January, 2013 to 31st December, 2022.

INCLUSION CRITERIA

All the patients in this study were diagnosed of typhoid intestinal perforation based on their clinical, laboratory and operative findings of perforation in the duodenum, jejunum, ileum, as well as in the colon. Majority of the tissue specimens were gotten from admitted patients, operated upon at the surgery department of F.M.C Keffi while a few were referrals from private hospitals within Keffi environs.

EXCLUSION CRITERIA

Only patients that had their provisional/clinical diagnosis querying ‘typhoid intestinal perforation’ were included this study. Other intestinal tissues diagnosed of volvulus, intussusception, cancer and trauma due to road transport accidents were excluded from this research. Ten (10) patients with incomplete demographic data were also excluded from the study.

METHOD

A total of 129 paraffin-embedded tissue blocks were retrieved from the tissue bank at Histopathology laboratory of the hospital. The demographic data of patients were obtained alongside the tissue blocks. This data included the age of patients, sex, provisional diagnosis, occupation, and clinical history. The tissue blocks were sectioned at 4µm on a rotary microtome and

stained using Haematoxylin and Eosin (H&E) staining technique [11] and Periodic Acid Schiff (PAS) technique [12] to compare and determine the most suitable technique in demonstrating typhoid intestinal perforation. The microscopic examination was done using x10 and x40 objectives of the Olympus light microscope.

STATISTICAL ANALYSIS

Statistical analysis was performed using the Statistical Package for Social Sciences software (SPSS, version 25.0). Data was analyzed using chi-square test and differences were considered statistically significant whenever the *P* value was $P < 0.05$. Comparison of staining efficacy was done using Wilcoxon Signed Rank Correlation. Other parameters were determined by using simple percentages, charts and mean values.

RESULTS

A total of 129 tissue blocks were analyzed during the period under review. Ten were excluded in most of the analysis due to incomplete data and the remaining 119 was used.

The patients were divided into seven (7) age groups. Their ages ranged from 6 months to 77 years with a mean of 24.8 years. Table 1 shows the

frequency distribution of findings among the 119 patients. The highest distribution of Typhoid Intestinal Perforation was recorded among the age group 10-19 years (27.74%) while age group 70-79 years recorded the lowest (1.68%).

Table 1: Age Distribution of Typhoid Intestinal Perforation

Age Group (Years)	Frequency	Percentage (%)
0-9	26	21.85
10-19	33	27.74
20-29	14	11.76
30-39	19	15.97
40-49	14	11.76
50-59	5	4.20
60-69	6	5.04
70-79	2	1.68
TOTAL	119	100

Out of the 119 with complete data, the majority 73 (61.34%) were males and 46 (38.66%) were females (Figure 1)

Figure 1: Sex Distribution of Typhoid Intestinal Perforation (1-Male, 2-Female)

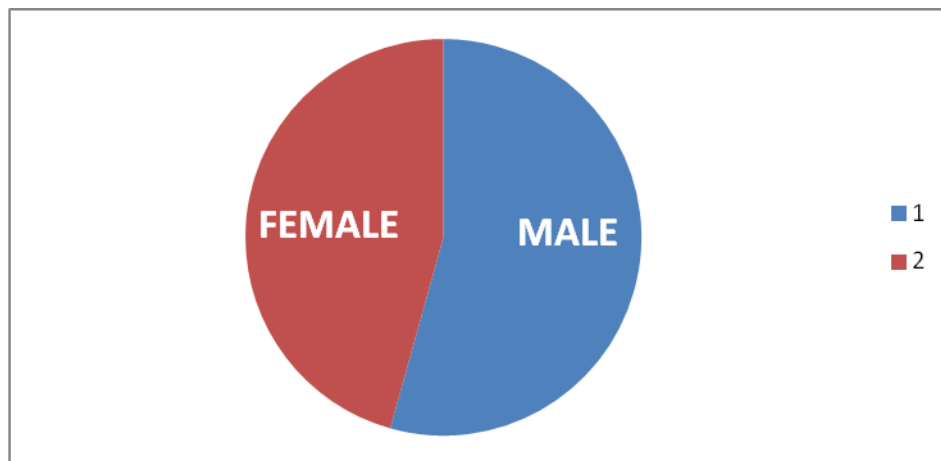


Table 2 shows the monthly pattern of TIP distribution. There was higher rate of infection during the dry season (November to March) with the higher cases in November (15.97%), December (24.7%) and January (10.92%) while cases of typhoid intestinal perforation were few during the rainy season (April to October)

Table 2

TABLE 2: MONTHLY DISTRIBUTION OF TYPHOID INTESTINAL PERFORATION CASES

MONTH	FREQUENCY	PERCENTAGE (%)
JANUARY	13	10.92
FEBRUARY	11	9.24
MARCH	12	10.08
APRIL	8	6.72
MAY	4	3.36
JUNE	3	2.52
JULY	4	3.36
AUGUST	3	2.52
SEPTEMBER	3	2.52
OCTOBER	10	8.40
NOVEMBER	19	15.97
DECEMBER	29	24.37
TOTAL	119	100

Out of the 119 perforations recorded in this study, small intestine accounted for the higher site of perforation with ileum (57.2%), jejunum (17.6%) and duodenum (16.8%). Only 8.4% occurred in the large intestine, which is the colon Table 3.

TABLE 3: Distribution of Perforation among the intestinal segments

Site of Perforation	Frequency	Percentage (%)
Duodenum	20	16.8
Jejunum	21	17.6
Ileum	68	57.2
Colon	10	8.4
TOTAL	119	100%

Socio-economic status of patients was seen to play a role in typhoid fever infection with higher rate of infection seen in patients with no formal education (39.5%) and complication as shown in Table 4

TABLE 4: SOCIO-DEMOGRAPHIC CHARACTERISTICS OF PATIENTS WITH TIP

FACTOR	FREQUENCY	PERCENTAGE (%)
1. Education:		

None	47	39.5
Primary	42	35.3
Secondary	18	15.1
Tertiary	12	10.1
TOTAL	119	100
2. Occupation:		
Unemployed	45	37.8
House Wife	5	4.2
Self Employed	9	7.6
Student	60	50.4
TOTAL	119	100

Comparison of stain contrast was done using chi-square test and Wilcoxon signed rank correlation. The PAS technique ranked above H&E as shown in Table 5. This result was statistically significant at $P < 0.001$

TABLE 5: COMPARISON OF STAINING CONTRAST OF H&E AND PAS

**Wilcoxon Signed Ranks Test
Ranks**

	N	Mean Rank	Sum of Ranks
PAS - H&E	Negative Ranks	11 ^a	31.50
	Positive Ranks	94 ^b	40.41
	Ties	14 ^c	
	Total	119	

Z = 6.862; P < 0.001

Key:

a. PAS < H&E

b. PAS > H&E

c. PAS = H&E

In the comparison of perforation sites of the intestinal segments, PAS method ranked above H&E. The intestinal perforation was better demonstrated (viewed) using PAS technique. This result was statistically significant at $P < 0.001$ as shown in Table 6.

TABLE 6: COMPARISON OF PERFORATION SITES STAINED BY H&E AND PAS

**Wilcoxon Signed Ranks Test
Ranks**

	N	Mean Rank	Sum of Ranks
Perforation site PAS – perforation site H&E			
Negative Ranks	11 ^d	31.50	252.00
Positive Ranks	63 ^e	33.78	1959.00
Ties	35 ^f		
Total	119		

Z = 6.106; P < 0.001

d. perforation site PAS < perforation site H&E

e. perforation site PAS > perforation site H&E

f. perforation site PAS = perforation site H&E

DISCUSSION

The results presented from this study clearly show that Typhoid intestinal perforation is common among patients attending Federal Medical Centre, Keffi and it cuts across all age groups. Highest perforation was recorded within the age group 10-19 years (Table 1). This trend was similarly reported by Grema *et al*, [7] and Edino *et al*, [13]. Also, according to Vinay *et al* [4], majority of enteric fever cases in endemic countries affect mostly children and adolescents.

The study showed that Typhoid intestinal perforation affected more males (61.34%) than females (38.66%) [Figure1]. This observation is similar to reports given by Ugwu *et al*, [8] and Grema *et al*, [7] but differs from the findings of Edino *et al* [13] who reported a higher prevalence in females. The reason for this disparity is not completely understood. However, Beniwal *et al* [14] reported that males are more exposed to risk factors and also, their genetic predisposition increases the risk of infection.

The disease clustered around patients aged 0-49 years (Table 1). This showed that it mainly affects the youth and this have a negative impact on the economy of the developing world because this age group constitute a larger percentage of the workforce.

Incidence of typhoid intestinal perforation increased rapidly between the months of November to March (Table 2) which is the peak of the dry season in the North-central part of Nigeria. During this period, there is usually scarcity of clean, potable water. The incidence however dropped in April when another rainy season begins. This pattern of seasonal incidence had also been reported by Ameh [15] and Ugwu *et al* [8].

The ileum is the most affected intestinal segment (Table 3). According to Kumwenda *et al* [16], hypertrophy of the Peyer's patches causes obstruction of lumen and constipation. In severe cases, necrosis of Peyer patches lead to ulceration, bleeding and eventually perforation of the terminal ileum. This explains why the highest number of perforations was recorded in the ileal segment.

Enteric fever continues to be a problem in most developing countries due to poor hygiene and food handling, limited potable water supply among others. Poverty and low socio-economic status are also associated factors. Over 60% of subjects in this study lacked significant means of livelihood (Table 4); this could influence their health seeking attitude. A lot of people in Keffi environs patronize traditional drug vendors due to poverty and they do not report to the hospital until their condition worsens. This is in accordance with the study done by Grema *et al* [7].

In Histological techniques, the haematoxylin and eosin (H&E) method is considered to be the routine staining technique and it is often referred to as the gold standard for histological diagnosis. The result presented in this study however, showed that Periodic Acid Schiff (PAS) technique gave better staining contrast at $P < 0.001$ when compared with H&E (Table 5). Contrast is the difference in visual properties that makes an object distinguishable from other objects and the background. PAS also made the perforation sites, as well as the mucus producing glands of the intestinal segments more visible (Table 6). Pujar *et al* [17] also reported that PAS stain gave better contrast than (H&E) in the diagnosis of oral lichen planus.

CONCLUSION

Typhoid intestinal perforation remains a disease of serious public health concern. The high distribution recorded in this research work might be related to late presentation to health facilities due to poor health seeking attitude of the people. Early presentation and avoidance of unorthodox medication will go a long way in reducing complications from typhoid fever infection.

The faeco-oral transmission of the causative agent also explains its distribution, which had been reported to have a relation with sanitary conditions. Detailed information about sanitary condition of patients' homes was not included in this study but poor sanitation is expected in a semi-urban community like Keffi, where water supply is poor and waste and faecal disposal is largely indiscriminate.

Although the H&E technique for demonstrating general tissue structure is the gold standard/ routine technique for Histology, the PAS method offers better contrast (with respect to stain uptake of the tissues), giving more details about the cells and glands of the intestine and hence better demonstration of typhoid intestinal perforation.

Abbreviations: H&E (Haematoxylin and Eosin), PAS (Periodic Acid Schiff), TIP (Typhoid Intestinal Perforation)

ETHICAL APPROVAL

Ethical approval was obtained from the Health Research Ethics Committee of Federal Medical Centre, Keffi.

This retrospective study was based on hospital records of patients diagnosed with Typhoid intestinal perforation and confidentiality was ensured by not writing out or disclosing the names of patients at any given time in any of

the research records. A letter of confidentiality was written to the Ethics committee to that effect.

Consent

As per international standard or university standard, patients' written consent has been collected and preserved by the author(s).

ACKNOWLEDGEMENT

I give all glory, honour and adoration to Almighty Allah (SWT) for the successful completion of this work. My profound gratitude goes to my supervisor, Dr. Erameh, Theophilus O. who is also my lecturer and mentor, for his tutorship, patience and assistance at every critical stage of this research.

Special thanks to the Head of Department, Dr. Ugbomoiko, Daniel for his mentorship, understanding and encouragement and also to all the lecturers of Medical Laboratory Science department, Igbinedion University Okada, Edo State, Nigeria.

I appreciate my siblings- Engr. Jubril Salawu, Engr. Kuburat Salawu, Aunty Muheebat and my parents- Alhaji & Alhaja Salawu Ajibowo for their moral and financial support.

To my special friend and partner, Mr. Shuaib Siyanbola Gambari, thanks for being there when it mattered most. Your love and support is mostly appreciated.

COMPETING INTEREST

No competing interest exists.

AUTHORS' CONTRIBUTIONS

SAG: The author designed the study, performed the statistical analysis, wrote the protocol and wrote the first draft of the manuscript.

TOE: The supervisor, managed the analysis of the study, assisted with microscopy and photomicrographs.

DOU: Methodology, data analysis, review of literature

AOI: Data analysis, methodology, correction of manuscript

AAA: Data collection, formal analysis, literature review

AO: Data analysis and methodology

All authors read and approved the final manuscript.

REFERENCES

1. Crum, N. F. : Current trends in typhoid fever. *Current Gastroenterology Report* 2003; (5) : 279-286. <https://doi.org/10.1007/s11894-003-0064-0>
2. Ukwenya, A.Y., Ahmed, A., Garba, E. S.: Progress in management of typhoid perforation. *Annals of African Medicine* 2011; (10): 259-65. doi:10.4103/1596-3519.87040
3. World Health Organization. Typhoid vaccines: WHO position paper, March 2018 - Recommendations. *Vaccine*. 2018; 37(2):214-216. <https://doi.org/10.1016/j.vaccine.2018.04.022>
4. Vinay, K., Abul, K. A., Nelson, F., Jon, C. A. Robbins & Cotran Pathologic Basis of Disease (8th edition) Saunders Elseiver Inc. pp801-803. (ISBN: 978-1-4160-3121-5) 2010.
5. Sumer, A., Kemik, O., Dulger, A. C., Olmez, A. *et al*: Outcome of surgical treatment of intestinal perforation in typhoid fever. *World Journal of Gastroenterology* 2010 (16): 4164-8. doi:10.3748/wig.v16.133.4164
6. Bhutta, Z. A.: Current concepts in the diagnosis and treatment of typhoid fever. *Med. Journal* 2006 (333):78-82. <https://dx.doi.org/10.1136/bmj.333.7558.78>
7. Gremma, B. A., Aliyu, I., Michael, G. C., Musa, A., Fikin, A. G., Abubakar, G. M. & Olusegun, S.: Typhoid ileal perforation in a

semi-urban tertiary health institution in North-Eastern Nigeria. *South African Family Practice* 2018 60: (5): 168-173.
<https://doi.org/10.1080/20786190.2018.1481604>.

8. Ugwu, B.T., Yiltok, S.J., Kidmas, A.T. & Opaluwa, A.S.: Typhoid intestinal perforation in North-central Nigeria. *West African Journal of Medicine* 2005. Vol. 24(1):1-6. doi:10.4314/wajm.v24i1.28152
9. Osifo, O. D., Ogiemwonyi, S.O.: Typhoid ileal perforation in children in Benin-city. *African Journal of Paediatric Surgery*. 2010 Vol. 7:96-100. doi:10.4103/0189-6725.62857
10. Nasarawa share: Keffi location, Nasarawa State. Available at www.longitudelatitude.org/keffi. Accessed 15th September, 2023.
11. Baker, F.J., Silvertown, R.E., Pallister, C.J. *Introduction to Medical Laboratory Technology*. (7th Edition). Bounty Press Limited. pp 220-229. (ISBN: 978-2965-28-6) 2007.
12. Ochei, J. & Kolhatkar, A.: *Medical Laboratory Science; Theory and Practice*. 7th reprint. Tata McGraw-Hill publishers, New Delhi, 452-453 (ISBN: 978-0-07-463223-9) 2008.
13. Edino, S.T., Yakubu, A.A., Mohammed, A.Z. & Abubakar, I.S.: Prognostic factors in typhoid ileal perforation, a prospective study of 53 cases. *Journal of National Medical Association* 2007 (99): 1042-5 PMID: 17913115;PMCID:PMC575870
14. Beniwal, U. S., Jindal, D., Sharma, J.: Comparative study of operative procedures in typhoid perforation. *Indian Journal of Surgery* 2003. 65(2): 172-7. ISSN:0972-2068
<https://tspace.library.utoronto.ca>
15. Ameh, E. A. Typhoid ileal perforation in children. A scourge in developing countries. *Annals of Tropical Paediatrics* 1999 (19): 267-272 <https://doi.10.1080/02724939992356>. PMID:10715713

16. Kumwenda, M., Iroh Tam, P. Y. An adolescent with multi-organ involvement from typhoid fever. *Malawi Medical Journal* 2019. 31(2):159-160. [[PMC free article](#)] [[PubMed](#)]
<https://doi:10.4314/mmj.v31i22.10>
17. Pujar, A., Pereira, T., Tamgadge, A., Bhalero S. & Tamgadge, S.: Comparing the efficacy of H&E, PAS and Fluorescent PAS-acriflavine techniques for demonstration of basement membrane in oral lichen planus. A Histochemical Study. *Indian Journal of Dermatology* 2015. 60: (5): 450-456. <https://doi.org/10.4103/0019-5154.159626>