

Case study

SPONTANEOUS HEMATOMA OF THE RECTUS ABDOMINIS MUSCLE DURING TREATMENT WITH NON-VITAMIN K ORAL ANTICOAGULANT: A RARE CLINICAL OCCURRENCE AND REVIEW OF THE LITERATURE.

Abstract

Vitamin k antagonist anticoagulants (VKAs) and non-vitamin K oral anticoagulants (NOACs) are widely used in the treatment of non-valvular atrial fibrillation and other indications, but both classes of medications carry a risk of potentially serious bleeding. Spontaneous hematoma of the rectus abdominis muscle is a rare complication of NOAC treatment. Several risk factors, such as trauma, surgery, anticoagulation, coughing, intense rectus muscle contractions, pregnancy, etc., have been reported to cause rectus sheath hematoma. We report a case of spontaneous hematoma of the rectus abdominis muscle associated with moderate hemoperitoneum in a patient treated with NOAC for non-valvular atrial fibrillation (AF). Abdominal ultrasound and computed tomography scan (CT scan) confirmed the diagnosis after clinical assessment. The treatment was generally conservative but in the case of a hemodynamically unstable patient; hemostatic procedures should be considered.

Keywords: Spontaneous Hematoma, Non-vitamin k oral anticoagulant, hemoperitoneum

Introduction

Prevention of thromboembolic risk in patients with atrial fibrillation (AF) is based on effective anticoagulation therapy. Despite the standardization of biological monitoring and a better definition of therapeutic objectives, anticoagulant treatment is still associated with a significant percentage of hemorrhagic accidents (1). Although non-vitamin k oral anticoagulants have all shown a favorable risk-benefit ratio in their safety and efficacy profile, in the prevention of thromboembolic events in patients with non-valvular atrial fibrillation and in the prevention and treatment of venous thromboembolism, are associated with a reduction in the risk of hemorrhage, particularly cerebral, compared to vitamin K antagonist anticoagulants (VKA). The risk of gastrointestinal bleeding is, however, similar to that of VKA anticoagulant or even increased (2-4). Among these complications, we find spontaneous hematomas which are exceptional but are life-threatening (5). We report a case of hematoma of the rectus muscle associated with moderate hemoperitoneum in a patient treated with NOAC for non-valvular atrial fibrillation.

Case Presentation

A 61-year-old female diabetic patient under insulin therapy consulted at the emergency department for sudden diffuse abdominal pain predominating in the peri-umbilical area associated with abdominal distension, and anuria without intestinal transit disorder or traumatic context. The patient's main history was cardiac arrhythmia due to atrial fibrillation under anticoagulants (Rivaroxaban® 20 mg/day) in a context of heart failure with reduced left ventricular ejection fraction (LVEF) under treatment. On admission, the patient was conscious, blood pressure was 100/74 mmHg, heart rate was 80 beats per minute, oxygen saturation was 96% on room air, and her body temperature was 36.5 °C. Pain was rated 8/10 on a visual analog scale. The clinical examination revealed mucocutaneous pallor, a distended abdomen sensitive to palpation, site of an abdominopelvic ecchymosis extending from the left hypochondrium to the right iliac fossa associated with a non-mobilizable, painful mass measuring approximately 12 x 6 cm (Fig.1)

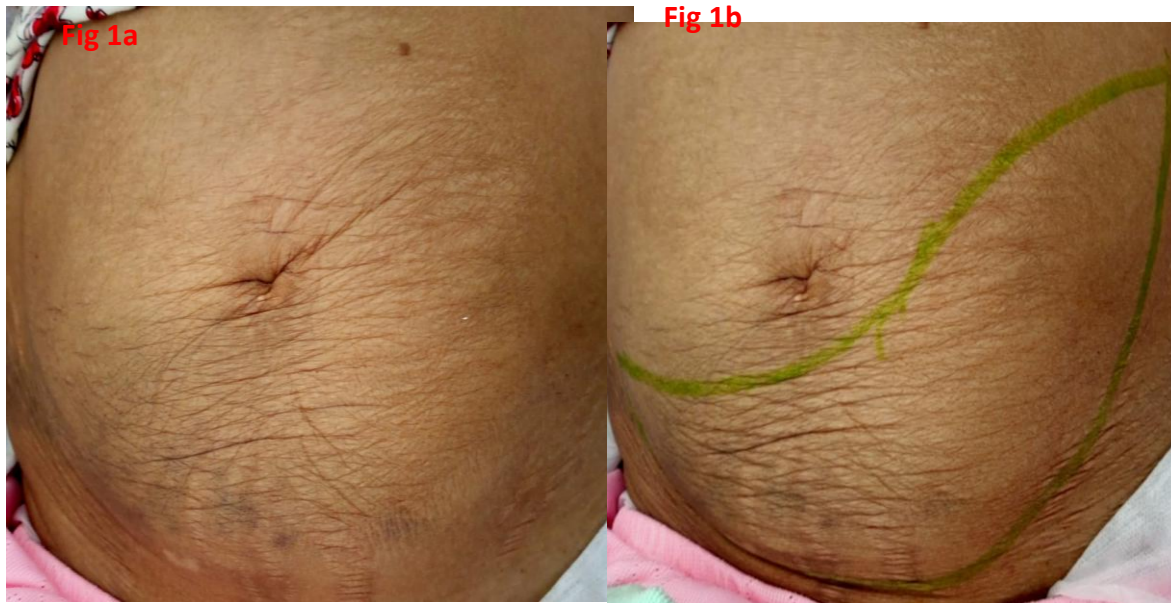

Figure 1: Photography of abdomen:distended abdomen, **a**-site of an abdominopelvic ecchymosis extending from the left hypochondrium to the right iliac fossa and **b**-a non-mobilizable, painful mass measuring approximately 12 x 6 cm.

Biological assessment showed a hemolytic anemia at 7.4 g/dl without inflammatory syndrome (C-reactive protein at 12 mg/l and leukocytosis at 8310/mm³). The prothrombin level was 50%. The liver assessment was normal whilst the renal assessment was abnormal (Creatinine at 23 mg/dl, urea at 1.46; GFR at 22ml/min, serum potassium at 5 meq/l) concluding an acute non-obstructive renal failure. The paraclinical assessment was completed by an abdominopelvic computed tomography (CT) scan without injection of contrast product (Fig. 2).

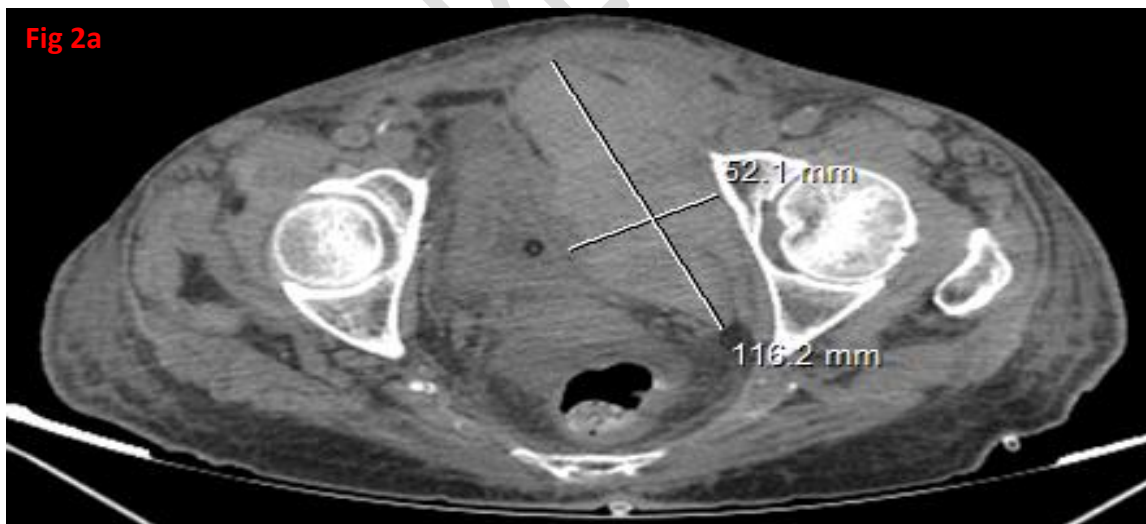


Figure 2a:Abdomin-pelvic CT scan: Cross section view: hematoma of the left rectus abdominis muscle measuring 116 x 52 mm. extending to a height of 140mm.

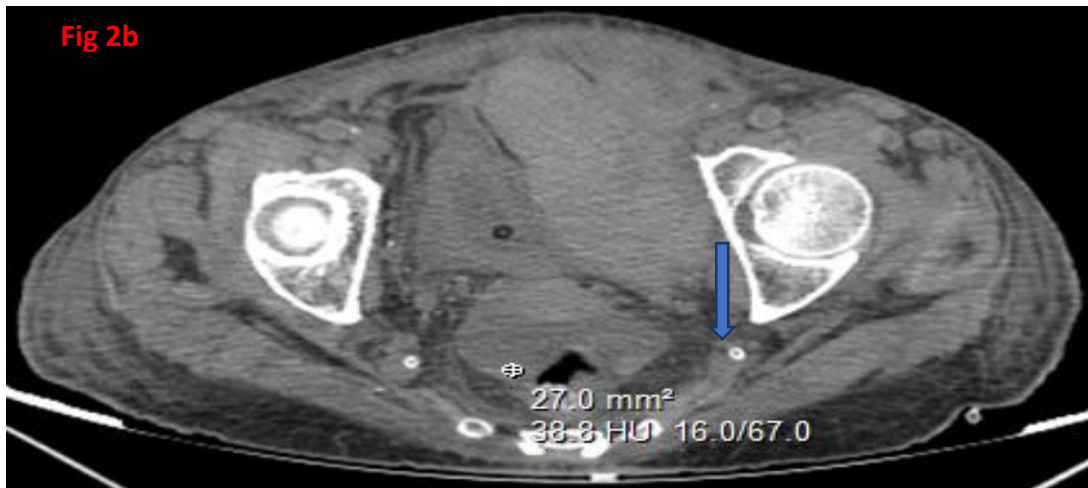


Figure 2b: Abdomin-pelvic CT scan:Cross section view: showing a moderate hematic peritoneal effusion (blue arrow).

This examination revealed a hematoma of the left rectus abdominis muscle, fairly well limited with regular polylobed contours of hematic density extending towards the Retzius space in the left pre- and lateral vesical areas up to the left obturatorinternus muscle measuring 116 x 52 mm. extended to a height of 140mm associated with a hematic peritoneal effusion.

The patient received a blood transfusion (three bags of packed red blood cells in two days) combined with a simple analgesic (paracetamol). The discontinuation of Rivaroxaban was also decided. The evolution was favorable clinically and biologically by the regression of the hematoma in 12 weeks and normalization of the renal function in only 4 days after intravenous hydration with saline serum. Hematoma is treated by bedrest and ice block packs placed on the abdomen during hospitalization.

Discussion

VKAs and NOACs are widely used in the treatment of non-valvular AF and other indications, but both classes of medications carry a risk of potentially serious bleeding(4,13).

The overall frequency of occurrence of severe hemorrhagic events with the new oral anticoagulants is lower than that of vitamin K antagonists (warfarin) except for spontaneous digestive hemorrhages which are more frequent with Rivaroxaban and less frequent intracerebral hemorrhages (4). Bleeding under VKA is well known while that under NOAC is still underdiagnosed.

Spontaneous hematomas are a known complication of treatment with non-vitamin k oral anticoagulants. Chtata et al. (6) reported the case of a mesosigmoidhematoma, De Brito et al. (7) reported a case of mesenteric hematoma as a complication of long-term non-vitamin k oral anticoagulant treatment.

Hematoma of the rectus abdominis muscle is a rare complication of anticoagulant treatment, and is often misdiagnosed. It is secondary to damage to the branches of the superior epigastric arteries in the sheath of the rectus muscle or due to direct muscle tear. Although it only represents less than 2% of the causes of abdominal pain (8). Its diagnosis must be made urgently due to its mortality rate, which ranges from 4 to 25% in anticoagulated patients (8). The main risk factors for hematoma of the rectus muscle, apart from abdominal trauma, include abdominal interventions (surgery, ascites paracentesis, peritoneal dialysis), forced contractions of the rectus muscle, particularly during

coughing efforts. and anticoagulant therapy (8). In our case, the risk increased in the presence of comorbidities (hypertension, renal insufficiency, etc.), drug interactions, duration and intensity of treatment and advanced age.

The diagnosis of rectus hematoma can be guided by the presence of abdominal pain occurring outside of any trauma associated with a palpable mass, as described in our patient. The pain is usually sharp, non-radiating and can affect all four quadrants. Secondly, a hematoma may appear and, due to the absence of aponeurosis posterior to the lower part of the rectus muscle, extend to the pelvis (9,13).

The diagnosis is confirmed by an abdominal ultrasound or CT scan. Abdominal ultrasound, although less sensitive than CT scan which has a sensitivity and specificity of 100% (10, 13), is especially important in the radiological monitoring of the hematoma. The abdominal CT scan allows, in addition to the diagnosis, to classify the severity of the hematoma (12).

Berna et al. (11) proposed a classification of the severity of rectus muscle hematoma based on abdominal CT-scan. Grade I (mild); corresponds to an intramuscular, unilateral hematoma with a fusiform appearance and resolves within one month. In grade II (moderate), the bleeding dissects the fascia transversalis but without extension into the Retzius space and may become bilateral and resolves in 2-4 months. Grade III (severe) corresponds to a wide dissection between the rectus and transversalis fascia, an intraperitoneal extension and in the space of Retzius, the hematoma propagates into the peritoneal cavity (11). In our patient, the hematoma was classified grade III but without hemodynamic instability.

Initial management and follow-up are mainly based on clinic and hemoglobin measurement (12,13). In a stable patient (hemodynamically, moderate pain and stable hemoglobin), the treatment remains primarily conservative (simple monitoring) like in our case. It consists of simple analgesia and management of hemostasis with discussion of stopping anticoagulants and antiaggregants drugs (12). This treatment will be associated with a blood transfusion in the event of significant drop in blood hemoglobin level. In cases of hemodynamic instability, invasive control of hemorrhage by embolization or vascular ligation should be considered (11,12).

Conclusion

Spontaneous hematoma of the rectus abdominis muscle is a rare complication of NOAC treatment. With increasing use of direct-acting oral anticoagulants in multiple clinical settings, clinicians should remain vigilant of this potentially life-threatening bleeding complication when a patient presents with acute abdominal pain. The diagnosis is generally made by ultrasound or abdominal CT scan. Conservative treatment with cessation of anti-coagulant and supportive transfusion remains the mainstay of treatment, except in cases of hemodynamic instability requiring hemostasis by embolization or vascular ligation.

Consent

As per international standard or university standard, patients' written consent has been collected and preserved by the author(s).

Ethical Approval:

As per international standard or university standard written ethical approval has been collected and preserved by the author(s).

References

1. Levine MN, Raskob G, Landefeld S, Kearon C. Hemorrhagic complications of anticoagulant treatment. *Chest*. 2001;119:108S-121S.
2. Ruff CT, Giugliano RP, Braunwald E, Hoffman EB, Deenadayalu N, Ezekowitz MD, Camm AJ, Weitz JI, Lewis BS, Parkhomenko A, Yamashita T, Antman EM. Comparison of the efficacy and safety of new oral anticoagulants with warfarin in patients with atrial fibrillation: a meta-analysis of randomised trials. *Lancet*. 2014;383:955-62.
3. Heidbuchel H, Verhamme P, Alings M, Antz M, Diener HC, Hacke W, Oldgren J, Sinnaeve P, Camm AJ, Kirchhof P. Updated European Heart Rhythm Association Practical Guide on the use of non-vitamin K antagonist anticoagulants in patients with non-valvular atrial fibrillation. *Europace*. 2015;17:1467-507.
4. Keith AA Fox et al, Prevention of stroke and systemic embolism with Rivaroxaban versus warfarin in patients with nonvalvular atrial fibrillation and moderate renal impairment, *European Heart Journal*. 2011; 32: 2387-2394,
5. Trompetas V, Yettimis E, Varsamidakis N, Courcoutsakis N, Kalokairinos E. Endoscopic diagnosis and conservative management of an intramural sigmoid haematoma complicating anticoagulant therapy. *ActaGastroenterol Belg*. 2007;70:313-5.
6. H. Chtata, A. Alahyane, M. Yaka, M. Oukabli, M. Taberkant, A. Elkirrat, Spontaneous hematoma of the mesosigmoid: an exceptional complication of long-term oral anticoagulants, *Clinical and Biological Gastroenterology*. 2009; 33:92-93.
7. P. De Brito, M.-A. Gomez, M. Besson, B. Scotto, D. Alison, Mesenteric hematoma: rare complication of long-term oral anticoagulant treatment, *Annals of Surgery*. 2006: 131: 529-532.
8. Salemis NS. Spontaneous rectus sheath hematoma presenting as acute surgical abdomen: an important differential in elderly coagulopathic patients. *GeriatrGerontol Int*. 2009;9:2002.
9. Nizam A, Dua A, Hameed T, Jain SK. *Maedica (Bucur)*. Spontaneous Rectus Sheath Hematoma Masquerading as Acute Abdomen. A Case Report. 2020 ;15:412-415
10. Hatjipetrou A, Anyfantakis D, Kastanakis M. Rectus sheath hematoma: a review of the literature. *Int J Surg*. 2015;13:267–71.
11. Berná JD, Garcia-Medina V, Guirao J, Garcia-Medina J. Rectus sheath hematoma: diagnostic classification by CT. *Abdomin Imaging*. 1996;21:62-4.
12. Cheuk-Lik Wong and Clarence Hao-Yu So. Spontaneous rectus sheath hematoma associated with apixaban in an elderly gentleman with chronic obstructive airway disease – a case report *Thromb J*. 2022;20 :59.

13. Koji Takahashi, Takeshi Nihei, Yohei Aoki, Miyuki Nakagawa, Naoaki Konno, AkariMunakata, Ken Okawara, and Hiroshi Kashimura. Spontaneous rectus sheath hematoma associated with warfarin administration: a case report. J Rural Med.2019;14:245-248.

UNDER PEER REVIEW