

## Case report

# **Efficacy and Versatility of the Medial Hemisoleus Flap for Complex Middle Third Tibial Defects: A Two-Case Report Analysis**

### **Abstract:**

Soft tissue injuries involving the middle third of the tibia can present significant clinical challenges, often leading to complications such as infection and nonunion. This article explores the efficacy of the medial hemisoleus flap as a valuable surgical technique for addressing these complex wounds. Two case reports are presented to illustrate the successful use of this flap in clinical practice. The medial hemisoleus flap offers consistent blood supply, improved arc of rotation, and reduced donor site morbidity, making it an excellent choice for reconstructive surgery in this anatomical region.

### **KEYWORDS:**

Soleus flap, Lower limb reconstruction, Tibial wound, Tibial Defects, Muscle flap

### **Introduction:**

Open wounds of the tibia can result from various causes, including trauma, surgery, or chronic ulceration. These wounds can lead to significant morbidity and the potential for limb loss, particularly when they occur in the middle third of the tibia. The middle third of the tibia has limited soft tissue coverage, making it susceptible to open wounds that may expose the bone and increase the risk of infection [1]. Additionally, soft tissue injuries associated with tibial fractures significantly contribute to delayed **union and/or nonunion**, emphasizing the importance of early wound coverage to minimize complications.

Local muscle flaps have been shown to enhance wound vascularity, provide bulk, limit bacterial colonization and infection, and promote rapid tissue regeneration [2-5]. Among these flaps, the soleus muscle flap has proven to be an excellent choice for soft tissue coverage in the middle third of the tibia. This article discusses the surgical technique for the medial hemisoleus flap and presents two **case reports** to highlight its effectiveness in clinical practice.

Comment [PB1]:

Comment [PB2]:

## Case Reports:

### Case 1:

A 17-year-old patient with a history of smoking presented with a medical condition dating back 2 years following a road accident (pedestrian hit by a car). This incident resulted in an open fracture of the left leg, which was treated with four screws and an external fixator for a duration of 1 year and 2 months. As a consequence of this treatment, a soft tissue defect with bone exposure developed in the middle third of the left leg.

**Comment [PB3]:** Change the statement to a better one

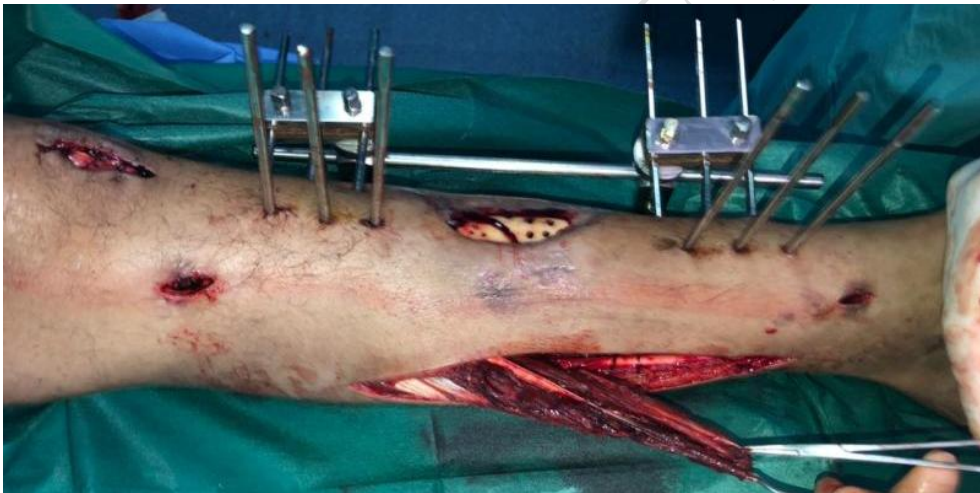

Figure 1: Removal of the intramedullary nailing, thorough debridement of the surgical site, **trepanning** of the exposed bone, and fracture stabilization with an external fixator.

**Comment [PB4]:**

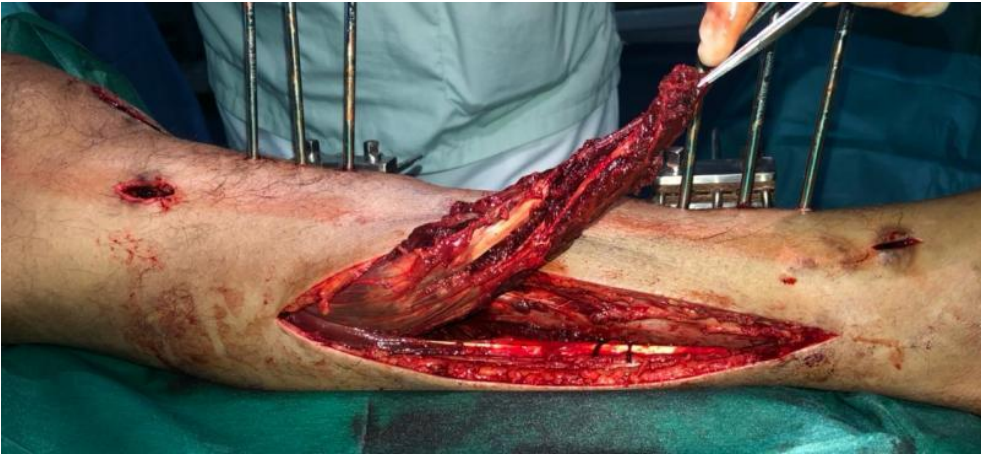

Figure 2: Hemisoleus flap raising.

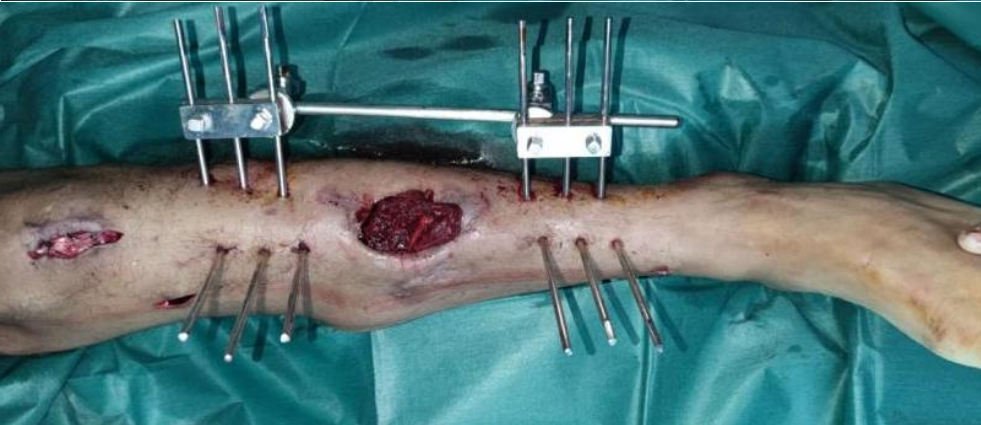
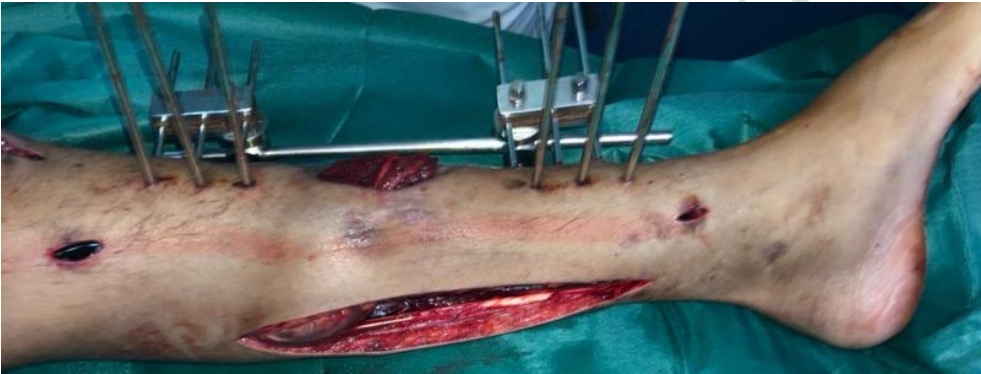

Figure 3: Flap rotation and tunneling to address the defect.

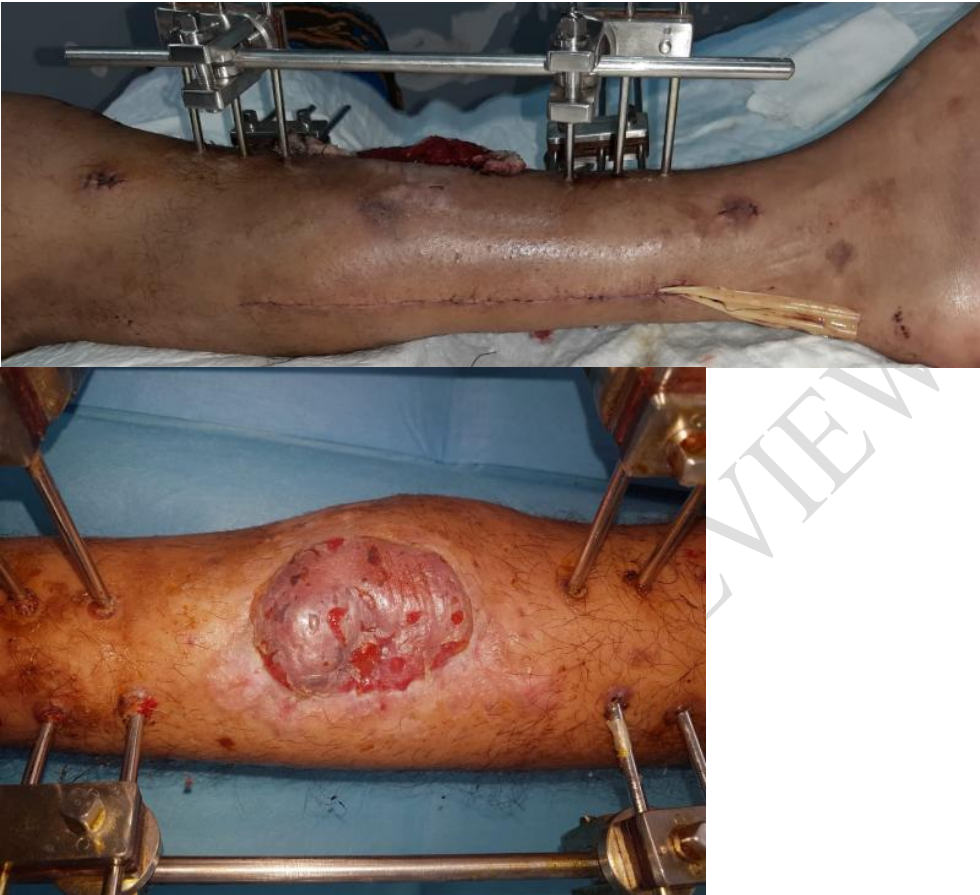

Figure 4: Split thickness skin graft at a later date.

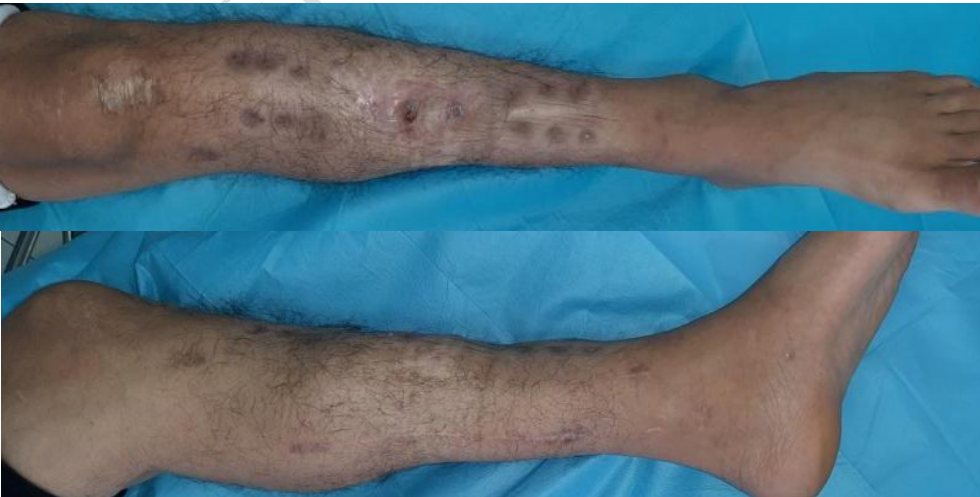

Figure 5: 1-year post-Op

## Case 2

A 25-year-old male **involved** in a traffic accident presents with a displaced open bone fracture of the middle third of the tibia and fibula with bone sequestrum.

Comment [PB5]:

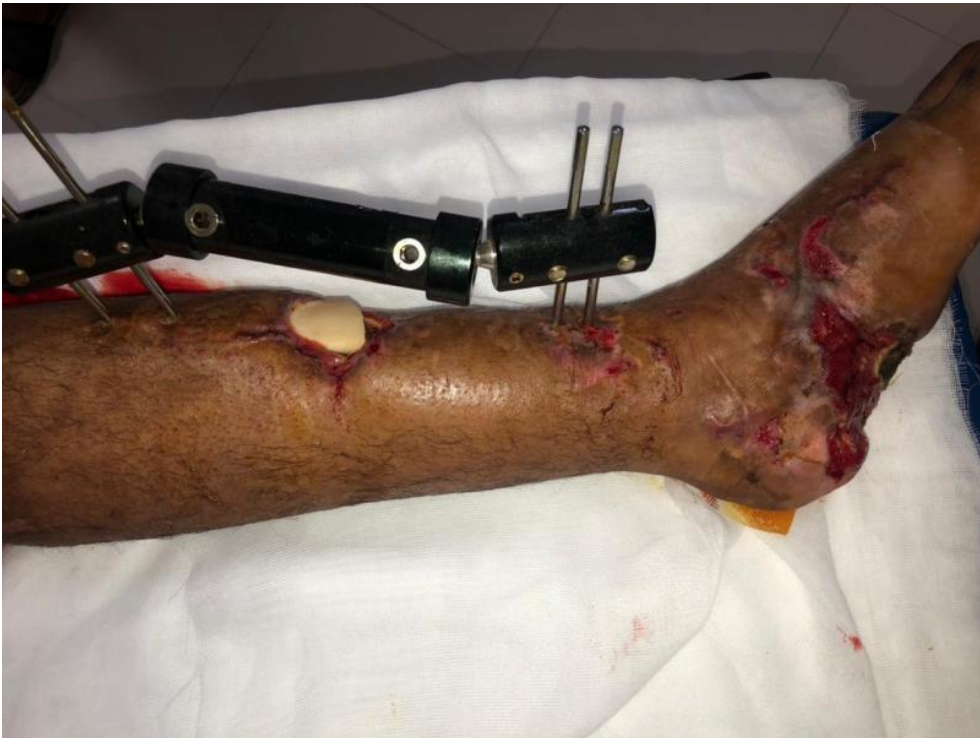

Figure 6: Preoperative picture showing a displaced fracture of the middle third of the tibia with the sequestrum exposed.

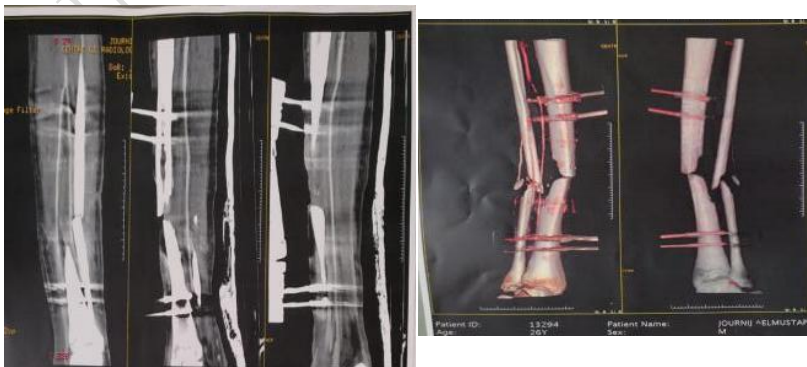

Figure 7: Displaced fracture of the middle third of the tibia and fibula with bone sequestrum.

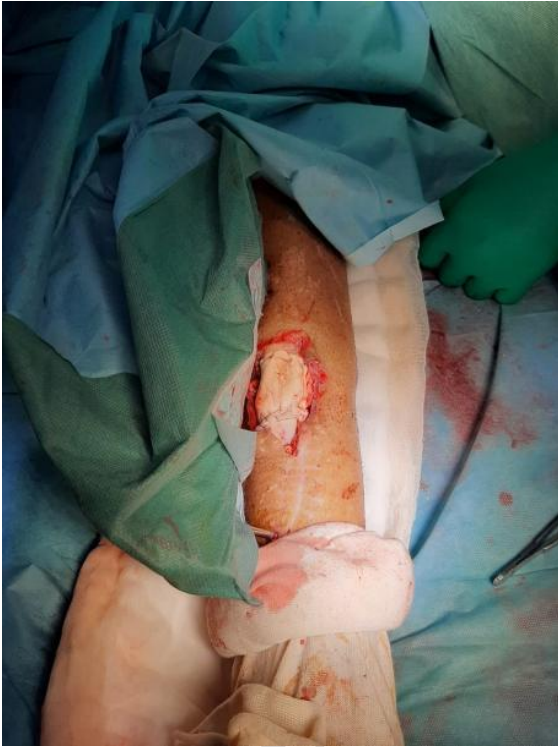

Figure 8: Sequestrectomy and realignment of the two bones with placement of a temporary surgical cement within the wound bed, and fracture stabilization is achieved by replacing the external fixator.

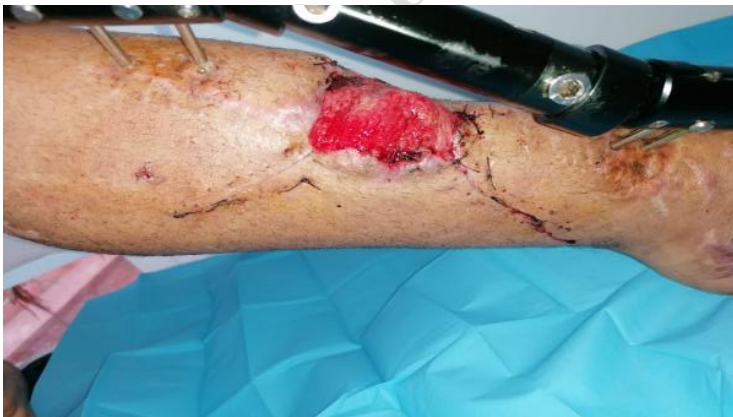
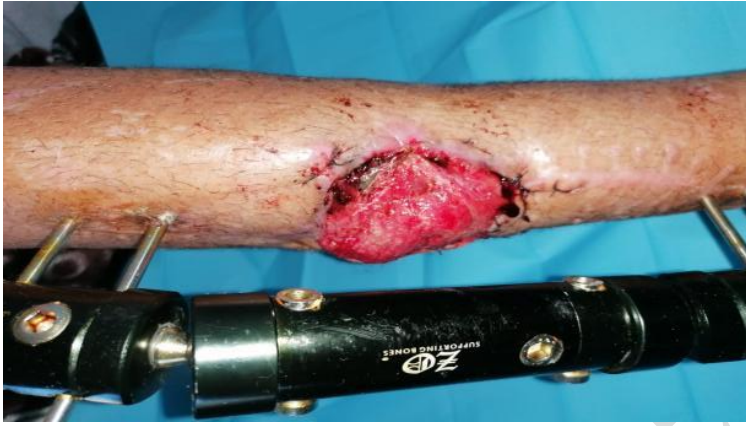
Figure 9: coverage by soleus flap

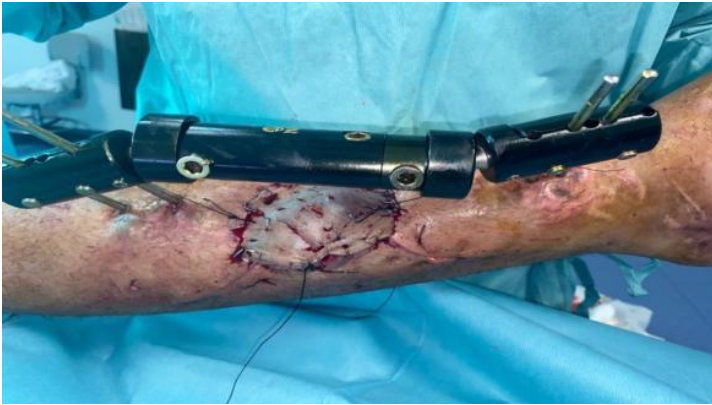

Figure 10: Split thickness skin graft at a later date

### **Surgical Technique (Medial Approach):**

The patient is placed in the supine position with a bolster under the contralateral side to facilitate external rotation of the extremity.

The cleavage point between the gastrocnemius and soleus muscles is typically located 2 to 3 cm from the tibial tuberosity, serving as the anatomical location for incision placement [7,8].

Careful identification and preservation of the great saphenous vein and nerve are essential for postoperative edema control.

The incision is made through the skin and subcutaneous fascia down to the deep fascia. Bridging veins are ligated, and the deep fascia is identified.

The gastrocnemius muscle is isolated and separated from the soleus muscle. Direct muscular arterial branches are identified and ligated.

The gastrocnemius muscle is gently reflected superiorly and laterally, and separated from the soleus muscle.

Dissection is carried out from proximal to distal until the conjoined tendon of the Achilles is reached.

The soleus attachment to the tibia is maintained during flap elevation to facilitate dissection, as the distal soleus is detached from the Achilles tendon.

The hemisoleus is classified as a type II muscle according to the Mathes and Nahai classification [9]. Its vascular supply is composed of one dominant pedicle accompanied by several minor pedicles supplying the vasculature to the muscle. The

blood supply to the medial half of the muscle arises from perforators originating from the posterior tibial artery. The lateral half is supplied by perforators from the peroneal artery, with both halves innervated by the motor branch of the tibial nerve [7,8].

The major and minor pedicles providing vasculature to the soleus are identified and preserved to enhance flap survivability. A distinct dissection plane is identified, allowing atraumatic separation of the soleus muscle from the fascia of the deep posterior compartment.

The soleus muscle is split longitudinally just lateral to the central raphe, preserving the intermuscular artery.

The muscle is rotated and inset into the defect without tension, and a split-thickness skin graft is secured to the flap for muscle coverage.

In cases where the flap is questionable, temporization with a dermal regenerative template and negative pressure wound therapy may aid in successful skin grafting at a later date.

A drain is placed between the superficial and deep posterior compartments at the harvest site for fluid management.

Before flap elevation, surgical sites should undergo thorough debridement, and any necessary fracture stabilization should be performed.

Comment [PB6]:

### **Discussion:**

Soft tissue injuries with bone exposure in the middle third of the tibia can pose significant clinical challenges, with high infection and nonunion rates [11]. The medial hemisoleus flap, originally described by Tobin in 1985 [12], has emerged as a valuable option for addressing these wounds. This flap offers several advantages:

- Consistent blood supply: The medial hemisoleus flap has a reliable blood supply, including dominant and minor pedicles, enhancing flap survivability [9].
- Improved arc of rotation: Splitting the muscle past the central raphe improves the reach of the flap, making it suitable for covering larger defects [12,13].

- Reduced donor site morbidity: Harvesting half of the muscle while preserving the lateral hemisoleus retains ankle plantar flexion strength with minimal donor site morbidity [10,13,14].
- Cost-effectiveness: Studies have shown reduced hospital stay, operative time, and costs when using the medial hemisoleus flap compared to free flaps, with equivalent postoperative outcomes [16].
- A skin graft is necessary for complete soft tissue coverage with an acceptable cosmetic outcome.

This technique offers numerous advantages, but its success is also contingent on careful patient selection, thorough surgical planning, and meticulous execution.

Patient evaluation is a crucial aspect of determining the suitability of the medial hemisoleus flap. Factors such as the patient's overall health, comorbidities, smoking history, and vascular status must be carefully assessed. In cases of compromised vascular supply to the flap region, additional preoperative evaluations like vascular Doppler, computed tomography angiography, magnetic resonance angiography, or angiography may be warranted [17]. Identifying patients with adequate vascular perfusion is essential to ensure the flap's viability and overall success.

The planning phase should include a thorough assessment of the soft tissue defect's size, location, and associated injuries, such as fractures. Soft tissue debridement should be performed meticulously to create a healthy wound bed for flap placement. Fracture stabilization, whether through internal or external fixation, is critical to prevent complications and ensure the long-term stability of the reconstructed area [18].

Variations of the medial hemisoleus flap and its combination with the gastrocnemius flap can be considered in cases with larger defects. Additionally, a thorough vascular workup may be necessary in high-energy trauma cases to ensure the viability of the flap [19].

Some surgeons have explored the use of osteomuscular flaps or basing the flap distally for specific clinical scenarios. The decision to use such variations should be based on the individual patient's needs and the surgeon's expertise [20].

Studies comparing the medial hemisoleus flap to alternative approaches, such as free flaps, have yielded promising results. Thornton and colleagues, as mentioned in the article, demonstrated

reduced hospital stays, shorter operative times, and cost savings when using the medial hemisoleus flap while achieving equivalent postoperative outcomes [16]. These findings underscore the economic and clinical advantages of this technique.

As plastic and reconstructive surgery continually evolves, further refinements and innovations related to the medial hemisoleus flap may emerge. Ongoing research may explore ways to optimize flap survival and cosmetic outcomes further. Additionally, the development of minimally invasive approaches or enhanced imaging techniques for vascular assessment may improve patient selection and overall flap success rates [21].

### **Conclusion:**

The medial hemisoleus flap has established itself as a versatile and reliable option for addressing complex soft tissue defects in the middle third of the tibia. Its consistent blood supply, improved arc of rotation, and reduced donor site morbidity make it a preferred choice for many surgeons. With careful patient selection, meticulous surgical planning, and an understanding of variations and combinations, the medial hemisoleus flap continues to play a pivotal role in enhancing patient outcomes and minimizing complications in the field of plastic surgery. Future research and innovation hold the potential to further enhance the utility and effectiveness of this technique.

### **Reference:**

1. Schmidt AH, Finkemeier CG, Tornetta P. Treatment of closed tibial fractures. *J Bone Joint Surg* 2003;85-A(2):352–68.
2. Calderon W, Chang N, Mathes SJ. Comparison of the effect of bacterial inoculation in musculocutaneous and fasciocutaneous flaps. *Plast Reconstr Surg* 1986; 77(5):785–94.
3. Chang N, Mathes SJ. Comparison of the effect of bacterial inoculation in musculocutaneous and random-pattern flaps. *Plast Reconstr Surg* 1982;70(1):1–10.

4. Gosain A, Chang N, Mathes S, et al. A Study of the relationship between blood flow and bacterial inoculation in musculocutaneous and fasciocutaneous flaps. *PlastReconstr Surg* 1990;86(6):1163.
5. Klebuc M, Menn Z. Muscle flaps and their role in limb salvage. *Methodist Debaquey Cardiovasc J* 2013;9:95–9.
6. Ahmad I, Khurram M. Hemisoleus muscle flap in the reconstruction of exposed bones in the lower limb. *J Wound Care* 2013;22(11):635–42.
7. Kelikian AS, Sarrafian SK. Sarrafians anatomy of the foot and ankle, 3rd edition. Philadelphia: Lippincott Williams & Wilkins. p. 326–36.
8. Raveendran SS, Kumaragama KGJL. Arterial supply of the soleus muscle: anatomical study of fifty lower limbs. *Clin Anat* 2003;16:248–52.
9. Mathes SJ, Nahai F. Classification of the vascular anatomy of muscle: experimental and clinical correlation. *PlastReconstr Surg* 1981;67:177–87.
10. Pu LIQ. Successful soft-tissue coverage of a tibial wound in the distal third of the leg with a medial hemisoleus muscle flap. *PlastReconstr Surg* 2005;115(1): 245–51.
11. Kohlprath R, Assal M, Uckay I, et al. Open fracture of the tibia in the adult: surgical treatment and complications. *Rev Med Suisse* 2011;7(322):2482, 2484–8.
12. Tobin GR. Hemisoleus and reversed hemisoleus flaps. *PlastReconstr Surg* 1985; 76(1):87–96.
13. Pu LIQ. Further experience with the medial hemisoleus muscle flap for soft tissue coverage of a tibial wound in the distal third of the leg. *PlastReconstr Surg* 2008; 121(6):2024–8.

14. Simon SR, Mann RA, Hagy JL, et al. Role of the posterior calf muscle in normal gait. *J Bone Joint Surg* 1978;60A:465.
15. Zenn M, Jones G. *Reconstructive surgery: anatomy, technique, and clinical application*. New York: CRC Press; 2012. p. 1628–53.
16. Thornton BP, Rosenblum WJ, Lee L. Reconstruction of limited soft-tissue defect with open tibial fracture in the distal third of the leg. *Ann Plast Surg* 2005;54(3): 276–80.
17. Schierle CF, Rawlani V, Galiano RD, et al. Improving outcomes of the distally based hemisoleus flap: principles of angiosomes in flap design. *Plast Reconstr Surg* 2009;123(6):1748–54.
18. Jose Antonio Delgado Perez, Pedro Rodriguez, Michael D. Liette, Suhail Masadeh. Medial Hemisoleus Flap for Middle Third of the Tibia Defects. *Clin Podiatr Med Surg* 37 (2020) 621–630.
19. Jitprapaikulsarn S, Benjawongsathien K, Patamamongkonchai C, Gromprasit A, Thremthakanpon W. Combined medial gastrocnemius and hemisoleus flap: a reproducible alternative for open tibial fractures complicated with large or double soft tissue defects. *Eur J Orthop Surg Traumatol*. 2021 Feb;31(2):413-420.
20. Johan MP, Nong I, Saleh R, Subagio ES, Asy'arie AP, Kawilarang MA. Distally based hemisoleus flap for soft tissue defect closure following chronic osteomyelitis of the distal tibia: A case report. *Int J Surg Case Rep*. 2021 Oct;87:106437.
21. Afzal MO, Haq AU, Riaz MA, Tarar MN, Alvi HF. Lower extremity reconstruction: utility of smartphone thermal imaging camera in planning perforator based pedicled flaps. *J Ayub Med Coll Abbottabad*. 2020 Oct-Dec;32(Suppl 1)(4):S612-S617.