

Comparison between CT-scan Finding and operative finding of patients with Chronic Rhinosinusitis undergoing Functional Endoscopic Sinus Surgery

Abstract:

Background: Chronic rhinosinusitis is a group of disorders characterized by inflammation of the mucosa of the nose and Paranasal sinuses for at least 12 consecutive weeks. It is a common clinical problem that has a significant impact on quality of life. CT-scan has become the modality of choice for assessment of CRS and Endoscopic sinus surgery is a minimally invasive technique and the surgical management of choice for chronic rhinosinusitis.

The aim of this study: To verify the agreement and associations between preoperative CT-scan and intraoperative ESS findings in patients with CRS and to evaluate the types and frequency of anatomical variants in the nasal fossa and paranasal sinuses as well as their clinical correlations in chronic rhinosinusitis.

Patients and Methods: This study is experimental study in which 50 subjects were collected by simple randomization technique as they visited our department in a period from January to December 2015. All the participants were guided to conduct a coronal, axial, and sagittal CT scan of the nose and paranasal sinuses before functional endoscopic sinus surgery. The anatomical variations and mucosal abnormalities on CT Scan & ESS were studied and analyzed.

Results: Septal deviation is the most common anatomical abnormality, 37(74%) of the participants have these abnormalities. The presence of agar nasi cells 34(68%), and chonca bullosa 28(56%) are the second and third most common anatomical variants found on CT-scan images. There is a high level of agreement between both the diagnostic tools at the high numbers of both positive and negative results for each abnormal finding.

Conclusions: There was a good correlation between CT and ESS findings and there was a slight difference between the diagnostic characteristics of these different tools.

Keywords: Chronic Rhinosinusitis, Functional Endoscopic Sinus Surgery, Ostiomeatal Complex, Computed Tomography.

Introduction:

A category of diseases known as chronic rhinosinusitis (CRS) is defined by inflammation of the nasal and paranasal sinus mucosa for at least 12 consecutive weeks. A prevalent clinical issue that significantly lowers quality of life is chronic rhinosinusitis. It is one of the most frequent causes for people to seek medical attention, and it has a significant direct medical expense ⁽¹⁾. About 5 to 15% of urban residents are impacted by CRS. According to reports, sinusitis is more common than any other chronic ailment (146/1000 people), and it's also supposedly getting more common ⁽²⁾.

In general, sinusitis ranks seventh in terms of frequency of antibiotic prescriptions. Regarding the correct diagnosis of this ailment and the best treatment options, there are still several disagreements. Discussions over the value of imaging investigations and when they might be beneficial will likely continue to impede the clinical solution to this widespread issue ⁽³⁾.

Surgery is investigated as a potential treatment for what is fundamentally an inflammatory disorder because medical treatment that just targets this inflammation may not be able to completely remove the condition ⁽⁴⁾. Today, endoscopic sinus surgery is recognized as the preferred surgical treatment for chronic rhinosinusitis ⁽⁵⁾. Because of a better understanding of the anatomy, better endoscopes and video equipment, newer instruments, and greater technology,

endoscopic sinus surgery is continually evolving. With functional endoscopic sinus surgery (FESS), inflamed tissue is surgically removed from key locations along the mucociliary clearance channels ⁽⁶⁾.

With the use of Functional Endoscopic Sinus Surgery (FESS), the sinus ostia and air cells are opened. Restoring sinus ventilation and proper function is the aim of this therapy^(7, 8). The idea behind FESS is to preserve the natural, non-obstructing architecture and mucous membrane while removing tissue that is obstructing the Osteo Metal Complex (OMC) and facilitating drainage ⁽⁹⁾.

According to the theory behind functional endoscopic sinus surgery (FESS), the osteomeatal complex (OMC) is a critical site in the pathophysiology of chronic sinus disease ⁽¹⁰⁾. Without contacting the mucosa in these sinuses, the elimination of mechanical blockage in the OMC area allows for appropriate ventilation, drainage, and resolution of secondary mucosal alterations in the frontal, maxillary, and ethmoid sinuses. With minimal damage to nasal and paranasal architecture, this aids in the restoration of the normal functional and anatomical position ⁽¹¹⁾.

Computed tomography (CT-scan) is the method of choice for treating inflammatory conditions of the sinuses, especially the osteomeatal complex. High-resolution CT is used to assess significant anatomical landmarks, the severity of the inflammatory sickness, and any alterations ⁽¹²⁾. The development of CT and its present, more widespread use have surely benefited the practitioner. The examination of the paranasal sinuses with CT has grown to be a helpful diagnostic tool and an essential component of surgical planning. The creation of intraoperative roadmaps is another use for it. The radiologic test of choice nowadays for assessing a patient's paranasal sinuses during sinusitis is CT ⁽¹²⁾.

The utilization of functional endoscopic sinus surgery (FESS) and CT scanning has enabled the modern sinus surgeon to treat patients more successfully, resulting in decreased morbidity and consequences. Sinus CT scans must be examined and

interpreted by medical professionals who wish to treat patients with sinus disease (13).

Aim of the study:

1. To verify the agreement and associations between preoperative CT-scan and intraoperative ESS findings in patients with CRS.
2. To evaluate the types and frequency of anatomical variants in the nasal fossa and paranasal sinuses as well as their clinical correlations in chronic rhinosinusitis.

Subjects and Methods:

This study was conducted in the Department of Otorhinolaryngology in Sulyaimania Teaching Hospital. The design of the study is experimental study and the sample size was determined by Slovin's formula is calculated as:

$$n = N / (1 + Ne^2)$$

Where: n = sample size; N = population size; e = acceptable margin of error

Accordingly 50 subjects were collected by simple randomization technique as they visited our department in a period from January to December 2015. All the participants have had signs and symptoms of chronic rhinosinusitis, and detailed history of the condition as well as related medical conditions was taken by an otolaryngologist then the participants were guided to conduct a coronal, axial, and sagittal CT scan of the nose and paranasal sinuses, then all the participants underwent functional endoscopic sinus surgery.

Data collection case sheets included general information regarding the participants' name, age, gender, residency, and blood group. Then information regarding Major and minor symptoms such as; facial pain/pressure, facial congestion/fullness, nasal obstruction/blockage, nasal discharge, hyposmia/anosmia, purulence on nasal exam, fever, headache, halitosis, fatigue, dental pain, cough, and ear pain.

Excluded subjects were: subjects visited for secondary revision, subjects with malignancy, and those with medical treatment less than 2 weeks of conducting CT scans.

The characteristics of the computed tomography were performed with 64-slice multidetector computed tomography with the patient in the supine position. After obtaining the scout projection, the area of scanning was defined to include the region from the roof of the frontal sinus down to the hard palate. Coronal sections were reformatted by the computer from the obtained axial sections with the same slice thickness of 2mm. The duration of the whole scanning is about 7 seconds. The CT scan is manufactured by Siemens Company. The photographs generated were photographed at appropriate window widths and window level, window width = 2000 HU and window level = 200 HU to depict the bony abnormalities as well as soft tissue pathologies.

Otolaryngologists and radiologists have evaluated and read the CT photographs. Anatomic variations of the paranasal sinuses that are consistent with CRS were weighed and evaluated on each participant's CT to search for the presence of these anatomical variations, both the right and left sides were considered as the same. Recorded anatomical variations included: choncha bullosa, agar nasi cell, onodi cell, paradoxical middle turbinate, haller cell, pneumatized uncinate process, septal deviation, large ethmoidal bulla, dehiscence of the optic canal, dehiscence of the carotid canal, and frontoethmoidal cells. The findings of CT Scans were then classified according to the Lund & Mackay (1993) radiological scoring system. Each sinus is graded between 0 and 2 (0 = no abnormality, 1 = partial opacification, and 2 = total opacification).

Statistical analysis:

Statistical Package for Social Sciences (SPSS) version 22 was used for data entry, calculations, and data interpretations. The data was described in mean and standard

deviation (SD) and frequencies and proportions. The sensitivity and specificity of CT-scan are calculated as part of measuring the characteristics of this test when abnormal findings on ESS are considered as the standard or the reference.

Results:

A total 50 participants are included in our study with a mean age of 37.8 years and a standard deviation of 10.23 years. The range of the ages was between 11 and 62 years. Sixty percent (30 participants) were males and 40% (20 participants) were females, with a male/female ratio of 3:2. Data of 28 (56%) participants were collected retrospectively while data of 22 (44%) participants was collected prospectively as shown in table (1).

Table (1): Study parameters.

Study parameters		Number (%)
Age groups (years)	11-25	6 (12.0)
	26-30	6 (12.0)
	31-45	29 (58.0)
	46+	9 (18.0)
Gender	Males	30(60.0)
	Females	20(40.0)
Types of study	Retrospective	28(56.0)
	Prospective	22(44.0)

The frequency and incidence of the frontoethmoidal cells were different for each type. Type I was the most common 8(16%) patients, and Type IV was the least common 2(4%) participants. Frequency and incidence of Type II & III were 6(12%) & 4(8%) participants respectively. Lund-Mackay scores were recorded in all of the participants. The mean Lund-Mackay score was 11.3 with a standard

deviation of 5.07, ranging from 2 to 23 points, and the highest value corresponded to greater severity of the disease. The participants who have a score of (10-14) are the highest number which is 19(38%). And there are only four (8%) participants with a score between (0-4). Other score groups and their correspondent number and percentage of participants are explained in figure (1).

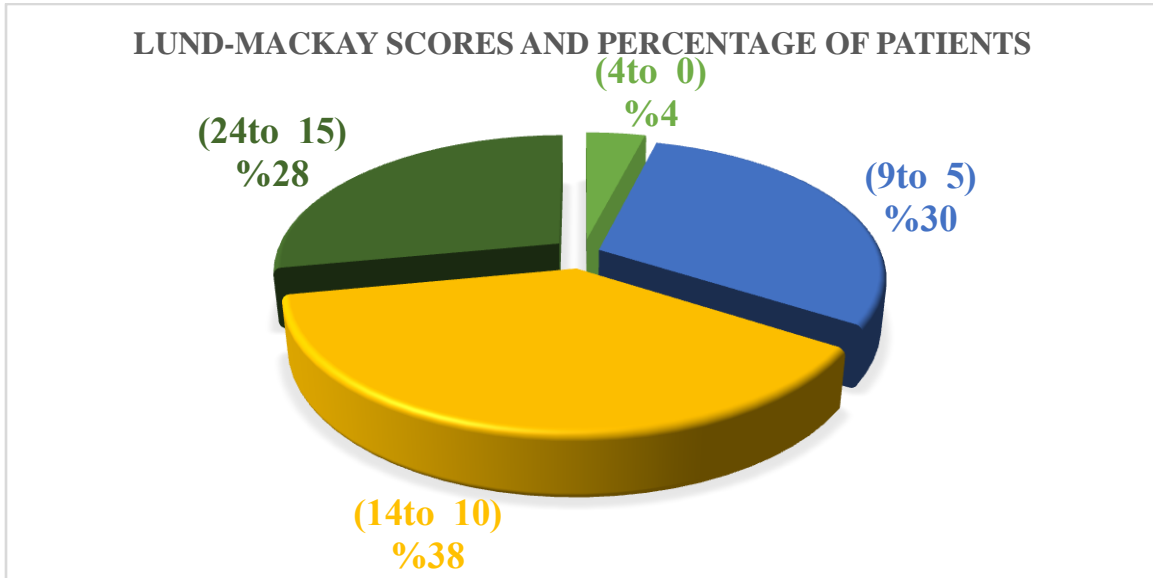


Figure (1): Lund-Mackay scores and the correspondent percentage of participants.

The most affected paranasal sinus was the maxillary sinuses, and then comes the anterior ethmoid and sphenoid sinuses in the second and third place. The osteomeatal complex was found to be mostly involved, 68% on the right side and 76% on the left. Other numbers and percentages are viewed in table (2).

Table (2): Incidence and frequency of partial & complete opacification and the correspondent affected sinuses.

Site	Partial Opacification	Complete Opacification
	No. (%)	No. (%)
Maxillary Rt.	26(52)	19(28)
Maxillary Lt.	29(58)	15(30)
Anterior Ethmoid Rt.	18(36)	17(34)
Anterior Ethmoid Lt.	18(36)	15(30)
Posterior Ethmoid Rt.	12(24)	15(30)

Posterior Ethmoid Lt.	12(24)	15(30)
Sphenoid Rt.	19(18)	10(20)
Sphenoid Lt.	10(20)	10(20)
Frontal Rt.	11(22)	11(22)
Frontal Lt.	9(18)	5(10)
OMC Rt.	0	34(68)
OMC Lt.	0	38(76)

The frequency of aberrant findings detected during ESS and by sinus CTs, there is a high level of agreement between both the procedures as we look at the high numbers of either both positive and both negative results for each abnormal finding. Both agree that: Septal deviation is available in 33 participants and absent in 11 participants, mucosal thickening present in 25 and absent in 10 participants, Polyps are present in 33 and absent in 11 participants. Other findings are all viewed in table (3).

Table (3): Comparison between CT and ESS findings in participants with Chronic Rhinosinusitis.

Findings	ESS Positive		ESS Negative	
	CT-scan positive	CT scan negative	CT-scan positive	CT scan negative
Septal deviation	33	3	3	11
Mucosal thickening	25	6	9	10
Polyp	33	2	4	11
Cyst	11	0	0	39
Mass	2	2	0	46
Hypertrophy of inferior turbinate	30	1	3	16
OMC obstruction	31	3	0	16
Chonca bullosa	14	0	5	31

To be able to calculate and compare diagnostic test characteristics in detecting abnormalities we have considered ESS results as the standard or the reference. Sensitivity and specificity for CT-scan test were calculated with 95% confidence interval (CI). True positive and true negative results were considered when the

results for both tests were similar. An abnormal finding was defined as false-positive when CT-scan showed an abnormality but the same abnormality was not observed during ESS. A false negative finding was considered to be present when an abnormal finding was observed during ESS but the same abnormality was not detected on CT-scan images. About the diagnostic characteristics of CT-scan, the sensitivity is the ability of the test to correctly identify participants with sinus abnormalities and it is calculated as the number of true positives/ (true positives + false negatives). Specificity is the ability of CT-scan to correctly identify those participants without sinus abnormalities when ESS diagnostic features are considered as the standard, specificity is calculated as: the number of true negatives/ (true negatives + false positives)as showed in table (4).

Table (4): Sensitivity and specificity of CT-scan imaging in diagnosis of abnormalities.

Findings	Sensitivity (95%CI)	Specificity (95% CI)
Septal deviation	91.7(77.5 to 98.2)	78.6(49.2 to 95.3)
Mucosal thickening	80.6(62.5% to 92.5)	52.6(28.9 to 75.5)
Polyp	94.3(80.8 to 99.3)	73.3(44.9 to 92.2)
Cyst	100(71.5 to 100)	100(91 to 100)
Mass	50(6.8 to 93)	100(92.3 to 100)
Hypertrophy of inferior turbinate	96.7(83.3 to 99.9)	84.2(60.4 to 96.6)
Hypertrophy of middle turbinate	76.9(46.2 to 95)	94.6(81.8 to 99.3)
OMC obstruction	91.2(76.3to 98)	100(79.4 to 100)
Chonca bullosa	100(71.5 to 100)	87.2(72.6 to 95.7)

More about the characteristics of CT-scan and ESS, when we compare the characteristics of ESS to CT-scan we find that for diagnosis of each of Mass,

Hypertrophy of inferior turbinate, OMC obstruction the odds ratio is above one which means ESS have diagnosed higher numbers of these abnormalities than as compared to CT-scan in our patients, for the rest of abnormalities, odds ratio is either one or below one. Which means that both ESS and CT-scan have diagnosed the same number of abnormalities or ESS have diagnosed less number of findings than CT-scan respectively as shown in table (5). None of the findings are statistically significant (P-values are more than 0.05).

Table (5): Anatomic abnormalities' Odds ratios and P-values when ESS and CT-scan are compared.

	Odds Ratio (OR)	P-value
Septal deviation	1	1
Mucosal thickening	0.75	0.5
Polyp	0.8	0.65
Cyst	1	1
Mass	2	0.4
Hypertrophy of inferior turbinate	0.84	0.67
Hypertrophy of middle turbinate	2.2	0.11
OMC obstruction	1.3	0.53
Chonca bullosa	0.63	0.29

Discussions:

Chronic rhinosinusitis, and its symptoms of nasal obstruction, nasal discharge, facial pain and headache, as well as abnormalities of smell is the most common disease and source of consultations of otolaryngologists⁽¹⁴⁾. Computed tomography (CT-scan) is the method of choice for treating inflammatory conditions of the sinuses, especially the osteomeatal complex. High-resolution CT is used to assess significant anatomical landmarks, the severity of the inflammatory sickness, and any alterations⁽¹⁵⁾.

CT is central to the modern management of chronic rhinosinusitis, owing to its ability to delineate mucosal disease, to demonstrate primary obstructive pathology,

and to image distal structures such as the posterior ethmoid sinus, which cannot be viewed with direct endoscopy ⁽¹⁶⁾. When computed tomography is combined with nasal endoscopy the diagnosis of sinonasal disease will become more rational and accurate ^(14, 17, 18). Overall, for areas that are not accessible to nasal endoscopy, CT scan can be useful in identifying the disease ⁽¹⁷⁾.

Prior to surgical intervention, the Lund-Mackay staging approach, which is based on a straightforward numerical score obtained from the CT scan, has been utilized to quantify inflammatory illness for some time.

The Lund-Mackay staging approach can be used to stage CT scan results since it is straight forward and trust worthy ⁽¹⁹⁾. This is the most accepted and recommended CT staging system ⁽²⁰⁾. It achieves the highest level of intra and inter-observer agreement without being time consuming when compared with the other scoring systems ⁽²¹⁾. A total score of 0-12 is considered for each side separately, and then a total score of 0-24 is obtained for each patient, and it has been proposed that patients submitted to endoscopic sinus surgery for CRS should have a minimum score of four ⁽⁴⁾.

The CT-scan images of our patients revealed different prevalence for the frontal cells, as it was 16% for Type I, 12% for Type II, 8% for Type III, and 4% for type IV. In a study conducted by Eweiss & Khalil they had higher prevalence for frontal cells and the results were as the following “Type I frontal cells were found 21.42%, Type II frontal cells were found in 26.429%, Type III frontal cells were found in 22.14%, and Type IV frontal cells were found in 8.5%.” ⁽²²⁾. As we consider the similarities and differences between CT-scan and ESS findings, septal deviation was evidenced in both diagnostic situations and had similar incidence which was 72% (36 patients), the same similarity was observed for diagnosing cysts 22% (11 patients). These similarities and differences can further be observed as we look at the odds ratios. For an odds ratio equal to 1, it means there are no

differences between both ESS and CT-scan in diagnosis of an abnormality such as (Septal deviation, Cyst). For an odds ratio greater than 1, it means ESS was superior to CT-scan in finding of an abnormality, such as (Mass, Hypertrophy of middle turbinate, and OMC obstruction). And for an odds ratio less than 1, it means CT-scan was superior in finding of an abnormality, such as (Mucosal thickening, polyp, hypertrophy of inferior turbinate, and concha bullosa). None of the above results were statistically significant (P-values were greater than 0.05). Due to lack or deficiency of studies conducted on the same topic and similar way of comparisons we were not able to retrieve or find any relevant articles to compare their findings to ours. Despite using a different method to compare ESS and CT scans, Zojaji *et al.*⁽¹⁸⁾ came to the same conclusion that the two diagnostic techniques have good to outstanding agreement. And they discovered that the detection of hypertrophy concha was more strongly supported by a CT scan (86% vs. 82% in favor of sinus endoscopy). Another important finding of their study was that, whereas only 31 (60%) of 51 patients had the same issue in ESS, mucosal thickness was present in 36 (70%) of 51 patients as demonstrated by CT⁽²³⁾.

The diagnostic characteristics of CT-scan in detecting abnormalities were calculated by considering ESS results as the standard or the reference. Sensitivity and specificity for CT-scan test were calculated with 95% confidence interval (CI). True positive and true negative results were considered when the results for both tests were similar. An abnormal finding was defined as false-positive when CT-scan showed an abnormality but the same abnormality was not observed during ESS. A false negative finding was considered to be present when an abnormal finding was observed during ESS but the same abnormality was not detected on CT-scan images. About the diagnostic characteristics of CT-scan, the sensitivity is the ability of the test to correctly identify patients with sinus abnormalities, and specificity is the ability of CT-scan to correctly identify those patients without

sinus abnormalities when ESS features are considered as the standard. We have noticed very high sensitivity of CT-scan in diagnosing almost all of the abnormalities (apart from Mass). This means, by considering ESS as a reference, CT-scan is highly dependable in finding sinus abnormalities.

Conclusions:

- In our study, there was a good correlation between CT and ESS findings, there were a slight difference between the diagnostic characteristics of these different tools, we state that both preoperative endoscopy and CT are complimentary in the assessment of various anatomical variations in the OMC, therefore, findings of both tests should be considered before FESS.
- Different and frequent anatomical variants may be found in the OMC, and a single individual may present with different variants. The presence of variants, either singly or in combination, does not constitute a disease state.

Ethical approval and Consent:

A written consent was taken from each participant involved in the study and the administrative agreement of the Department of Otorhinolaryngology and the bioethics committee in Sulyaimania Teaching Hospital.

References

1. Benniger MS. Rhinosinusitis, Scott-Brown's Otolaryngology Head and Neck Surgery. Seventh edition, 2008; 113:1439-1448.
2. Mackay IS and Lund VJ. Classification and differential diagnosis of rhinosinusitis, Scott- Brown Otolaryngology Head and Neck Surgery. Seventh edition, 2008; 108:1380-1385.
3. DeCastro A, Mims L, Hueston WJ. Rhinosinusitis. *Primary Care: Clinics in Office Practice*. 2014; 41(1): 47-61.
4. Ni JS, Kompelli AR, Nguyen SA, *et al*. The Sinus and Nasal Quality of Life Survey (SN-5) in the management of pediatric chronic rhinosinusitis: a

- systematic review and meta-analysis. *Int J Pediatr Otorhinolaryngol*. 2018; 111: 162-169.
5. Zhao X-Y, Chen M, Cheng L. Current and Emerging Treatment Options in Sinus and Nasal Diseases: Surgical Challenges and Therapeutic Perspectives. *Journal of Clinical Medicine*. 2023; 12(4):1485. <https://doi.org/10.3390/jcm12041485>
 6. Howard L. Levine, Clemente MP. Surgical anatomy of the paranasal sinus surgery, Endoscopic and Microscopic Approaches. First edition, 2005;1 :23-34.
 7. Ghori SM, Aziz B, Rashid A, Pal MB. An Analysis of Functional Endoscopic Sinus Surgery (FESS) for Sinonasal Disease. *PJMHS*. 2012; 6(4): 827-830.
 8. Homsy MT and Gaffey MM. Sinus Endoscopic Surgery. In: StatPearls. Treasure Island (FL): StatPearls Publishing; 2023 Jan-. Available from: <https://www.ncbi.nlm.nih.gov/books/NBK563202/>
 9. Al-Mujaini A, Wali U, Alkhabori M. Functional endoscopic sinus surgery: indications and complications in the ophthalmic field. *Oman medical journal*. 2009;24(2): 70.
 10. Stanojković, V. Correlation Between Computed Tomography And Intraoperative Finding In Functional Endoscopic Surgery of Nose And Paranasal Sinuses. *Acta Medica Medianae*. 2010;49(3): 616-073.
 11. Dua K, Chopra H, Khurana AS, Munjal M. CT scan variations in chronic sinusitis. *Indian Journal of radiology and imaging*. 2005;15(3): 315.
 12. Papadopoulou AM, Bakogiannis N, Skrapari I, Bakoyiannis C. Anatomical Variations of the Sinonasal Area and Their Clinical Impact on Sinus Pathology: A Systematic Review. *Int Arch Otorhinolaryngol*. 2022 Jul; 26(3): e491–e498. doi: 10.1055/s-0042-1742327
 13. Usmani T, Fatima E, Raj V, Aggarwal K. Prospective Study to Evaluate the Role of Multidetector Computed Tomography in Evaluation of Paranasal Sinus Pathologies. *Cureus*. 2022;14(4):e24011. doi:10.7759/cureus.24011
 14. Asif AW, Sohif K, Mohammad L. CT scan evaluation of the anatomical variations of the osteomeatal complex. *Indian J Otolaryngology Head Neck surgery*. 2009;61:163-168.
 15. Mendiratta V, Baisakhiya N, Singh D, Datta G, Mittal A, Mendiratta P. Sinonasal Anatomical Variants: CT and Endoscopy Study and Its Correlation with Extent of Disease. *Indian J Otolaryngol Head Neck Surg*. 2016;68(3):352-358. doi:10.1007/s12070-015-0920-x

- 16.Nouraei SAR, Elisay AR, Dimarco A, *et al.* Variations in paranasal sinus anatomy: implications for the pathophysiology of chronic rhinosinusitis and safety of endoscopic sinus surgery. *Journal of Otolaryngology-Head and Neck Surgery*.2009; 38(1): 32.
- 17.Pokharel M, Karki S, Shrestha BL, Shrestha I, Amatya RC. Correlations between symptoms, nasal endoscopy computed tomography and surgical findings in patients with chronic rhinosinusitis. *Kathmandu University Medical Journal*. 2013; 11(3): 201-205.
- 18.Zojaji R, Mirzadeh M, Naghibi S. Comparative evaluation of preoperative CT scan and intraoperative endoscopic sinus surgery findings in patients with chronic rhinosinusitis.2008;77-82.
- 19.Alshammari D, Alshaikh R, Bakheet M, Janahi W, Alreefy H. Correlation between Radiological Staging of Chronic Rhinosinusitis and Revision of Endoscopic Sinus Surgery. *International Journal of Otolaryngology and Head & Neck Surgery*. 2021; 10: 119-130. <https://doi.org/10.4236/ijohns.2021.102013>
- 20.Sudiro M, Kuntara A, Waldi D. Correlation of Lund-Mackay Score on Computed Tomography Scan and Nasoendoscopic Score in Chronic Rhinosinusitis. *Acta Inform Med*. 2023; 31(1): 53-56. doi:10.5455/aim.2023.31.53-56
- 21.Krishniya P, Rajpurohit P, Sharma VK, Aseri Y, Verma PC. A Prospective Correlation Study between Computerized Tomography of Paranasal Sinuses and Nasal Endoscopy Findings in Patients of Chronic Rhinosinusitis Undergoing Functional Endoscopic Sinus Surgery. *Indian Journal of Otolaryngology and Head & Neck Surgery*. 2022 Dec; 74(Suppl 3): 4706-4712.
- 22.Eweiss AZ & Khalil HS. The prevalence of frontal cells and their relation to frontal sinusitis: a radiological study of the frontal recess area. *ISRN otolaryngology*. 2013.
- 23.Singhal P,Sonkhaya N,Mishra P, Srivastava SP. Impact of Anatomical and Radiological Findings forconsideration of functional endoscopic sinus surgery.*Indian J Otolaryngol Head Neck Surgey*.Dec 2012;64(4):382-385.