

EFFECTS OF OYSTER MUSHROOM (*Pleurotus ostreatus*) ON BODY WEIGHT AND PATHOLOGY OF VITAL ORGANS IN PATHOGENIC STAPH INFECTION

ABSTRACT

Aims: Oyster mushroom is rich in secondary metabolites of pharmacological importance. This study evaluates the effect of ethanolic extract of Oyster mushroom on the vital organs of *Staphylococcus aureus* infected Wistar rats after seven days of administration.

Study design: Completely randomized design was used in the study.

Place and Duration of Study: This study was carried out at the Microbiology, Parasitology and Ethnoveterinary medicine Unit of the Department of Animal Production and Health, Federal University of Technology, Akure, Nigeria, between March and December 2022.

Methodology: The mushroom was processed using a cold extraction technique. A bacterial suspension of *Staphylococcus aureus* was inoculated via oral route into the experimental animals, which were randomly distributed into six groups of five. Group 1: normal control; group 2: positive control; group 3: negative control, inoculated but received no antimicrobial; and group 4 to 6 were inoculated, and administered with 625, 1250 and 2500 mg dose of the extract respectively. The treatment was administered for seven days, after which blood samples were cultured for the bacterial count and vital organs were analysed for pathological changes.

Results: The colony count was significantly raised at 625 mg dose while the dose ranging from 1250 to 2500 mg yielded insignificant bacterial growth ($P < 0.01$). The percentage weight gain was significantly lower ($P < 0.01$) in 1250 mg extract in comparison with the negative control after 7 days complete treatment but there was no statistical variation in the 7 days post-treatment percentage weight gain and the relative organ weight ($P < 0.01$). The histological sections showed no variation from normal controls except 625 mg liver that showed some vacuolations within the hepatocytes.

Conclusion: The organ-body mean weight was proportionate, and the histological sections of the liver, kidney, skin, lungs, heart and spleen were indicative of no anatomical variations as compared with the normal control tissues. The beneficial effect of *P. ostreatus* on the vital organs was further established by the active clearing of *S. aureus* infection at 1250 to 2500 mg dose with no observable pathological change in the tissues. The bioactive agents inherent in *P. ostreatus* were effective against *S. aureus* infection. The vacuolations observed in the low dose liver sections unveiled the ill effect of under-dose treatment and its consequence on the liver cells. The histopathological investigations were suggestive of the safety and tolerance of *P. ostreatus* to the body system. Nevertheless, further studies should be carried out on its toxicological profiles.

Key Words: *Pleurotus ostreatus* (Oyster mushroom), *Staphylococcus aureus*, colony count, vital organs, tolerance

1. INTRODUCTION

Staphylococcus aureus is a major bacterial human pathogen that is responsible for a number of clinical manifestations [1]. Treatment remains challenging to manage due to the emergence of multidrug resistant strain [2]. The enormous resistant strains of microorganisms have called for the continuous development of antimicrobials from the natural source.

Mushrooms are macro-fungi with a distinctive fruiting body, which can be hypogeous or epigeous, large enough to be seen with the naked eye, and can be picked by hand. Mushrooms have long been used as a valuable food source and as traditional medicines in Japan and China and many parts of the world. A series of species of mushrooms are classified as poisonous and hazardous to health because they contain toxic substances. Toxic substances are also found in some mushroom species with useful properties [3]. Many medicinal mushrooms have potential benefits ranging from supporting immune function to aiding in weight loss. Some species of mushrooms have health-promoting properties such as antioxidant, antimicrobial, anticancer, cholesterol-lowering and immunostimulatory effects [4].

Oyster mushroom is scientifically referred to as *Pleurotus ostreatus*. It is a macro-fungus of family basidiomycetes and globally consumed as food and drugs. It is very rich in protein thereby served as supplements in low-income countries and has been found to contain vitamins B1 (thiamin), B2 (riboflavin), B5 (niacin), B6 (pyridoxine, and B7 (biotin) [5]. The fruiting body of the mushroom is a potential source of lignin and phenol degrading enzymes. *Pleurotus* have been found with effective anti-microbial activity against simple and multiple drug-resistant isolates of *Escherichia coli*, *Staphylococcus epidermidis* and *S. aureus* [6]. In Nigeria *P. ostreatus* is used in traditional medicine and among the edible mushrooms largely consumed as a spice in vegetable soups and also fried to serve as meat. The mushroom is cultivated for food and industrial purposes worldwide. Currently, mushroom extracts are recommended as dietary supplements to enhance immune function and antitumor activity [7].

The health enhancing properties of most mushrooms are attributed to the secondary metabolites inherent in them which function as biological response modifiers (BRM). Biological response modifiers are substances that stimulate the body's response to infection and disease [8]. The body is known to produce these substances but not in appreciable quantity hence, exogenous supply through diet or dietary supplements are needed. In an attempt to search for antimicrobials of minimal or no toxicity to vital organs mushrooms cannot be overlooked because of their great diversity.

The change in the weight of an internal organ can be used in interpreting the opinion regarding the cause of death during an autopsy. The increase in the weight of an internal organ can be determined when the weight of test organ is compared with the reference / normal control. It is required to describe and recognize if there is pathological lesion [9]. Changes in the weight of an internal organ may be the only evidence to show that an organ is not normal. An elevated weight of the heart is an evidence of myocardial hypertrophy (abnormal enlargement or thickening of the heart muscle) [10] that macroscopically and microscopically might be difficult to recognize. In an increased pulmonary resistance, the right ventricle of the heart may enlarge due to the increase in the pressure required to pump blood through the pulmonary circulation. Similarly, changes in kidney weight may reflect renal toxicity, tubular hypertrophy, or chronic progressive nephropathy. In clinical medicine

any deviation from the normal weight of an internal organ would be indicative of pathology to that organ or a compensatory mechanism in response to applied stress to an organ. This study is designed to determine the effect of *P. ostreatus* extract on the liver, heart, spleen, lungs and kidneys of *Staphylococcus aureus* -infected Wistar rats.

2. MATERIAL AND METHODS

2.1 Source of test organisms

Clinical isolate of *Staphylococcus aureus* was obtained from the Federal Medical Centre, Owo. The bacterial species was isolated from a wound culture, identified and confirmed using standard biochemical tests. It was characterized as Gram positive cocci in clusters, positive for catalase and coagulase test.

2.2 Processing of mushroom extract used for the studies

Healthy and mature fresh oyster mushrooms were from a mushroom field located in Osogbo, Osun State, Nigeria. The mushroom was transported in labeled cellophane bags within six hours of the collection into the medical microbiology laboratory, identified, and confirmed by molecular analysis as *Pleurotus ostreatus* [11]. The mushroom was clean by removing dirt and cut with a sterile surgical blade into small diameters, then dried at ambient temperature for two weeks. The pieces were turned every 24 h, until perfectly dry and ground into a fine powder; processed using the cold extraction method. The mushroom powder was soaked in a 2 L glass beaker using 99 % ethanol as the extracting solvent. The beaker mouth was corked using clean foil paper, and the mixture was continually agitated every hour. After 72 h the mushroom ethanol mixture was stirred and filtered using a clean muslin cloth. The filtrate was concentrated *in vacuo* using a rotary evaporator and evaporated to dryness at 40 ° C. The crude extract was labelled and preserved at 4°C inside a refrigerator until use.

2.3 Preparation of Experimental animals

Apparently healthy white Wistar albino rats of 82.0 g- 92.2 g body weight were obtained from various sellers in Osogbo, Osun State. They were housed in plastic cage, fed with commercial feed pellets once in a day and clean drinking water. The room temperature was maintained between 28 and 32 °C with 12 h light and 12 h darkness. The bedding, feeding trough and utensils, and the environment was maintained clean on daily basis. The animals were handled with care according to the National Institute of Health (NIH) animal care guidelines [12]. The Wistar rats were distributed into 6 groups of 5 and allowed to acclimatize in 7 days before the experiment commences. Each animal was inoculated orally with a 0.3 ml *S. aureus* suspension of standard inoculums equivalent to 0.5 Mc Farland standard (1×10^6 Cfu/ml), were allowed to be in the system for 3 days watching for signs of infection.

2.4 Administration of the mushroom extract

A graded dose of the extract, 625 mg/kg, 1250 mg/kg and 2500 mg/kg was administered for 7 days. Graded dose of extract administered was determined using $LD_{50} > 5000$ mg/kg. The mushroom extract was weighed with the aid of a sensitive weighing balance and stock solution was prepared inside a clean conical flask using clean distilled water, and passed through 0.45 mm diameter membrane filter, prior to use. Individual dosages were prepared according to body weight and administered appropriately through oral route with the aid of the feeding trough. Appearance, behavior, body weight, gross examination of organs and organ weight and rectal temperature were recorded daily and weekly after 7 days administration of extract.

2.5 Microbiological Blood Culture

Colony count of blood cultured directly on solid medium was performed on the fresh blood sample obtained from the Wistar rats after seven days post treatment with the mushroom

extract. Blood was collected from the heart under aseptic condition, and inoculated into cooled sterile peptone water at ratio 1:10 dilution. Serial dilution (10^{-1} to 10^{-4}) of one volume of cultured broth was prepared immediately in a set of sterile test-tubes. Under aseptic condition 100 μ l diluted blood was mixed with 10 ml, 45 °C cooled molten Manitol salt agar, gently mixed, and allowed to set. The plates were incubated at 37 °C and examined for bacterial growth every 24 h for 72 h. Along with the direct colony count, the remaining portion of the cultured broth was also incubated at 37 °C for 72 hr. It was sub-cultured on Manitol salt agar and cultured plates were placed in the incubator at 37 °C for 24 h. The tests were set up in triplicates. After 24 h all the plates were examined and plates with bacterial growth were subjected to gram staining and biochemical reactions [13]. The bacterial (*Staphylococcus aureus*) colonies were counted and recorded.

2.6 Gross Pathological Evaluation of the Vital Organs

The animals were starved for 12 hours and sacrificed by cervical dislocation method. The kidney, liver, heart, lungs, spleen and skin were excised and examined fresh for pathological changes. The organs were then preserved in 10 % formaldehyde buffered saline. Histopathological analysis was carried out as described by Ochei and Kolhatkar [14]. The tissues were fixed in formol saline to prevent putrefaction and post mortem changes. Paraffin sections were prepared from the fixed tissues and sections cut with the microtome from the paraffin wax block. The cut sections were floated out in warm water, mounted on clean microscope slides, dried and stained with Hematoxylin and Eosin (H&E) [14]. The stained sections were mounted in a good mountant under a cover glass and labeled appropriately. The stained sections were observed under the microscope, at x400 magnification. The relationship between the mean organ and mean body weight of Wistar rats after seven days administration of extract from *P. ostreatus* spp. was evaluated and recorded.

2.7 Statistical analysis of data

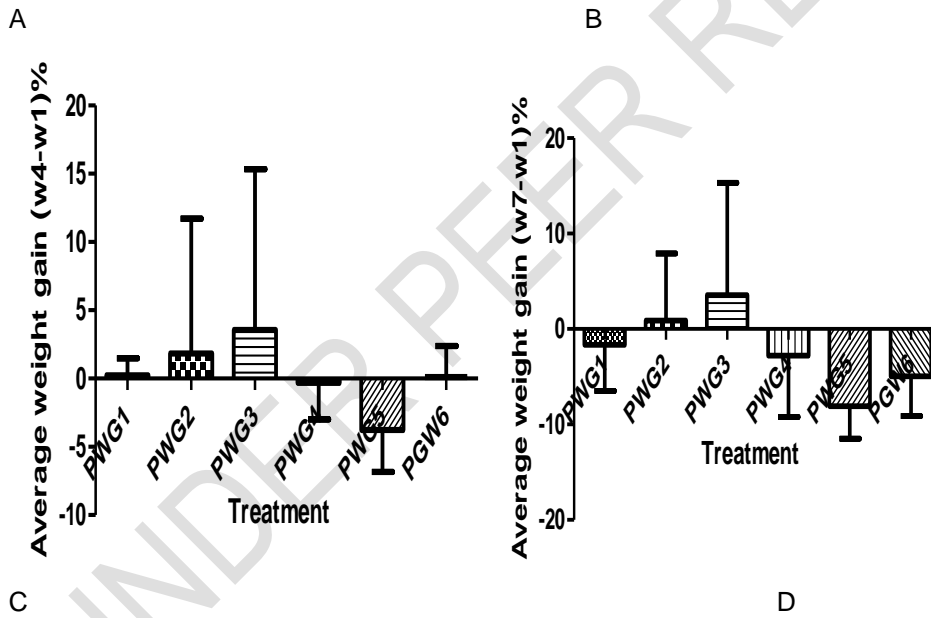
The results of five replicates were pooled and expressed as mean \pm standard deviation (SD). Data obtained were subjected to one-way analysis of variance (ANOVA), and treatment means were compared using Turkey's Multiple Comparison test with the GraphPad prism 5 at 99%, $P < 0.01$ level of significance. The correlation of the relative organ weight, observation from organs grossly examined the pathological changes in the tissues and safe administration of *P. ostreatus* extract were determined.

3. RESULTS

All the groups experienced weight loss during the incubation period till the fourth day of administering the antimicrobial. (Figure 2 A and 2 B). A significant average weight gain and loss were observed in the negative control and the 1250 mg dose $P < 0.01$ after seven days of administration of the antimicrobial ((Figure 2 C). Figure 2 D showed no statistical variation in the average weight gain after seven days post-administration of the antimicrobial. The *S. aureus*-inoculated rats demonstrated no statistically significant variation in the mean body weight. A significantly raised colony count was observed in the negative control and 625 mg dose, after 7 days post-administration of the extract $P < 0.01$ (Figure 1 A and 1 B). In figure 2C, both the treatments and controls showed no growth after 48 h of incubation at 37 °C, but scanty growth of statistical significance was observed in the normal control, 1250 mg and 2500 mg after 72 h of incubation at 37 °C. The negative control produced the highest colony count, followed by the 625 mg and the positive control in descending order $P < 0.01$. Figure 3 demonstrated the relative organ body ratio, with no significant variation at a 99 % confidence interval.

Plates 2 to 4 showed the histological tissues of some vital organs, the heart, lungs, skin, and kidney. There were no observable signs of toxicity during the gross examination and no anatomical variations compared with the normal control tissues. However, Plate 1 showed

some vacuolations in both the negative control and the liver treated with 625 mg dose extract.



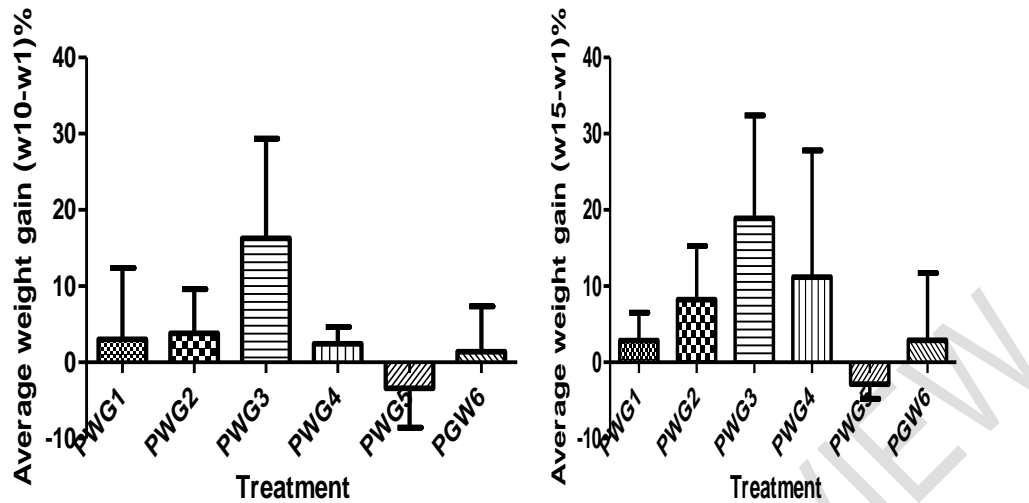


Figure 1. Mean body weight gain before and during administration, and after 7 days post-administration of *P. ostreatus* to *S. aureus* infected Wistar rats

Legends:

Figure 1 shows the percentage weight gain of Wistar rats during the experiment in which BW1 was the normal control group (placebo), not inoculated, received only feed and drinking water; BW2 was the positive control, was inoculated and administered with standard antibiotics (Ciprofloxacin) for 7 days; WB3 was the negative control group, was inoculated but not administered with antibacterial agent; WB4 was inoculated and administered with 625 mg dose of extract for 7 days; WB5 was inoculated and administered with 1250 mg dose extract for 7 days; WB6 was inoculated and administered with 2500 mg dose extract.

1.1A: Weight gain before administration of extract. The percentage of the mean weight gained after 3 days of *S. aureus* incubation, (W4-W1) % is the difference between the body weight on day 4 and day 1 of the experiment. It shows no statistical difference at $P < 0.01$ significance.

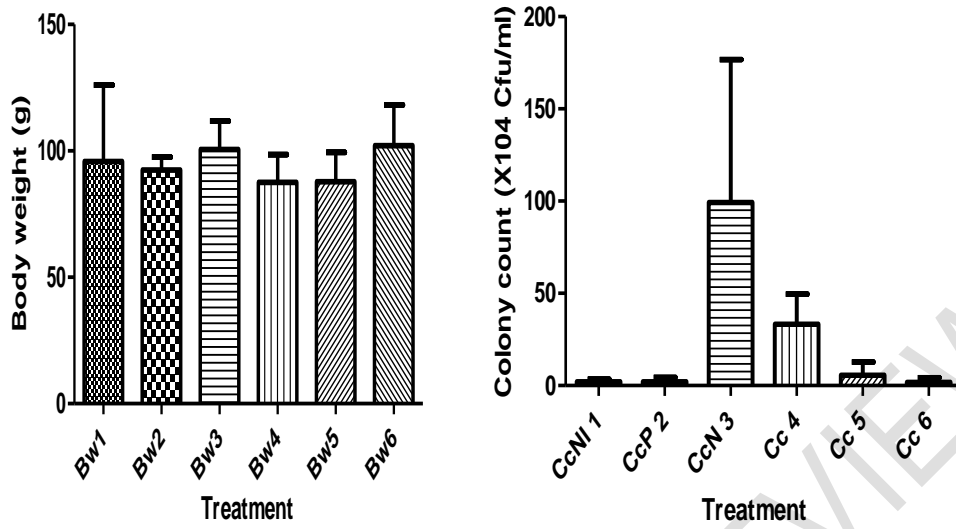
1.1B: Weight gain during administration of extract. The percentage weight gained after 4 days administration (W7- W1) % is the difference between the body weights on day 7 and day 1. It shows no significant statistical variation at $P < 0.01$.

1.1C: Weight gain after 7 days administration of extract. The percentage weight gained after 7 days administration (W10- W1) % is the difference between the body weights on day 10 and day 1. Weight gained in the negative control (WB3) was significantly raised compared with 1250mg dose (WB5) which was significantly reduced at $P < 0.01$.

1.1D: Weight gain after 7 days post-administration of extract (W15- W1) % is the difference between the body weights on day15 and day 1. It shows no significant change in weight as compared with controls at $P < 0.01$.

A

B



C

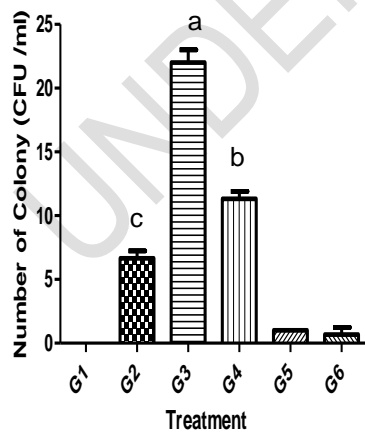
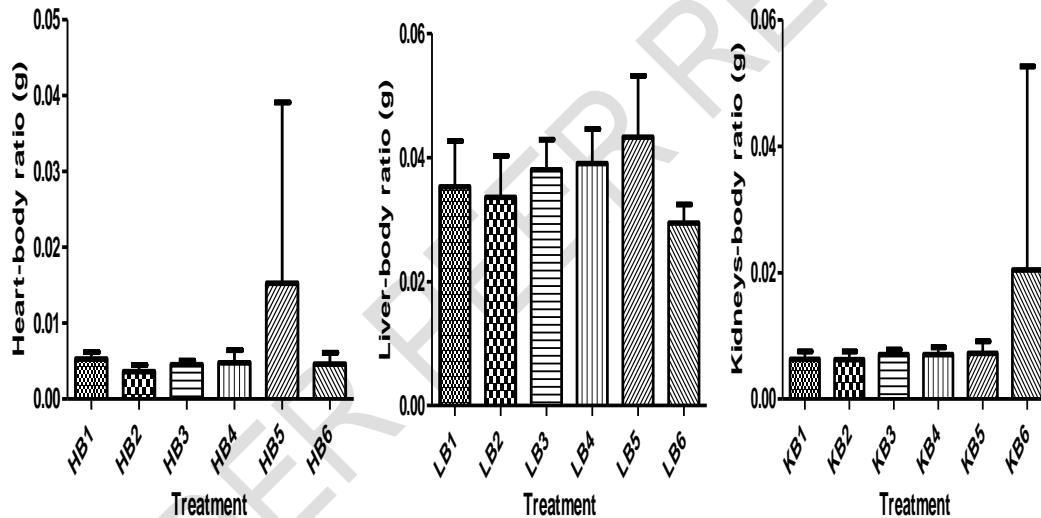


Figure 2: Mean body weight and average colony count after 7 days post-treatment of *S. aureus* infected Wistar rats

Figure 2A shows the mean body weight on the day the rats were sacrificed, with Bw1: normal control (placebo); Bw 2: positive control, inoculated and administered with standard antibiotics; Bw3: negative control, inoculated but received no antimicrobial; Bw4: inoculated and administered with 625 mg dose; Bw5: inoculated and administered with 1250 mg dose and Bw 6: inoculated and administered with 2500 mg dose. It shows no significant statistical difference at $P < 0.01$ level.

Figure 2B shows the mean colony count of *S. aureus* in blood culture after 7 days post-administration of oyster mushroom extract, in which CcNI 1: normal control (placebo); CcP 2: positive control; CcN 3: negative control; Cc 4: administered with 625 mg extract; Cc 5: administered with 1250 mg extract; Cc 6: administered with 2500 mg extract. It shows significant statistical difference between CcN 3 and Cc 5 and Cc 6; no significant statistical variation between CcNI 1, CcP 2, Cc 5 and Cc 6; and no significant statistical variation between CcN 3 and Cc 4 at $P < 0.01$.

Figure 2C demonstrated colony count within 72 h of incubation on solid media. Each point represent the mean value and standard deviation at $P < 0.01$ significance. G1= normal control, G2= positive control, G3= negative control, G4=625 mg, G5= 1250 mg, and G6 =2500 mg treatment; a, b and c are significant variations at $P < 0.01$; $n = 3$.



D

E

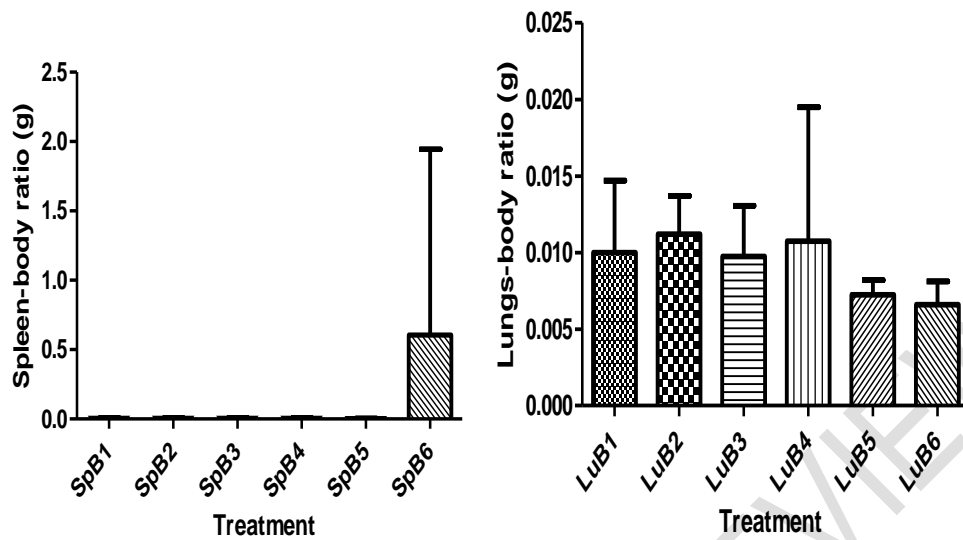


Figure 3: Mean body weight and relative organ weight ratio of Wistar rats after seven days post administration of *P. ostreatus*

Figure 3 shows relative organ weight ratio in Wistar rats after seven days post administration of *P. ostreatus*. Mean value of organ weight relative to the mean value of the body weight on the day the rats were sacrificed. Each point represent the mean value and standard deviation at $P < 0.01$ significance. A is the heart- body weight ratio where HB1 = normal control heart; HB2 = positive control heart; HB3= negative control heart; HB4= 625 mg heart; HB5= 1250 mg heart; and HB6= 2500 mg heart. It shows no significant statistical variation at $P < 0.01$. B is the liver- body weight ratio where LB1 = normal control liver; LB2 = positive control liver; LB3= negative control liver; LB4= 625 mg liver; LB5= 1250 mg liver; and LB6= 2500 mg liver. It shows no significant statistical variation at $P < 0.01$. C was the kidneys- body weight ratio where the two kidneys were considered as a unit; KB1 = normal control kidney; KB2 = positive control kidney; KB3= negative control kidney; KB4= 625 mg kidney; KB5= 1250 mg kidney; and KB6= 2500 mg kidney. It shows no significant statistical variation at $P < 0.01$. D was the spleen- body weight ratio where SpB1 = normal control spleen; SpB2 = positive control spleen; SpB3= negative control spleen; SpB4= 625 mg spleen; SpB5= 1250 mg spleen; and SpB6= 2500 mg spleen. It shows no significant statistical variation at $P < 0.01$. E was the lungs- body weight ratio where LuB1 = normal control lungs; LuB2 = positive control lungs; LuB3= negative control lungs; LuB4= 625 mg lungs; LuB5= 1250 mg lungs; and LuB6= 2500 mg lungs. There was no significant statistical variation in the relative organ weight at $P < 0.01$.

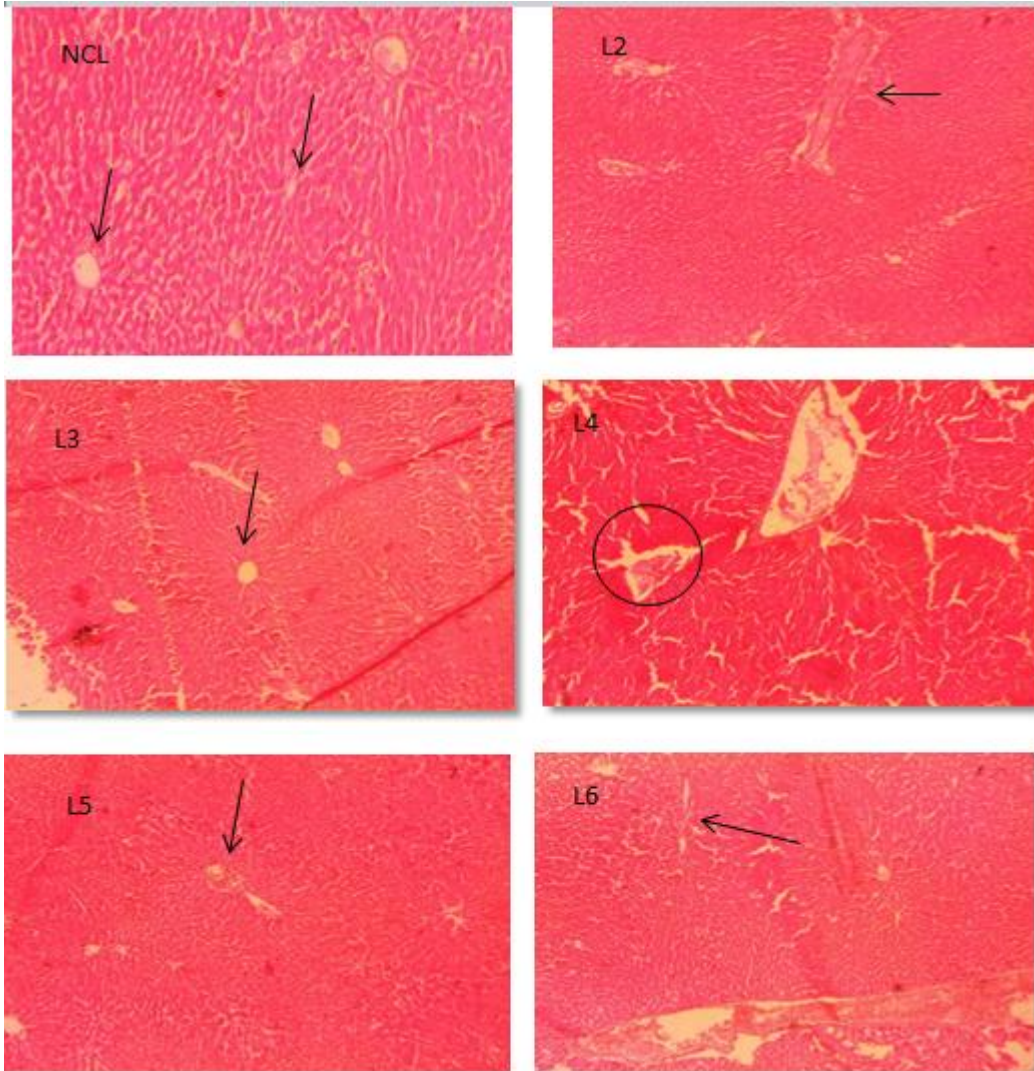


Plate 1: Photomicrograph of normal liver tissue showing central arteriole (arrow) clearly demonstrated in NCL (normal control), L2, L3; L5 and L6; and some vacuoles in L4 $\times 400$
Key: L2= positive control, L3= negative control, L4= treatment with 625 mg dose, L5 = treatment with 1250 mg dose, and L6 = treatment with 2500 mg dose of the extract

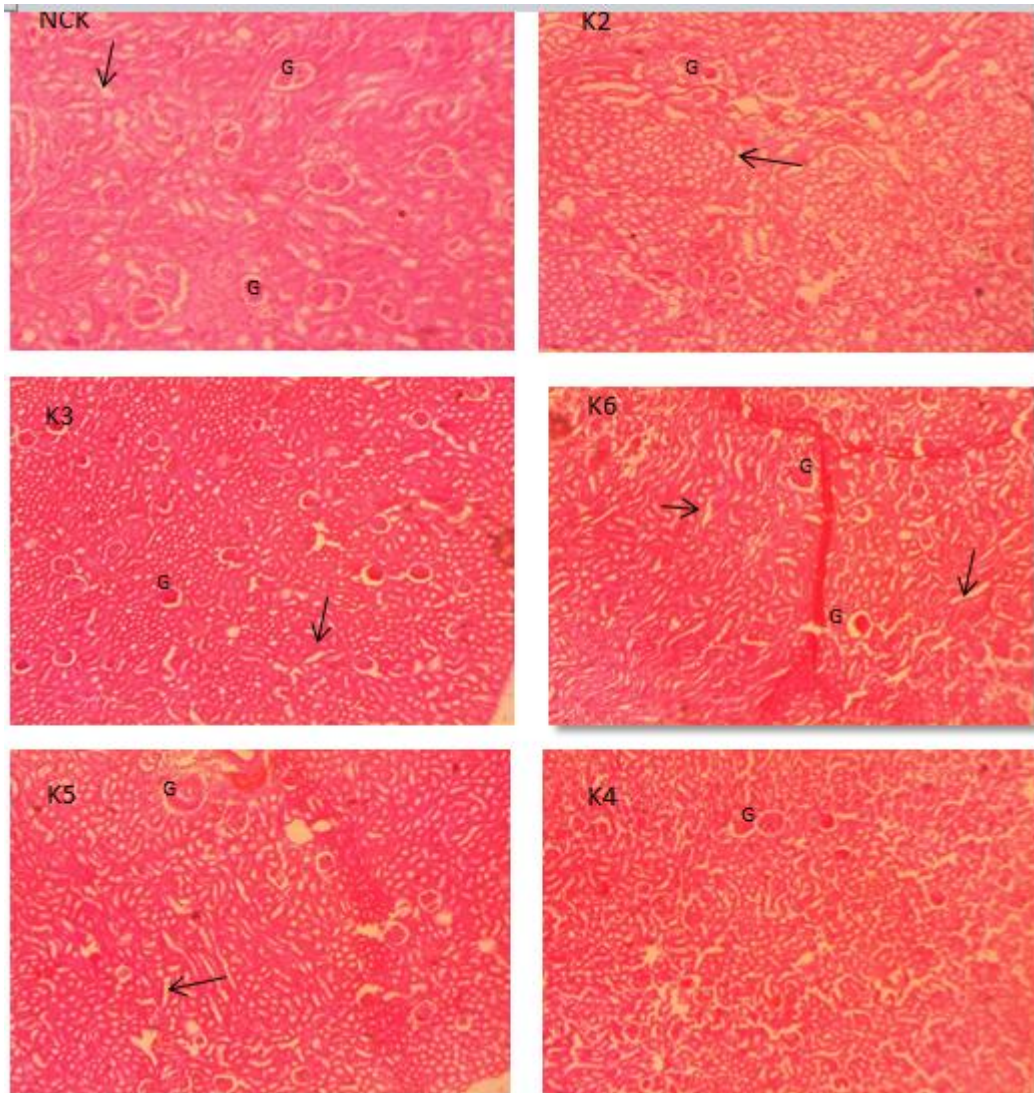


Plate 2: Photomicrograph of kidney sections showing some glomerulus well preserved (G) and convoluted tubules (arrow) in normal control kidney (NCK), K2: K3; K4; K5 and K6 × 400

Key: K2= positive control, K3= negative control, K4= treatment with 625 mg/kg extract, K5 = treatment with 1250 mg/kg extract and K6 = treatment with 2500 mg/kg extract

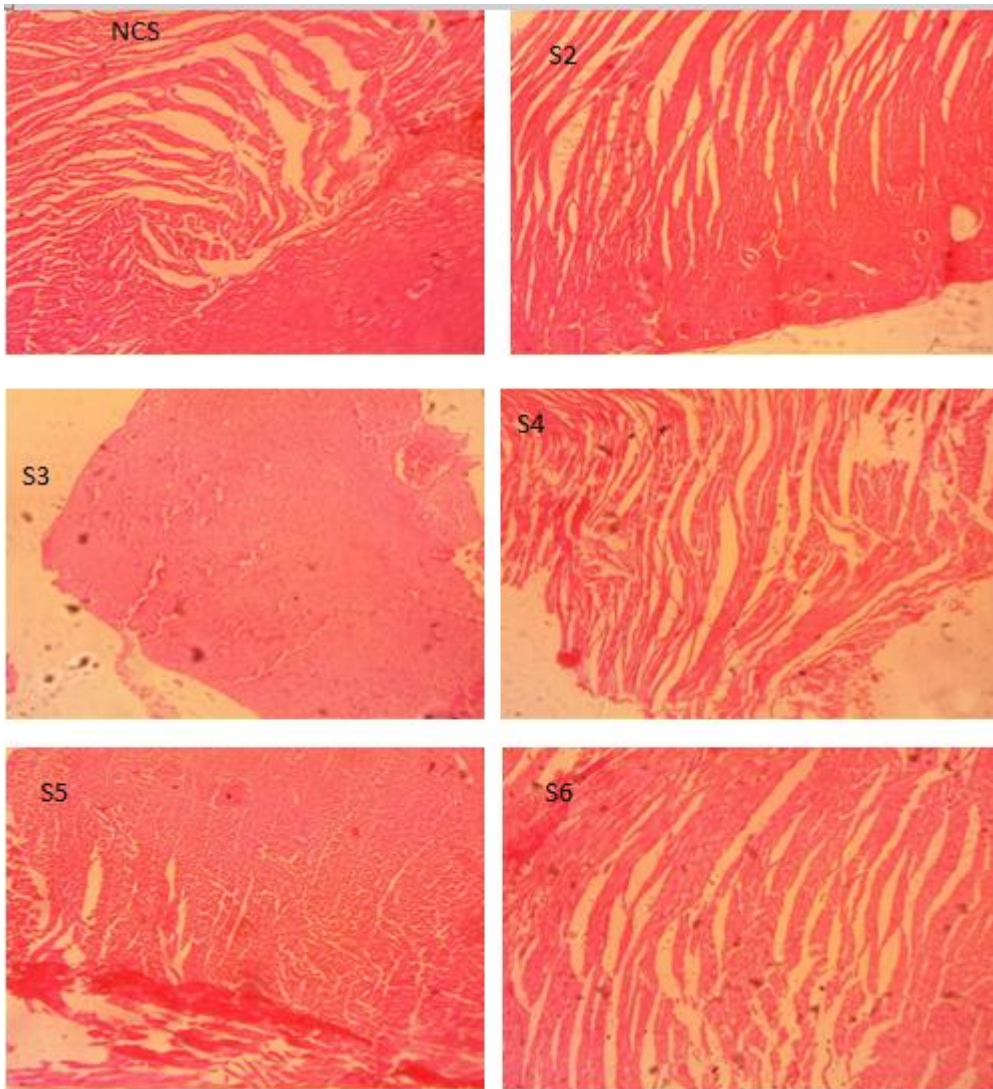


Plate 3: Photomicrograph of skin tissues, sections showing normal skin tissue in normal control (NCS), positive control (S2), negative control (S3), treatment with 625 mg (S4), 1250 mg (S5) and 2500 mg (S6) dose of the extract x 400

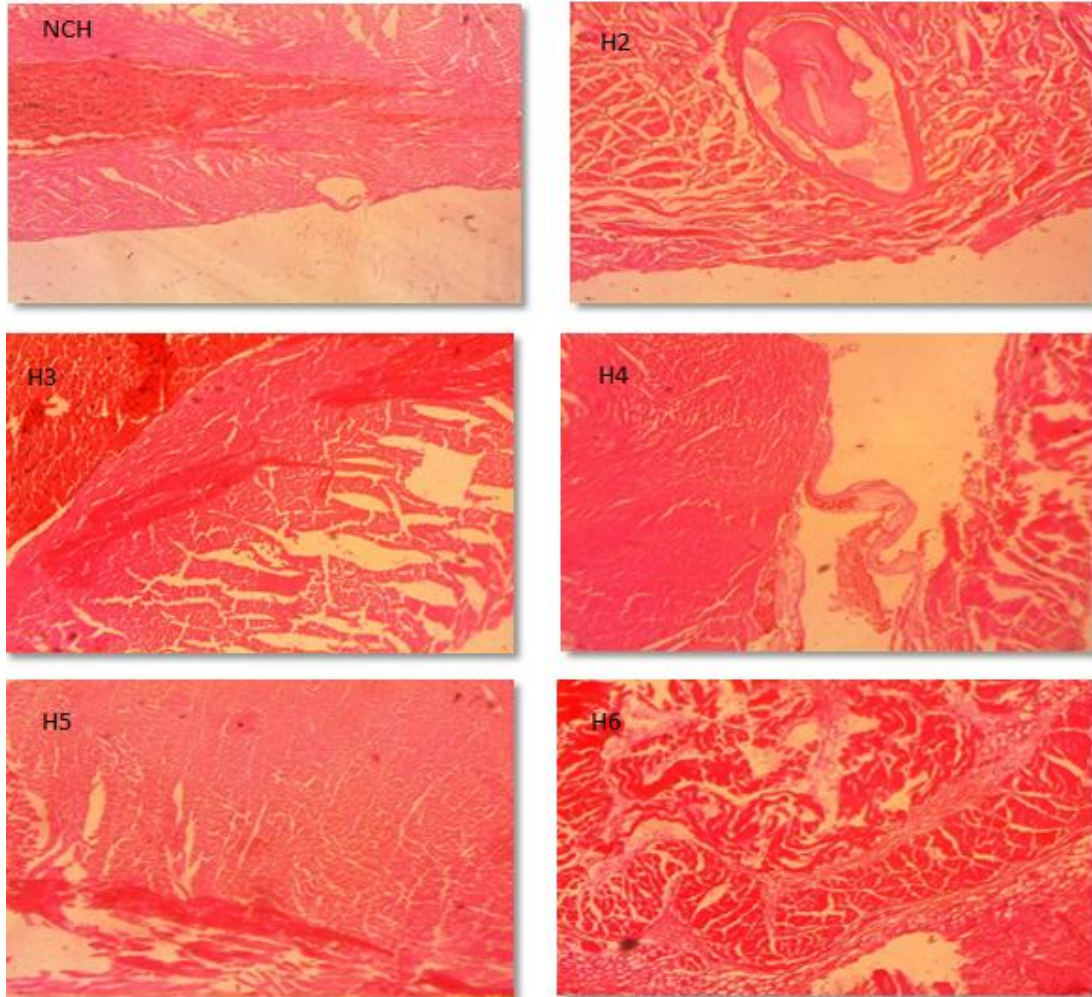


Plate 4: Photomicrograph of heart tissue sections showing normal features in normal control (NCH), positive control (H2), negative control (H3), 625 mg (H4), 1250 mg (H5) and 2500 mg mushroom extract (H6) × 400

4. DISCUSSION

Mushrooms are macro-fungi and have long been used as protein supplements and traditional medicines in some countries including Nigeria. The active ingredients in Oyster mushrooms could be responsible for the weight loss initially observed in the treatment. A 625 mg dose might not contain enough bactericidal agents that could produce a cure from the pathogen. However, the dose ranging from 1250 to 2500 mg body was potent against *Staphylococcus aureus* infection, this might be attributed to the bioactive compounds (phenolic and flavonoids) inherent in the mushrooms as reported by some researchers [15, 16]

The least weight gain in the treatment is similar to the work of Chang *et al.* [17, 18]; Delzenne and Bindels, [19]; Murphy *et al.* [20] who reported the activity of *Pleuroteus* sp. in the gut which consequently leads to a reduction in inflammation and weight gain. Fard *et al.* [21] also reported lower body weight in chickens fed with mushroom supplements.

P. ostreatus produced no clinical signs of toxicity on the heart, spleen, skin, lungs, liver, and kidneys, it correlates the findings of Zhu et al. [22] and Liwei et al.[24] who reported the hepatoprotective activity of *P. ostreatus*. On the contrary, some pathological changes observed in 625 mg liver could result from the under dose that might be too insignificant to produce a cure [24]. These findings agree with the report of Fakoya [25] that *P. ostreatus* produced no toxic effect on the liver and kidneys of animals fed with *P. ostreatus* supplement.

5. CONCLUSION AND RECOMMENDATION

The histological investigations are suggestive of safety and tolerance of *P. ostreatus* to the body system. *P. ostreatus* at 1250 to 2500 mg/kg dose is potent against pathogenic staph infection and has no observable ill effect on the vital organs, the lungs, kidney, liver, spleen, and heart. This information could be useful in the production of new antimicrobials of commercial value which will be less toxic to the body system.

ETHICAL APPROVAL

All of the animals used in this study received humane care according to the criteria outlined in the Guide for the Care and the Use of Laboratory Animals prepared by the National Academy Science and published by the National Institute of Health (USA). The ethic regulations have been followed in accordance with national and institutional guidelines for the protection of animals' welfare during experiments.

REFERENCES

- 1 Rasigade JP, Vandenesch F,. Staphylococcus aureus: a pathogen with still unresolved issues. Infect. Genet Evol. 2014.; 21, 510-4.
- 2 Chambers HF. Community-associated MRSA- resistance and virulence converge. N Engl J Med. 2005; 352 (14): 1485-7
- 3 Sergy G, Ramin R, Josef D, Aristidis T. Poisoning associated with the use of mushrooms: A review of the global pattern and main characteristics *Food and Chemical Toxicology* 2019; 128:267-279. doi: 10.1016/j.fct.2019.04.016.
- 4 Chang ST, Wasser SP. The role of culinary-medicinal mushrooms on human welfare with a pyramid model for human health, *International Journal of Medicinal Mushrooms*. 2012; 14 (2): 95–134.
- 5 Deepalakshmi K, Mirunalini S. *Pleurotus ostreatus*: an oyster mushroom with nutritional and medicinal properties. *Journal of Biochemical Technology*. 2014; 5 (2):718-726
- 6 Akyuz M, Onganer AN, Erecevit P. Kirbag S. Antimicrobial activity of some edible mushrooms in the Eastern and Southeast Anatolia region of Turkey *GU Journal of Science*. 2010; 23 (2):125-130
- 7 Valverde ME, Hernandez-Perez T, Paredes-Lopez O. Review Article Edible mushrooms: improving human health and promoting quality life *International Journal of Microbiology*. 2015; 14. <https://doi.org/10.1155/2015/376387>.
- 8 Nisar J, Mustafa I, Anwar H, Sohail MU, Hussain G, Ullah MI, Faisal MN, Bukhari SA, Basit A. Shiitake culinary-medicinal mushroom, *Lentinus edodes* (Agaricomycetes): A species with antioxidant, immunomodulatory, and hepatoprotective activities in hypercholesterolemic rats. *International Journal of Medicinal Mushrooms*. 2017; 19 (11): 981–990.
- 9 Mubbunu L, Bowa K, Petrenko V, Silitongo M. Correlation of internal organ weights with body weight and body height in normal adult Zambians: A case study of Ndola Teaching Hospital Anatomy. *Research International*. 2018; 5.

- 10 Samak M, Fatullayev J, Sabashnikov A, Zerriouh M, Schmack B, Farag M, Popov AF, Dohmen PM, Choi YH, Wahlers T, Weymann A. Cardiac hypertrophy: An introduction to molecular and cellular basis. *Medical Science Monitor Basic Research*. 2019; 22: 75–79.
- 11 Oyekanmi BA, Onifade AK, Osho IB, Adetuyi FC. Haematological and biochemical properties of *Pleurotus ostreatus* mushroom species. *Nigerian Journal of Mycology*. 2019; 11:102- 114.
- 12 National Res Council (US) Committee for the update for the care and use of Laboratory Animals National Academies Press (US) 2011 Google Scholar
- 13 Cheesebrough M. *District Laboratory Practice in Tropical Countries Part 2* Cambridge University press 2000; p 434.
- 14 Ochei J, Kolhatkar A. *Medical Laboratory Science Theory and Practice* Tata Mcgraw-Hill Publishing Company Limited: New Delhi. Sixth Reprint, p. 1338. 2007.
- 15 Oyekanmi BA, Onifade AK, Osho IB, Adetuyi FC. Assessment of antimicrobial properties and bioactive agents inherent in *P. ostreatus*. *Nigerian Journal of Mycology*. 2019; 11: 129- 144.
- 16 Pingla S, Anjali K, Deepali NKC, and Shailesh KJ. Nutrients and Bioactive compounds of *Pleurotus ostreatus* mushroom. *NewBioWorld A Journal of Alumni Association of Biotechnology* 2021; 3(2): 8-12
- 17 Chang CJ, Lin CS, Lu CC, Martel J, Ko YF, Ojcius DM, Tseng SF, Wu TR, Chen YY, Young JD, Lai HC. *Ganoderma lucidum* reduces obesity in mice by modulating the composition of the gut microbiota. *Nature Communications*. 2015;6:7489. <http://dx.doi.org/10.1038/ncomms8489>.
- 18 Fang Q, Lai Y, Zhang D. Gut microbiota regulation and prebiotic properties of polysaccharides from *Oudemansiella raphanipes* mushroom. *World Journal of Microbiology and Biotechnology* 2023; 39: 167. <https://doi.org/10.1007/s11274-023-03616-1>
- 19 Delzenne NM, Bindels LB. Gut microbiota: *Ganoderma lucidum*, a new prebiotic agent to treat obesity? *Nature Reviews Gastroenterology&Hepatology*. 2015; 12: 553–554. <http://dx.doi.org/10.1038/nrgastro.2015.137>.
- 20 Murphy EA, Velazquez KT, Herbert KM. Influence of high-fat diet on gut microbiota: A driving force for chronic disease risk. *Current Opinion in Clinical Nutrition and Metabolism Care*. 2015; 18: 515–520.
- 21 Fard SH, Toghyani M, Tabeidian SA. Effect of oyster mushroom wastes on performance, immune responses and intestinal morphology of broiler chickens. *International Journal of Recycling of Organic Waste in Agriculture*. 2014; 3: 141.
- 22 Zhu B, Li YZ, Hu T, Zhang Y. The hepatoprotective effect of polysaccharides from *Pleurotus ostreatus* on carbon tetrachloride-induced acute liver injury rats. *International Journal of Biological Macromolecules* 2019; 131: 1–9.
- 23 Liwei Z, Yuxiao L, Xiaobin F, Qinghong L, Yuanhui L, Jiamin H, Yankiong W, Yongqiang D, Huimin DW. Hepatoprotective Effects of *Pleurotus ostreatus* Protein Hydrolysates Yielded by Pepsin Hydrolysis. *Catalysts* 2020, 10(6), 595; <https://doi.org/10.3390/catal10060595>
- 24 Kalam S, Gul MZ, Singh R, Ankati S. Free radicals: Implications in etiology of chronic diseases and their amelioration through nutraceuticals. *Pharmacologia*, 2015; 6: 11-20.
- 25 Fakoya S. Bio-safety quality and nutritional status of *Pleurotus ostreatus* cultivated on sawdust of two selected tropical trees. *Research Journal of Environmental Toxicology*. 2011; 5 (6): 378-384

UNDER PEER REVIEW