

Determination of Gender Variations Based on Anatomical Shapes of the Orbit on Plain Radiographs

ABSTRACT

Introduction: Cephalometry has been widely used in substantial aspects of medicine. There exist obvious differences between male and female bony features from early development to adulthood. The morphometric assessment of the orbit and familiarity with its anatomy is significant clinically in the diagnosis of lesions in the orbit and reconstructive surgeries of the face. There is an important link between diagnostic radiology and ophthalmology. Most previous studies use direct techniques on living, cadaveric specimens, or dry bones to assess the orbital dimensions.

Aim: To determine the gender variations based on the shapes of the orbit using Plain Radiographs

Materials and Methods: A 5-year retrospective cross-sectional study using 255 normal skull radiographs obtained from the Department of Diagnostic Radiology of Usmanu Danfodiyo University Teaching Hospital Sokoto from 2004 to 2009 was carried out with male to female ratio of 4:1. The radiographs were mounted on a viewing box, and the orbital shapes were noted.

Results: In the male subjects, the shape of the orbit was oval in 68 (33.0%), quadrangular in 55 (26.7%), and round in 83 (40.3). In the female subjects, the oval-shaped orbit was found in 27 (55.1%), quadrangular shape in 12 (24.5%), and in round shape 10 (20.4%).

Conclusions: The commonest type of orbit seen in males is the round type, followed by the oval type with the quadrangular being the least type. While in females the predominant type of orbit seen was oval, followed by the quadrangular type, with the round type being the least common. Although, the differences were not statistically significant. The round type of orbit shows the strongest tendency in sex identification.

Keywords: *Orbit, Cephalometry, Shapes, Morphometric, Radiographs*

INTRODUCTION

Anthropometry is defined by the Centre for Anthropometry Studies in Australia (CAA) as a science that relates to the measurement of body dimensions.

Cephalometry is a branch of anthropometry that describes measurements of head and face in cadaveric, living, or radiological specimens. This aspect of physical anthropology has been widely used in a substantial aspect of medicine (Umar and Shugaba, 2005). Attempts to establish reliable cephalometric differentiation between races are as old as craniometry itself and although the mandible and cranial capacity are in this connection less dependable, satisfactory characterization has been established for some racial groups and especially for Caucasians and Negroes, it has been utilized to classify people according to race, criminal temperament, intelligence, etc. (Westcott and Jantz, 1999).

Forensic anthropologists believe that by taking some 90 measurements of a skull they can correctly assign its owner's continent of origin – broadly speaking, its race, though many anthropologists prefer not to use the term craniometry – with 80 percent accuracy (Wade, 2002).

The orbital margin has the form of a quadrilateral with rounded corners. The relationship between the orbital height and width is given by the *orbital index*, which varies in the different races of mankind (Williams *et al.*, 1999).

Taking the orbital index as the standard, three classes of the orbit are recognized by taking the measurement at the orbital margin. The large (Megaseme) is seen mostly in yellow races usually with round orbital openings, the medium (Mesoseme) is seen mostly in the White races, and the small (Microseme) is seen mostly in black races with usually rectangular orbital openings.

The orbital opening is directed forward and slightly laterally and is tilted so that the upper and lower margins slope gently downwards from the medial to the lateral side. The orbital margin is made up of three bones: the frontal, zygomatic, and maxilla.

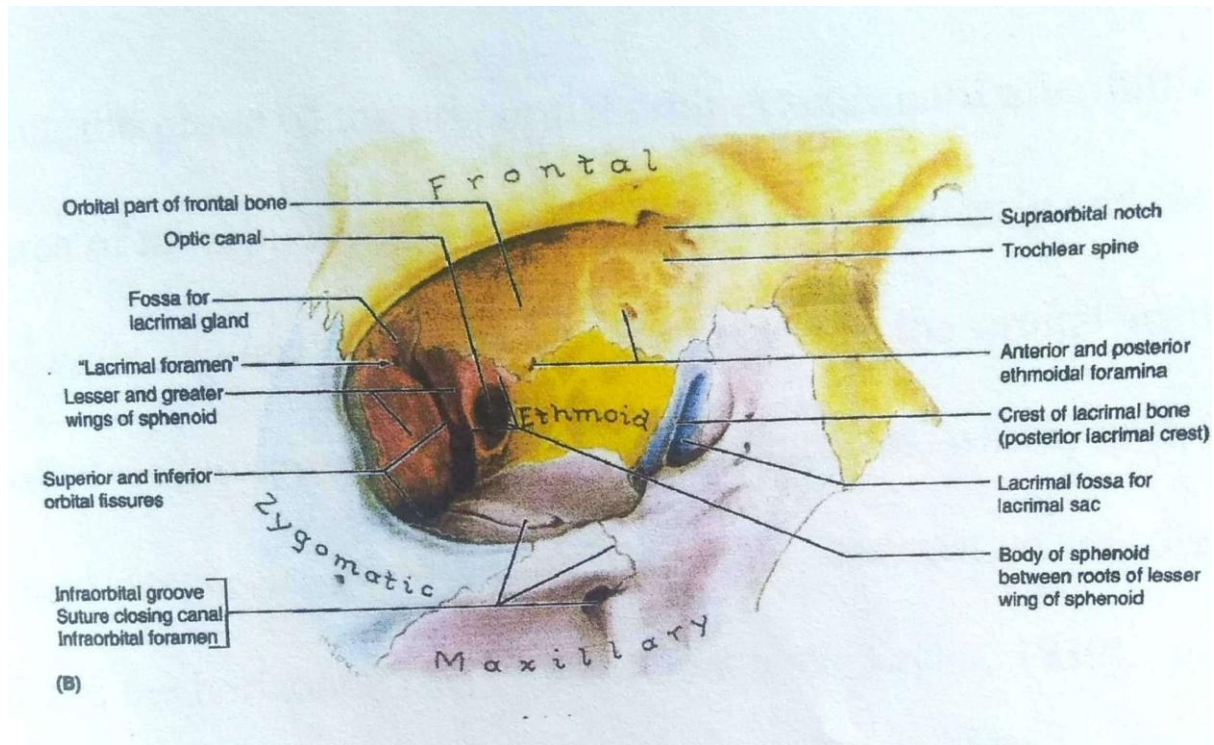


Figure 1: Anterior View of the Orbit showing its parts.

(Adopted from Keith L. Moore's Textbook of Clinically Oriented Anatomy)

The morphometric assessment of the orbit by radiography and familiarity with its anatomy is significant clinically in knowing how to diagnose and tackle subtle orbital bony injuries, subtle lesions of retro-orbital space and the orbital muscles, and reconstructive surgeries. It is also relevant in diagnosing disease states of the orbit in case of space-occupying lesions especially those causing proptosis, edema of the soft tissue, and/or hemorrhage. This shows an important link between diagnostic radiology and ophthalmology. Most of the previous work was done on Caucasian (Karakas *et al.*, 2002), Asian subjects (Lloyd and Glynn, 1973), and a few Africans in Nigeria (Umar and Shugaba, 2005) and were mostly done via invasive/direct techniques of measurement on living (Umar and Shugaba, 2005) and cadaver or dry skull bones (Karakas *et al.*, 2002). The research provided findings on different shapes of the orbits using radiographic methods in Nigerian subjects.

MATERIALS AND METHODS

This retrospective cross-sectional study of normal plain skull radiographs collected from the Radiology Department, Usmanu Danfodiyo University Sokoto was over a 5- year period

from September 2004 to September 2009. Selection of the radiographs for the study was based on clear visualization and recognition of orbital margins on both right and left sides and determination of a distinct lower orbital margin from the superimposition of the petrous part of the temporal bone which is usually forecasted there in the view.

All the radiographs were ascertained to have been taken by well-trained radiographers in a standardized condition and manner (target to film distance/film to focus distance TFD/FFD of 40 inches (100) cm of which only radiographs interpreted by well-trained radiologists were selected. The radiographs studied were of good quality and clarity of the anatomical features of the orbital shape was noted by direct visualization as either oval, round, or quadrangular.

Statistical Methods

The data was initially sorted out manually, tabulated, and then entered on a computer using Microsoft Word and Microsoft Excel.

INSTAT Statistical Package was used for the data analysis. Comparisons of mean values in relation to sex and age distribution of the subjects were done using Student's T-Test. Chi-Square (with Yates correction) was used for the comparison of proportions. Proportional percentages of orbital types based on orbital shapes observed were also analyzed.

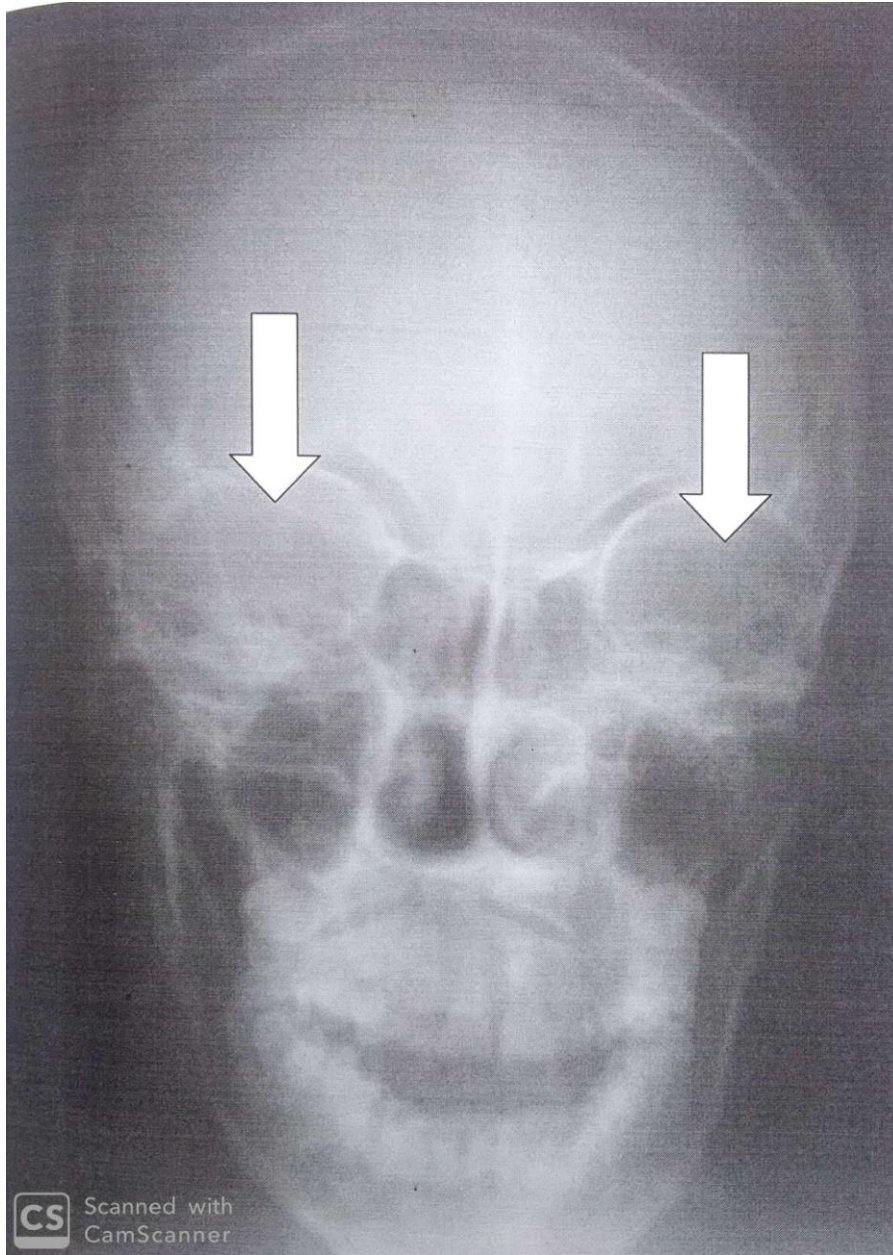


Figure 2: A posteroanterior view of a 31-year-old male skull radiographs with the white bold arrows pointing at the orbits.

Ethical consideration

Ethical clearance for the study was obtained from the Ethical Committee of the Radiology Department of Usmanu Danfodiyo University Teaching Hospital Sokoto, Nigeria.

RESULTS

Five hundred (500) radiographs of the skull were collected from the archives of the Radiology Department; Usmanu Danfodiyo University Teaching Hospital, Sokoto, for the study.

The radiographs were from subjects seen from September 2004 to September 2009. Out of this number, only 255 satisfied the inclusion criteria. The age range of the subjects for the study is between 1-70 years. Of this number, two hundred and six (206) were radiographs from males, and forty-nine (49) from females (m: f ratio = 4:1)

Mean and Standard Deviation of Orbital Dimensions in Relation to Gender

Parameter	MALE						FEMALE					
	Right			Left			Right			Left		
	Mean(mm)	S. D	SEM	Mean(mm)	S. D	SEM	Mean(mm)	S. D	SEM	Mean(mm)	S. D	SEM
Orbital Height	36.6	15.4	1.1	36.4	8.4	0.6	32.0	16.3	2.3	31.8	7.1	1.0
P Value	0.87						0.90					
Orbital Width	41.3	5.1	0.4	41.8	5.4	0.4	37.3	4.5	0.6	37.9	4.8	0.7
P Value	0.36						0.50					

Table 1: Mean and Standard Deviation of Orbital Dimensions in Relation to the Gender of the Subjects and between the Right and Left Sides of the Orbit.

Table 1 compares the mean orbital dimensions of the male and female subjects used for this study. The mean heights of the right and left orbits for the male are 36.6mm (SD=15.4) and 36.38mm (SD=8.4) respectively, while for the female are 32.0mm (SD=16.3) and 31.82mm (SD=7.2) on the right and left side. The p-value in the male is 0.8667 and 0.8970 in the female, that meaning there is no statistically significant difference in the orbital heights of both male and female compared to both right and left orbits.

The mean widths of the right and left orbits for the male subjects are 41.3mm (SD=5.1) and 41.8mm (SD=5.4) respectively and for the female 37.3mm (SD=4.5) for the right and 37.9mm (SD=4.8) for the left. The p values are 0.3557 for the male and 0.5005 for the female which indicates that there is no statistically significant difference in orbital widths in both male and female subjects.

The Various Anatomical Shapes of the Orbit and their relation to Sex

Shape of the Orbit	Male		Female	
	Frequency	Percentage (%)	Frequency	Percentage (%)
Oval	68	33.0	27	55.1
Quadrangular	55	26.7	12	24.5
Round	83	40.3	10	20.4
Total	206	100	49	100

$X = 8.5$; $df = 4$; $p < 0.05$

Table 2: The Various Anatomical Shapes of the Orbit and their relation to Gender

No significant statistical difference in comparison to other values at $p > 0.05$

The various anatomical shapes of the orbit seen in the study were as shown in Table 2. In the male subjects, the shape of the orbit was oval in 68(33.0%) of the subjects, quadrangular in 55(25.7%), and round in 83(40.3%) of the subjects. Thus, the most predominant shape of the orbit in the male subject was round then followed by oval, and then the quadrangular type with the least number of subjects. In the female subjects, the oval shape is more predominant 27(55.1%), then the quadrangular 12(24.5%), and the least round 10(20.4%).

DISCUSSION

Previous studies by Karakas *et al.*, 2002, Umar and Shugaba, 2005 and Lloyd and Glynn, 1973 on assessment of the orbital dimensions were done directly either on dry skulls or living beings or cadaveric bodies. Radiographic studies were also employed where plain radiographs were used as well as Ultrasonography, Digital Imaging, Conventional Tomographic Scans, Computed Tomographic Scans, Magnetic Resonance Imaging, Contrast Studies, and Colour Doppler. This current study assessed the dimension and normal variants of the anatomical features of the orbit from normal anteroposterior plain skull radiographs of subjects as was applied by Lloyd and Glyn in 1973.

The mean value of the orbital heights of all the subjects for the right and left orbits found in this study were 35.70 ± 8.37 on the right and 35.50 ± 8.05 on the left and the minimum range of

the heights was 19.00mm on the right and 18.00mm on the left. The maximum height was 58.00mm on the right and 68.00mm on the left. Thus, there is a slight increase in the range of the left orbital heights as compared to that of the right. However, the difference is not statistically significant.

The mean value of the orbital widths of all the subjects under study were 40.53 ± 5.23 on the right and 41.04 ± 5.53 on the left and the minimum range of values for the width was 26.00mm on both sides. The maximum ranges of the orbital widths were 54.00mm on the right and 55.00mm on the left virtually no difference between the two sides and no statistically significant difference of significance between the two sides.

The types of orbital shapes described on the posteroanterior radiographic view of the skull were oval and quadrangular (rectangular) as shown in the study by Lloyd, another third type (round) was observed during this study. It was found that the round type is more common in male subjects with 40.3% occurrence, and then followed by the oval type with 33.0%, and then the quadrangular being the least with 26.7%. In the female subjects, the oval shape is more predominant 27(55.1%), then the quadrangular 12(24.5%), and the least round 10(20.4%).

The mean orbital dimensions and the indexes of the skull radiographs of the male subjects were greater than those of the female counterparts. However, the differences observed were not proven to be significant statistically.

Conclusion

The male subjects tend to have larger dimensions than the female in all the parameters, but the difference is not statistically significant. The oval type of orbit is found to be more common in the first three decades of life but from the 4th to 6th decade the round type predominates, and all three different shapes are more common in the male subjects than in the females.

Limitations of the

Being this a retrospective study of plain skull radiographs, some personal biodata such as height, tribe, and religion could not be fully ascertained. The male subjects were more represented in the study as opposed to the female with a ratio of four to one (4:1).

Recommendations

It is essential to do more on Cephalometry of the orbit in Nigerian subjects or black of African descent on a larger scale to generate baseline data for reference. More studies can also be done to identify the likely differences in dimensions, size, and shape of the orbit that may exist between the diverse groups in Nigeria and other African countries. Comparative studies can be carried out to compare plain radiographic measurement of the orbit with studies using more modern equipment such as Computerized Tomography and Magnetic Resonance Imaging.

REFERENCES

1. Blodi, F.C (1975). Developmental anomalies of the skull affecting the eye. Archives of Ophthalmology. **57**: 593-610.
2. David Sutton, (1980) (Editor) A Textbooks of Radiology and Imaging. Third Edition, Volume Two: 1075-1115.
3. Duboulay, G.H: (1965) Principles of X-Ray Diagnosis of the Skull, London Butterworth & Co., Ltd.
4. Evans, R.A., Schwartz, J.F and Chutorian, A.M: Radiologic Diagnosis in Paediatric Ophthalmology. Radiologic Clinic of North America, 1963.
5. Helmy, I. D Tadros, A.A., and Michael, M. A (1969). The Anatomical Basis of Medical Practical Practice. The Human Skeleton. Alexandria 1st Edition 194-196.
6. Karakas, P., Bozkir, M. and Oguz, O Morphometric Measurements from Various Reference Points in the Orbit of Male Caucasians. Surgical and Radiologic Anatomy, 2002, Vol. 24, No.6 P 358-362.
7. Last, R.J: Eugene Wolff's Anatomy of the Eye and Orbit (1968). The Orbit and Paranasal Sinuses. 6th Edition. H.K Lewis and Co Ltd London 1-29.
8. Lloyd M.A., Glynn A.S (1975) Radiology of the Orbit, W.B. Saunders, and Company Ltd London. 1st Edition 1-29.
9. Lombardi, G. (1971). Orbitography. In Newton, T.H and Potts, D.G: Radiology of the Skull and Brain. St. Louis, C.V Mosby Co.
10. Manorama, B. Sudha, S. Veena, C. *et al.*, (2006): Diagnosis Radiology. Neuroradiology including Head and Neck Imaging. Jaypee Brothers Medical Publishers (p) Ltd 2nd Edition 19:437-457.

11. Merrell, R.A., Yanagisawa, E (1968: Radiographic Anatomy of the Paranasal Sinuses, Archives of Otolaryngology. **8**, 184.
12. Newton, T.H and Potts, D.G (1971) (Editors) Radiology of the Skull and Brain, the Skull: Volume 1, Book 2. 20(5) 463-486.
13. Saddler, T.W: Langman's Medical Embryology (2006): Lippincott Williams & Wilkins Co. India. 10th Edition. 9:125-132.
14. Susan, S. Harold E *et al.*, (2005). Gray's Anatomy. The Anatomical Basis of Clinical Practice. Elsevier Churchill Livingstone. 39th Edition. 27: 487-489; 28:493-495; 48:688-690.
15. Umar, M.B.T. Singh, S.P., Shugaba, A.I. (2005): Orbital Measurements among the Ethnic Groups of Plateau State, Nigeria, Highland Medical Research Ltd. July-December; Bol. 3. 2: 26-28.
16. Westcott, D.K and Jantz, R.L (1999) Anthropometric Variation Between the Sixious and Assiniboine. Human Biology (United States), 71(5): 877-888.
17. Wade N.: 2002. A New Look at Old Data May Discredit a Theory on Race. New York Times. 8 October.
18. Williams, P.L; Bannister, L.H; Berry M.M; Collins, P; Dyson, P; Dussek, J.E. Ferguson, M.W.J: Gray's Anatomy in: Skeletal System Edited by Soames, R.W. Churchill Livingstone, Edinburgh, London. 555-560. 1999.
19. Zizmor, J: Atlas of Orbital Radiography (Section One). Birmingham Alabama: Aesculapius. 1973.