

## Original Research Article

### **EFFECTS OF AQUEOUS EXTRACT OF *Moringa Oleifera* SEED ON THE HISTOLOGY OF THE KIDNEY IN WISTAR RATS**

#### **ABSTRACT**

*Moringa oleifera*, also called the “magic tree”, has a long history of use in the treatment of many diseases including those affecting the liver and kidney. This research work focuses on the effect of aqueous extract of *Moringa oleifera* seed on the kidney of healthy Wistar rats. Twenty (20) rats weighing between 100 - 150g were divided into four groups (A-D) of five rats each. Group A was control and received food and water. Group B, C and D received 400mg/kg, 800mg/kg and 1600mg/kg of aqueous extract of *Moringa Oleifera* per body weight respectively. The extract was administered orally for 21 days. On the 22<sup>nd</sup> day, the rats were sacrificed by cervical dislocation and the kidneys fixed in 10% formalin for histological studies using H&E. Histological observation showed proliferation of the mesangial cells in group B while in groups C and D glomerular sclerosis were observed. This study submits that aqueous extract of *Moringa oleifera* seed has nephrotoxic tendencies, and this effect was dose dependent.

Keywords: Kidney, *moringa oleifera*, nephrotoxic, cervical dislocation

#### **INTRODUCTION**

*Moringa Oleifera* is called the Miracle Tree for good reason. Its leaves, pods, flowers, fruits, roots, bark, and seeds have dietary and medicinal benefits (Anwar *et al.*, 2007). *Moringa Oleifera* is rich in vitamins A, several forms of Vitamin B, Vitamins C, D and E. In fact, it has more of these vitamins than a variety of common food sources like carrots, oranges and milk. There is twice as much calcium in *Moringa Oleifera* leaves than in milk. Iron is found in large quantities in *Moringa Oleifera* leaves as well. There is three times as much iron in this plant than in spinach. The leaves can be consumed to stimulate your metabolism, thus aiding in weight loss. *Moringa Oleifera* provides energy without sugar.

Herbalism is use of herbs for therapeutic or medicinal value. All of the amazing health benefits of *Moringa Oleifera* leaves and seeds make them a regular in the diets of people who live where they grow in Asia, Africa and South America. But despite the use of medicinal plants for therapeutic uses to remedy illnesses, there are still some disadvantages as some of these medicinal plants are taken without scientifically proven dosages, hence the need for this study.

The pathological effect of the aqueous extract of *Moringa Oleifera* seed on the skin, liver, gill, and kidney of fingerling and adult of Nile tilapia (*Oreochromis niloticus*) has been reported (Ayotunde *et al.*, 2009). Pathologic lesions observed include different levels of cells degeneration in the gill, lamellar hyperemia, and hypertrophy of gill arch occurred, while hyperplasia, disarrangement of hepatic cell, necrosis, and vacuolation occurred in fish liver and kidney. Damages of different organs became severe with increasing concentration of aqueous extract of *M. oleifera* seeds and time of exposure (Ayotunde *et al.*, 2009).

*Moringa Oleifera* also prevents hyperlipidemia and hepatocytes ultrastructural changes present in iron deficient rats (Ndog *et al.*, 2007). It was found that *Moringa Oleifera* reduced iron deficiency, diet induced increases in serum and hepatic lipids, with dose dependent increases of serum quercetin and kaempherol, but did not prevent anemia. In iron deficient hepatocytes, slightly swollen mitochondria and a few glycogen granules were observed, but glycogen granules increased and mitochondria were normalized by treatment with *Moringa Oleifera*. Furthermore, lipoproteins were observed in the Golgi complex under treatment with *Moringa Oleifera*. These results suggest a possible beneficial effect of *Moringa Oleifera* in the prevention of hyperlipidemia and ultra-structural changes in hepatocytes due to iron deficiency (Sangel *et al.*, 2012).

*Moringa Oleifera* seeds have antibacterial effects against *Staphylococcus aureus*, *Vibrio cholerae* and *Escherichia coli*. This gives credence to the use of *Moringa Oleifera* seeds and leaves as an antiseptic in traditional-medicine (June 2010 issue of "Revista do Instituto de Medicina Tropical de Sao Paulo"). A similar study, reported in the June 2009 issue of "Anais da Academia Brasileira de Ciencias," investigated the larvicidal effect of *Moringa Oleifera* seed extract. The researchers found that this extract was toxic to the larvae of the yellow fever mosquito, an insect that spreads a number of diseases. On the other hand, it was found that the extract was harmless to rats. The authors conclude that the seeds and their extract could be used in mosquito control programs. (Foild *et al.*, 1995) (Acquaye *et al.*, 2000).

The seed powder of *Moringa Oleifera* was analysed for its phytochemical composition using Folin-Denis spectrophotometric method. The seed powder had the following composition: nitrogen (2.98%), crude; Protein (18.63%), tannins (322.9 mg/100g), alkaloids (8.24 mg/100g) and saponins (9.13%). The predominant elements in the seed powder were: aluminum ( $144 \pm 4$  ppm) calcium ( $602 \pm .22$  ppm), potassium ( $732 \pm 164$  ppm), phosphorus (0.6|9 mg/kg) sodium ( $86.2 \pm 4.9$  ppm), manganese ( $17.5 \pm 0.4$  ppm), while Magnesium, Iron, Chromium, and Zinc were all beyond detection limits (Kawo *et al.*, 2009).

The kidneys are reddish-brown in colour and approximately 10cm long, 5cm wide and 2.5 cm

thick. The kidneys lie retroperitoneal on the posterior abdominal wall, one on each side of the vertebral column (Moore and Dailey, 5<sup>th</sup> Edition). One important function of the kidney is to rid the body of waste materials that are either ingested or produced by metabolism. A second function that is especially critical is to control the volume and composition of the body fluids. For water and virtually all electrolytes in the body, the balance between intake (due to excretion or metabolic consumption) is maintained in large part by the kidneys (Homeostasis). The regulatory functions of the kidney maintain stable environment for the cells necessary for them to perform their various activities.

The kidneys perform their most important function by filtering the plasma and removing substances from the filtrate at variable rates, depending on the needs of the body. Ultimately, the kidneys clear unwanted substances from the filtrate (and therefore from the blood) by excreting them in the urine, while returning substances that are needed back to the blood, this task is carried out (or performed) in the functional and structural unit of the kidney- the nephron (Guyton, 11<sup>th</sup> Edition; Ganong, 21<sup>st</sup> Edition). The kidney performs their most important functions by filtering the plasma and removing substances from the filtrate at variable rates, depending on the needs of the body. Ultimately the kidneys clear unwanted substances from the filtrate (and therefore from the blood) by excreting them in the urine while returning substances that are needed back to the blood (Guyton, 11<sup>th</sup> Edition).

## **Methodology**

### **Materials**

Materials used for this research study were Pestle and mortar, 5ml Syringe, dissecting set, rubber bowls, wire gauze, hand gloves, refrigerator, weighing balance, distilled water, surgical blade, glass slides, cover slips, picric acid, microtome.

### **Plant Material**

Matured *Moringa Oleifera* pods were obtained from a residential place in Nnewi North, Anambra State and authenticated at the department of pharmacology at Nnamdi Azikiwe University Agulu. The *Moringa Oleifera* seeds were manually removed from their pods and were air dried for 2 weeks at room temperature and pulverized. 250g of the seed powder was realized and soaking in 1 liter of warm distilled water. It was then stirred vigorously and allowed to stand for 24 hours and was filtered. The bulk filtrate was stored in the refrigerator until use.

### **Experimental Design**

Twenty male Wistar rats weighing between 100 - 150g were obtained from the Department of Physiology, Nnamdi Azikiwe University and acclimatized for two weeks in the Animal house

unit of the research laboratory of the Department of Human Anatomy, Nnamdi Azikiwe University. The animals were randomly divided into four (4) groups (A-D) of five (5) rats each, lettered. Group A served as control and received food and water only. Groups B-D served as the experimental groups. Group B received 400mg/kg per body weight of the extract. Groups C and D received 800mg/kg and 1600mg/kg per body weight of the extract respectively.

The rats were housed in plastic cages and were fed with growers mesh and water *ad libitum*. A hygienic environment was maintained to prevent infection. They were kept at room temperature throughout the period. All administration was done orally with a cannula and lasted for 21 days. On the 22<sup>nd</sup> day animals were sacrificed by cervical dislocation and the kidneys harvested and fixed immediately in 10% formalin for histological processing using the H&E according to the method of Drury *et al* (1967).

### Statistical Analysis

Numerical data obtained from this study were expressed as Mean  $\pm$  Standard deviation for the control and treated groups using Instat 3 graphed 1998 version. A probability level of P less than 0.05 (P<0.05) was considered statistically significant.

## RESULT

**Table 1: The Effect of Aqueous *Moringa Oleifera* Seed Extract On the Body Weight of Wistar Rat**

Group	Dose of Extract (mg)	Initial B.W (Mean $\pm$ SD) (kg)	Final B.W (Mean $\pm$ SD) (kg)	Difference in B.W (kg)	% Difference in B.W (kg)
A	Nil	94.74, $\pm$ 7.2	114.26, $\pm$ 10.0*	19.520	0.1952
B	400	85.40, $\pm$ 12.0	118.02, $\pm$ 11.8**	32.620	0.3262
C	800	94.14, $\pm$ 11.6	137.12, $\pm$ 11.8**	42.980	0.4298

<b>D</b>	1600	92.66,±9.4	143.54,±8.9***	50.880	0.5088
----------	------	------------	----------------	--------	--------

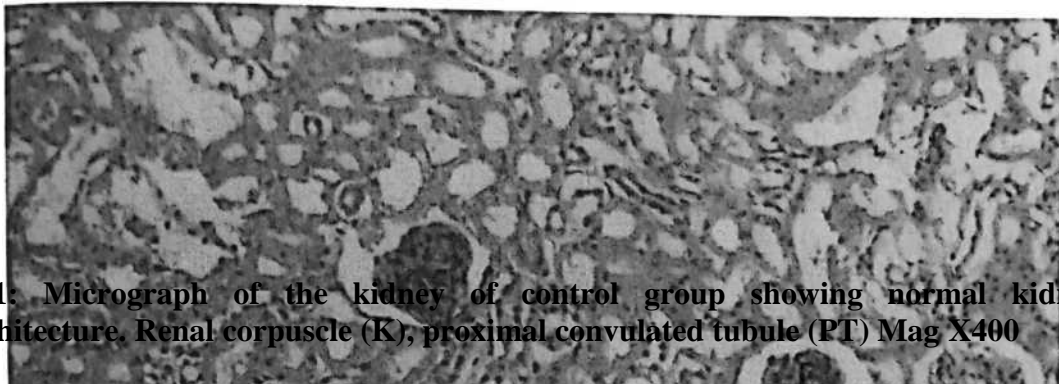
\*= significant \*\*= highly significant, S.D = Standard Deviation, B.W = Body Weight,

Body weight of rats were significantly increased at the final stage of the experiment compared to the initial stages for both control and test groups. This implies that administration of aqueous extract of moringa did not adversely affect rat body weight or impede their ability to acquire normal body weight increase associated with growth and development.

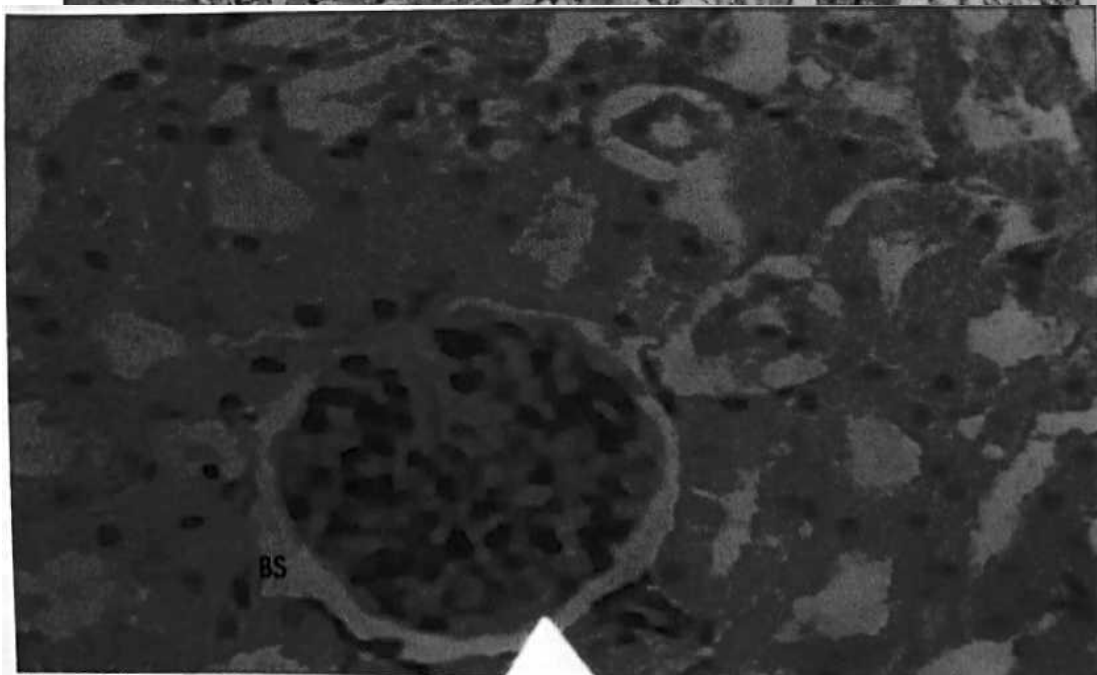
### **Result of histological studies**

The kidney of the control showed normal architecture. The granular cytoplasm was clearly seen. Lymphocytes were seen lining the interstitium. The glomeruli were also very visible with tufts of blood capillaries in them. Proximal convoluted tubules were seen around the glomerulus, and far from it is the distal convoluted tubules all located in the renal cortex.

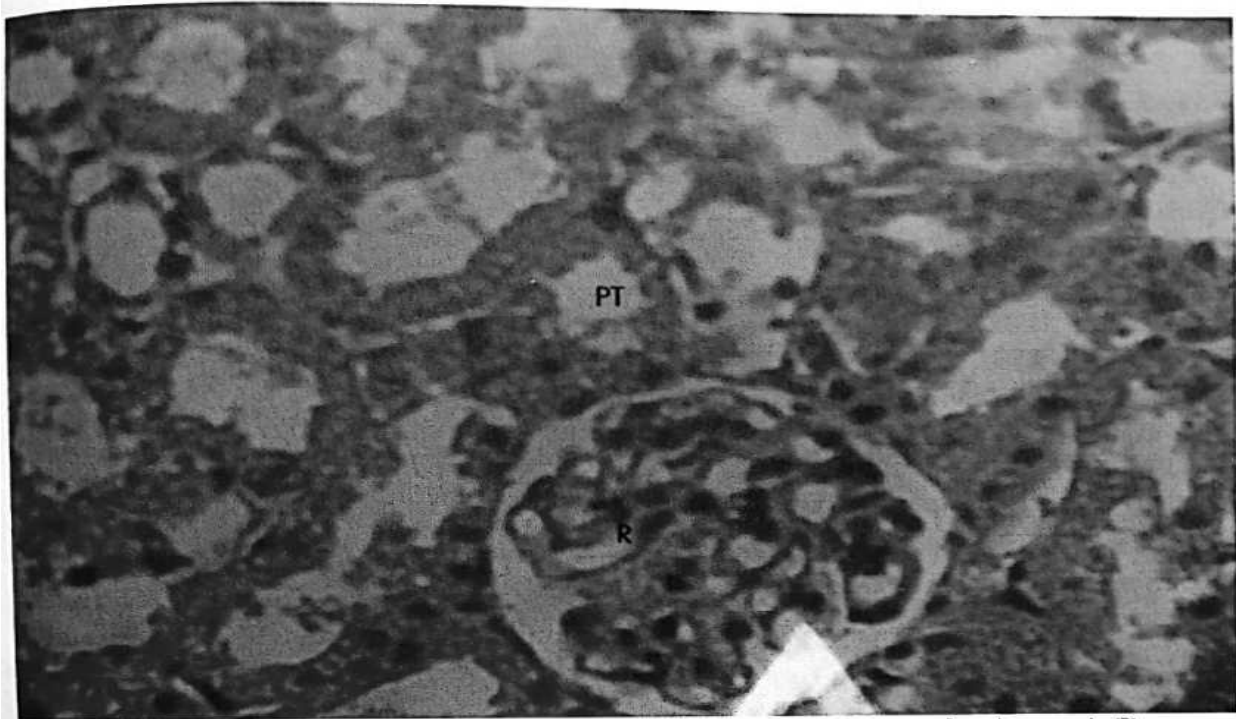
In the low dose group, which was administered with 400mg/kg of body weight of the aqueous *Moringa Oleifera* seed extract; there were proliferation of the mesangial cells leading to the thickening of mesangial basement membrane thereby reducing in the bowman's space. In the medium dose group, which was administered with 800mg/kg of body weight of the aqueous *Moringa Oleifera* seed extract, cell necrosis was observed. Focal sclerosis was also observed. The architecture of the glomerulus was mildly distorted. In the high dose group, which was administered with 1600mg/kg of body weight of the aqueous *Moringa Oleifera* seed extract, the normal architecture of the kidney was more distorted than the 800mg/kg of body weight dose. Areas focal glomerular sclerosis was observed.



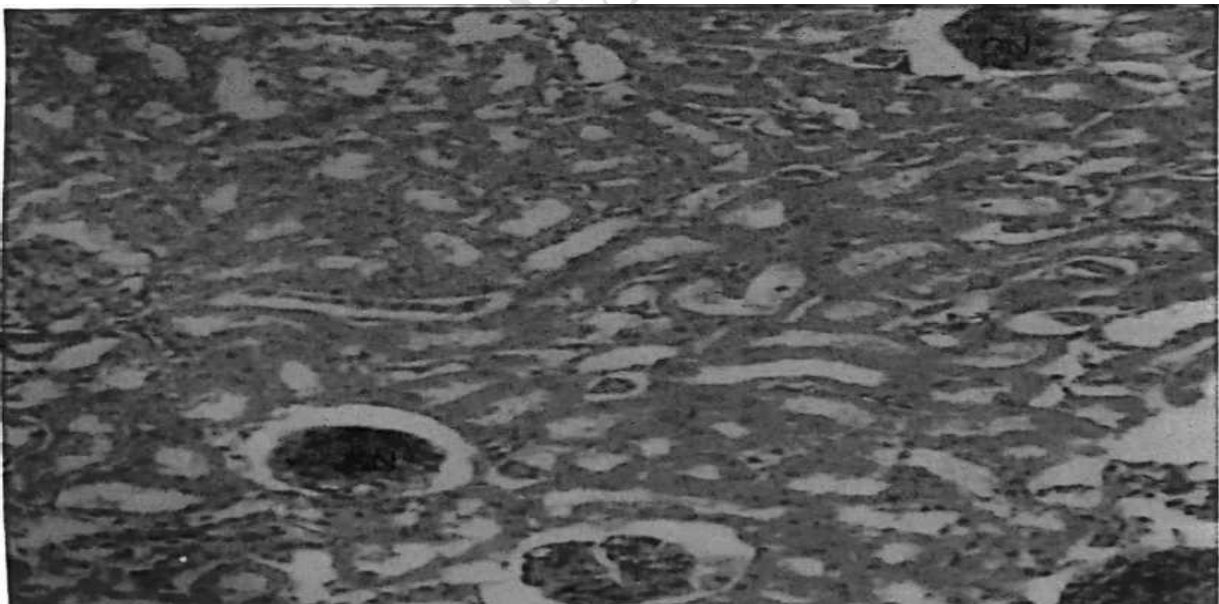
**Plate 1:** Micrograph of the kidney of control group showing normal kidney cytoarchitecture. Renal corpuscle (K), proximal convoluted tubule (PT) Mag X400



**Plate 2:** Micrograph of kidney at low dose (400mg/kg of body weight of moringa seed extract). Arrow shows mesangial basement membrane thickened due to proliferation of the mesangial cells and Bowman's space (BS) decreasing in size (X400).



**Plate 3: Micrograph of kidney at low dose (800mg/kg of body weight of Moringa seed extract) showing areas of focal sclerosis (X 200).**



**Plate 4: Micrograph showing aggregation of inflammatory cells (arrow head) in high dose (1600mg/kg) X400.**

## DISCUSSION AND CONCLUSION

The present study was carried out to determine the effect of aqueous *Moringa Oleifera* seed extract on the kidney in albino rat. There was observable histological degeneration that took place in the kidney tissue. There was also observable increase in body weight in the experimental groups compared to the control group as presented in table 1.

The histological observation of the kidney in the control group showed normal features of the kidney with the glomerulus and the bowman's space, proximal and distal convoluted tubules well outlined. In the treatment groups, there were slight changes and degeneration that were observed. There were proliferations of mesangial cells of the bowman's space, leading to thickening of the basement membrane, focal sclerosis was also observed at the glomerulus, thereby increasing the bowman's space as well as aggregation of inflammatory cells in the high dose group. Histopathological examination of the kidney tissue sections showed that the administration of aqueous *Moringa Oleifera* seed extract is toxic to the kidney. This was evident by comparing the control group to the treatment group.

The level of toxicity was dose dependent in line with the reports of Ajibade *et al.*, (2012) which may be due to the presence of alkaloids in the plant as reported by Sinha *et al.*, (2007).

The result obtained in this study was in line with that obtained in a similar study demonstrated by Ajibade *et al.*, 2012. In their work, methanolic extract of *Moringa Oleifera* administered to albino rats resulted in degenerative changes and mild cortical congestion and interstitial haemorrhages at the cortex of the kidney.

### Conclusion

This study established that aqueous *Moringa Oleifera* seed extract might be nephrotoxic in a dose-dependent fashion.

### REFERENCES

- Ajibade T. O., Olayemi F. O. and Arowolo R. O. A (2012). The Haematological and Biochemical effects of methanolic extract of the seeds of *Moringa Oleifera* in rats. Department of Veterinary Physiology, Biochemistry and Pharmacology, Faculty of Veterinary Medicine, University of Ibadan, Ibadan, Nigeria. *Journal of Medicinal Plants Research* Vol. 6(4), pp. 615-621.
- Anwar F., Latif S., Asharf M., Gilani AH (2007). *Moringa Oleifera*- a food plant with multiple Medicinal Uses. *Journal of Botany*, Vol.39 (5), pp.1443- 1453.
- Acquaye D, Smith M, Letchamo W, Simon J (2000). The miracle tree: Center for new use agriculture and natural plant product. Rutgers University, Cook College. Pg 65-78

Dalen, M.B., Pam, J. S., Izang, A. & Ekele, R. 2009. Synergy between *Moringa Oleifera* seed powder and alum in the purification of domestic water science world journal Vol 4. Pg 125-128 www.sciecnceworldjournal.org ISSN 1597-6343

David Shier, Jackie Butler, Ricki Lewis (2010) Hole's Human Anatomy and Physiology, 12<sup>th</sup> Edition, McGraw-Hill, New York. Pg. 776- 778.

Foidl, N., Makkar, I.P.S. and Becker, K. 2001. The potential of *Moringa Oleifera* for Agricultural and Industrial Uses, in: L.J. Fuglie (Ed.), The Miracle Tree: The Multiple Uses of *Moringa Oleifera*. CTA, Wageningen, Netherlands: pg 45-76

Gupta R, Dubey DK, Kannan GM, Flora SJ. (2007). concomitant administration of *Moringa Oleifera* seed powder in the remediation of arsenic - induced oxidative stress in mouse. Ceil boil international, 44-56

Guyton A.C & Hall J.E (2006). Urine formation by the kidneys: glomerular filtration, renal blood flow, and their control; the body fluids and kidneys. Text Book of Medical Physiology, 11<sup>th</sup> edition. Pg 303 – 325.

Inderbir Singh (2002). Textbook of human histology with colour atlas, Jaypee Brothers, Medical publishers (P) Ltd New Delhi Pg 264-270.

Inderbir Singh and G.P.Pal (2007) Human Embryology, Eighth edition, Rajiv Beri for Macmillan India Ltd, New Delhi. Pg 249-244.

Jemeison, G.S (1939), Ben {*Moringa Oleifera*} seed oil. Oil and Soap. Pp 173- 174 Karahan I, Atessahim A, Yilmaz S, Ceribasi A.O and Sakin F (2005). Protective effect of lycopene on gentamicin - induced oxidative stress and nephrotoxicity in albino rats. Journal of Toxicology. Pg 134- 140.

Kawo, A.H., Abdullahi, B.A., Gaiya, Z.A. Halilu, A., Dabai, M. and Dakare, M.A. (2009). Preliminary Phytochemical Screening, Proximate And Elemental Composition of *Moringa Oleifera Lam* Seed Powder. Bayeio Journal of Pure and Applied Sciences, Volume 2(1): 96 - 100

Mangale S. M. Chonde S. G. Jadhav A. S. and Raut P. D. (2007). Study of *Moringa Oleifera* (Drumstick) seed as natural Absorbent and Antimicrobial agent for River water treatment. Journal of Natural. Production Plant Resource. Pg 87 - 90

Moore KL, Dailey AF, (2006): Clinically Oriented Anatomy, 5<sup>th</sup> Edition, Lippincott Williams and Wilkins Publication, UAS, ISSN 0-7817- 3639-0(2)289-300 5th Moore and Persaud.

The Developing Human. Clinically Oriented Embryology 6<sup>th</sup> Edition. WB. Sanders Publication Company. ISSN 0-58089-2180-0. Pg 245-255

Le Strange R, Angus, Robertson (1977). A history of herbal plants. Pg 24

Poon M.K, Chiu P.Y, Leung. H.Y, Siu A.H and Ko K.M (2007). A yang invigorating Chinese herbal formula protects against gentamicin- induced nephrotoxicity in rats. Department of Biochemistry, Hong Kong University of Science and Technology, clear water bay, Hong Kong SAR, China.

Romanes, G.J Cunningham's Manual of Practical Anatomy: 15th Edition, volume 2 Oxford University press inc; New York. Pg 89 – 97.

Sinha M, Manna P, Sil PC (2007): Amelioration of galactosamine — induced nephrotoxicity by a protein isolated from the leaves of the herb *Cajanus Indicus* L. department of Chemistry, Bose institute, Kolkata. Pg 34-40

William F. Ganong; Review of Medical Physiology, 21<sup>st</sup> Edition, Lange Medical Books, McGraw - hill publications, USA, 2003 ISBN -0-07-121765 - 7 (25) 502 - 508. Pg 250 - 265

Young B, Heath J. W, Stevens A, Lowe S. J, and Deakin J. P (2000). Kidney in the Urinary System. Wheater's Functional Histology. A Text and Colour Atlas, 4<sup>th</sup> Edition. Pg 303 – 320.