

Applicability of the 1470 Nm Diode Laser in Facial Aesthetics: An Evidence-Based Review

ABSTRACT

Introduction: Endolaser or Endolift® is a minimally invasive procedure carried out using a diode laser with a wavelength that can range from 980 to 1470 nm. This laser is inserted into the subcutaneous layer through an optical fibre probe to reduce fat and induce skin retraction via neocollagenesis. **Objectives:** To assess the effects of the 1470 nm diode laser on subdermal lipolysis and rejuvenation based on evidence-based practice. **Methodology:** An evidence-based literature review was conducted to elucidate the impact of the 1470 nm diode laser on facial rejuvenation. This review involved an exploration of scientific articles published and accessible within the databases MEDLINE, PubMed, SCIELO, and LILACS spanning the years from 2013 to 2023. **Results:** Six reports utilising the 1470 nm diode laser for aesthetic purposes were identified, underscoring the prevailing knowledge gap regarding applying the 1470 nm diode laser for aesthetic purposes such as lipolysis and as an adjunct for facial rejuvenation. **Conclusion:** While the 1470 nm diode laser is currently widespread within the domain of facial aesthetics, a constrained body of research with a high level of scientific evidence exists. This suggests an urgent requirement for well-designed further investigations, such as randomised clinical trials.

Keywords: Endolaser. Endolift® laser. Laser lipolysis. 1470 nm diode laser. 1470 nm bare-fibre diode laser.

1. INTRODUCTION

Patients' pursuit of aesthetic enhancement and concerns about the risks associated with invasive rejuvenation surgeries have become prevalent in aesthetic clinics. Within this context, lasers have emerged as an alternative in the Aesthetic Medicine field to defer the necessity of traditional plastic surgeries for facial contouring. The photothermal action of lasers on subdermal tissues yields a compacting and skin-retracting effect, producing outcomes akin to classical procedures while affording patients greater comfort, reduced pain, minimised scarring, and shorter recovery periods [1].

The high-powered 1470 nm diode laser represents an innovative technology harnessed for cosmetic treatments, purportedly targeting fat cells to induce skin tightening. This mechanism is believed to transpire through light absorption by water within cells, simultaneously heating the water until the cell ruptures [2]. This treatment addresses long-term skin laxity and superficial wrinkles by stimulating the formation of new fibrous collagen septa that, in turn, retract the skin [3].

The recently disseminated technique, initially recognised as Endolaser [3-4] and subsequently as Endolift® [5-6], involves the fortification of skin tissues using an optical fibre probe [7]. Introducing a laser beam with a wavelength ranging from 980 nm to 1470 nm through an optical strand into the superficial subcutaneous layer reduces subcutaneous fat, and skin toning can be achieved via neocollagenesis [8].

In this context, the current study endeavours to assess the effects of the 1470 nm diode laser with regard to subdermal lipolysis and rejuvenation, grounded in evidence-based practices. The goal is to evaluate the common recommendations regarding this technology's utilisation and assess the evidence supporting or contradicting these recommendations.

The application of lasers in rejuvenation treatments within Aesthetic Medicine has evolved significantly since the advancement of knowledge surrounding selective photothermolysis in the 1980s [35]. The laser demonstrates unique behaviour when its interaction with biological tissues is examined [36]. Although the fundamental nature of this light has remained consistent, the depth of understanding regarding its multifaceted biological interactions has considerably deepened. This expanding comprehension has spurred equipment companies to adapt their platforms and even reintroduce previously discontinued equipment due to a lack of technical knowledge [37].

The escalating demand for minimally invasive procedures yielding substantial, consistent, and lasting outcomes, coupled with technological and technical advancements, has bestowed a prominent position on laser platforms in the global aesthetic market. This technology has the potential not only to defer or prevent plastic surgeries, making them safer, but also to serve as a crucial tool in meeting the growing demand for minimally invasive, high-performance procedures [37].

When considering the delivery of light into subdermal tissue via an optical fibre sensor, it is imperative to determine which structures are targeted and with what intensity. The light wavelength addressed in this study primarily targets water and tissue fat, though it can also affect other structures through thermal effects, commonly termed "side effects" [38].

Understanding this interaction between light and skin necessitates adherence to specific application methodologies. The heterogeneity of skin and varying dermal tolerance among individuals makes it nearly obligatory to possess a fundamental knowledge of the skin to be irradiated by the laser, enabling the customisation of treatment protocols [39].

As the high-powered 1470 nm diode laser interacts with tissue water, it encounters its primary absorption target. This interaction facilitates the "evaporation of tissue water," a phenomenon contingent on the fluence applied per cubic centimetre of tissue. A thermal effect ensues upon absorption of tissue water, inducing the retraction of collagen fibres, lipolysis, neocollagenesis, and neovascularisation [24-28].

This cascade of physiological reactions yields the desired treatment effects, resulting in skin rejuvenation, improved elasticity, reduced laxity, and enhanced hydration. Efficient utilisation of this technology necessitates scientific comprehension and clinical proficiency in tailoring protocols according to each patient's characteristics [40].

2. METHODOLOGY

2.1 Bibliographic search and database retrieval

An evidence-based bibliographic review was conducted to elucidate the effects of the 1470 nm diode laser in the context of facial rejuvenation. This comprehensive review systematically examined scholarly articles available in prominent databases, including MEDLINE (Medical Literature Analysis and Retrieval System Online), PubMed (National Library of Medicine), SCIELO (Scientific Electronic Library Online), and LILACS (Latin American and Caribbean Health Sciences). The search encompassed the period from 2013 to 2023 to capture the most relevant and contemporary literature on the subject (Figure 1).

2.1.1 Eligibility Criteria

Studies were selected that reported the utilisation of the 1470 nm diode laser for facial rejuvenation, along with descriptions of the techniques employed in the treatment, within the time frame of 2013 to 2023. Sources excluded encompassed review articles, studies involving animal models, publications exceeding a decade in age, and those that were only partially accessible.

2.1.1.1 Levels of Evidence

In order for a clinician to perform a safe and effective treatment, it is essential that they rely on robust proof in the decision-making process, ensuring an appraisal of the best available research evidence [9]. Analysing the evidence

pyramid (Figure 2) is one of the most well-known methods to depict the sources of evidence and classify them as strong or weak. The top of the pyramid portrays the most substantial proof and includes controlled, randomised clinical trials and systematic reviews. More inadequate sources of verification encompass epidemiological studies, disease models, case series, reports, and textbooks (the latter two are not peer-reviewed). Evidence categorised as level I denotes the highest quality and comprises randomised controlled trials. Level IV represents the lowest quality, including textbooks, editorials, expert opinions, etc. (Figure 1).

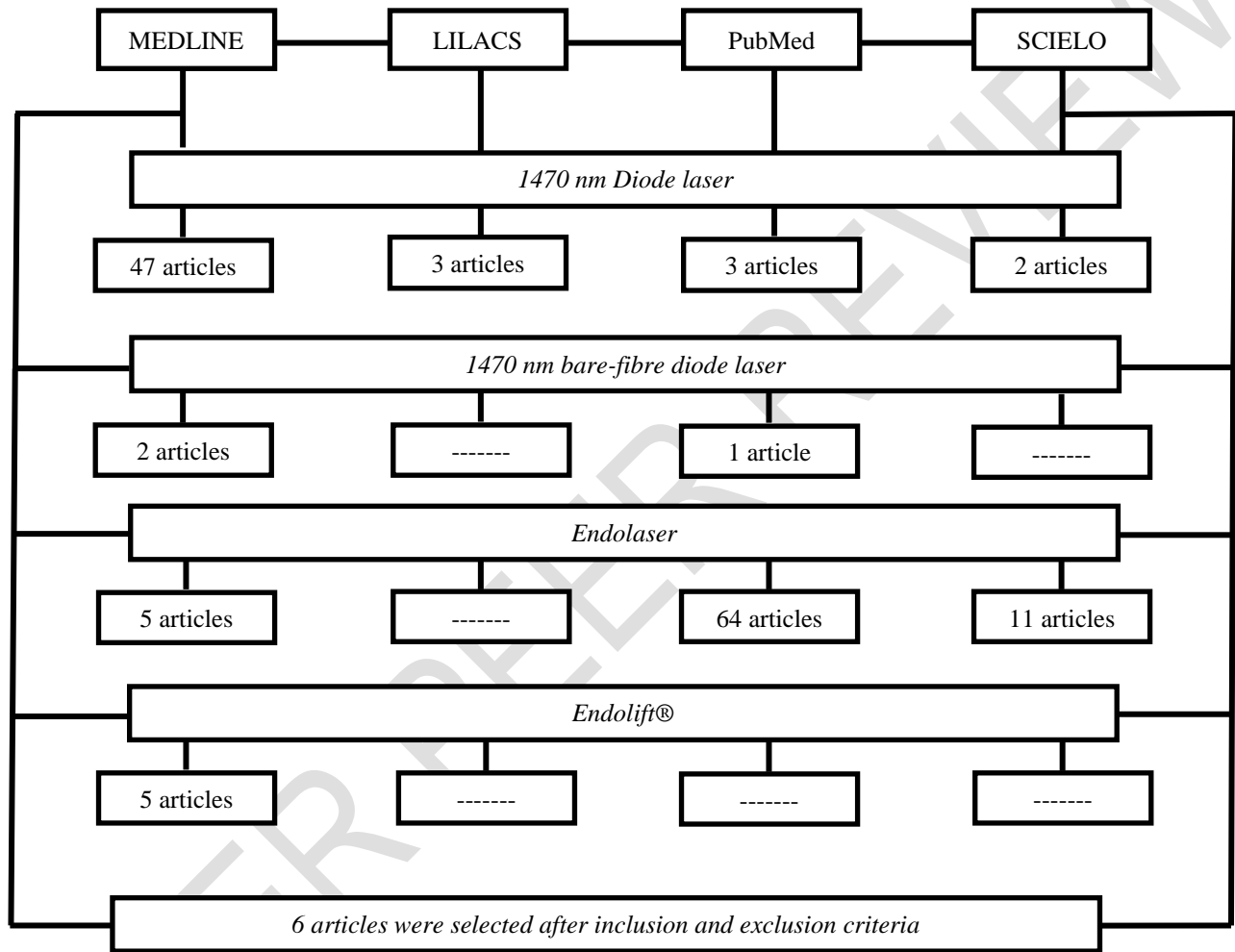


Fig. 1. Flowchart of the bibliographic search process (Authors, 2023)

As depicted in Figure 2, the pyramid represents studies according to their levels of evidence in a semi-quantitative manner. The pinnacle of the pyramid signifies the most substantial evidence level. While it is more desirable, there are few studies of high scientific impact. The pyramid's base represents the less desirable proof level; however, it is the most abundant. Hence, selecting robust scientific studies becomes imperative to guide clinical practice with a solid, safe, and efficacious scientific basis.

The assessment of proof is conducted based on a classification system that incorporates levels of evidence by study type (Table 1), which can be applied to the Health Sciences. In this classification scheme, Level I corresponds to the highest quality evidence. Levels IV to VII encompass proof of lower quality.

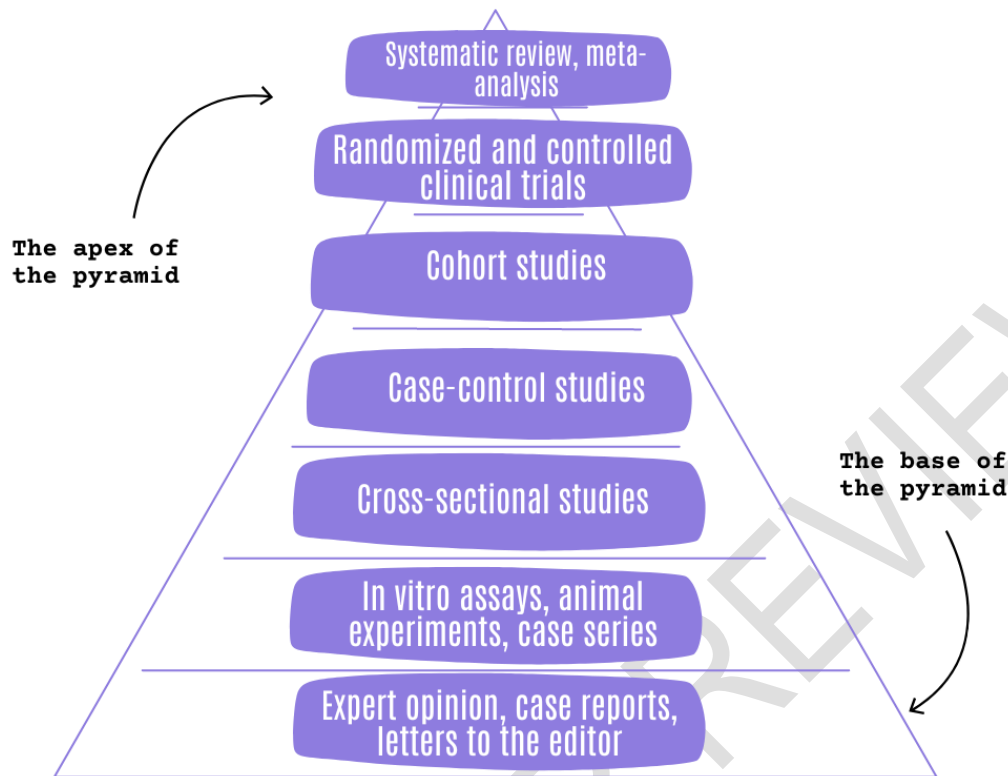


Fig. 2. Hierarchy of scientific evidence according to study type (Adapted [10-12])

Table 1. Levels of evidence and description by study type

Level I: Systematic review or meta-analysis of all relevant randomised controlled trials
Level II: Randomized controlled trials (well-designed)
Level III: Controlled trials without randomisation (well-designed)
Level IV: Case-control and cohort studies (well-designed)
Level V: Systematic reviews of descriptive and qualitative studies
Level VI: Single descriptive or qualitative studies
Level VII: Opinion of authorities and reports of expert committees

Source: Adapted [13]

3. RESULTS AND DISCUSSION

3.1 Evidence associated with the use of 1470 nm diode laser for lipolysis and rejuvenation

Evidence 1- Laser-assisted lipolysis for neck and submental remodelling in Rohrich Type IV patient: Fact or fiction? [14]

The study was conducted with ten Fitzpatrick skin phototypes I to IV patients with neck ageing (Rohrich type IV [15-17] - moderate to severe skin laxity and lipodystrophy, see Appendix I), with a mean age of 59.3 ± 8.6 . The laser was a 1470 nm diode laser (Alma® Lasers, Cesarea, Israel) and a 600-micrometre optical fibre probe introduced through a 2 mm blunt-tipped cannula. The laser energy was delivered through three side windows in continuous mode at 15 W of power. The parameters of this study reached an external temperature of 42°C, measured by an infrared thermometer (CEM DT-

880B, Shenzhen Everbest Machinery Industry Co. Ltd, China). The total energy delivered to the treated submental area ranged from 10 to 14 kJ.

Regarding the technique, tumescent anaesthesia was used in all patients (Klein's formula, lidocaine 0.1% and 1:1,000,000 epinephrine, average of 200-300 mL [18]). The energy was applied in crisscross fan-like motions in the deep plane. After energy delivery, the same cannula was used to aspirate liquefied fat connected to a device at 1 bar of negative pressure (Lipo-MR™, Ordisi SA, Barcelona).

Patients were instructed to wear a compression facial garment (VOE SA Barcelona, Spain) during the day for 15 days to maintain the lax skin attached to the submental plane. Subsequently, its use was recommended for an additional 30 days during the night. The mean cervicomental angle decreased from 191.5 ± 5.7 to 164.9 ± 14.2 degrees ($p < 0.01$). This demonstrated a systematic reduction in fat thickness and improved skin appearance. The investigators decided to perform complementary surgery for two patients who were unsatisfied with the results. The platysma was advanced and plicated six months after the 1470 nm diode laser treatment.

Laser lipolysis alone seems insufficient for complete remodelling in the Rohrich type IV aged neck, with complementary surgery necessary for Grade IV cases.

#Evidence 2 - Endolaser soft lift: From theory to practice [1]

In this study, Endolift® procedures were performed using a 1470 nm diode laser (Eufoton® LASEmaR® 1500, Via Flavia 23/1, 34148 Trieste, Italy), employing a cannula inserted through a wing-shaped incision in the skin, reaching the junction between the deep dermis and the superficial layer of subdermal fat.

The cannula should move back and forth three times within each tunnel to achieve the correct photothermal lesion, emitting laser light while moving backwards. The tunnels should be oriented along antigravitational lines, and their number can vary from a minimum of 3 to a maximum of 10, depending on the treated area. The procedure should be repeated thrice at 4- or 5-month intervals for optimal results.

It was stated that the treatment can be performed under local anaesthesia, and there may be a burning sensation for at least 4-5 hours, which can be managed with oral analgesics. The patient will wear a compressive dressing 24 hours a day during the first four days postoperatively and only during the night for an additional four days. Oedema and bruising may occur in the treated areas, which will spontaneously resolve. Antibiotic therapy was suggested. Results become visible three or four months after the last treatment, but to achieve the best outcome, one must wait at least eight months due to the time required for subcutaneous scars to remodel the treated area.

This study observed favourable outcomes and high patient satisfaction at six months post-procedure. Endolift® is not a substitute for facelift surgery. However, it presents a viable alternative for those patients who decline traditional surgery.

#Evidence 3 - The 1470 Nm diode laser effectiveness in facial fat reduction with the Endolifting technique: A pilot study [19]

Ten patients were treated with a 1470 nm diode laser (Delight® 1470, VYDENCE Medical) in a single session on the mandibular and submental regions, utilising a 400-micron optical fibre sensor with power ranging from 4-8 W in continuous mode. Patients were instructed to maintain the dressing for four days and undergo four sessions of manual lymphatic drainage once a week.

Diagrams in a "fan" configuration were designed with vectors spaced approximately 1-2 cm apart. Subsequently, an anaesthetic button was applied at the convergence point of the vectors using 2% 3M™ Xylestesin™ with a vasoconstrictor to enable the creation of an orifice, utilising a 30 G needle. A 22G/50mm cannula was introduced to create channels for the optical fibre passage and the introduction of anaesthetic (0.1 ml of 2% 3M™ Xylestesin™ with vasoconstrictor) towards each vector. The optical fibre probe was inserted to the distal limit of the traced vector on the skin, making three to six passes with the laser activated. After the entire region had been irradiated with the laser, massage manipulation was performed to drain the emulsified adipose tissue through the orifice. Patients were followed up for four months, and during that period, they were reassessed twice. The first assessment occurred immediately after the second month of treatment and the second at the end of the fourth month.

Following treatment and evaluation at the end of 60 days, a distinct reduction in fat was observed in the cheeks and submental region. Additionally, the skin from which submental fat was removed exhibited significant retraction, leading to a noticeable reduction in sagging and wrinkles.

#Evidence 4 - Endolift® and multi-wavelength laser photobiomodulation: a randomised controlled trial study on 96 subjects, treating skin laxity of the lower third of the face [20]

In this randomised controlled study, 96 individuals were included to treat the lower third of the face. They were divided into three groups: 1) 6 men and 26 women received Endolift® followed by laser photobiomodulation at various wavelengths (532 nm, 808 nm, 1064 nm) at 7-, 14-, and 21-day intervals. 2) 6 men and 26 women underwent a single session of Endolift®. 3) 6 men and 26 women received only laser photobiomodulation at various wavelengths. Both groups were followed up on days 60, 120, and 540 days after treatment.

The Endolift® session was performed with a 300-micron microfibre with radial emission, connected to a 1470 nm diode laser, inserted without incision or anaesthesia, directly into the superficial middle hypodermis.

The fibre was moved throughout the intervention area in a fan-shaped pattern, delivering energy first retrograde and then anterograde, creating micro tunnels mainly oriented along anti-gravitational vectors. During the procedure, the skin surface temperature should never exceed 40°C (measured by an external thermal sensor). The cumulative energy of Endolift® ranged from 500 J to a maximum of 1400 J, with an average of 800 J for the entire area.

The delivered laser photo biomodulation energy at various wavelengths was approximately 4 J/cm² for each emission, with a total of 12 J/cm² considering the overlap technique in each zone, with an average total of 360 J/cm² for each subject.

Most individuals experienced a change in the degree of ptosis, transitioning from grades 4 to grades 2 and 1. Results from the three groups revealed that the combination of both treatments (Endolift® and laser photo biomodulation at wavelengths 532 nm, 808 nm, and 1064 nm) achieved quicker effects, while treatment solely with laser photo biomodulation at various wavelengths achieved a slower result.

The utilisation of Endolift® laser technology was considered an innovative treatment aimed at lifting tissues within the skin. The use of laser photo biomodulation at various wavelengths in combination with Endolift® demonstrated a significant role in achieving the desired 'gentle' rejuvenation model that is increasingly sought after.

#Evidence 5 – Endolift® the “lunch-time” laser lifting for the lower eyelids: case report [21]

A case report of a 43-year-old patient with wrinkles and skin laxity in the lower eyelids treated in a single session of Endolift® is presented. No anaesthesia was performed. A 200-micron fibre was connected to an Italian 1470 nm semiconductor laser (Eufoton® - Italy). The thread was inserted into the skin without incision between the orbicularis oculi muscle and the septum.

The entry point of the fibre was 1 cm inferiorly to the lateral corner of the eye. The total laser energy was 80 J for each side. Prior to Endolift®, treatment of fine telangiectasias was performed with a 532 nm diode laser.

The lower eyelids, as well as different areas of the face, neck, and body, had benefited from the potential of Endolift® to retract and remodel tissues, resulting in overall skin tightening that continued to progress in the months following the treatment.

#Evidence 6 - Treatment of hypertrophic scars and keloids using an intralesional 1470 nm bare-fibre diode laser: a novel efficient minimally-invasive technique [22]

A prospective single-centre cohort study evaluated the efficacy of a non-ablative fractional diode laser and fibre in treating hypertrophic and keloid scars in various anatomical regions caused by trauma, burns, acne, or surgery in 21 patients over two years.

A non-ablative fractional laser LASEmaR® 1500 (Eufoton®, Trieste, Italy) emitting wavelengths of 1470 nm was utilised in this study. The energy was delivered through a disposable bare optical fibre probe with a diameter of 300 microns. The power was adjusted based on the scar's hardness to penetrate the scar, starting from 3 W and gradually increasing to a maximum power of 6 W, with a maximum fluence of 999.9 kJ/cm². The optical fibre sensor was initiated with the laser to penetrate and deliver the energy through 1 to 4 passes of the scar. The procedure was repeated once every one or two months until satisfactory results were achieved for both the clinician and the patient.

There was a 27.7% and 28.2% reduction in scar thickness for hypertrophic and keloid scars, respectively. The study indicated that the 1470 nm fibre laser could be a promising treatment modality for hypertrophic and keloid scars, demonstrating to be a safe and effective method based on subjective and objective analyses. Nevertheless, additional investigations into the mechanisms of the fibre laser, including immunohistopathological studies, are needed to confirm these results.

For a long period, the predominant procedures performed with the 1470 nm diode laser were exclusively intended for medical treatment, such as laser-assisted liposuction for gynecomastia [23], laser-assisted liposuction for body contouring and facial fat grafting [24-25], ablation of large saphenous veins [26], pilonidal sinus disease [27], vascular lesions [28], and other medical conditions. Nonetheless, this technology has opened a new paradigm of applicability in the field of facial aesthetics, as this wavelength emits light energy preferentially absorbed by water, producing a rapid contouring effect in addition to reducing adipose tissue, providing skin firmness and aesthetic improvement [24].

3.2 Considerations

This study's motivation was driven by this new paradigm of applicability of the 1470 nm diode laser in aesthetics. The six articles found after the literature search revealed that few studies had been conducted to elucidate the efficiency and safety of the 1470 nm diode laser in facial aesthetics. Through the literature search, six articles were selected, corresponding to the following levels of evidence: Level II (Evidence 4); Level IV (Evidence 6); Level VI (Evidences 1 and 3); Level VII (Evidences 2 and 5). Therefore, new studies must be conducted in the light of science with a high level of proof, bringing positive and safe impacts to the decision-making of facial rejuvenation treatments.

Tumescence is one of the essential steps of the procedure and should be performed before the passage of the fibre that will deliver energy to the subcutaneous tissue. Its role is to increase the homogeneity of the laser's action in a heterogeneous set of tissues, such as the face. It also allows for increased space between the reticular dermis and the superficial aponeurotic muscle system, avoiding significant vascular and nerve injuries. Tumescence anaesthesia is widely used in skin and adipose tissue surgeries, such as liposuction and vascular surgeries. This procedure involves infusing large volumes of a low-concentration local anaesthetic solution until tissue tumescence is achieved [29]. Therefore, it is a crucial safety link in the performance of Endolaser/Endolift®. However, from the verification presented here, only one reported using tumescence anaesthesia (Evidence 1), another suggested local anaesthesia (Evidence 2), anaesthetic button (Evidence 3), without anaesthesia (Evidences 4 and 5), and finally, without any mention (Evidence 6).

It was noticed that there is no standardisation in the use of fibre for energy delivery to the skin; nevertheless, its use is determined based on the thickness of the skin in the treated region to avoid nerve injuries. Among the analysed studies, optical fibres of 600 microns were used (Evidence 1), 400-micron fibres (Evidence 3), 300-micron fibres (Evidence 4 and 6), and 200-micron fibres (Evidence 5). It needs to be clarified whether this difference can cause loss or gain of light during the procedure, making it another point of discussion. All the evidence reported promising results with the 1470 nm diode laser, whether for reducing adipose tissue, skin retraction, eyelid retraction, or hypertrophic scars.

The 1470 nm wavelength of the diode laser is one of the longest in the infrared spectrum. It achieves rapid and efficient heating of subcutaneous tissue due to its high fat and water absorption level. The heat generated when the laser energy is absorbed alters the Na⁺K⁺ balance of the cell membrane, allowing the transport of extracellular fluid into the cell [30].

As mentioned earlier, the 1470 nm diode laser is still a tool that has continuously improved the safety of procedures and long-term results for aesthetic surgeons. It is commonly used to remove excess fat effectively, and due to its quality, even grafting can be performed [24]. Therefore, this level of safety and effectiveness can also be achieved in facial aesthetics, provided that controlled studies are conducted for this purpose.

The degree of photothermal effect on adipose tissue depends on the internal tissue temperature. Temperatures between 50-65°C destroy adipocytes and induce tissue necrosis and healing [31]. In parallel, the 1470 nm diode laser has a high-water absorption coefficient, causing gentle heating of the adipose tissue sufficient to induce lipid release and reduce tissue viscosity [32]. The localised, controlled, and reversible thermal injury also provides a haemostatic effect by coagulating small blood vessels, minimising blood loss and subsequent hematomas [33]. Given these statements, monitoring the temperature during the Endolaser/Endolift® procedure becomes essential to maintain procedure reliability, as most studies in the literature suggest.

A relevant point to consider in this discussion regarding skin pigmentation is that the 1470 nm diode laser does not seem to enhance melanin deposition, thereby not causing hyperpigmentation. Conversely, scientific evidence suggests that its use reduces the pigmentation of scars and may destroy melanin accumulation, thus reducing pigmentation [22]. This information is especially interesting for patients with melasma and hyperpigmentation, who can undergo

Endolaser/Endolift®, benefiting from facial rejuvenation effects without compromising skin quality with hyperpigmentation or exacerbations.

Other studies aimed at reducing forehead wrinkles and treating expression lines also demonstrated that Endolift® is a safe technique for the supraorbital and supratrochlear nerves and does not leave scars or require patient recovery time. These findings maximise the potential uses of Endolaser/Endolift®, favouring treating other aesthetic conditions [34].

4. CONCLUSION

Evidence-based clinical decision-making is a pivotal starting point for evaluating novel technologies in facial aesthetic procedures. Available evidence reveals that published studies encompass a limited number of samples, are bounded by technique-related limitations, and exhibit low proof. A comprehensive literature analysis indicates that aesthetic treatments utilising the 1470 nm diode laser suggest both safety and effectiveness. However, despite its growing prominence in facial aesthetics, the literature concerning the 1470 nm diode laser still needs to be more extensive in studies characterised by strong scientific proof. This underscores the urgent necessity for well-designed, randomised clinical trials to address this gap and establish a more robust foundation of knowledge in this field.

CONSENT

It is not applicable.

ETHICAL APPROVAL

It is not applicable.

REFERENCES

1. Scrimalli L, Lomeo G. Endolaser soft lift: from theory to practice. *Aesthet. Med.* 2015;1(1):27-29.
2. biolitec AG: www.biolitec.com.
3. Longo L, Dell'Avanzato R, Longo D. ENDOLIFT® and multi-wavelength laser photobiomodulation: a randomised controlled trial study on 96 subjects, treating skin laxity of the lower third of the face. *Laser Ther.* 2022;29(2):115-120.
4. Scrimalli L, Lomeo G, Dell'Avanzato R, Crippa A. Endolaser soft-lift: a new approach on body contouring. Perspective and suggestions. *Eur. J. Aesth. Medicine and Dermatology.* 2013;3(3):86-90.
5. Sigova J, Kaliterna D, Abdelmaksoud A, Kamalska M. Progressive Lipodystrophy: topical laser treatment with Endolift® procedure using Eufoton® LASEmaR®1500 1470-nm wavelength. *J. Appl. Cosmetol.* 2023. 41(1):53-57. DOI: <https://doi.org/10.56609/jac.v41i1.66>.
6. Nilforoushzadeh MA, Heidari-Kharaji M, Fakhim T, Hanifnia A, Nouri M, Roohaninasab, M. Endolift® laser for jowl fat reduction: clinical evaluation and biometric measurement. *Lasers Med Sci.* 2022;37(5):2397-2401. DOI: 10.1007/s10103-021-03494-9.
7. Dell'Avanzato, R. & Dell'Avanzato, G. Endolift®: lunch-time laser lifting with no downtime. *Aesthetic & Anti-Aging Medicine World Congress.* Monte Carlo, Monaco, Sep/2021.
8. Moura AO, Borges FS, Moura ACR. Endolaser Treatment of Aesthetic Disorders: Clinical Experience of 4 Years. *Int J Med Sci Clin Invent.* 2023;10(5):6770-6782.
9. Center for Evidence-Based Medicine website. Levels of evidence. Available at: www.cebm.net. It was accessed on June 19, 2012.
10. Pereira C, Veiga N. Educação Para a Saúde Baseada em Evidências. *Millenium.* 2014. 46 (Janeiro/Junho). p. 107-136.
11. Guyatt G, Cairns J, Churchill D, Cook D, Haynes B, Hirsh J, et al. Evidence-Based Medicine Working Group. Evidence-based medicine. A new approach to teaching the practice of medicine. *JAMA.* 1992;268(17):2420-5. DOI: <https://doi.org/10.1001/jama.1992.03490170092032>.
12. McAlister FA, Laupacis A, Wells GA, Sackett DL. Users' Guides to the Medical Literature XIX. Applying Clinical Trial Results B. Guidelines for Determining Whether a Drug Is Exerting (More Than) a Class Effect. *JAMA.* 1999;282(14):1371-1377. DOI: <https://doi.org/10.1001/jama.282.14.1371>.
13. Melnyk BM. Implementing the Evidence-Based Practice (EBP) Competencies in Healthcare: A Practical Guide to Improving Quality, Safety, and Outcomes.; 2016. (Table 1.1, p. 11).

14. Leclère FM, Moreno-Moraga J, Alcolea JM, Casoli V, Trelles MA. Laser Assisted Lipolysis for Neck and Submental Remodeling in Rohrich Type IV Patient: Fact or Fiction?. *J. Cosmet. Laser Ther.* 2015;17(1):31-6. DOI: 10.3109/14764172.2014.968581.
15. Rohrich RJ, Narasimhan K. Long-term results in face lifting: observational results and evolution of technique. *Plast Reconstr Surg.* 2016;138(1):97-108.
16. Rohrich RJ, Ghavami A, Mojallal A. The five-step lower blepharoplasty: Blending the eyelid-cheek junction. *Plast Reconstr Surg.* 2011;128(3):775-83.
17. Rohrich RJ, Rios JL, Smith PD, Gutowski KA. Neck rejuvenation revisited. *Plast Reconstr Surg.* 2006;118:1251-1263.
18. Klein J. Tumescent technique. *Am J Cosmet Surg.* 1987;4:263-267.
19. Dias L, Almeida D, Borges FS, Bravin C, Cruz S, Caruso P, et al. The 1470 Nm Diode Laser Effectiveness in Facial Fat Reduction with the Endolifting Technique: Pilot Study. *Int J Med Sci Clin Invent.* 2023;10(6): 6788-6795. DOI: <https://doi.org/10.18535/ijmsci/v10i6.02>.
20. Longo L, Dell'Avanzato R, Longo D. ENDOLIFT® and multi-wavelength laser photobiomodulation: a randomised controlled trial study on 96 subjects, treating skin laxity of the lower third of the face. *Laser Ther.* 2022;29(2), 115-120.
21. Dell'Avanzato R. Endolift® the "lunch-time" laser lifting for the lower eyelids: Case report. *Laser Ther.* 2022;29(3):157-159.
22. Li K, Nicoli F, Cui C, Xi WJ, Al-Mousawi A, Zhang Z, et al. Treatment of hypertrophic scars and keloids using an intralesional 1470 nm bare-fibre diode laser: a novel efficient minimally-invasive technique. *Sci. Rep.* 2020;10: 21694. DOI: 10.1038/s41598-020-78738-9. ~
23. Trelles MA, Alcolea JM, Bonanad E, Moreno-Moraga J, Leclère FM. Laser-assisted liposuction for gynecomastia: statistical and ultrasound follow-up of the effects observed in skin retraction. *Cir. Plást. Liberolacionam.* 2013;39(4):425-438.
24. Heller L, Menashe S, Plonski L, Ofek A, Pozner JN. 1470-nm Radial fibre-assisted liposuction for body contouring and facial fat grafting. *J. Cosmet. Dermatol.* 2022;21:1514-1522.
25. Shapira E, Plonski L, Menashe S, Ofek A, Rosenthal A, Brambilla M, et al. High-Quality Lipoaspirate Following 1470-nm Radial Emitting Laser-Assisted Liposuction. *Ann Plast Surg.* 2022;89(4): e60-e69. DOI: <https://doi.org/10.1097/sap.0000000000003316>.
26. Pannier F, Rabe E, Rits J, Kadiss A, Maurins U. Endovenous laser ablation of great saphenous veins using a 1470 nm diode laser and the radial fibre – follow-up after six months. *Phlebology.* 2011;26:35-39.
27. Pappas AF, Christodoulou DK. A new minimally invasive treatment of pilonidal sinus disease with the use of a diode laser: a prospective large series of patients. *Colorectal Dis.* 2018;20(8):O207-O214. DOI: <https://doi.org/10.1111/codi.14285>.
28. Wollina U, Goldman A. The dual 980-nm and 1470-nm diode laser for vascular lesions *Dermatol Ther.* 2020;33(4): e13558, 2020. DOI: <https://doi.org/10.1111/dth.13558>.
29. Grossmann M, Sattler G, Pistner H, Oertel R, Richter K, Schinzel S, et al. Pharmacokinetics of Articaine Hydrochloride in Tumescent Local Anesthesia for Liposuction. *J Clin Pharmacol.* 2004;44:1282-1289.
30. Klein JA. Tumescent technique for local anesthesia improves safety in large-volume liposuction. *Plast Reconstr Surg.* 1993;92(6):1085-1098.
31. Tagliolatto S, Medeiros VB, Leite OG. Laserlipolysis: Update and literature review. *Surg Cosmet Dermatol.* 2012;4(2):164-174.
32. Mordon SR, Wassmer B, Reynaud JP, Zemmouri J. Mathematical modeling of laser lipolysis. *Biomed Eng Online.* 2008;7:10. DOI: <https://doi.org/10.1186%2F1475-925X-7-10>.
33. Nicoli F, Constantinides J, Ciudad P, Sapountzis S, Kiranantawat K, Lazzeri D. et al. Free lymph node flap transfer and laser-assisted liposuction: A combined technique for the treatment of moderate upper limb lymphedema. *Lasers Med Sci.* 2015;30(4):1377-1385.
34. Nilforoushzadeh MA, Fakhim T, Kharaji MG, Torkamaniha E, Nouri M, Roohaninasab M, et al. Endolift® laser an effective treatment modality for forehead wrinkles and frown lines. *J. Cosmet. Dermatol.* 2022;00:1-6.
35. Stewart, Nicholas et al. "Lasers and laser-like devices: part one." *The Australasian Journal of Dermatology* vol. 54,3 (2013): 173-83. doi:10.1111/ajd.12034
36. Insero, Giacomo et al. "The safe use of lasers in biomedicine: Principles of laser-matter interaction." *Journal of public health research* vol. 12,3 22799036231187077. 31 Jul. 2023, doi:10.1177/22799036231187077
37. S. T. C. P. L. (2023, April 11). Increasing Demand for Non-invasive Procedures Drives Growth in Medical Aesthetics Market. *Globe News Wire*. Retrieved August 20, 2023, from <https://www.globenewswire.com/en/news-release/2023/04/11/2644581/0/en/Increasing-Demand-for-Non-invasive-Procedures-Drives-Growth-in-Medical-Aesthetics-Market.html>
38. Kaub, Leon, and Christoph Schmitz. "Comparison of the Penetration Depth of 905 nm and 1064 nm Laser Light in Surface Layers of Biological Tissue Ex Vivo." *Biomedicines* vol. 11,5 1355. 4 May. 2023, doi:10.3390/biomedicines11051355

39. Cios, Aleksandra et al. "Effect of Different Wavelengths of Laser Irradiation on the Skin Cells." International journal of molecular sciences vol. 22,5 2437. 28 Feb. 2021, doi:10.3390/ijms22052437
40. Heidari Beigvand, Hazhir et al. "Assessment of Laser Effects on Skin Rejuvenation." Journal of Lasers in medical sciences vol. 11,2 (2020): 212-219. doi:10.34172/ijms.2020.35

Appendix I

Table 2. Rohrich Classification (Adapted: 15-17)

Grade	Description
I	No skin sagging, excellent skin tone, and lipodystrophy
II	Mild skin sagging with or without narrow bands of the medial platysma (<2 cm)
III	Moderate skin sagging with or without wider platysmal bands (>2 cm)
IV	Moderate to severe skin sagging and significant lipodystrophy