

Case report

Transmesenteric Internal Hernia Presenting with Strangulation of Bowel in Adult- A Case Report

Abstract

A congenital transmesenteric hernia is a rare condition characterized by the presence of a congenital defect in the mesentery, allowing bowel loops to herniate through the mesenteric defect. This herniation can lead to bowel strangulation and small bowel obstruction. While more frequently observed in the paediatric population, it is exceptionally uncommon in adults. Overall, internal hernias have an incidence of 0.2 to 0.9%, and congenital transmesenteric hernias make up only 5-10% of all internal hernias. As of May 2016, there were only 18 reported cases of adult congenital transmesenteric hernias in the medical literature. This condition presents with recurrent abdominal pain or acute intestinal obstruction, often accompanied by a mortality rate exceeding 50%. Early intervention and surgical treatment are crucial to prevent severe morbidity and mortality. We present the case of a 21-year-old female who complained of severe abdominal pain, constipation, and two days of bilious vomiting. Ultrasonography and plain X-rays indicated acute intestinal obstruction. An emergent laparotomy revealed a transmesenteric internal hernia with strangulated small bowel. Fortunately, there was no evidence of gangrene. We successfully untwisted the small bowel and reduced it through the large congenital terminal mesenteric defect. A simple repair of the mesenteric defect was performed.

Keywords

Congenital transmesenteric hernia, internal hernia, mesenteric defect.

Introduction

Congenital transmesenteric internal hernia is an exceptionally rare condition, and all cases typically manifest as acute intestinal obstruction. Early diagnosis and explorative laparotomy are imperative to mitigate the associated high mortality and morbidity. Nearly all documented cases are identified during surgery. (2,3)

Internal hernias leading to small bowel obstruction account for 5-10% of all cases, with these hernias being either congenital or acquired. Acquired hernias are more common and often occur following procedures like gastric bypass surgery or abdominal trauma. Congenital internal abdominal hernias can be categorized as follows: (1,2,3)

1. Para-duodenal hernias - 20-50%
2. Foramen of Winslow hernias - 8%
3. Paracecal hernias - 6%
4. Inter-sigmoid hernias - 5%
5. Congenital transmesenteric hernias - 5%
6. Trans-omental hernias - 1.3%
7. Supra-vesical or bowel ligaments hernias - 4-7%

Transmesenteric hernias are the most prevalent internal hernias in children, primarily attributed to a defect or window in the mesentery of the terminal small bowel (71%) and, to a lesser extent, mesocolic defects (26%). Whereas cases in adults are rarely reported. (2,3)

Case Report

On August 2, 2015, a 21-year-old female was admitted to our medical centre with complaints of severe abdominal pain, constipation, and vomiting that had been ongoing for two days. Her abdominal ultrasonography and plain abdominal x-ray revealed signs of acute intestinal obstruction.

Importantly, there was no history of abdominal trauma or prior abdominal surgery. Upon physical examination, abdominal distension was observed, accompanied by tenderness in the right iliac fossa and exaggerated bowel sounds. All blood laboratory investigations, including kidney function tests, returned normal results. Based on these findings, the provisional preoperative diagnosis was acute intestinal obstruction.

An explorative laparotomy was performed, through a mid-line incision. During the procedure, serous fluid was aspirated, and a mass of small bowel was identified in the right iliac fossa. By untwisting the bowel, a herniated segment of small bowel was gently extracted through a large defect located within the terminal mesentery. To our utter surprise, the large oval shaped defect of measured approximately 10x5 cm in size, situated about 20 cm proximal to the ileocecal junction. Vascular arcade was seen all around the defect very near to free edge. After the successful reduction of the internal hernia, the small bowel appeared normal in colour, and there were no signs of bowel gangrene. Consequently, the mesenteric defect was meticulously repaired using interrupted 2.0 silk sutures. No other anomalies or malformations of the small bowel were identified within the abdominal cavity. The abdomen was closed in layers, with the placement of a drainage tube in the pelvic cavity. The postoperative period was uneventful, and the drain was removed on the fourth day following surgery. The patient was discharged eight days after the surgical intervention. (Fig 1-6)

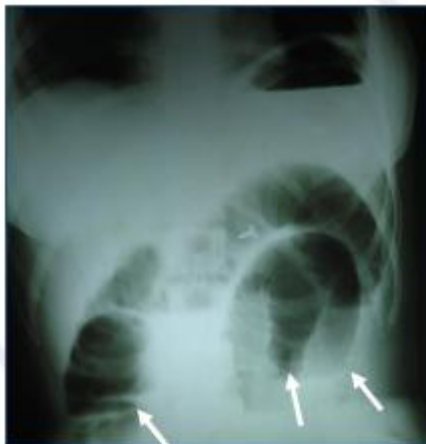

Fig-1 Plain Abdomen x-ray showing multiple fluid levels

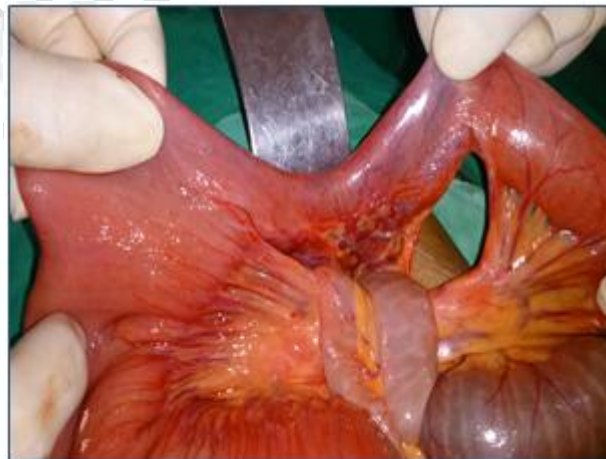

Fig-2 Intraoperative photograph showing a transmesenteric hernia

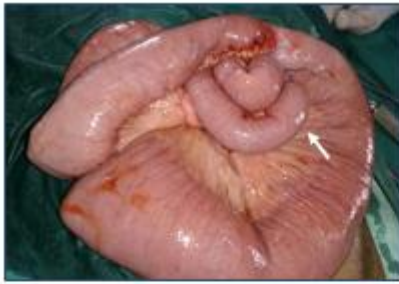

Fig-3 Intraoperative photograph showing strangulation of bowel in transmesenteric hernia

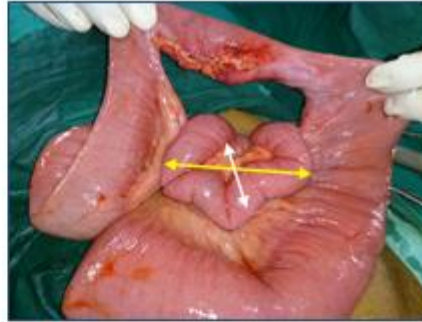


Fig-4 Intraoperative photograph showing strangulation of bowel with transmesenteric defect of size 10x5 cm

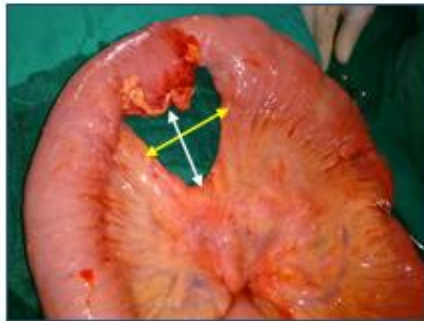


Fig-5 Intraoperative photograph showing transmesenteric defect of size 10x5 cm

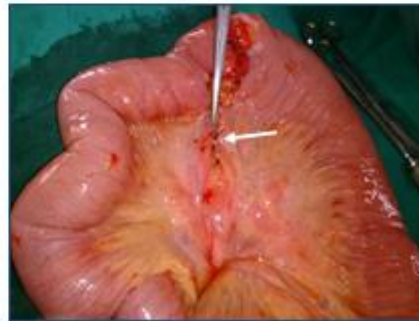

Fig-6 Intraoperative photograph showing transmesenteric defect sutured with 2.0 silk

Discussion

In 1936, Rokitansky was the first to report cases of transmesenteric hernia during autopsies. Until May 2016, only 18 cases of bowel obstruction due to congenital mesenteric internal hernias had been documented in the published literature, involving 7 males and 11 females. Transmesenteric hernia is an unusual cause of bowel obstruction, especially in children. In 1885, Treves described a region of the mesentery near the terminal ileum encircled by the ileocolic artery and its major branches. This area, known as Treves' fold, lacks fat, blood vessels, and lymph nodes, making it highly susceptible to transmesenteric hernias. (2,5,7)

Internal hernias can be either congenital or acquired, with most being para-duodenal (53%). Other types of internal hernias are exceedingly rare. A congenital transmesenteric hernia is a rare defect in the mesentery of the small bowel. Although internal hernias have an overall incidence of less than 1%, they constitute 5-10% of all hernias, making them a rare cause of intestinal obstruction. If strangulation occurs and goes untreated, the risk of mortality is over 50%. In adult patients, mesenteric defects are mostly the result of trauma or previous gastric bypass surgery. (2,3)

Diagnosing a congenital transmesenteric hernia preoperatively is challenging. It has been reported that a CT scan can suggest the presence of an internal hernia. The most critical diagnostic method, however, remains abdominal CT, where the clustering of small bowel loops and abnormalities in the mesenteric vessels serve as helpful findings. Ultimately, surgical intervention is required to confirm the diagnosis. (2,4,5)

Conclusion

Congenital Transmesenteric hernia stands as an uncommon etiology for small bowel obstruction, and its preoperative diagnosis poses a considerable challenge. In cases of transmesenteric hernias, an emergency laparotomy is deemed mandatory. The risk of small bowel incarceration or strangulation is notably high, resulting in elevated rates of mortality and morbidity. Therefore, early diagnosis followed by an exploratory laparotomy should be regarded as the gold standard approach to treatment.

References

1. Lingegowda AP, Amit B, Pillai PR, Chandrayya R. Congenital Transmesenteric Hernia - A Rare Presentation. *J Indian Assoc Pediatr Surg.* 2023 Jan-Feb;28(1):72-74. doi: 10.4103/jiaps.jiaps_73_22. Epub 2022 Dec 12. PMID: 36910300; PMCID: PMC9997596.
2. Kumar, Naveen & Ansari, Abu. (2016). Congenital adult transmesenteric hernia as small bowel obstruction. *Hellenic Journal of Surgery.* 88. 238-244. 10.1007/s13126-016-0325-7.
3. Vallumsetla R, Govind Rao N. Congenital transmesenteric internal hernia - A case report with literature review. *Indian J Surg.* 2010 Jun;72(3):268-70. doi: 10.1007/s12262-010-0065-9. Epub 2010 Aug 26. PMID: 23133264; PMCID: PMC3452639.
4. Andreia Felizes, Mariana Morgado, Marta Janeiro, Miroslava Gonçalves, Congenital transmesenteric hernia presenting as neonatal ascites, *Journal of Pediatric Surgery Case*
<https://doi.org/10.1016/j.epsc.2017.09.014>.
5. Ryuta Saka, Takashi Sasaki, Keigo Nara, Toshimichi Hasegawa, Satoko Nose, Hiroomi Okuyama, Takaharu Oue, Congenital Treves' field transmesenteric hernia in children: A case series and literature review, *Journal of Pediatric Surgery Case Reports*,
<https://doi.org/10.1016/j.epsc.2015.06.013>.
6. G Umaparan and others, Congenital trans-mesenteric herniation: a rare cause of small intestine strangulation in adults, *Journal of Surgical Case Reports*, Volume 2012, Issue 11, November 2012, rjs003, <https://doi.org/10.1093/jscr/rjs003>
7. Kelahan, L., Menias, C.O. & Chow, L. A review of internal hernias related to congenital peritoneal fossae and apertures. *AbdomRadiol* 46, 1825–1836 (2021).
<https://doi.org/10.1007/s00261-020-02829-4>
8. Orhan Kalaycı , Ahmet Yazıcı, Mustafa Yandı, Serdar Topaloğlu, Strangulated congenital mesenteric hernia: a case report, *Ulus Travma Acil Cerrahi Derg*, September 2015, Vol. 21, No.
9. Bahar A, Pooria F, Alborz S. Transmesenteric internal hernia with sac and volvulus in a 7-month infant with multiple and recurrent episodes of abdominal pain and vomiting: A case report. *J Gastroenterol Dig Dis.* 2018;3(1):14-16.
10. Fitzgibbons RJ, Greenburg AG, Nyhus LM. Nyhus and Condon's hernia. Philadelphia: Lippincott Williams & Wilkins; 2002. pp. 453–65