

Cryptogenic Organizing Pneumonia

ABSTRACT

The lung cancer is one of the most important health problems all over the world. Early diagnosis is life-saving for patients because it is an aggressive cancer. Cryptogenic organizing pneumonia is defined as a form of idiopathic interstitial pneumonia stem from pulmonary reactions against injuries. An interesting case that mimics cancer radiologically will be presented in this study.

A 51-year-old male patient admitted to the our clinic with cough and sputum complaints. No pathological finding was detected and, there was no obvious pathology on chest X-ray. A solitary pulmonary nodule of 10 mm in size was detected in the lateral aspect of the left upper lobe of the left lung on CT. Solitary pulmonary nodule was reported as malignancy border involvement in FDG-PET. The nodule was excised completely with the help of VATS. The pathology of the patient was reported as cryptogenic organizing pneumonia.

Cryptogenic organizing pneumonia mimics many lung pathologies, most notably lung cancer. According to the symptoms and signs, clinicians should definitely rule out lung cancer if there is suspicion. Because a late diagnosis or delayed treatment of lung cancer reduces the life expectancy.

Keywords: cancer, cryptogenic, lung, pneumonia, surgery

1.INTRODUCTION

The lung cancer is one of the most important health problems all over the world. It is the second leading cause of cancer-related death [1]. In patients admitted with respiratory symptoms, pathological findings can be detected radiologically. Early diagnosis is life-saving for patients because it is an aggressive cancer. Therefore, radiological pathological findings are very significant to physicians. Cryptogenic organizing pneumonia (COP) is defined as a form of idiopathic interstitial pneumonia stem from pulmonary reactions against injuries [2]. Interstitial pneumonia, which also causes lung parenchymal destruction, is aggressive and has

a poor prognosis [3]. While pneumonias usually respond to antibiotics, these can also be resistant. An interesting case that mimics cancer radiologically will be presented in this study.

2.PRESENTATION OF CASE

A 51-year-old male patient admitted to the our clinic with cough and sputum complaints. His smoking history was 25 packs-year and no comorbidity. No pathological finding was detected in the physical examination. There was no obvious pathology on chest X-ray. Computed tomography (CT) of the thorax was performed because the complaints persisted despite using Levofloxacin 500 mg/day for 14 days before. A solitary pulmonary nodule of 10 mm in size was detected in the lateral aspect of the left upper lobe of the left lung on CT (Figure 1).

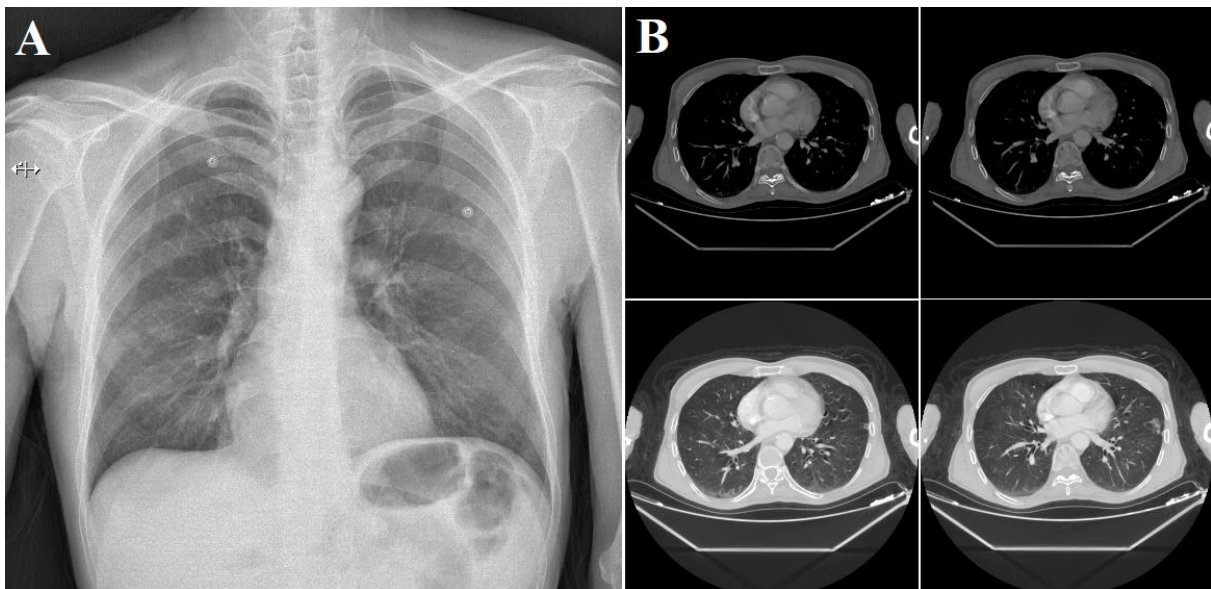


Figure 1.A. Preoperative Chest X-ray B. Images of preoperative CT

The patient's laboratory parameters were normal. Fluorodeoxy glucose positron emission tomography (FDG-PET) was performed for possible tumor exclusion. Solitary pulmonary nodule was reported as malignancy border involvement in FDG-PET. Bronchoscopy was considered normal. Bacterial culture of bronchoalveolar lavage (BAL) was non-growth and acid resistant bacteria (ARB) was as negative. Surgical excision was planned because it was not suitable to transthoracic biopsy. The nodule was excised completely with video-assisted thoracoscopic surgery (VATS). The pathology of the patient, who was discharged on the 3rd postoperative day, was reported as cryptogenic organizing pneumonia. The patient had no respiratory complaints at the 3rd month follow-up (Figure 2).

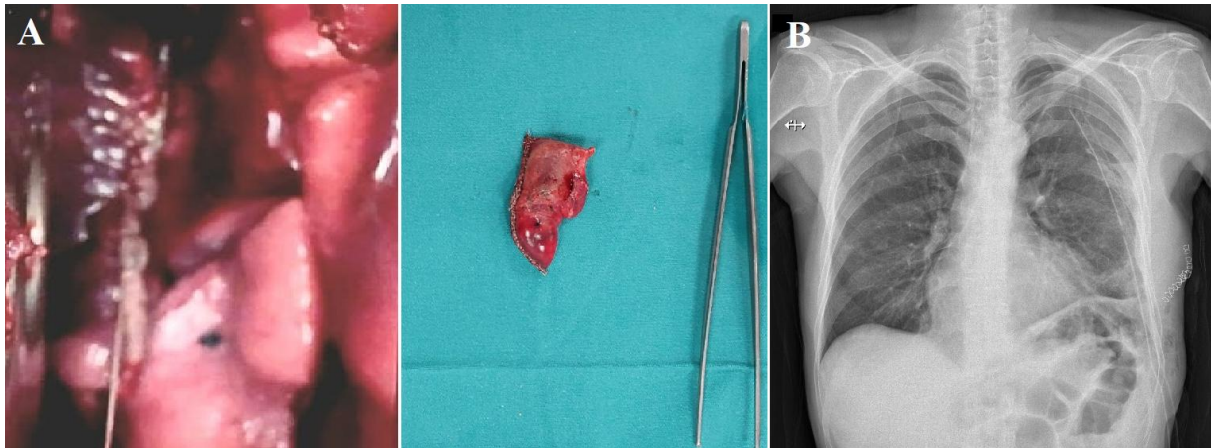


Figure 2.A. Images of exploration of the thorax and nodular lesion B. Postoperative chest X-ray

3.DICCUSSION

Organizing Pneumonia is a clinical radiological and histological pattern characterized by granulation tissue in terminal or respiratory bronchioles and alveoli. This disease may be secondary to non-pulmonary pathologies such as infections, drug toxicity, radiotherapy, autoimmune diseases and oncological conditions [4,5]. It is defined as "cryptogenic" if it is found not to be associated with pulmonary or extrapulmonary pathologies. In other words, COP is considered idiopathic. COP is difficult and time consuming to diagnose because it can mimic many pneumopathological diseases. That's why it can be diagnosed by radiologists and clinicians by evaluating it with a focus on excluding other diseases [6].

One of the most important diseases that its mimics is lung cancer. Lung cancer is known to be very serious and deadly, both by humans and in the literature. In fact, it is the most important disease that should be excluded in lung pathologies. Therefore, even in a simple lung infection, if there is no response to antibiotics or if the lesion does not regress, lung cancer should be suspected. For example, there was no response to antibiotics in this case. Antibiotic sensitive to sputum, tracheal aspirate or BAL bacterial culture is of course the most perfect method. The most common microorganisms in community-acquired pneumonia were reported as S.Pneumonia, M.Pneumonia, C.Pneumonia, H.Influenza and K.Pneumonia. Sometimes empirical antibiotics are preferred because there is not enough time to wait for the culture result and sometimes there is no growth in the culture. In scientific studies, antibiotics such as amoxicillin, ampicillin, co-amoxiclav, penicillin G, cefaclor, cefuroxime, cefotaxime, ceftriaxone, azithromycin, clarithromycin are recommended in the treatment of mild and moderate pneumonia. In severe cases, levofloxacin and moxifloxacin are recommended in

addition to these antibiotics [7,8]. In addition, antibiotics such as piperacillin/tazobactam, cefoperazone/sulbactam, imipenem, meropenem, vancomycin, teicoplanin and linezolid can be used depending on the type of bacteria. Our case used completed levofloxacin despite incomplete amoxicillin/clavulanate treatment. However, there was no regression in both clinical and radiological findings. Laboratory parameters and pulmonary function tests were normal. Lung cancer was suspected after a pathological nodular lesion was detected in the left upper lobe on CT. Bronchoscopic examination was normal, there was no growth in BAL culture and ARB was negative. Already clinical findings were not compatible with tuberculosis. Further investigation was necessary to rule out possible lung cancer. This is why FDG PET was performed. A biopsy was planned after the Standardized Intake Value (SUV) was reported as consistent with malignancy. Exclusion of lung cancer was essential. Minimally invasive method was preferred and the lesion was excised completely. Pathology was reported as cryptogenic organizing pneumonia.

Early diagnosis of lung cancer is an accepted approach. Without a scan or if there are no severe symptoms, the diagnosis is usually not made until the advanced stages [9]. Therefore, suspicious findings of the lung are alarming for physicians. While cough and shortness of breath are the more often symptoms, hemoptysis is the most serious in lung cancer [10]. Our case had cough and sputum complaints. Despite the absence of a serious symptom of hemoptysis, the complaint of a long-standing cough was significant. The absence of radiological and clinical improvement though the empirical treatments required further investigations. According to the symptoms and signs, clinicians should definitely rule out lung cancer if there is suspicion. Because a late diagnosis or delayed **treatment of the lung cancer** reduces the life expectancy.

4.CONCLUSION

The lung cancer is one of the more significant health problems all over the world. Early diagnosis is life-saving for patients because it is an aggressive cancer. Cryptogenic organizing pneumonia is defined as a form of idiopathic interstitial pneumonia stem from pulmonary reactions against injuries. Cryptogenic organizing pneumonia mimics many lung pathologies, most notably lung cancer. According to the symptoms and signs, clinicians should definitely rule out lung cancer if there is suspicion. Because a late diagnosis or delayed treatment of lung cancer reduces **the life** expectancy.

CONSENT AND ETHICAL APPROVAL

Informed consent form was obtained from the patient himself. The patient has permission to publish. As per international standard or university standard written ethical approval has been collected and preserved by the author(s).

ABBREVIATIONS

ARB: Acid resistant bacteria

BAL: Bronchoalveolar lavage

COP: Cryptogenic organizing pneumonia

CT: Computed tomography

FDG-PET: Fluorodeoxy glucose positron emission tomography

VATS: Video-assisted thoracoscopic surgery

REFERENCES

1. Ibodeng G-O, Uche I.N, Mokuia R, et al. A snapshot of lung cancer: where are we now?-a narrative review. *Ann Transl Med.* 2023 Mar 31;11(6):261.
2. Radzikowska E, Fijolek J. Update on cryptogenic organizing pneumonia. *Front Med (Lausanne)* 2023;10:1146782.
3. Bayrakçı O. Prognosis of Covid-19 according to pneumonia types. *Asian J Res Inf Dis* 2022;9(1):8-12.
4. Cordier J.-F. Organising pneumonia. *Thorax* 2000;55:318–328.
5. Sambataro D, Sambataro G. Patients with Interstitial lung disease secondary to autoimmune diseases: How to recognize them? *Diagnostics* 2020;10:208.
6. Tiralongo F, Palermo M, Distefano G, Vancheri A et al. Cryptogenic Organizing Pneumonia: Evolution of Morphological Patterns Assessed by HRCT. *Diagnostics* 2020;10(5):262.
7. Bayrakçı O. The Effect of levofloxacin combinations on CRP decrease in SARS CoV-2 pneumonia. *J Pharm Res Int* 2022;34(27A):71-76.
8. Chou C-C, Shen C-F, Chen S-J, Chen H-M et al. Recommendations and guidelines for the treatment of pneumonia in Taiwan. *J Microbiol Immunol and Infect.* 2019;52(1):172-199.
9. Gharraf H.S, Mehana S.M, ElNagar M.A. Role of CT in differentiation between subtypes of lung cancer; is it possible? *The Egyptian J Bronchol* 2020;28:14.
10. Latimer X KM. Lung cancer: clinical presentation and diagnosis. *FP Essentials* 2018;464:23-26.