

CD117 positive cells significantly exist in immune-targeted follicles of Alopecia Areata

ABSTRACT

Aim: Studying the expression of CD117 (c-kit) in hair follicles of Alopecia Areata (AA).

Place and Duration of Study: Department of dermatology and venereology, Minia university hospital, Egypt and Department of Pathology and laboratory medicine, Western University, Ontario, Canada, between July 2022 and July 2023.

Methodology: This study included 16 AA patients, Skin biopsies were obtained from each participant and stained with hematoxylin and eosin (H&E) and CD117 immune stain, all hair follicles are numbered and evaluated for presence of infiltrates and expression of CD117. Correlation was done between existence of perifollicular inflammatory infiltrate and expression of CD117 in all hair follicles in cross section.

Results: Within 82 follicles examined, CD117 was significantly expressed in immune targeted follicles. The median of positive expression was 2 with interquartile range (IQR) (1-3), the expression decreased in non-infiltrated follicles the median was 1 with IQR (0-1.8) with statistically significant difference ($P = 0.001$).

Conclusion: CD117 is significantly expressed in hair follicles of AA and is correlated to the immune cytotoxic infiltrates and possibly to the pathogenesis of alopecia areata.

Keywords: [CD117 - Alopecia Areata – hair follicle-immunohistochemistry].

1. INTRODUCTION

AA is a disorder that results in non-scarring hair loss. The main theory of AA pathogenesis pointed to autoimmune mechanism led to the destruction of the hair follicle [1]. The hair follicle is made up of cells from the keratinocytes and melanocytes, which are responsible for hair development and color, and they express the c-kit [2]. C-kit may be responsible for hair growth as well as hair pigmentation [3]. Although humoral immune responses against tyrosinase, TRP-1, TRP-2, gp100 and Melan-A were not demonstrated in patients with AA, yet, it's been known for a while that certain peptides related to melanogenesis are the autoantigens that are targeted by the immune system in AA [4]. It is known that the prevalence of alopecia areata is significantly increased in individuals with dark brown hair, while blond individuals were less likely to be diagnosed with the condition [5]. The involvement of c-kit in human AA has not yet been fully understood. To address this issue, we performed histopathological and immunohistochemical, analysis in scalp biopsy specimens, focusing on c-kit.

2. MATERIAL AND METHODS

1- Selection of study cases

The present study included 16 patients with AA attending the Dermatology Out-patient Clinic of Minia University Hospital **people that already started treatment were excluded** .

1.1 Clinical data

- Full history was taken from all patients including: personal history (age, sex and occupation), present history (onset, course and duration of the disease) history of other autoimmune diseases, past history (previous disease or medications) and family history of AA.
- All patients provided an informed consent (for subjects under 18 years of age, parents were asked to provide signatures on the consent forms).
- Approval of ethical committee was obtained.

1.2 Skin biopsy

- Skin biopsies were taken from all patients from the edge of AA patch for histological and immunohistochemical examinations.
- Skin biopsy specimens were obtained using 3 mm punches after infiltration of the skin with local anesthesia containing 2% lidocaine (Debocaine, Sigma-Tec).
- Each biopsy was immediately fixed in 10% formalin, routinely processed and embedded in a paraffin block. Transverse section was done for each biopsy 1 mm above the dermal subcutaneous junction [6].

1.3 Histological examination

The presence and density of any detected perifollicular lymphocytic infiltrate for each follicle was evaluated either with significant perifollicular mononuclear infiltrate or without.

2- Immunohistochemical examination

2.1 staining methods

Formalin-fixed, paraffin-embedded tissue of the skin biopsy specimens underwent the immunoperoxidase staining of CD117 antibody at London Health sciences Centre/Western University, Ontario, Canada. All tissue sections underwent a pretreatment procedure resulting in deparaffinization, rehydration, and Heat Induced Epitope Retrieval (HIER) through Pretreatment procedure (PT) Link[®] technology. Dako Autostainer Plus[®] instrument and standardized staining procedure (London Laboratory Services Group, London, ON) added 150 µL EnVision™ FLEX Peroxidase-Blocking Reagent, cd117 antibody, 150 µL EnVision™ FLEX Mouse (LINKER), 150 µL EnVision™ FLEX/Horse Radish Peroxidase and 150 µL diaminobenzene (DAB) to the tissue sections. Each run through the procedure, which contained one positive control tissue. Tissues were exposed to c-kit antibody.

The slides were examined and scanned using Aperio glass slide scanner at Department of Pathology and laboratory Medicine at Western University. The ScanScope scans microscope slides at 20×, 40× to a digital image that can be viewed with software that simulates the use of a light microscope. The files can be viewed and manipulated using a

free software program called ImageScope. Representative photographs were captured using Aperio ScanScope™ technology at equivalent exposure times.

2.2 Assessment of the antibody staining

Follicles examined in sections according to Trautman et al [7]. And were scored objectively from 0 to +3 as follow: 0 (no cells were immune-stained), 1 (from 1 to 5 positive immune-stained cells), 2 (from 6 to 10 positive cells) and 3 (more than 10 positive cells)

3- Statistical analysis

Data analysis was carried out using the IBM SPSS version 25 statistical package software. Data were expressed as median (IQR) for non-parametric quantitative data, in addition to both number and percentage for qualitative data. Analyses were done between the two groups for non-parametric quantitative data using the **Mann-Whitney test** between each two groups; Correlation between variables was done using **Spearman's correlation**. **A P-value less than 0.05** was considered statistically significant.

3. RESULTS AND DISCUSSION:

The current study was conducted on 16 patients with AA attending the Dermatology out-patient clinic, Minia University Hospital, Minia, Egypt. Of these patients 6 (37.5%) were males and 10 (62.5%) were females. Their age ranged from 5 to 40 years with a mean± SD (19.6±10.2). The duration of the disease ranged from 5 days to 36 months with a mean±SD (5.5±8.9). No family history was present in all patients. As regard disease activity (with hair pulling test), 7 (43.8%) were active and 9 (56.3%) were stable. One case gave history of vitiligo on the same AA lesion (Table 1).

Histopathologic examination using routine H&E stain of all hair follicles revealed that 50 follicles (61%) had significant mononuclear inflammatory infiltrate (Figure 1,2) and 32 follicles (39%) had insignificant infiltrate.

Within the 82 follicles examined for 16 AA cases 60 follicles showed positive staining. Positive cells ranged from 1 to 24 per follicle. CD117 was significantly expressed in immune targeted follicles (Figure 3,4). The median of positive expression was 2 with inter quartile range (IQR) (1-3), the expression decreased in non-infiltrated follicles (Figure 5) the median was 1 with IQR (0-1.8) with statistically significant difference (P = 0.001) (Table 2). Expression total score was 123 with average of 1.2 using (0 to +3) scoring system.

Table 1. Demographic and clinical Data of all patients.

		Descriptive statistics N=16
--	--	--

Age	<i>mean±SD</i>	(19.56±10.17)
	<i>IQR</i>	(9.5-27)
Sex	<i>Female</i>	10(62.5%)
	<i>Male</i>	6(37.5%)
Activity (hair pull test)	<i>Stable</i>	7(43.8%)
	<i>Active</i>	9(56.3%)
History of other autoimmune diseases	<i>-Ve</i>	15(93.8%)
	<i>+Ve</i>	1(6.3%)
Family history of autoimmune diseases	<i>-Ve</i>	16(100%)
	<i>+Ve</i>	0(0%)
Duration	<i>mean±SD</i>	(5.54±8.9)
	<i>IQR</i>	(1-4.8)

Table 2. CD117 comparative expression in infiltrated and non-infiltrated follicles according to Mann-Whitney test.

		Perifollicular mononuclear inflammatory infiltrate		P value
		No	Yes	
		N=32	N=50	
CD117	<i>Median</i>	1	2	0.001*
	<i>IQR</i>	(0-1.8)	(1-3)	

***Significant level at P value < 0.05**

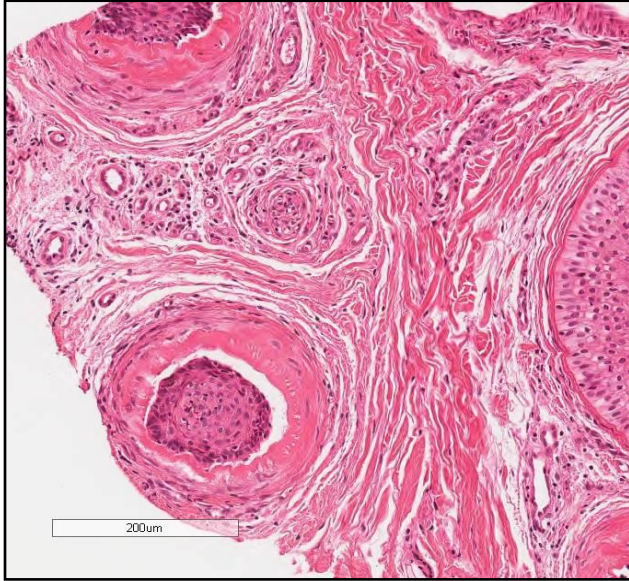

Fig.1 H&E staining of AA specimen showing significant perifollicular mononuclear inflammatory infiltrate around several follicles in different stages (100X) in cross section.

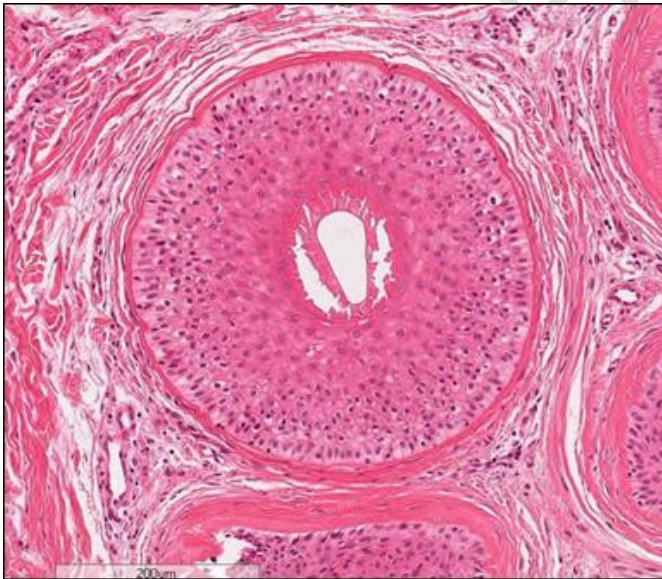


Fig.2 H&E stain of AA specimen showing significant perifollicular mononuclear inflammatory infiltrate around anagen follicle (100X). in cross section.

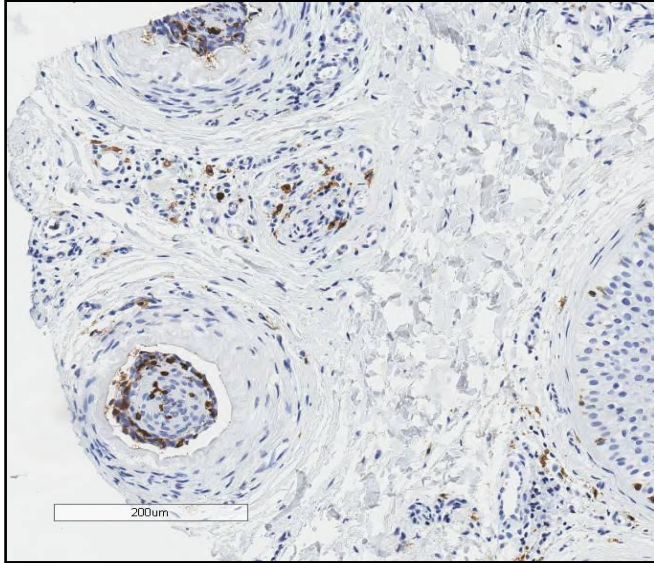


Fig.3 CD117 immune stain of AA specimen showing marked expression in immune targeted follicle (100x) same follicles of figure.1

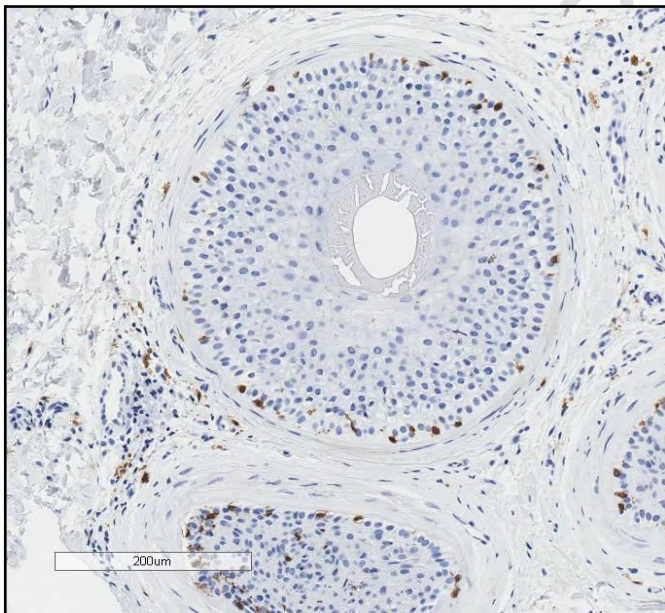


Fig.4 CD117 immune stain of AA specimen showing marked expression in immune targeted follicle in cross section (100x) same follicles of figure.2

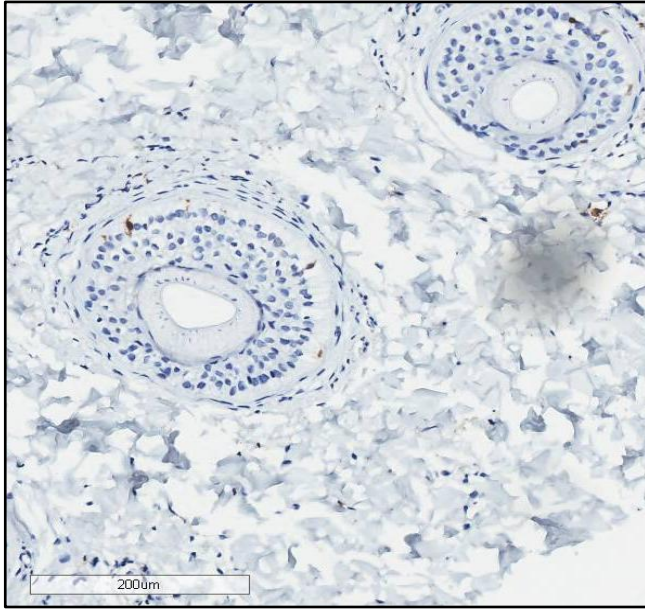


Fig.5 CD117 immune stain of AA specimen showing decreased expression with insignificant perifollicular inflammatory infiltrate in cross section (100x)

Alopecia Areata is an autoimmune condition that is characterized by patchy loss of hair on the scalp or other hair-bearing surfaces [8]. New insights have been introduced into the etiopathogenesis of AA, including genetics, immunology, oxidative stress, microbiome, allergy, microbiota, epigenetics, and other factors [9]. The best way to think about AA is to consider it as autoimmune disease that's specific to hair follicles and triggered by CD8+T cells [10]. The key role of cytotoxic CD8+ cells in human AA was first demonstrated by Gilhar et al [11] and has been confirmed in a mouse model of AA, in which the JAK pathway in CD8+ cells was identified as an important target for pharmacological intervention [12].

Until now, the specific autoantigen responsible for AA has not been identified [13]. It is established that gray/white hair is usually spared in AA lesions [14]. Concurrently, the question requires answer: Why are the gray hairs in AA often don't fall out? The interesting clinical phenomenon led us to hypothesize that follicular melanocytes may be involved in the pathogenesis of AA. Paus proposed that melanocyte metabolites could be antigenic and serve as the primary cause of autoimmune attacks [15].

Several melanocyte subpopulations had been identified; these melanocytes are predominantly located in the infundibulum, hair follicle bulge, outer root sheath, and the hair bulb [16]. Activated melanocytes are present in at least two hair follicle sites, including the hair bulb and infundibulum. The melanotic melanocytes in the hair bulb matrix above the dermal papilla are the only subpopulation to produce pigment for the hair shaft. In addition to activated melanocytes, undifferentiated or poorly differentiated amelanotic pigmented cells

could be identified in the hair follicle bulge (melanocyte stem cells reservoir), outer root sheath [13].

There are some conflicting results about the role of melanocytes in AA. Some authors reported that melanocyte initiate autoimmunity in AA [13-15-17], and according to others, Trichohyalin is a potential major autoantigen [18].

The histologic features of AA vary according to the disease stage. In acute, active disease there is peribulbar infiltration of CD8+ and CD4+ T lymphocytes surrounding anagen follicles, with extension into the hair matrix keratinocytes. These lymphocytes cause disorganization and apoptosis of hair matrix cells [19].

In the context of AA, hair follicles bulb immune privilege is most relevant for understanding disease pathogenesis, given the peri-and intra-follicular inflammation is primarily focused on the bulb and lower follicle [20].

If the melanocytes are the targeted element in the hair bulb, then the question will be why lymphocytes did not attack the epidermal ones. Several publications by Desmond Tobin pointed to the difference in characters and antigenicity of melanocytes regarding their position either epidermal or follicular and further differences exist between bulbar melanocytes which is the main targeted area in AA and other melanocytes in outer root sheath or the bulge [16].

The c-kit receptor is a transmembrane protein with tyrosine kinase activity encoded by the oncogene c-kit. It is an important member of type III receptor tyrosine kinase family and acts as a receptor for stem cell factor. The binding of stem cell factor to c-kit transactivates the receptor tyrosine kinase to activate melanogenesis [2].

Within the 82 follicles examined for AA cases 60 cases showed positive staining. The statistical data obtained showed significant positive correlation between expression of c-kit and existence of the mononuclear infiltrate (P value 0.001), which could demonstrate the relevance of melanocytic antigens in the induction of AA, and also explain why white hairs are not affected in the disease. Our results are in agreement with that of Mourad et al [21] who reported an increase in count of c-kit-positive cells in AA than in normal and a positive correlation between the intensity and count of c-kit positive cells per hair follicle in relation to the severity of alopecia. Also, Mohanan et al [22].and Ashrafuzzaman et al [23] documented a significant increase in the expression of CD117 in anagen and catagen follicles among AA patients.

4. CONCLUSION

We conclude that the stem cell factor receptor c-kit is significantly expressed in hair follicles in alopecia areata and its density is correlated to the immune cytotoxic infiltrates. Subsequently, melanocytes could be implicated in the pathogenesis of alopecia areata.

CONSENT

As per international standard or university standard, patients' written consent has been collected and preserved by the authors.

ETHICAL APPROVAL

As per international standard or university standard written ethical approval has been collected and preserved by the authors.

Disclaimer

This paper is an extended version of a **preprint** document of the same author.

The **preprint** document is available in this link: <https://www.researchsquare.com/article/rs-3278271/v1>

[As per journal policy, preprint article can be published as a journal article, provided it is not published in any other journal]

REFERENCES

- 1-Rajabi F, Drake LA, Senna MM, Rezaei N. Alopecia areata: a review of disease pathogenesis. *Br J Dermatol.* 2018;179(5):1033-1048. doi:10.1111/bjd.16808.
- 2-Cruse G, Metcalfe DD, Olivera A. Functional deregulation of KIT: link to mast cell proliferative diseases and other neoplasms. *Immunol Allergy Clin North Am.* 2014;34(2):219-237. doi:10.1016/j.iac.2014.01.002.
- 3-Galanis A, Levis M. Inhibition of c-Kit by tyrosine kinase inhibitors. *Haematologica.* 2015;100(3):e77-e79. doi:10.3324/haematol.2014.117028.
- 4- Kemp EH, Sandhu HK, Weetman AP, McDonagh AJ. Demonstration of autoantibodies against tyrosine hydroxylase in patients with alopecia areata. *Br J Dermatol.* 2011;165(6):1236-1243. doi:10.1111/j.1365-2133.2011.10597.x
- 5- Yousaf A, Lee J, Fang W, Kolodney MS. Notice of Retraction. Yousaf A et al. Association Between Alopecia Areata and Natural Hair Color Among White Individuals. *JAMA Dermatol.* 2021;157(8):1007-1008. doi:10.1001/jamadermatol.2021.1832.

- 6- Headington JT. Transverse microscopic anatomy of the human scalp. A basis for a morphometric approach to disorders of the hair follicle. *Arch Dermatol.* 1984;120(4):449-456.
- 7-Trautman S, Thompson M, Roberts J, Thompson CT. Melanocytes: a possible autoimmune target in alopecia areata. *J Am Acad Dermatol.* 2009;61(3):529-530. doi:10.1016/j.jaad.2009.01.017.
- 8- Zhou C, Li X, Wang C, Zhang J. Alopecia Areata: an Update on Etiopathogenesis, Diagnosis, and Management. *Clin Rev Allergy Immunol.* 2021;61(3):403-423. doi:10.1007/s12016-021-08883-0.
- 9- Simakou T, Butcher JP, Reid S, Henriquez FL. Alopecia areata: A multifactorial autoimmune condition. *J Autoimmun.* 2019;98:74-85. doi:10.1016/j.jaut.2018.12.001.
- 10-Paus R, Bulfone-Paus S, Bertolini M. Hair Follicle Immune Privilege Revisited: The Key to Alopecia Areata Management. *J Investig Dermatol Symp Proc.* 2018;19(1):S12-S17. doi:10.1016/j.jisp.2017.10.014.
- 11- Gilhar A, Ullmann Y, Berkutski T, Assy B, Kalish RS. Autoimmune hair loss (alopecia areata) transferred by T lymphocytes to human scalp explants on SCID mice. *J Clin Invest.* 1998;101(1):62-67. doi:10.1172/JCI551.
- 12- Xing L, Dai Z, Jabbari A, et al. Alopecia areata is driven by cytotoxic T lymphocytes and is reversed by JAK inhibition. *Nat Med.* 2014;20(9):1043-1049. doi:10.1038/nm.3645.
- 13- Xie B, Sun J, Song X. Hair Follicle Melanocytes Initiate Autoimmunity in Alopecia Areata: a Trigger Point. *Clin Rev Allergy Immunol.* 2022; 63 (3):417-430. doi:10.1007/s12016-022-08954-w.
- 14- Jia WX, Mao QX, Xiao XM, Li ZL, Yu RX, Li CR. Patchy alopecia areata sparing gray hairs: a case series. *Postepy Dermatol Alergol.* 2014;31 (2):113-116. doi:10.5114/pdia.2014.40956.
- 15- Paus R. The Evolving Pathogenesis of Alopecia Areata: Major Open Questions. *J Investig Dermatol Symp Proc.* 2020;20 (1):S6-S10. doi:10.1016/j.jisp.2020.04.002.
- 16- Tobin DJ, Bystryn JC. Different populations of melanocytes are present in hair follicles and epidermis. *Pigment Cell Res.* 1996;9(6):304-310. doi:10.1111/j.1600-0749.1996.tb00122.x

- 17-Simon JD, Hong L, Peles DN. Insights into melanosomes and melanin from some interesting spatial and temporal properties. *J Phys Chem B*. 2008;112(42):13201-13217. doi:10.1021/jp804248h.
- 18- Leung MC, Sutton CW, Fenton DA, Tobin DJ. Trichohyalin is a potential major autoantigen in human alopecia areata. *J Proteome Res*. 2010;9(10):5153-5163. doi:10.1021/pr100422u.
- 19- Strazzulla LC, Wang EHC, Avila L, et al. Alopecia areata: Disease characteristics, clinical evaluation, and new perspectives on pathogenesis. *J Am Acad Dermatol*. 2018;78(1):1-12. doi:10.1016/j.jaad.2017.04.1141.
- 20- Bertolini M, McElwee K, Gilhar A, Bulfone-Paus S, Paus R. Hair follicle immune privilege and its collapse in alopecia areata. *Exp Dermatol*. 2020;29(8):703-725. doi:10.1111/exd.14155.
- 21- Mourad, B., Hasby, E. and Elfar, N., 2020. Immunohistochemical study assessing stem cell factor receptor C-kit in patients with alopecia. *Egyptian Journal of Dermatology and Venereology*, 40(2), p.84.
- 22- Mohanan S, Sylvia MT, Carounanidy U, Bhat RV. Expression of CD117 and platelet-derived growth factor receptor α in patients with alopecia areata. *Indian J Dermatol Venereol Leprol*. 2020;86(6):643-648. doi:10.4103/ijdvl.IJDVL_557_19.
- 23- Ashrafuzzaman M, Yamamoto T, Shibata N, Hirayama TT, Kobayashi M. Potential involvement of the stem cell factor receptor c-kit in alopecia areata and androgenetic alopecia: histopathological, immunohistochemical, and semiquantitative investigations. *Acta Histochem Cytochem*. 2010;43(1):9-17. doi:10.1267/ahc.09032.