

Comparison of Preoperative Computerized Tomographic Scan of Temporal Bone Findings with Intra Operative Findings in Patients with Chronic Otitis Media undergoing Tympanomastoidectomy:A Descriptive Study

Abstract:

Background: Since ancient times, chronic suppurative otitis media (CSOM) has been a significant contributor to middle ear illness. Antibiotics have been extremely helpful, but (CSOM) is still a frequent condition, and its consequences present a challenge to both otologists and radiologists. Due to the intricate anatomical nature of the middle ear and inner ear, radiological assessment of the temporal bone is challenging.

Aim of the study: To compare between preoperative CT scan findings of the temporal bone with the operative findings in patients with CSOM undergoing tympanomastoidectomy.

Methodology: A Descriptive cross-sectional prospective has been adopted and 35 patients with Chronic Suppurative Otitis Media were admitted at the Department of Otolaryngology/ Alsulaymaniyah Teaching Hospital of Otolaryngology, Head and Neck Surgery, and Zhian Hospital during the period from February to December 2015. A detailed history and careful physical examination, clinical tests revealed that all of the patients had Chronic Suppurative Otitis Media, typically with discharge from the ear and hearing loss. Each patient had their clinical history collected, and they all underwent a thorough ear, nose, and throat examination as well as an attentive otoscopic and microscopic ear examination. Additionally, all patients underwent an audiological evaluation that included pure tone audiometry, tympanometry, and HRCT.

Results: Thirty -five patients were included in this study. The mean age of the patients was 33 years; 51.4% were males and 48.6% were females. The most common presenting symptom was aural discharge in 71.4%; the second one was hearing loss in 28.6%. Mastoid pneumatization was found in 82.9% by CT while

by surgery, it was found in 17.1%. CT findings showed that middle ear involvement in 11.4%, mastoid involvement in 11.4%, mastoid with middle ear involvement in 54.3%, and EAC, mastoid, and middle ear involvement in 17.1%. While the surgical findings showed middle ear disease in 20%, mastoid involvement in 11.4%, mastoid with middle ear involvement in 57.1%, and EAC, mastoid and middle ear involvement in 11.4%. The CT findings for eroded Malleus, Incus integrity, and stapes in 31.4%, 37.1%, not visualized while surgical findings showed eroded Malleus, Incus, and stapes integrity that 28.6%, 54.3%, and 28.6% respectively. The CT findings for an eroded facial canal, the lateral semicircular canal, the posterior external auditory canal wall, and sigmoid sinus plate integrity were 12.4%, 8.6%, 22.9%, and 11.4% in that order, while the surgical findings of the eroded facial canal, the lateral semicircular canal, and the posterior external auditory canal wall were found in 20.0%, 5.7%, 17.1%, and 14.2% respectively. Both CT and surgical findings of Integrity of the tegmen showed that 32 patients (91.4%) were found to have intact tegmen, and 3 patients (8.6%) had eroded tegmen and both showed that the eroded scutum found in 25.7%.

Conclusions: The current study concluded a positive correlation between CT and surgical findings that has many advantages in preoperative planning for the eradication of the disease, choosing the best approach & has a very important role in the orientation of the surgeon during the surgery to avoid any possible complications.

Keywords: Chronic Otitis Media, Computerized Tomography, Intra Operative Findings, Temporal Bone, Tympanomastoidectomy.

Introduction:

Since ancient times, chronic suppurative otitis media (CSOM) has been a significant contributor to middle ear illness. Although antibiotics have made a significant contribution, (CSOM) is still a frequent condition, and its consequences

present a challenge for both otologists and radiologists ⁽¹⁾. Due to the intricate anatomical nature of the middle ear and inner ear, radiological assessment of the temporal bone is challenging. High-resolution computed tomography (HRCT), a recent invention, has significantly improved the imaging of ear components. Modern thin-section HRCT technology enables imaging of osseous structures with a spatial resolution of 0.45 to 0.65 mm using sophisticated algorithms. HRCT benefits from good topographic visualization and is free of obtrusive structure-superimposition effects. It is crucial to take scans in both the axial and coronal planes of view since the various temporal bone components are frequently visible in just one projection ^(2, 3). When there are CNS Complications of CSOM, for example, the need for preoperative neuroimaging is fairly obvious. Preoperative facial paralysis, vertigo with a positive fistula test, and when a revision mastoidectomy is being considered but there are no specifics about the previous treatment are other acceptable uses of CT scanning. Its capacity to assess the degree of soft tissue involvement in the middle ear, posterior tympanic spaces, and antrum may help the surgeon choose between a canal wall-up operation and an open procedure ⁽⁴⁾. Widespread adoption is hampered by concerns about sensitivity and specificity in determining the severity of underlying pathology and forecasting asymptomatic consequences. Although routine CT is not recommended for the diagnosis of cholesteatomas, it may be crucial in difficult cases (revision cases, intact tympanic membrane, a history that does not match the physical examination well, etc.) ^(1, 3).

The benefits of preoperative CT imaging were to improve preoperative planning-counseling, by its suggestion about the extent of disease in cholesteatoma and may therefore influence the surgeon to use a surgical technique specific to those findings. If imaging suggests that the disease is localized to the middle ear, a trans-canal approach may provide sufficient exposure ⁽⁵⁾. If the epitympanum alone is involved, an atriotomy may be indicated. In some patients, if a cholesteatoma sac is confirmed to be minimal by imaging, one may choose to treat it conservatively

with routine cleaning in the office ^(5, 6). The more reliable information the surgeon has to augment the preoperative examination, the better he or she can plan what needs to be done, and the better the patient can be informed of risks and expectations ⁽⁷⁾.

Aim of the study:

To compare preoperative CT scan findings of the temporal bone with the surgical outcomes in patients with CSOM undergoing tympanomastoidectomy.

Patients and Methods:

The setting of the study:

During the period from February 2015 through December 2015, 35 patients with chronic suppurative otitis media were admitted at the Department of Otolaryngology / Alsulaymaniyah Teaching Hospital of Otolaryngology, Head and Neck Surgery, and Zhian Hospital in which the decision for tympanomastoid exploration was taken, and all patients underwent a preoperative CT scanning of the temporal bone (axial, coronal sections). Of those (35) patients, 18 were males and 17 were females, the mean age of patients was 33 years with 7=76 years range.

Study design:

A Descriptive cross-sectional prospective has been adopted.

Inclusion criteria

Patients; with chronic suppurative otitis media with preoperative CT-scan that was prepared for tympanomastoidectomy.

Exclusion criteria:

1. Intracranial complication.
2. Congenital external ear Artesia.

Preoperative Evaluation:

Following a thorough physical examination and extensive medical history, all patients received a clinical diagnosis of chronic suppurative otitis media, typically with discharge from the ear and hearing loss. Each patient had their clinical history

collected, and they all underwent a thorough ear, nose, and throat examination as well as an attentive otoscopic and microscopic ear examination. Additionally, all patients underwent an audiological evaluation that included pure tone audiometry, tympanometry, and HRCT.

CT scan technique:

HRCT scan technique was done in axial sections and reconstructed in coronal sections with (0.6-1) mm section thickness (contiguous slices) at the radiology (CT) department, Alsulaymaniyah Teaching Hospital, and Radiological Center of Zhian Private Hospital.

In Alsulaymaniyah Teaching Hospital Department of Radiology the device is named Somatom, Definition AS, manufactured (2011) by SIEMENS, (64) detectors, the patient in spine position, and (5) minutes is enough to complete the scanning.

The CT images were viewed with a bone window setting to obtain optimal visualization of the bony detail and associated soft tissue, non-contrast CT was adequate.

Following each tympanomastoid exploration, a proforma was completed which itemized the anatomical structures usually encountered in tympanomastoid surgery.

A similar proforma was completed for the radiological findings were compared with the surgical findings and statistically correlated. All surgical procedures were performed by, or under the direct supervision of a senior otolaryngologist, and the operative findings were recorded

Operative procedure:

All surgeries were performed under general anesthesia with endotracheal intubation. The patients were positioned in a supine position with the patient's head turned toward the contralateral side, and the hair was shaved superior and posterior to the pinna to provide approximately (1-2) cm of hairless skin.

The operating room was sterilized with povidone-iodine. The operational microscope is used to inspect the TM and EAC. Removal of cerumen or other

material from the EAC is done carefully to prevent bleeding. A lidocaine and epinephrine injection is administered at the bony-cartilaginous junction. The medialmost portion of the hair-bearing canal skin can be used to estimate the location of this junction. Post auricular injection is used to administer medication to the four quadrants of the canal using a (25) gauge needle with the bevel pointed toward the bone. It is important to keep an eye on the bony canal to make sure the EAC's skin has blanched to the TM without developing any blebs.

If a tympanometry flap needs to be elevated along with a mastoidectomy, a transcanal Lempert incision is made. It is started in the middle of the posterior wall just (1-2) mm medial to the osteocartilaginous junction by Rosen knife, then it is extended superiorly to (12 o'clock) in line with the lateral process of the malleus, then it is returned to (6 o'clock). Inferior incisions are created with an 11-blade and extend laterally 1- 2 mm from the end of the superior incision to the incisuraterminalis. If more hemostasis is required, an EAC can be placed with a cotton ball drenched with topical adrenaline.

A postauricular incision is made with a no. (22) blade after relocating the microscope. From just above and posterior to the helix's root and down to the mastoid tip, the incision is made. The incision should be made between 0.5 and 1 cm behind the postauricular sulcus. Now being harvested is temporalis fascia.

By cutting through the periosteum along the linea temporalis, the mastoid cortex is made visible. From the back of the periosteal incision, a vertical limb is stretched toward the mastoid tip. This could be done in a T shape. The cortex is cleared of soft tissue using a periosteal elevator so that the trans-canal incision may be seen. To retract the ear anteriorly, the tape is inserted through the canal and brought out through the postauricular incision. The Henle spine, the cribriform region, and the linea temporalis are among the surface features of the mastoid that are located along with self-retaining retractors. An approximation of the antrum's position is given by MacEwen's (supramental) triangle.

Depending on the location and extent of the disease and the anatomical configuration, drilling may begin via transcortical (mastoid) or transcranial routes. A large (8 mm) cutting burr is used initially, before being reduced to a (6) then a (4) mm cutting burr more medially after entry into the antrum with vigorous irrigation and suction. For the ultimate thinning of bone underlying structures like the middle fossa tegmen or sigmoid sinus, or when drilling close to the facial nerve, a diamond burr should be utilized. To minimize the risk of harm, the drilling should follow the underlying structure. To enable great vision of the structures as they are identified and to assist in minimizing unintentional harm, it is crucial to "cauterize" the borders of the mastoid cavity during the surgery.

The first cuts are done posterior to the EAC and then parallel to the linea temporalis. The sigmoid sinus' posterior route is generally approximated by the triangle's third side. The air cell system is visible when the mastoid cortex has been removed. The LSCC may be recognized after the antrum has been penetrated. The LSCC and tegmen can be seen once, at which point the incus' brief process can be seen. The presence of the disease process will determine whether or not the posterior canal wall needs to be removed. After the middle ear and mastoid pathologies were removed, the wound was stitched up in two layers with bandages and dressings. In the Transcanal route, use the Cordatympani as a reference before drilling from inside out to expose the attic, the antrum, and finally all of the mastoid air cells.

Statistical analysis:

Data were analyzed using the statistical package for social sciences (SPSS, version 19). Frequencies and percentages were calculated. The McNemar test was used. A p-value ≤ 0.05 was considered statistically significant.

Results:

Distribution of COM according to age was demonstrated in figure (1) which showed that thirty five patients were included in the study. The mean age of the patients was (33 years) with an age range between (7 – 76 years).Eighteen patients were males (18/35; 51.4%), and the rest were females (17/35; 48.6%).

Table (1): Distribution of COM according to age.

Sociodemographic characteristics		No.	%
Age groups	<20	10	29.0
	20-29	7	20.0
	30-39	5	14.0
	40-49	6	17.0
	≥50	7	20.0
Sex	Males	18	51.0
	Females	17	49.0

Distribution of chief complain in COM was demonstrated in figure (1) and illustrated that the most common presenting symptom was aural discharge (25/35; 71.4%); the second one was hearing loss (10/35; 28.6%).

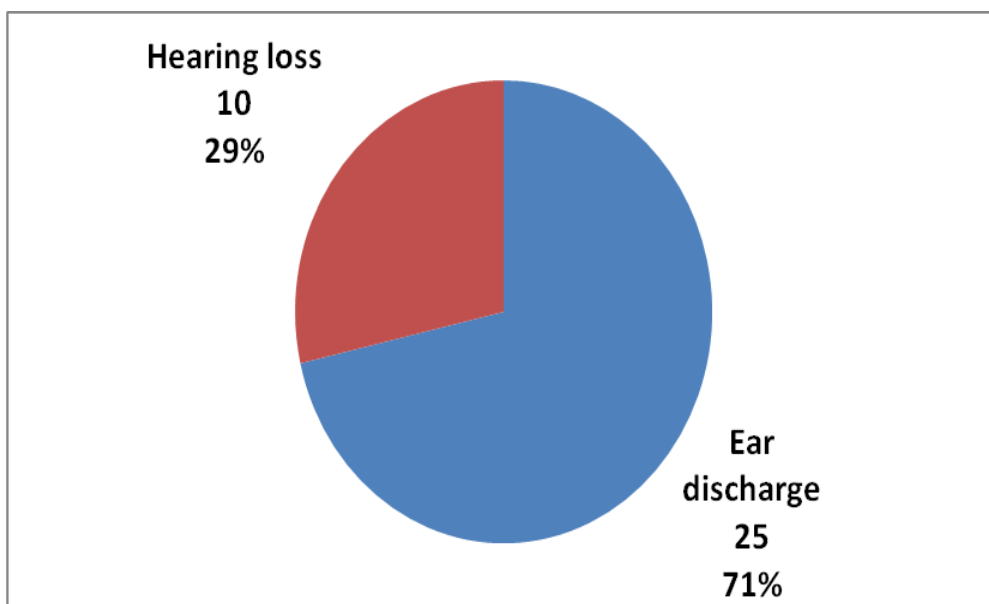


Figure (1): Distribution of chief complain in COM.

The proportions of Pneumatization/sclerosis of the mastoid bone was demonstrated in figure (2) which elicited that the mastoid pneumatization were in CT and surgery (29) patients were sclerotic (hyperdense) (82.9%) and (6) patients were with pneumatized mastoids (hypodense) (17.1%). sensitivity and specificity were 100%.

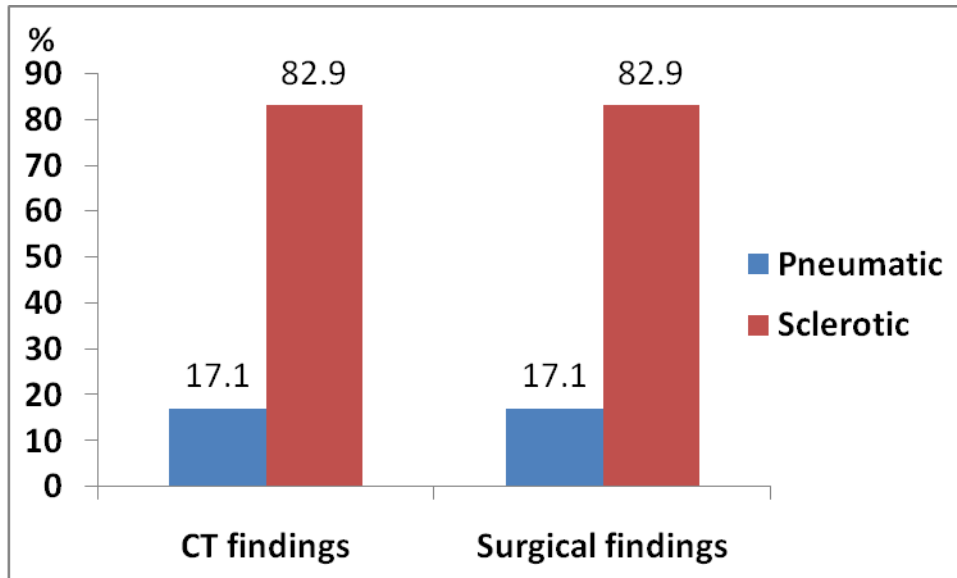


Figure (2): The proportions of pneumatization/sclerosis of the Mastoid in CT and surgery.

Distribution of site of soft tissue mass and opacification between CT and surgery was demonstrated in table (2). This table showed that in relation to CT findings; Two patients had clear (no soft tissue opacification in middle ear and mastoid) (2/35; 5.7%), and four patients had middle ear disease (4/35; 11.4%), four patients with mastoid involvement only (4/35; 11.4%), nineteen patients with mastoid and middle ear involvement (19/35; 54.3%) and six patients with EAC, mastoid and middle ear involvement (6/35; 17.1%). The Surgical findings showed as seven patients had middle ear disease (7/35; 20%), four patients with mastoid involvement only (4/35; 11.4%), twenty patients with mastoid and middle ear involvement (20/35; 57.1%) and four patients with EAC, mastoid and middle ear involvement (4/35; 11.4%).

Table (2): Distribution of site of soft tissue mass and opacification between CT and surgery.

Site according to CT	Site of soft tissue mass at surgery								
	n	Middle ear only		Mastoid only		Middle ear & mastoid		EAC+Middle ear+Mastoid	
		No.	%	No.	%	No.	%	No.	%
No opacification	2	1	50.0	0	0.0	1	50.0	0	0.0
Middle ear only	4	4	100	0	0.0	0	0.0	0	0.0
Mastoid only	4	0	0.0	3	75.0	1	25.0	0	0.0
Middle ear & mastoid	19	2	10.5	1	5.3	16	84.2	0	0.0
EAC+Middle ear+ Mastoid	6	0	0.0	0	0.0	2	33.3	4	66.7
Total	35	7	20.0	4	11.4	20	57.1	4	11.4

Comparison between scutum integrity in CT and surgery was shown in figure (3) and revealed that according to CT findings, twenty six patients (26/35; 74.3%) were found to have intact scutum, and nine patients (9/35; 25.7%) were eroded. While in surgical findings, twenty six patients (26/35; 74.3%) were found to have intact scutum, and nine patients (9/35; 25.7%) were eroded. The sensitivity was (88.9%) and specificity was (96.9%) of CT scan in detecting the eroded bone compared with results of surgery.

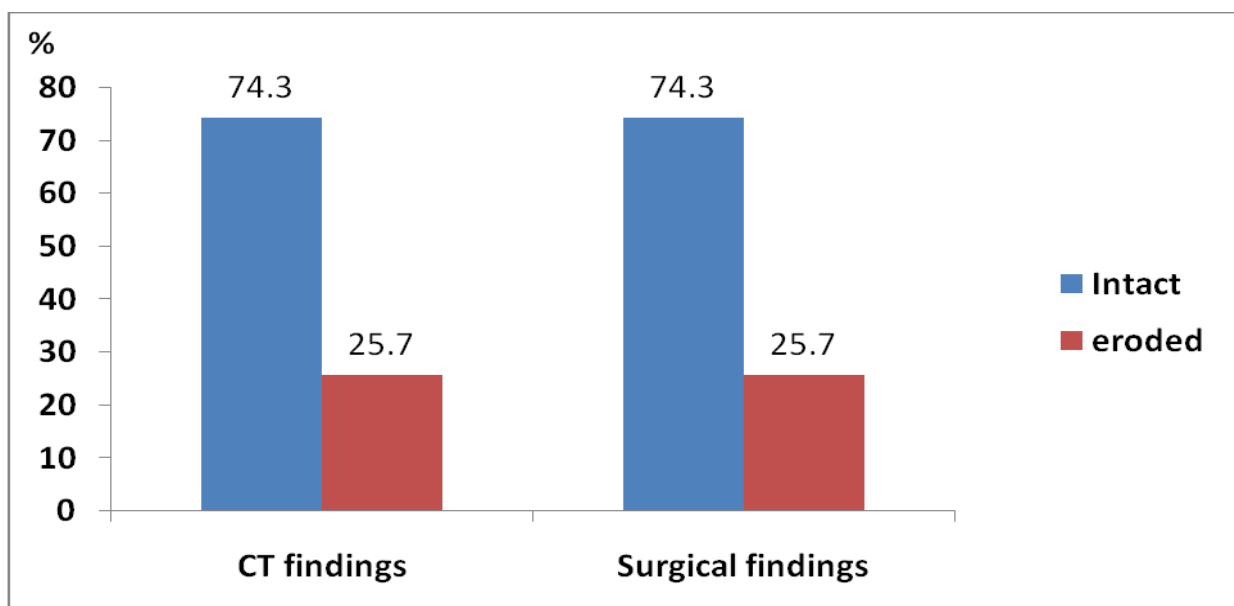


Figure (3): Comparison between scutum integrity in CT and surgery.

Comparison between Malleus integrity in CT and surgery was showed in table (3) which demonstrated that the CT findings; twenty four patients (24/35; 68.6%) were found to be intact malleus; eleven patients had eroded malleus (11/35; 31.4%).Twenty two (22/35; 62.9%) were found to be intact incus; thirteen patients had eroded incus (13/35; 37.1%).Four patients (4/35; 11.4%) were found to be intact stapes; in 31 patients could not visualize. While surgical findings showed that 25 patients (71.4%) were found to be intact; ten patients had eroded malleus (10/35; 28.6%).Sixteen patients (16/35; 45.7%) were found to be intact incus; nineteen patients had eroded incus (19/35; 54.3%).Twenty five patients (25/35; 71.4%) were found to be intact stapes; ten patients had eroded stapes (10/35; 28.6%).The sensitivitywere (100%, 68.4%); and specificity were (96%, 100%) for malleus and incus respectively of CT scan in detecting the eroded bone compared with results of surgery.

Table (3): Comparison between Malleus and incus integrity in CT and surgery.

Site	Status	CT findings	Surgery findings
Malleus integrity	Intact	68.5%	71.4
	Eroded	31.5%	28.6%
Incus integrity	Intact	62.8%	45.7%
	Eroded	37.2%	54.3%

Comparison between CT and surgery was showed in table (4) and revealed that concerning the CT findings for facial canal, 31 patients with intact facial nerve canal (88.6%) and 4(12.4%) patients had eroded canal. In the surgical findings, 28 patients were with intact facial nerve canal (80.0%) while 7 patients had eroded canal. The sensitivity was (28.6%) and specificity was (92.9%) of CT scan in detecting the eroded bone. Regarding thelateral semicircular canal, CT findings, 32 patients (91.4%) were found to have intact lateral semicircular canal and 3 patients (8.6%) were found to have eroded lateral semicircular canal. In the

surgical findings, 33 patients (94.3%) were found to have intact lateral semicircular canal and 2 patients (5.7%) were found to have eroded lateral semicircular canal. Sensitivity was (50%) and specificity was (93.9%) of CT scan in detecting the eroded bone compared with results of surgery. Both CT and surgical findings of Integrity of the tegmen showed that 32 patients (91.4%) were found to intact tegmen; and 3 patients (8.6%) have eroded tegmen. Sensitivity was (66.7%) and specificity was (96.9%) of CT scan in detecting the eroded bone compared with results of surgery.

For the Posterior external auditory canal wall, the CT findings were found 27 patients (77.1%) were found to intact posterior external auditory canal wall; and 8 patients (22.9%) have eroded posterior external auditory canal wall. Surgical findings, 29 patients (82.9%) were found to intact posterior external auditory canal wall; and 6 patients (17.1%) have eroded posterior external auditory canal wall. Sensitivity was (83.3%) and specificity was (89.7%) of CT scan in detecting the eroded bone compared with results of surgery in posterior external auditory canal wall.

For the sigmoid sinus plate integrity, CT scanning has correctly identified four out of five patients with eroded sigmoid sinus plate (4/35; 11.4%). It has one false positive case where it could not be proven surgically. While the surgical findings for sigmoid sinus plate erosion found in 5 patients (14.2%) and the other 30 patients (85.8%) found to have intact sigmoid sinus plate. The sensitivity was 100%, specificity was 96%.

Table (4): Comparison between Malleus integrity in CT and surgery.

Site	Status	CT findings	Surgery findings	p-value*
		No. (%)	No. (%)	
Facial canal	Intact	31(88.6)	28(80.0)	0.000
	Eroded	4(12.4)	7(20.0)	
Lateral semicircular canal	Intact	32(91.4)	33(94.3)	0.000
	Eroded	3(8.6)	2(5.7)	

Integrity of the tegmen	Intact	32(91.4)	32(91.4)	0.000
	Eroded	3(8.6)	3(8.6)	
Posterior external auditory canal wall	Intact	27(77.1)	29(82.9)	0.001
	Eroded	8(22.9)	6(17.1)	
Sigmoid sinus plate integrity	Intact	31(88.6)	30(85.8)	0.000
	Eroded	4(11.4)	5(14.2)	

Discussion:

Although it is a regular practice to utilize a CT scan to assess the paranasal sinuses before endoscopic sinus surgeries, its use before mastoid surgery is unclear. Before endoscopy and treatments, computed tomography scan imaging reduces the danger of harm to nearby structures like the orbit and skull base. Preoperative CT scans for mastoid surgery have been shown to have many benefits, including the ability to image anatomical details, disease severity, and the presence of any asymptomatic complications⁽⁸⁾.

According to age in our study which includes 35 patients with the clinical diagnosis of chronic suppurative otitis media; the commonest age group in our patients was less than 20 years (28.6%) and (20- 29) years (20%); this agrees with Sinha, *et al*⁽⁹⁾ study included 20 patients with the clinical diagnosis of chronic suppurative otitis media and cholesteatoma and the commonest age group of the patients was (10-20) years (35%).

According to sex (18 male, 17 female) and the percentage (male 51.4 %, female 48.6%) male to female ratio (1.05:1); this agrees with Saraf *et al.*,⁽¹⁰⁾ who reported a male-to-female ratio of (1.59:1), but Gerami *et al.*,⁽¹¹⁾ had a highly skewed male to female ratio of (2.48:1) respectively.

About chief complain commonest complaints were otorrhea (71.4 %) followed by hearing loss (28.6 %); this agrees with Sinha *et al.*,⁽⁹⁾ study commonest complaints were otorrhea (100%) followed by hearing loss (85%), this can be explained as most of our cases were an active type of COM.

Regarding pneumatization of mastoid; Knowledge of mastoid pneumatization aids in the planning of surgical approach e.g. whether to do canal wall down or up type of surgery⁽¹²⁾. In the present study, mastoid pneumatization was in CT 29 patients were sclerotic (82.9%) and 6 patients were with pneumatized mastoids (17.1%). So sensitivity was (100%) and specificity (100%) this agree with, similar results were reported by Vlastarakos *et al.*,⁽¹³⁾ and Rai⁽¹⁴⁾. The explanation behind this might be that in sclerotic mastoid if the disease process is limited to the attic, the approach to it is by transcanal and avoid injuries to the important structures and avoid complications.

The site of soft tissue mass in our study was more common in both the middle ear and mastoid, which was found in (19/35, 54.3%) patients in CT and (16/35, 45.7%) patients during surgery. This agrees with GinniDatta *et al.*⁽¹⁾ who found that CT with soft tissue in (19),(76%) cases was present in both the middle ear and mastoid, this can be explained as soft tissue opacity may be a fluid collection, granulation tissue, polyps or cholesteatomas.

Regarding scutum integrity in our study in CT, 26 patients appear intact but of this one of them was eroded at surgery and in CT, 9 patients appear eroded but of these one of them was intact at surgery, so sensitivity was (88.9%) and specificity was (96.9%) and if there was bony erosions including scutum we should suspect cholesteatomas and this erosion can be seen clearly in coronal view; this agree with the study of Kataria *et al.*,⁽¹⁵⁾ which reported that out of 18 subjects which showed scutum erosion on HRCT, 17 subjects had same findings when examined during surgery. In Keskin *et al.*,⁽¹⁶⁾ study 28 of the scutum erosions were confirmed in surgery among 35 patients diagnosed by CT. Sensitivity was (80%) and specificity was (90.4 %).

In ossicular chain integrity; visualization or non-visualization of the ossicles respectively, indicates the presence or erosion of the structure of the chain in almost all of the cases if the CT scanning is viewed in a correct window setting. When ossicular erosions are visualized, the probability of a present

cholesteatomas about (90%); in the present study, CT findings found that 11 patients had eroded malleus (31.4%); 13 patients had eroded incus (37.1%); four patients had intact stapes (4/35; 11.4%), and (31) not visualized; While surgical findings ten patients had eroded malleus (10/35; 28.6%); nineteen patients had eroded incus (19/35; 54.3%); ten patients had eroded stapes (10/35; 28.6%). Sensitivity was (100%, 68.4%); and specificity was (96%, 100%) for malleus and incus respectively of CT scan in detecting the eroded bone compared with the results of surgery.

There were agreements on the malleus and incus, but there was a dispute regarding the stapes. According to Datta *et al.*⁽¹⁾, the malleus looked to be intact in the ear ossicles in 6 (24%) cases on CT, but it was later discovered to be intact in 4 (16%) cases, while in the other 2 cases, it had partially eroded. 19 (76%) of the cases where the malleus seemed to be eroded on CT had this finding confirmed intraoperatively. On CT, the incus looked to be intact in 5 (20%) cases. Preoperatively, it was discovered to be intact in 2 (8%) cases, and it was partially necrotic in the remaining 3 (12%) cases. On CT incus appeared to be eroded in 20(80%) cases and all these cases were confirmed preoperatively. On CT Stapes appeared to be intact in 11(44%) cases, eroded in 4(16%) cases, and not visualized in 10(40%) cases, preoperatively it was eroded in 5(20%) cases and found to be intact in 20(80%) cases. Out of 10 cases not visualized on CT, all were intact preoperatively⁽¹⁾; Keskin *et al.*,⁽¹⁶⁾ reported their sensitivity, and specificity of (80%), and (46.1%) respectively for ossicular erosion. The stapes were visualized only in four cases because may be related to the radiologist, the positions of stapes, very small in size and may be overlapped by soft tissue mass. The importance of which ossicles were involved aids us in deciding on the types of tympanoplasty required.

Facial nerve canal integrity in our study CT findings were thirty-one patients with intact facial nerve canal (31/35; 88.6%); four patients with eroded canal while surgical findings twenty-eight patients with intact facial nerve canal (28/35; 80 %);

seven patients with eroded canal. Sensitivity was (28.6%) and specificity was (92.9%); so this result agrees with the low sensitivity and relatively high specificity in our study could be correlated with Rai⁽¹⁴⁾ with sensitivity and specificity of (33.33%) and (100%) and Lemmerling *et al.*,⁽¹⁷⁾ respectively. Similar results were found by Alzoubi *et al.*,⁽¹⁸⁾ and Payal *et al.*,⁽¹⁹⁾. Tok *et al.*,⁽²⁰⁾ study reported a dehiscence fallopian canal in two patients whereas it was detected in four more patients intra-operatively. On statistical analysis of HRCT, sensitivity (33.33%), specificity (100%), Manik *et al.*,⁽²¹⁾ showed a sensitivity of (55%) and specificity of (95%) for facial canal dehiscence.

Regarding lateral semicircular canal integrity, our CT findings were that 32 patients (91.4%) were found to have intact lateral semicircular canals; 3 patients (8.6%) were found to have eroded lateral semicircular canals; while in surgery 33 patients (94.3%) were found to have intact lateral semicircular canal; 2 patients (94.3%) were found to have eroded lateral semicircular canal. Sensitivity was (50%) and specificity was (93.9%); this agrees with Boruah *et al.*,⁽¹²⁾ who have had 6 patients with surgically confirmed LSCC fistula. Five out of six cases were visible in the pre-operative CT scans; In two patients, according to Tok *et al.*'s study⁽²⁰⁾, the lateral semicircular canal had eroded; however, three patients had it intraoperatively. In terms of statistical analysis, the HRCT's sensitivity is 66.66% and its specificity is 95.74.

Regarding tegmen integrity in the present study CT findings were 32 patients (91.4%) were found to have intact tegmen, and 3 patients (8.6%) had eroded tegmen; while surgical findings 32 patients (91.4%) were found to have intact tegmen; and 3 patients (8.6%) have eroded tegmen; sensitivity was (66.7%) and specificity was (96.9%) of CT scan in detecting the eroded bone compared with results of surgery; this was corresponding to Datta *et al.*, only 2 (8% of) cases of dural plate erosion were discovered postoperatively, compared to 4 (16%) occurrences on CT. On CT, the dural plate was intact in 21 (84%) of the cases, but it was also present in 23 (92%) of the cases before surgery. In the current study,

CT of the posterior external auditory canal wall found that 27 patients (77.1%) had intact posterior external auditory canal wall; and 8 patients (22.9%) had eroded posterior external auditory canal wall; with opacification in the middle ear and mastoid; while surgical findings were 29 patients (82.9%) were found to intact posterior external auditory canal wall; and 6 patients (17.1%) have eroded posterior external auditory canal wall and cholesteatoma. The statistical analysis show sensitivity was (83.3%) and specificity was (89.7%) of the CT scan in detecting the eroded bone compared with the results of surgery in the posterior external auditory canal wall; bony erosion, an additional sign for the presence of cholesteatoma was identified in 6 cases. This is comparable to the findings of Zaman *et al.*,⁽²²⁾ who discovered cholesteatoma with a sensitivity of (100.0%) and a specificity of 88.1%. Mitra *et al.*,⁽²³⁾ reported a sensitivity and specificity of 100% for the diagnosis of cholesteatoma in their HRCT study of 100 patients. A current study about sigmoid sinus plate integrity showed that CT scanning has correctly identified four out of five patients with eroded sigmoid sinus plates (4/5; 80%). It has one false positive case where it could not be proven surgically; the sensitivity was (100%), specificity was (96%). While Kataria *et al.*,⁽¹⁵⁾ found that CT scanning has missed one eroded sigmoid sinus plate which was proven surgically; while Guarano and Joharjy⁽²⁴⁾ showed that CT scanning has correctly identified the erosion in sigmoid sinus plate.

Conclusion:

The current study concluded a positive correlation between CT and surgical findings that has many advantages in preoperative planning for eradication of the disease, choosing the best approach & having a very important role in the orientation of the surgeon during the surgery to avoid any possible complications.

Consent

As per international standard or university standard, patients' written consent has been collected and preserved by the author(s).

Ethical Approval:

As per international standard or university standard written ethical approval has been collected and preserved by the author(s).

References:

1. Datta G. Correlation of preoperative HRCT findings with surgical findings in Unsafe CSOM. *IOSR Journal of Dental and Medical Sciences*. 2014; 13:12005.
2. Browning GG and Merchant SN. Chronic otitis media, Scott-Brown otolaryngology Head and Neck surgery, 7th edition. Edward Arnold, 2008, chapter 237c: 3396-3438.
3. Swartz JD and Loevner LA. Imaging of the temporal bone, 4th ed. New York, THIEME; 2009: 1-6.
4. Stevens SM and Lambert PR. Mastoidectomy, Surgical Techniques, Cummings otolaryngology, Head and neck surgery. 6th edition, 2015, chapter 142: 2189-2190.
5. Chole RA. Chronic Otitis Media, Mastoiditis, and Petrositis Cummings otolaryngology, Head and neck surgery. 6th edition, 2015, chapter 139: 2139-2155.
6. Hamilton J. Chronic otitis media in childhood, Scott-Brown otolaryngology, Head and Neck surgery 7th edition. Edward Arnold, 2008, chapter 74: 947.
7. Krishnan B and Parida S. Preoperative Evaluation and Investigations for Maxillofacial Surgery. In: Bonanthaya K, Panneerselvam E, Manuel S, Kumar VV, Rai A. (eds) Oral and Maxillofacial Surgery for the Clinician. Springer, Singapore. 2021. https://doi.org/10.1007/978-981-15-1346-6_2
8. Gerami H, Naghavi E, Wahabi-Moghadam M, Forghanparast K & Akbar MH. Comparison of preoperative computerized tomography scans imaging of temporal bone with the intra-operative findings in patients undergoing mastoidectomy. *Saudi medical journal*. 2009; 30(1): 104–108.

9. Sinha AK, Mustafa SN, Raushan EA, Kumar G. Role of High Resolution Computed Tomography in Cholesteatoma. *Int J Sci Stud.* 2014; 2(8):164-168.
10. Saraf A, Singh P, Ahmad R, Kalsotra P. Role of CT Scan In Unsafe Chronic Otitis Media Cases Of Jammu. *International Journal Dental and Medical Sciences Research.* July-Aug 2021; 3(4): 806-810
11. Gerami H, Naghavi E, Wahabi-Moghadam M, Forghanparast K, Akbar MH. Comparison of preoperative computerized tomography scans imaging of temporal bone with the intra-operative findings in patients undergoing mastoidectomy. *Saudi Med J.* 2009; 30(1):104-108.
12. Boruah DK, Sharma BK, Sanyal S, *et al.* Role of high resolution computed tomography in the evaluation of suppurative diseases of middle ear and mastoids and their complications with surgical correlation. *J. Evolution Med. Dent. Sci.* 2016; 5(17):850-858, DOI: 10.14260/jemds/2016/197
13. Vlastarakos PV, Kiprouli C, Pappas S, Xenelis J, Maragoudakis P, Troupis G, *et al.* CT scan versus surgery: How reliable is the preoperative radiological assessment in patients with chronic otitis media. *Eur Arch Otorhinolaryngol.* 2012; 269:81-86.
14. Rai T. Radiological study of the temporal bone in chronic otitis media: Prospective study of 50 cases. *Indian J Otol.* 2014; 20:48-55.
15. Kataria T, Sehra R, Grover M, Sharma S, Verma N, Sharma MP. Correlation of Preoperative High-resolution Computed Tomography Temporal Bone Findings with Intra-operative Findings in Various Ear Pathologies. *Indian Journal of Otolaryngology and Head & Neck Surgery.* 2022; 74(Suppl 1): 190-199. <https://doi.org/10.1007/s12070-020-01950-6>
16. Keskin S, Çetin H, Töre HG, *etal.* The Correlation of Temporal Bone CT With Surgery Findings in Evaluation of Chronic Inflammatory Diseases of The Middle Ear. *Eur J Gen Med.* 2011; 8(1):24-30.
17. Lemmerling MM, Foer BD, VandeVyver V, Vercruyse JP, Verstraete KL. Imaging of the opacified middle ear. *European J Radiol.* 2008; 66: 363-371.
18. Alzoubi FQ, Odat HA, Al-Balas HA, Saeed SR The role of preoperative CT scan in patients with chronic otitis media. *Eur Arch Otorhinolaryngol.* 2009 Jun; 266(6):807-809.
19. Payal G, Pranjal K, Gul M, Mittal MK, Rai AK Computed tomography in chronic suppurative otitis media: value in surgical planning. *Indian J Otolaryngol Head Neck Surg.* 2012 Sep; 64(3): 24-29.
20. Tok S, Adapinar B, Incesulu A, Gurbuz MK. The examination of middle ear ossicles with preoperative 64-detector computed tomography in cases with

chronic otitis media and cholesteatoma and comparison of operation findings. *IntAdv Otol.*2013; 9:349-352.

21. Manik S, Dabholkar Y, Bhalekar S, Velankar H, Chordia N, Saberwal A. Sensitivity and Specificity of High-Resolution Computed Tomography (HRCT) of Temporal Bone in Diagnosing Cholesteatoma and Its Correlation with Intraoperative Findings. *Indian Journal of Otolaryngology and Head & Neck Surgery.* 2021; 73(1): 25-29. <https://doi.org/10.1007/s12070-020-01892-z>
22. Zaman SU, Rangankar V, Muralinath K, Shah VKG, Pawar R. Temporal Bone Cholesteatoma: Typical Findings and Evaluation of Diagnostic Utility on High Resolution Computed Tomography. *Cureus,* 2022; 14(3): e22730. <https://doi.org/10.7759/cureus.22730>
23. Mitra M, Thakare P, Monteiro B, Amle D. The role of high-resolution computerized tomography as a diagnostic tool in the evaluation and planning of management of patients with chronic otitis media. *Muller J Med Sci Res.* 2021; 12: 6.
24. Guarano JL and Joharjy IA. Middle ear cholesteatoma: characteristic CT findings in 64 patients. *Ann Saudi Med.* 2004; 24(6): 442-447.