

Case Report

Rhesus Change in *Pleomorphic Sarcoma* Patients With Chemotherapy Protocol *Non Rhabdomyosarcoma Soft Tissue Sarcoma* (NRSTS) Cycle 5

ABSTRACT

Introduction:

Changes in Rhesus blood group during cancer treatment are very rare. The Rhesus blood group is a genetic characteristic that usually remains for a lifetime. In this case, a child experiences a Rhesus change during treatment of *pleomorphic sarcoma* using *Non Rhabdomyosarcoma Soft Tissue Sarcoma* (NRSTS) therapy, which includes surgery, chemotherapy, and radiotherapy. The side effects of chemotherapy on red blood cells may cause changes to the Rhesus antigen.

Case:

A 17-year-old boy underwent chemotherapy with a history of blood transfusion as many as 9 times using A Rhesus negative blood. However, the latest crossmatch examination showed his blood group was weak A Rhesus positive. The patient was then given a transfusion of A Rhesus positive blood which was considered compatible. Before transfusion, the patient was given a corticosteroid injection premedication and monitored for 2 weeks.

Conclusion:

The Rhesus blood group is important in blood transfusion. *Pleomorphic sarcoma* treatment, such as chemotherapy, has the potential to affect the expression of Rhesus antigen. Alkylating agents can replace hydrogen atoms with alkyl radicals, which can modify chemical groups and change the normal sequence of the polypeptide chain which can alter the expression of the Rhesus antigen.

Keywords: Rhesus blood group changes, *Pleomorphic sarcoma*, *Non Rhabdomyosarcoma Soft Tissue Sarcoma* (NRSTS).

INTRODUCTION

Pleomorphic sarcoma also known as pleomorphic undifferentiated sarcoma or previously known as malignant fibrous histiocytoma (MFH), is a type of cancer that originates from soft tissues in the body, such as muscle, fat, blood vessels, nerves, tendons, and other connective tissues that support and connect various body structure organs. These tumors earn the name "pleomorphic" based on the variation in shape and size of cells found in the tumor. Pleomorphic sarcoma usually occurs in adults with an average age of 50-70 years, although it can appear at any age. These tumors usually grow in the extremities (arms and legs), but can also appear in the abdomen, chest or elsewhere in the body. The diagnosis of pleomorphic sarcoma is obtained through a series of physical examinations, medical imaging techniques such as MRI or CT scans, and tissue biopsies to examine cancer cells histopathologically.^{1,2}

In cases of pleomorphic sarcoma, chemotherapy is one of the chosen treatment methods for this disease. Chemotherapy is a therapy using cytotoxic agents aimed at killing or stopping the growth of cancer cells and is inseparable from various side effects. Based on the observations emerging in this case are possible changes in the RBCs, including the potential for changes in antigen expression resulting in Rhesus changes in the patient.³

Rhesus blood type changing during cancer treatment are not common case. Rhesus (Rh) blood type is determined by the presence or absence of specific antigens on the surface of red blood cells. Classified as Rhesus positive (Rh+) if the antigen is present, and Rhesus negative (Rh-) if the antigen is not present. The Rhesus blood type were inherited from parents and usually last a lifetime. In this case, a child experienced a Rhesus change while undergoing cancer treatment. The patient received chemotherapy therapy with the Non Rhabdomyosarcom Soft Tissue Sarcoma (NRSTS) protocol. Where the treatment of Non Rhabdomyosarcom Soft Tissue Sarcoma (NRSTS) includes the benefits of removing tumors, chemotherapy, and radiotherapy, depending on the stage and size of the tumor.^{2,4}

The chance of rhesus change happening is very small because it is part of blood type that influenced by genetic factor that usually did not change for life. Therefore, a change in the Rhesus blood type during cancer treatment is a very rare phenomenon. Observations from this case will hopefully add to our understanding of the complex dynamics between chemotherapy and physiological response to the therapy in patient.^{4,5}

CASE PRESENTATION

A 17-year-old boy came to the hospital complained that he wanted to continue the 5th cycle of chemotherapy, the patient complained that his an open post-biopsy wound from 4 months ago did not heal properly, the wound appeared to be seeping (+) but there is no bleeding (-).

NA patients with blood type A negative Rhesus underwent a series of blood type and crossmatch tests to evaluate the compatibility of blood transfusions. Starting from 30 July 2022 to 19 November 2022, this test shows that the patient has a strong positive Anti-A response (4+), while Anti-B is negative (-), and is consistent with blood type A. The Rhesus test always shows a negative result, with major and minor crossmatches always showing compatibility. (Table 1)

Patient NA was admitted to the hospital on December 5, 2022, planning to undergo chemotherapy treatment. On December 6, the patient had NA blood work, the blood type examination showed that his blood type was A positive Rhesus. After crossmatching with packed red cells blood group A positive Rhesus, the results of the examination showed a compatible major negative and positive auto control, so that the blood can be removed and transfused to the patient. A similar situation occurred on December 9, the NA patient tried blood again with the same blood group results, namely blood group A positive Rhesus compatible with major negative with positive autocontrol, so that blood could come out and be transfused to the patient (Table 1). Prior to the blood transfusion, positive Rhesus was given premedication in the form of corticosteroid injections, namely methylprednisone 62.5 mg/8 hours (1 mg/kg/8 hours) with monitoring for 2 weeks.

On December 10, the NA patient returned to try 2 PRC blood, then a blood type examination was carried out which showed positive blood type A Rhesus. Since UTDRS blood stock is limited, blood requests are sent to PMI. PMI then issued 2 PRC bags with positive blood type A Rhesus.

On December 11, 2022, the evening duty officer at the hospital received a call from patient room on the ground floor, informed that patient NA has blood type A negative Rhesus according to information from the family. The NA patient had previously undergone 9 blood transfusions, using blood type A negative Rhesus. The transfusion was carried out from July 30 2022 to November 19 2022. Responding to this information, the afternoon duty officer immediately requested a new blood sample and carried out a repeat serological examination. Examination of the blood type using a tool, showed blood type A Rhesus XX (tools could not read) with the results of the examination showing that the patient had a strong positive Anti-A response (+4/99), while Anti-B and negative controls (-/0). The Anti-D value is unreadable (?/50) or weakly positive and Cell A1 shows a negative result (-/0). Meanwhile, the response to Cell B was strong positive (4+/99). (Figure 1). The next step is to do a manual blood group examination that visually reads Rhesus +2 or weakly positive. Then a crossmatch was carried out with positive packed red cell (PRC) blood type A Rhesus blood, the results of the examination showed a major negative crossmatch and positive auto controls, so that the blood was considered compatible and could be transfused to patients. On the same day an antibody screening test was carried out, the results were negative (-/0) (Figure 2).

The same thing happened on December 12, 2022. The evaluation of the blood group examination using a tool again showed blood type A Rhesus XX (the tool did not read), the results of the blood group test using the tool showed a strong positive Anti-A response (+4/95), while Anti- B and negative control (-/0). The Anti-D status is still unreadable (?/29) or weakly positive, and Cell A1 also shows a negative result (-/0). The reaction to Cell B was still strongly positive (4+/99) (Figure 3). Then a blood group examination was carried out manually and visually it read weakly positive Rhesus. After crossmatching with positive Rhesus type A PRC blood, the results again showed a negative major crossmatch and positive auto controls. So that the blood is considered compatible and can be transfused into patients. On the antibody screening examination, the result was negative (-/0). (Figure 4)

On December 13, 2022, a Du examination was carried out at PMI to detect the D antigen variant and the results showed that the patient's blood type was NA Rhesus D negative.

Examination of vital signs, obtained compos mentis awareness, pulse 102x/minute, respiratory rate 24x/minute, with a temperature of 36.7 C (axiller). The patient's weight is 50 kilograms, and the height is 170 centimeters. Physical examination of the patient found palpebral conjunctiva to appear pale in both eyes. Examination of the right thigh revealed an open wound measuring 5x6 cm, muscle base, uneven tissue edges, pain (+), bleeding (-), seepage (+)

At the Anatomical Pathology biopsy examination on July 20, 2022, the results of a malignant tumor biopsy were obtained with a predominance of pleiomorphic sarcoma.

Table 1. Result of Blood Type and Crossmatch Test NA

Blood Type Test								
Date	Grouping Cell		Rhesus	Blood Type		Crossmatch Mayor	Crossmatch Minor	Autocontrol
	Anti A	Anti B	Anti D	ABO	Rhesus	Compatible	Compatible	-
7/30/2022	4+	-	-	A	-	Compatible	Compatible	-
9/6/2022	4+	-	-	A	-	Compatible	Compatible	-
9/9/2022	4+	-	-	A	-	Compatible	Compatible	-
9/10/2022	4+	-	-	A	-	Compatible	Compatible	-
9/15/2022	4+	-	-	A	-	Compatible	Compatible	-
9/19/2022	4+	-	-	A	-	Compatible	Compatible	-
9/23/2022	4+	-	-	A	-	Compatible	Compatible	-
11/6/2022	4+	-	-	A	-	Compatible	Compatible	-
11/19/2022	4+	-	-	A	-	Compatible	Compatible	-
12/6/2022	4+	-	+	A	+	Compatible	Compatible	+
12/9/2022	4+	-	+	A	+	Compatible	Compatible	+
12/10/2022	4+	-	+	A	+	Compatible	Compatible	+
12/11/2022	4+	-	50 ?	A	+	Compatible	Compatible	+
12/12/2022	4+	-	29 ?	A	+	Compatible	Compatible	+
Antibody Screening Test								
12/11/2022	Negative /(-)							
12/12/2022	Negative /(-)							
Du Test								
12/13/2022	Rhesus D (-)							

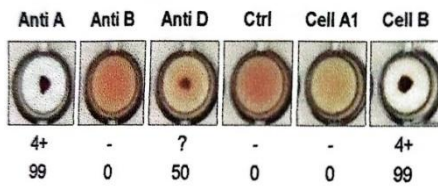


Figure 1. ABO-D Group Rhesus 12/11/2022



Figure 2. Anti Body Screening 12/11/2022

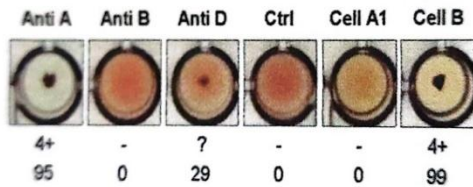


Figure 3. ABO-D Group Rhesus 12/12/2022




Figure 4. Anti Body Screening 12/12/2022

DISCUSSION

Rhesus blood type is one of the most complex blood groups known in humans. Rhesus blood type is the second most important after the ABO blood type in the field of transfusion medicine. The complexity of the Rhesus blood group antigen starts with the highly polymorphic gene that encodes it. Significance of the Rhesus blood group is related to the fact that the Rhesus antigen is highly immunogenic. In the case of the D antigen, individuals who do not produce the D antigen will produce anti-D if they encounter the D antigen on an RBC transfusion (causing a hemolytic transfusion reaction). Therefore, Rhesus status is routinely determined in blood donors and transfusion recipients.⁶

It is important to always perform an accurate serological examination and consider the various factors that can influence the expression of the Rhesus antigen before carrying out a blood transfusion.⁴

Sometimes there is a change in the Rhesus blood group from negative to positive. In these patients it is likely that the changes are due to variations in the expression of the Rhesus antigen on the patient's red blood cells. Variations in the expression of the Rhesus antigen on red blood cells which can lead to inconsistent Rhesus test results. In this case, the examination results showed that the patient had a weakly positive Rhesus. Weak positive rhesus is a condition in which the expression of rhesus antigen in red blood cells is lower than normal, and this can cause false or variable results on serological tests.^{7,8}

Variations in expression of Rhesus antigens on red blood cells occur due to differences in the structure and amount of antigen present on the surface of red blood cells. The Rhesus antigen system is the second most important blood group system after the ABO system and consists of several antigens, including the D, C, c, E, and e antigens. Rhesus D antigen is the most important and immunogenic among these five antigens.⁶

This patient underwent ankylosing agent chemotherapy. Alkylating agents can bind to the surface of red blood cells, potentially disrupting the cell surface. Alkylating agents can replace hydrogen atoms with alkyl radicals, cross-chain DNA and protein strands, and cause mutations and chromosomal aberrations so that the possibility of Rhesus changes occurs.⁹

Blood administration protocol is used according to Permenkes Number 91 of 2015. Patients with positive Rhesus blood group (D+) do not require a re-examination of Rhesus (D) on donor blood. However, in patients with negative Rhesus (D-) blood group, a re-examination of Rhesus (D) and weak D on donor blood should be performed. Only Rhesus negative (D-) blood with weak D negative can be given to patients with Rhesus negative (D-) blood group. Patients with weak D positive should be given Rhesus negative (D-) blood. In an emergency situation, the patient can be given a transfusion with positive Rhesus blood type (D+) for the first blood bag, however, it is better to be transfused with negative Rhesus (D-). So that in this patient with the last positive rhesus (D+) it is recommended to give a blood type transfusion with negative Rhesus (D-).¹⁰

In cases of emergency blood transfusions, positive Rhesus can be given and before the transfusion procedure, premedication is given in the form of corticosteroid injections with monitoring. This patient received 62.5 mg/8 hours of methylprednisone (1 mg/kg/8 hours) before a positive Rhesus transfusion with 2 weeks of monitoring.⁶

CONCLUSIONS AND SUGGESTIONS

Rhesus blood type is important in blood transfusions and variations can be caused by several factors. Pleomorphic sarcoma patients undergoing chemotherapy with ankylosing agents may experience Rhesus changes because these agents can damage red blood cells and induce mutations and chromosomal aberrations that can cause Rhesus changes.

Our suggestion is before performing transfusion procedure, an accurate Rhesus serological examination of the patient following the Minister of Health Regulation Number 91 of 2015. Ensure post-transfusion monitoring to prevent adverse reactions from transfusions.

REFERENCES

1. Carvalho SD, Pissaloux D, Crombé A, Coindre J-M, danLe Loarer F. Pleomorphic sarcomas: the state of the art. *Surgical Pathology Clinics*. 2019;12(1):63-105.
2. Milgrom SA, Million L, Mandeville H, Safwat A, Ermoian RP, danTerezakis S. Non- rhabdomyosarcoma soft- tissue sarcoma. *Pediatric Blood & Cancer*. 2021;68:e28279.
3. Sternheim A, Bickels J, danM Malawer M. Treatment of primary pleomorphic soft tissue sarcoma of the extremities. *The Open Surgical Oncology Journal*. 2011;3(1).
4. Mouro I, Colin Y, Chérif-Zahar B, Cartron J-P, danVan Kim CL. Molecular genetic basis of the human Rhesus blood group system. *Nature Genetics*. 1993;5(1):62-5.
5. Cooper B, Tishler PV, Atkins L, danBreg WR. Loss of Rh antigen associated with acquired Rh antibodies and a chromosome translocation in a patient with myeloid metaplasia. *Blood*. 1979;54(3):642-7.
6. Iwamoto S, Yamasaki M, Kawano M, Okuda H, Omi T, Takahashi J, dkk. Expression analysis of human Rhesus blood group antigens by gene transduction into erythroid and non-erythroid cells. *International journal of hematology*. 1998;68(3):257-68.
7. Dean L. *Blood Groups and Red Cell Antigens*: Bethesda (MD): National Center for Biotechnology Information (US); 2005. ; 2005.
8. Samoilova K, Klimova K, Priezzheva L, danArtsishevskaya R. Rhesus-like antigenic activity manifested in red blood cells of rhesus-negative blood donors and increased expression of ABO antigens after UV-irradiation of blood. *Bulletin of Experimental Biology and Medicine*. 1985;99(4):486-8.
9. Connors TA. I. Alkylating Agents. *Acta Radiologica Diagnosis*. 1971;11(311_suppl):9-17.
10. Regulation of the Minister of Health of the Republic of Indonesia No. 91/2015 about Blood Transfusion Procedure Standards.