

Case study

Arteriovenous Malformation of Rectum causing Lower Gastro Intestinal Bleed Managed Successfully with Trans-Catheter Arterial Embolisation – A Case Report

ABSTRACT

Gastrointestinal arterio-venous malformations are uncommon causes of lower GI bleeding. Rectal AVMs are even rarer, and a high index of suspicion is needed to correctly diagnose them. There is no standardized treatment option for rectal AVMs. The choice of treatment has to be individualized, considering the overall performance and clinical status of the patient. Treatment options range from minimally invasive procedures like embolization to resection procedures such as anterior resection, ultra-low anterior resection, or abdominoperineal resection. Here, we present a case report of a large rectal AVM leading to lower GI bleeding, which was successfully managed by transarterial embolization.

Keywords: Arteriovenous malformation, Coil embolization, Lower GI bleed, Hemangioma, Colorectal hemangioma, Trans-arterial embolization

INTRODUCTION

Gastrointestinal arterio-venous malformations (AVMs) are a rare entity. In the gastrointestinal tract, AVMs are more common in the small intestine and colon. Rectal AVMs are rare, and very few case reports have been published in the literature [1]. AVMs typically consist of an inflow artery, an outflow vein, and a collection of abnormal vessels in between. Most GI AVMs are asymptomatic and are discovered incidentally through endoscopy. However, they can cause severe, painless gastrointestinal bleeding and subsequent chronic anemia [2]. Upper GI endoscopy, colonoscopy, contrast-enhanced CT scan/MRI, along with high-resolution angiography, help in the diagnosis of gastrointestinal AVMs [3]. The choice of treatment for rectal AAVMs includes less invasive procedures like transarterial embolization (TAE) and sclerotherapy, along with more invasive procedures like limited segmental resection, low anterior

Comment [D1]: In my opinion abstract should have a brief description of the case

Comment [D2]: Abbreviate first

Comment [D3]: Abbreviate first , however known

Comment [D4]: You have not abbreviated AAVMs , write arterial AVMs

resection, and abdominal perineal resection [1]. A decision regarding the treatment modality has to be made while considering the patient's overall clinical status and quality of life (QOL).

CASE DESCRIPTION

This 55-year-old gentleman presented to the emergency room at our hospital with a history of lightheadedness followed by an episode of per rectal bleeding. He went to his nearby hospital, where he was stabilized and started on a blood transfusion. He was hemodynamically stable. He is diabetic, hypertensive, and underwent PTCA 3 months ago, following which he has been on antiplatelet drugs (Aspirin). On abdominal examination, no palpable mass is felt, and the abdomen is soft. On per rectal examination, no active bleeding is noticed, and no palpable mass or growth is felt. His Hb is 8.5 g/dL, and other blood parameters are normal. Upper gastrointestinal endoscopy is normal. Colonoscopy revealed blood stains up to the level of the rectosigmoid junction, beyond which it is normal, with no active bleeding/growth/ulcer/lesion noted up to the level of the terminal ileum. A 640-slice contrast-enhanced computerized tomography (CECT) (Fig 1) of the abdomen revealed a well-defined lobulated intensely enhancing vascular mass lesion measuring 5.0 x 8.2 x 7.7 cm (AP x TR x CC) noted in the rectovesical pouch superior to the level of seminal vesicles, anterior to the mid rectum. There was no evidence of calcifications in the mass. The lesion is supplied by multiple prominent dilated superior rectal branches of the inferior mesenteric artery and drained by a tortuous dilated inferior mesenteric vein. The inferior mesenteric vein is dilated and tortuous until the confluence with the splenic vein, which has a maximum calibre measuring 9.2 mm. This lesion had a mass effect over the urinary bladder anteriorly and the rectum posteriorly. The above findings were suggestive of peri-rectal vascular malformation/hemangioma.

Fig 1 – 640 Slice CECT of the pelvis showing enhancing vascular mass lesion in the rectovesical pouch supplied by blood vessels from Inferior Mesenteric Artery.

Comment [D5]: Was

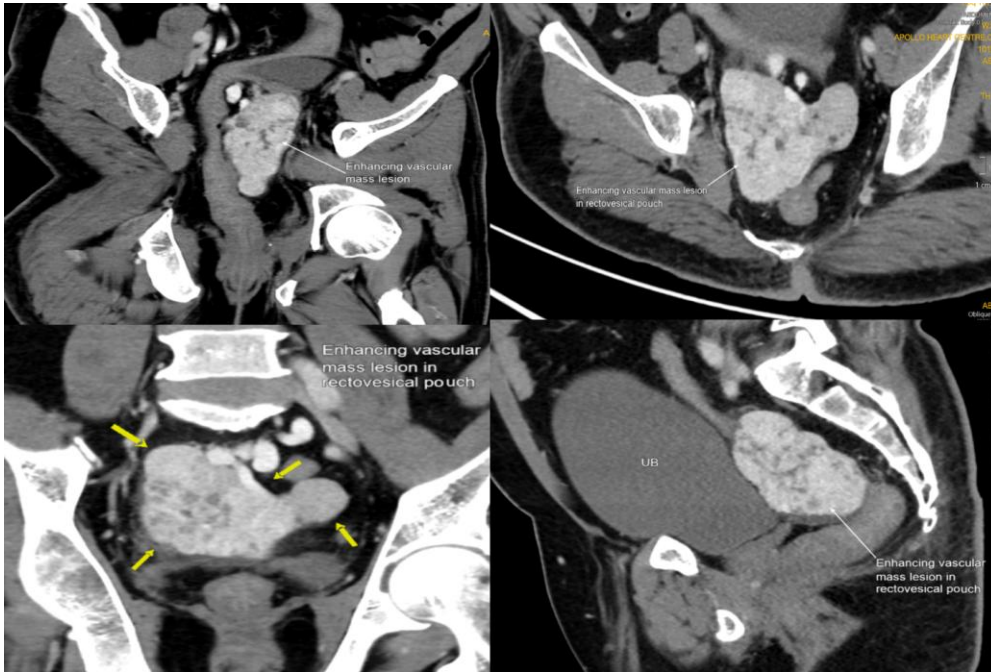
Comment [D6]: Abbreviate

Comment [D7]: Use a connecting word between the sentences

Comment [D8]: was

Comment [D9]: was

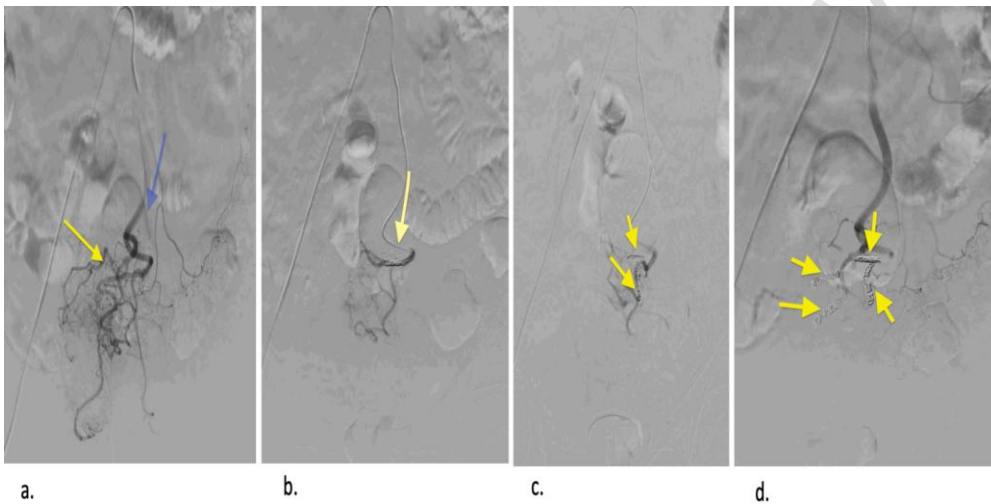
Comment [D10]: was



Considering the recent diagnosis of Coronary artery disease and PTCA, a decision was made to opt for a less invasive interventional procedure in the form of Trans Arterial Embolization (TAE). Under local anaesthesia and ultrasound guidance, the right common femoral artery was accessed through an AA guidewire, and an angiogram was performed. The angiogram (Fig. 2) revealed multiple feeders from the inferior mesenteric artery. Super-selective cannulation of the feeders was performed using a micro-catheter and guidewire. Embolization was carried out using 500-700 μ Polyvinyl alcohol (PVA) particles, and four 14x3 cm coils were utilized. Post-procedure angiogram showed no obvious filling of the lesion through the feeders, confirming the completion of embolization. After the procedure, the patient remained hemodynamically stable and was discharged from the hospital the following day.

Comment [D11]: were

Fig 2 – Pictures showing trans arterial embolization a. pre-procedure angiogram showing multiple feeder branches arising from the Inferior mesenteric artery, b and c . embolization with coil showing decreased filling of AVM and d. Post-procedure angiogram showing complete absence of filling of the AVM.



DISCUSSION

Gastrointestinal Arterio-Venous Malformations (AVMs) are rare; among them, 56% occur in the colon, 43% in the small intestine, whereas Rectal AVMs are extremely rare [4]. The etiology of AVMs is not clearly understood; AVMs mainly fall into two categories - Congenital and Acquired. Congenital cases are related to genetic abnormalities in the formation of transforming growth factor beta.[5] The acquired cases were explained by the hypothesis of a precapillary sphincteric dysfunction and degeneration of the postcapillary venules caused by vascular dilatation and obstruction of venous outflow in the submucosa due to dilation of the lumen of the digestive tract [6].

Comment [D12]: u have already abbreviated it above in your text

A common presentation of Rectal AVM is an intermittent bloody stool, pain, and mild anemia; however, they have varied symptomatology, including mild abdominal discomfort, constipation, vague abdominal pain, and bleeding per rectum. Rectal AVMs can also present with massive blood loss requiring multiple blood transfusions [7]. Once the patient is hemodynamically stable, it is important to thoroughly investigate and rule out other known causes of Lower GI bleed. The initial investigations include Upper GI endoscopy, Lower GI endoscopy, Contrast Enhanced Computerized Tomography (CECT), and blood investigations. Endoscopy/Colonoscopy is not of much benefit as, most of the time, the mucosa appears normal, as it has been in our patient. If there is a suspicious AVM in CECT or MRI, Digital Subtraction Angiography helps in the definitive diagnosis of AVM [8]. Computed tomography angiography (CTA) plays an important role in the diagnosis of AVM with a sensitivity, specificity, and positive predictive value of 70%, 100%, and 100%, respectively [9].

The choice of treatment for rectal AVMs depends on multiple factors like the size of the lesion, location of the lesion, and clinical status of the patient. Conservative management can be an option for asymptomatic or mild/non-progressive AVMs. These can be followed up with the help of transrectal endoscopic ultrasonography [10]. Successful conservative management and follow-up with the help of tranexamic acid have been reported [11]. Treatment options consist of reducing or arresting blood flow to the AVM and complete removal of the AVM. Endoscopic treatment with the help of Sclerotherapy or elastic ligation can be used as both a diagnostic and a therapeutic intervention. However, incomplete obliteration of vessels and the toxicity of the sclerosant are concerns [12]. Trans-arterial embolization (TAE) is a promising, less invasive treatment that can control the symptoms. Cyanoacrylate adhesives such as NBCA (N-butyl

Comment [D13]: are of concern

cianoacrylate) or Onyx (ethylene vinyl alcohol polymer) and spherical embolic material (Embosphere®) can be used as embolizing agents in TAE [13]. Materials like reels, embolization coils, gel foam, collagen, autologous blood clots, and ethanol (Polyvinyl alcohol particles) have been used as agents in TAE [14]. The arrest of the flow can be confirmed immediately after the procedure in TAE. The dreaded complication of TAE includes intestinal ischemia, with a 14 to 20% rate in the literature [15]. TAE can also be used in case of recurrence after primary treatment and as a modality for palliative treatment as it avoids surgery and is less invasive [10].

The choice of surgical treatment for Rectal AVMs varies depending on the characteristics and location of the lesion. Apart from the morbidity and complications of the surgical procedures, the possibility of a permanent stoma has to be considered. Procedures like Anterior resection, abdominoperineal resection, or ultralow anterior resections with colo-anal anastomosis by either a trans-anal approach [16], laparoscopic approach [17], and robotic approach [18] were described in various case reports. While surgical resection promises complete removal of the lesion and has the least chance of recurrence, these procedures are technically challenging with associated morbidity. They should be performed only by surgeons with considerable expertise in colorectal surgery.

CONCLUSION

Rectal Arteriovenous Malformations are a rare entity. A high index of suspicion is needed to diagnose it correctly. Colonoscopy, CECT Abdomen, and Digital subtraction angiography help arrive at a diagnosis. The choice of treatment ranges from lesser invasive procedures like Sclerotherapy and trans-arterial embolization to more invasive procedures like surgical resections with or without a stoma. The procedure of choice has to be decided, keeping in mind

the patient's overall clinical status and quality of life. Transarterial embolization appears to be a reliable procedure that can be used safely in Gastrointestinal AVMs.

REFERENCES

1. Ishikawa S, Mukai S, Hirata Y, Kohata A, Kai A, Namba Y, Okimoto S, Fujisaki S, Fukuda S, Takahashi M, Fukuda T. Rectal arteriovenous malformation treated by transcatheter arterial embolization. *Case Reports in Gastroenterology*. 2020 May 7;14(1):7-14.
2. Trieu DT, Ho AH, Van Le Q. Colorectal Arteriovenous Malformations causing Prolonged Bleeding were Managed Successfully by Laparoscopic Low Anterior Resection with Sphincter Preservation: A Case Report. *The Korean Journal of Gastroenterology*. 2023 May 25;81(5):216-20.
3. Richter JM, Hedberg SE, Athanasoulis CA, Schapiro RH. Angiodysplasia: clinical presentation and colonoscopic diagnosis. *Digestive diseases and sciences*. 1984 Jun;29:481-5.
4. Kobayashi K. Arteriovenous malformation of the Intestine: review of 230 cases reported in Japan. *Stomach and Intestine*. 2000;35(6):753-62.
5. McAllister KA, Grogg KM, Johnson DW, et al. Endoglin, a TGF-beta binding protein of endothelial cells, is the gene for hereditary haemorrhagic telangiectasia type 1. *Nat Genet*. 1994;8:345-351.
6. Boley SJ, DiBiase A, Brandt LJ, Sammartano RJ. Lower intestinal bleeding in the elderly. *The American Journal of Surgery*. 1979 Jan 1;137(1):57-64.
7. Richardson JD, Max MH, Flint Jr LM, Schweisinger W, Howard M, Aust JB. Bleeding vascular malformations of the intestine. *Surgery*. 1978 Sep 1;84(3):430-6.

8. Parthasarathy M, Basu A, Omer AR. Massive per rectal bleeding in a child due to caecal arteriovenous malformation treated successfully by embolisation. *Case Reports*. 2013 Aug 21;2013:bcr2013010187.
9. Junquera F, Quiroga S, Saperas E, Pérez-Lafuente M, Videla S, Alvarez-Castells A, Miró JR, Malagelada JR. Accuracy of helical computed tomographic angiography for the diagnosis of colonic angiodysplasia. *Gastroenterology*. 2000 Aug 1;119(2):293-9.
10. Mallios A, Laurian C, Houballah R, Gigou F, Marteau V. Curative treatment of pelvic arteriovenous malformation—an alternative strategy: transvenous intra-operative embolisation. *European journal of vascular and endovascular surgery*. 2011 Apr 1;41(4):548-53.
11. Cotzias E, Rehman SF, Arsalani Zadeh R, Smith D. Conservative management of diffuse cavernous haemangioma of the sigmoid and rectum. *The Annals of The Royal College of Surgeons of England*. 2020 Jan;102(1):e1-3.
12. Seffinger MA. Our past, present, and future are in our hands. *J Am Osteopath Assoc*. 2014 Jan;114(1):4. doi: 10.7556/jaoa.2014.001. PMID: 24384967.
13. Saito N, Sasaki S, Shimizu T, Nozaki A, Yamatsu Y, Takahashi K, et al. Embolization with microspheres in the treatment of subcutaneous arteriovenous malformation: a case report. *Sosyo*. 2015 Apr;6(2):77–81.
14. Almadi MA, Almessabi A, Wong P, Ghali PM, Barkun A. Ectopic varices. *GastrointestEndosc*. 2011 Aug;74(2):380-8. doi: 10.1016/j.gie.2011.03.1177. Epub 2011 May 25. PMID: 21612777.
15. Fishman SJ, Shamberger RC, Fox VL, Burrows PE. Endorectal pull-through abates gastrointestinal hemorrhage from colorectal venous malformations. *J Pediatr Surg*. 2000 Jun;35(6):982-4. doi: 10.1053/jpsu.2000.6947. PMID: 10873049.

16. Zeng Z, Wu X, Chen J, Luo S, Hou Y, Kang L. Safety and Feasibility of Transanal Endoscopic Surgery for Diffuse Cavernous Hemangioma of the Rectum. *Gastroenterol Res Pract*. 2019 Jun 19;2019:1732340. doi: 10.1155/2019/1732340. PMID: 31320895; PMCID: PMC6607704.
17. Fu ZW, Wang LX, Zhang ZY, Luo QF, Ge HY. Three-dimensional laparoscopy-assisted bowel resection for cavernous hemangioma of the rectum: Report of two cases. *Asian J Endosc Surg*. 2019 Jul;12(3):337-340. doi: 10.1111/ases.12636. Epub 2018 Aug 9. PMID: 30094939.
18. Fujii Y, Kobayashi K, Kimura S, Tsuji E, Miyai H, Tanaka M, Takiguchi S. Robotic surgical procedure for diffuse cavernous hemangioma of the rectum: A case report. *Asian J Endosc Surg*. 2020 Oct;13(4):564-568. doi: 10.1111/ases.12783. Epub 2020 Jan 20. PMID: 31960573.