

Determination of Age-Related Variations with Orbital Dimensions of the Orbit Based on Plain Radiographs of Nigerians: A 5-Year Retrospective Cross-Sectional Study

ABSTRACT

Introduction: Cephalometry has been widely used in substantial aspects of medicine. The morphometric assessment of the orbit and familiarity with its anatomy is significant clinically in the diagnosis of lesions in the orbit and reconstructive surgeries of the face. There is an important link between diagnostic radiology and ophthalmology. Most previous studies use direct techniques on living, cadaveric specimens, or dry bones to assess the orbital dimensions.

Aim: To determine the relationship between the orbital dimensions and the increase in age

Materials and Methods: A 5-year retrospective cross-sectional study using 255 normal skull radiographs obtained from the Department of Diagnostic Radiology of Usmanu Danfodiyo University Teaching Hospital was done. The radiographs were visualized on an illuminator and measurements of the orbital dimensions were made with the aid of a transparent ruler and a pencil.

Results: The orbital dimensions of the subjects used in this study in relation to their age groups revealed a steady rise in the dimensions with the increase in age until the age range of 51-60 years when it reaches the peak value and then gradually declines. In the measurement of the interorbital distance in relation to age, it was similarly found to increase with increasing age of the subjects however reaching its peak at the age range of 31-40 years then gradually dropping.

Conclusions:

The orbital dimensions show a positive correlation with increasing age.

Keywords: *Orbit, Cephalometry, Dimensions, Morphometric, Radiographs*

INTRODUCTION

Cephalometry is a branch of anthropometry that describes measurements of head and face in cadaveric, living, or radiological specimens. This aspect of physical anthropology has been widely used in a substantial aspect of medicine¹. Attempts to establish reliable cephalometric differentiation between races are as old as craniometry itself and although the mandible and cranial capacity are in this connection less dependable, satisfactory characterization has been established for some racial groups and especially for Caucasians and Negroes, it has been utilized to classify people according to race, criminal temperament, intelligence, etc².

Forensic anthropologists believe that by taking some 90 measurements of a skull they can correctly assign its owner's continent of origin – broadly speaking, its race, though many anthropologists prefer not to use the term craniometry – with 80 percent accuracy³. **Sex estimation is recommended based on the orbital region, as sexual discrimination is possible with more than 80% accuracy for both sexes, which is a high percentage of correct estimation⁴.**

The orbital margin has the form of a quadrilateral with rounded corners. The relationship between the orbital height and width is given by the *orbital index*, which varies in the different races of mankind⁵.

The orbital opening is directed forward and slightly laterally and is titled so that the upper and lower margins slope gently downwards from the medial to the lateral side. The orbital margin is made up of three bones: the frontal, zygomatic, and maxilla⁶.

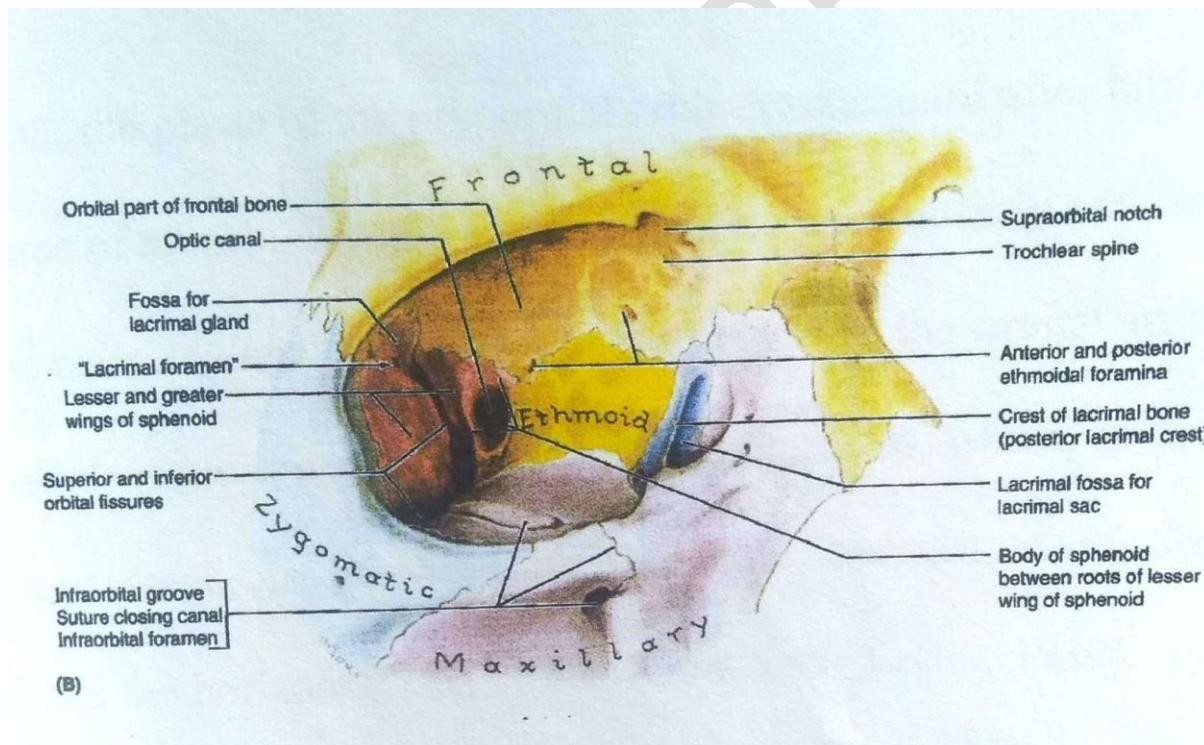


Figure 1: Anterior View of the Orbit showing its parts (Adopted from Keith L. Moore's Textbook of Clinically Oriented Anatomy)⁶.

The morphometric assessment of the orbit by radiography and familiarity with its anatomy is significant clinically in knowing how to diagnose and tackle subtle orbital bony injuries, subtle lesions of retro-orbital space and the orbital muscles, and reconstructive

surgeries⁷. It is also relevant in diagnosing disease states of the orbit in case of space-occupying lesions especially those causing proptosis, edema of the soft tissue, and/or hemorrhage⁸. There is an important link between diagnostic radiology and ophthalmology⁹. **Moreover, knowledge of orbital morphometry is valuable in evaluating the severity and complications that may arise before surgeries are performed to enhance adequate planning¹⁰.**

Most of the previous work was done on Caucasian⁴, Asian subjects^{7,9}, and a few Africans in Nigeria¹, and were mostly done via invasive/direct techniques of measurement on living¹ and cadaver or dry skull bones⁵.

The aim of the study was to assess the dimensions and normal variants of the anatomical features of the orbit from normal anteroposterior plain skull radiographs of subjects as was applied by Lloyd and Glyn in 1973. The objectives were to establish baseline data for the orbital heights, orbital widths, the shape of the orbit, and their prevalence for the population under the study. Thus, the research provided findings on different dimensions of the orbits using radiographic methods in Nigerian subjects. It also provided reference points in the dimension of the orbit in Nigerians using plain X-ray and its relationship with the increase in the age of individuals.

MATERIALS AND METHODS

This retrospective cross-sectional study of normal plain skull radiographs collected from the Radiology Department, Usmanu Danfodiyo University Sokoto was over a 5-year period from September 2004 to September 2009. Selection of the radiographs for the study was based on clear visualization and recognition of orbital margins on both right and left sides and determination of a distinct lower orbital margin from the superimposition of the petrous part of the temporal bone which is usually forecasted there in the view.

All the radiographs were ascertained to have been taken by well-trained radiographers in a standardized condition and manner (target to film distance/film to focus distanced TFD/FFD of 40 inches (100) cm of which only radiographs interpreted by well-trained radiologists were selected. The radiographs studied were of good quality and clarity of the anatomical features of the orbital shape was noted by direct visualization as either oval, round, or quadrangular.

Statistical Methods

The data was initially sorted out manually, tabulated, and then entered on a computer using Microsoft Word and Microsoft Excel.

INSTANT Statistical Package was used for the data analysis. Comparisons of mean values in relation to the age distribution of the subjects were done using the Student's T-Test. Chi-Square (with Yates correction) was used for the comparison of proportions. Proportional percentages of orbital types based on orbital shapes observed were also analyzed.

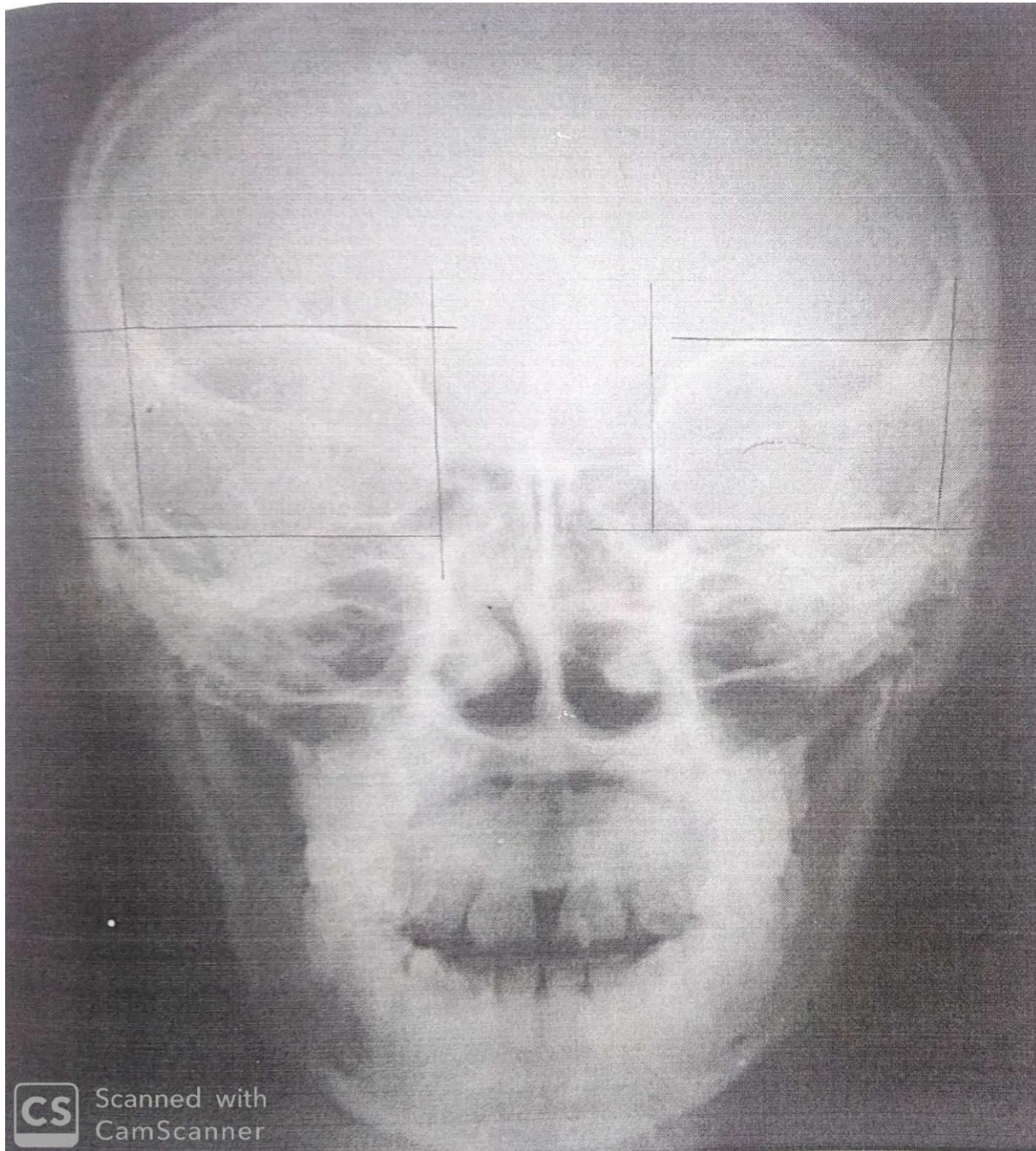


Figure 2: A posteroanterior view of a 31-year-old male skull radiograph illustrating the Orbital dimension.

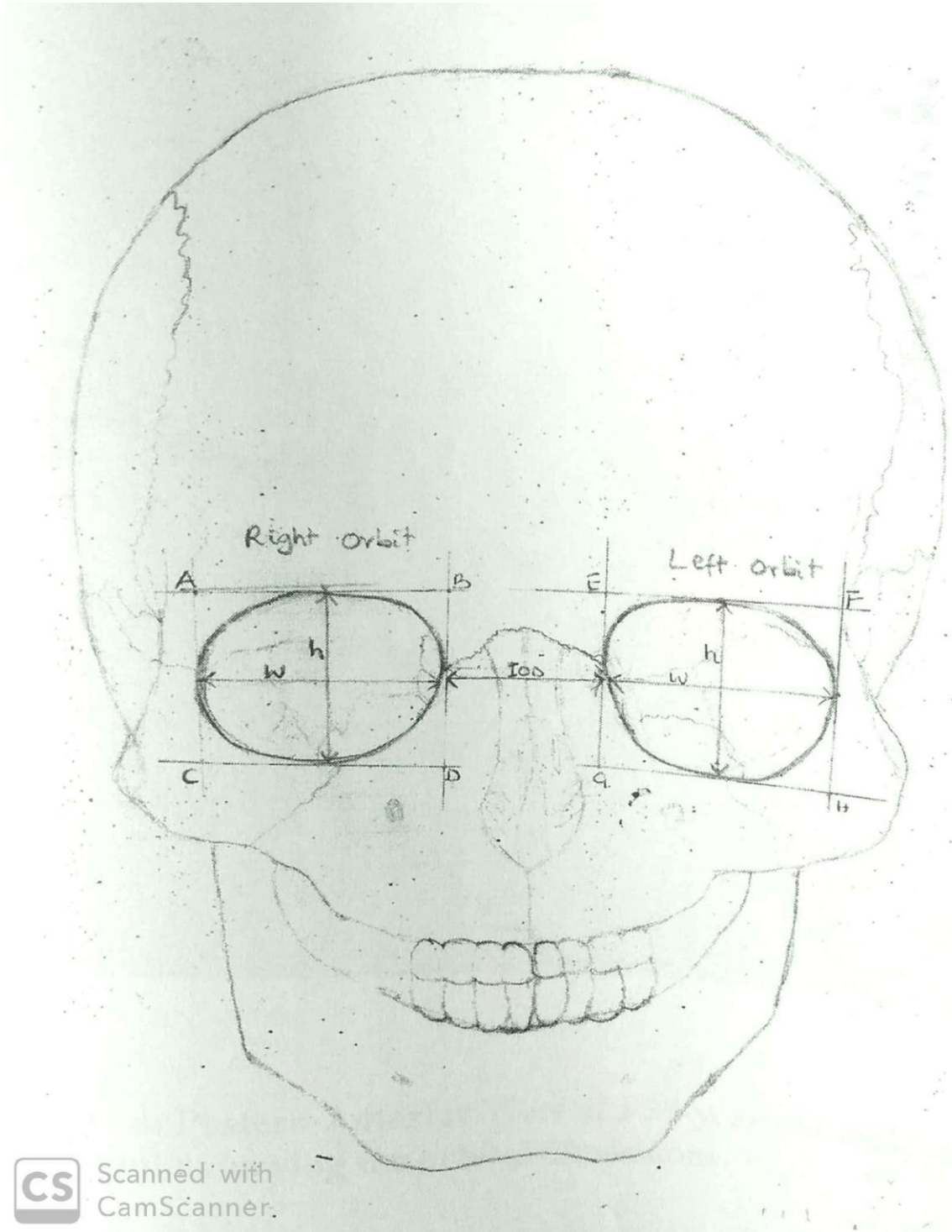


Figure 3: An annotated diagram of the anterior aspect of the skull showing the orbits and their dimensions.

RESULTS

Five hundred radiographs of the skull were collected from the archives of the Radiology Department at Usmanu Danfodiyo University Teaching Hospital Sokoto for the study. The radiographs were from subjects seen from September 2004 to September 2009. Two hundred and fifty-five satisfied the inclusion criteria.

Mean and Standard Deviation ($\pm 1SD$) of the Orbital Dimensions in Relation to Age Group

Age Group (Yrs)		1-10	11-20	21-30	31-40	41-50	51-60	61-70
Frequency		34	48	70	54	32	13	3
	Height(mm)	29.8 \pm 6.6	38.8 \pm 6.6	35.7 \pm 7.8	38.1 \pm 7.8	39.3 \pm 8.8	41.2 \pm 7.1	39.3 \pm 7.4
Right Orbit	Width(mm)	36.3 \pm 2.8	39.3 \pm 5.2	40.9 \pm 4.1	42.5 \pm 5.3	42.1 \pm 6.0	41.6 \pm 5.0	39.7 \pm 8.5
	Index (%)	82 \pm 18	84 \pm 16	87 \pm 16	90 \pm 15	93 \pm 17	99 \pm 4	100 \pm 13
	Height(mm)	29.4 \pm 6.2	35.5 \pm 7.2	35.2 \pm 7.2	37.8 \pm 7.4	38.7 \pm 8.8	41.1 \pm 6.4	39.0 \pm 8.7
Left Orbit	Width(mm)	36.7 \pm 3.0	39.2 \pm 5.6	41.7 \pm 4.5	42.9 \pm 5.9	42.6 \pm 5.8	43.2 \pm 5.4	42.3 \pm 6.7
	Index (%)	81 \pm 7.8	86 \pm 18	84 \pm 4	89 \pm 16	91 \pm 15	96 \pm 14	92 \pm 19
Inter Orbit Distance (mm)		29.8 \pm 4.8	33.5 \pm 6.1	35.5 \pm 6.1	35.6 \pm 5.2	35.1 \pm 4.6	33.9 \pm 4.4	31.0 \pm 1.0

Table 1: Mean and Standard Deviation ($\pm 1SD$) of the Orbital Dimensions in Relation to Age Groups

Table 1 above displayed the mean orbital dimensions and index with respect to age groups in decades i.e., 1-10, 11-20, and so on. The age ranges of the subjects under study were 1-70 years. The dimensions were increased with age until they reached the peak at the age group of 51-60 before they started declining.

As seen in the above table, there is a steady increase in the orbital heights, orbital widths, and orbital indexes of both the right and left orbit and their inter-orbital distance from the age group of 1-10 to the age group of 11-20.

The lowest value of the orbital heights was seen in the age group of 1-10 with 29.8mm (SD=6.6) on the right and 29.4mm (SD=6.2) on the left and the highest value of the orbital height is seen in the age group of 51-60 with orbital right height of 41.23mm (SD=7.1) and left orbital height of 41.1mm (SD=6.4). The lowest value of orbital width was seen in the age group of 1-10 with a right orbital width of 36.3mm (SD=2.8) and a left orbital width of 36.7mm (SD=3.0) and the highest value is seen in the age group of 31=40 with right orbit width of 42.5mm (SD=5.3) and the left orbital width of 42.6mm (SD=5.8). the lowest value of orbital index is seen in the age group of 1-19 with the right orbital index of 82 (SD=18) and left orbital index of 81 (SD=18) and the highest value is seen in the age group of 61-70 and 51-60 with the right orbital index of 100 (SD=3) and left orbital index of 97 (SD=14) respectively. The longest inter-orbital distance is seen in the age group of 31-40 with 35.6mm (SD=5.2) and the least interorbital distance is seen in the age group of 1-10 with 28.6mm (SD=4.8).

Parameters	Mean Values (mm)				Age Groups (Yrs)					
	Right		Left		1-5			6-10		
Age Group (Yrs)	1-5	6-10	1-5	6-10	df	t	P Value	df	t	P Value
Orbital Height (mm)	28.6±8.1	30.3±5.5	27.9±7.8	30.2±4.7	32	2.04	0.81	36	2.03	0.98
Orbital Width (mm)	35.3±4.4	36.1±3.0	35.8±3.5	36.6±3.5	32	2.04	0.70	36	2.03	0.53
Orbital Index	82±24	84±11	79±24	83±12	32	2.04	0.72	36	2.03	0.78
Inter	24.8±4.9	30.6±4.6	24.8±4.9	30.6±4.6						

Orbital Distance (mm)										
--------------------------------------	--	--	--	--	--	--	--	--	--	--

Table 2: Comparison of Mean Orbital Dimensions between the Sub-Age Group 1-5 and 6-10

Table 2 compares the mean orbital dimensions of the sub-age groups 1-5 and 6-10. The mean orbital height for the sub-age groups 1-5 and 6-10 are 28.6mm (SD=8.1) on the right and 27.9mm (SD=7.8) on the left with ($t=2.04$; $df=32$; $p=0.81$) and 30.3mm (SD=5.5) on the right and 30.2mm (SD=4.7) on the left with ($t=2.03$; $df=36$; $p=.98$) respectively.

The mean orbital widths of the sub-age groups 1-5 were 35.5mm (SD=4.4) for the right and 35.8mm (SD=3.5) for the left with ($t=2.04$, $df=32$, $p=0.70$); 6-10 were 36.1mm (SD=3.0) for the right and 36.7mm (SD=3.5) for the left with ($t=2.03$, $df=36$, $p=0.53$).

The mean orbital index for the age group 1-5 was 82 (SD=24) for the right and 79 (SD=24) for the left with ($t=2.04$, $df=32$, $p=0.72$); for the age group 6-10 was 84 (SD=11) for the right and 83 (SD=12) for the left with ($t=2.03$, $df=36$, $p=0.78$). the mean interorbital distance for sub-age group 1-5 was 24.8mm (SD=4.9), and 30.6mm (SD=4.6) for the sub-age group 6-10.

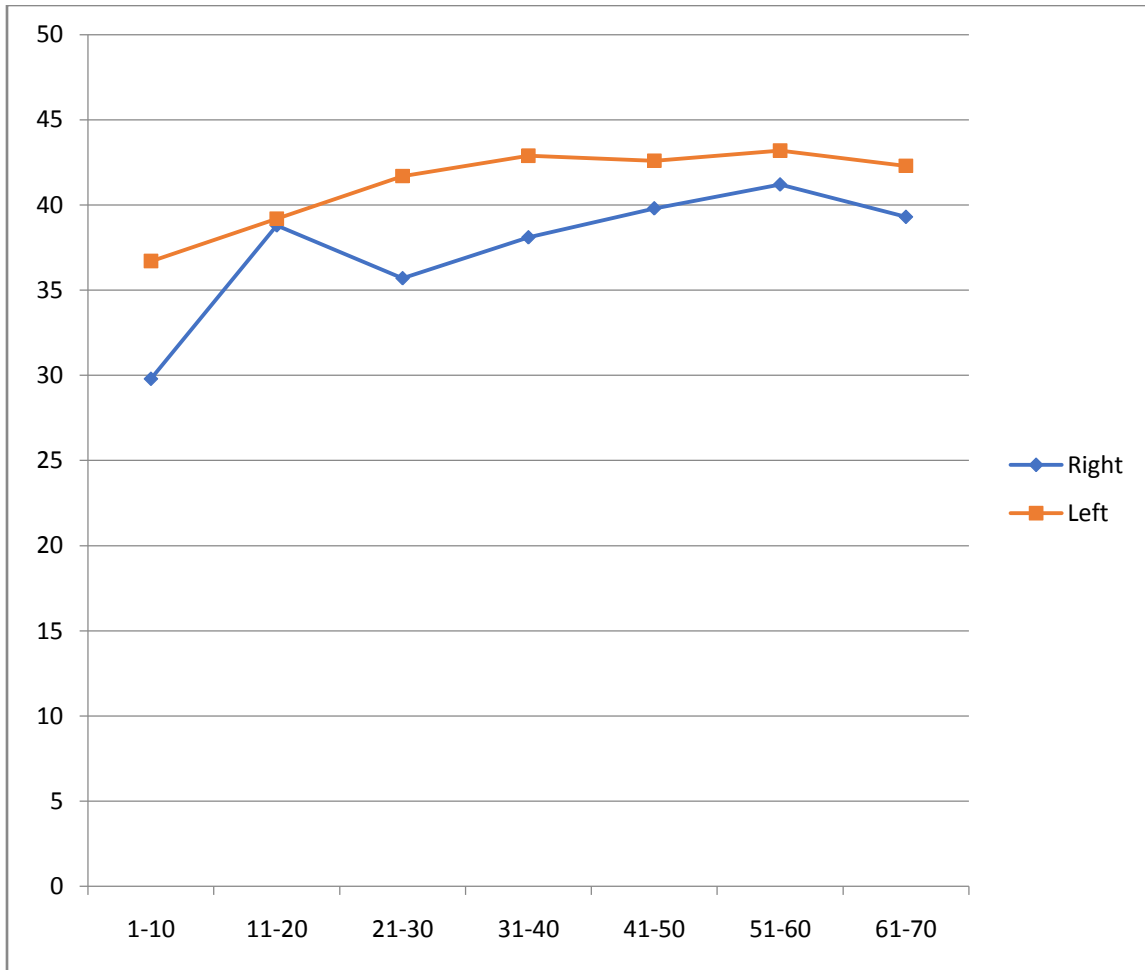


Figure 4: Graphical Representation of the Mean and Standard Deviation of the Orbital Height in Relation to Age Groups.

UNDER REVIEW

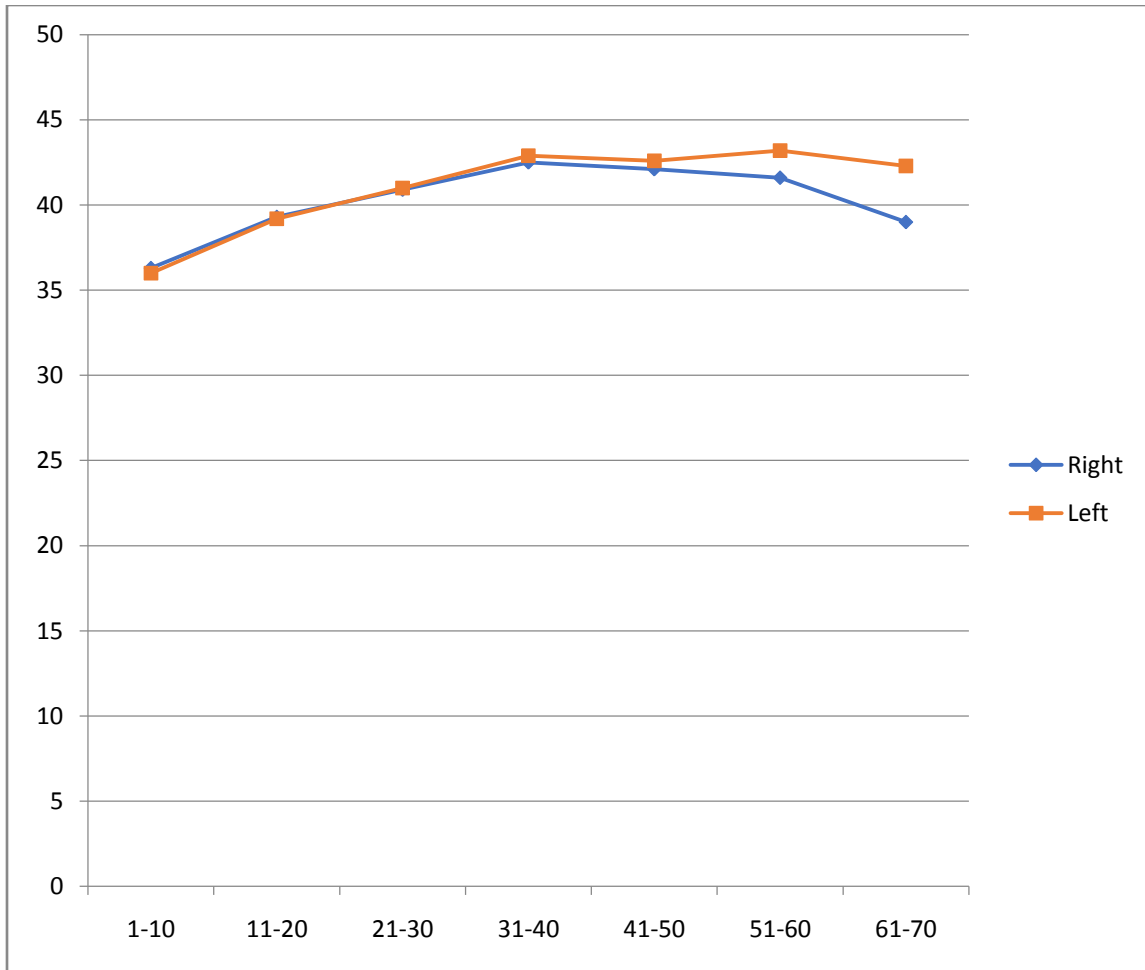


Figure 5: Graphical Representation of the Mean Orbital Width in Relation to Age Groups.

UNDER REVIEW

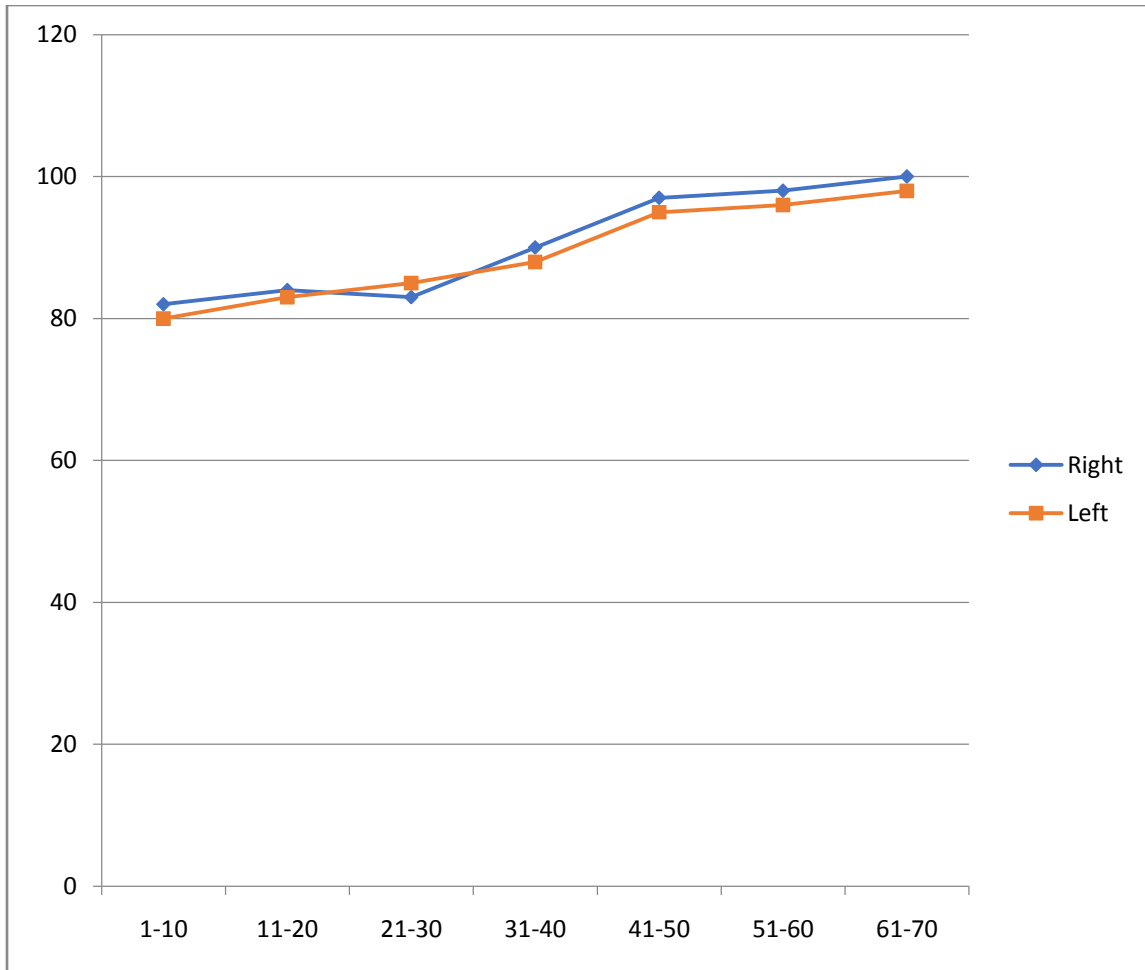


Figure 6: Graphical Representation of the Mean Orbital Index in Relation to Age Groups.

UNDER REVIEW

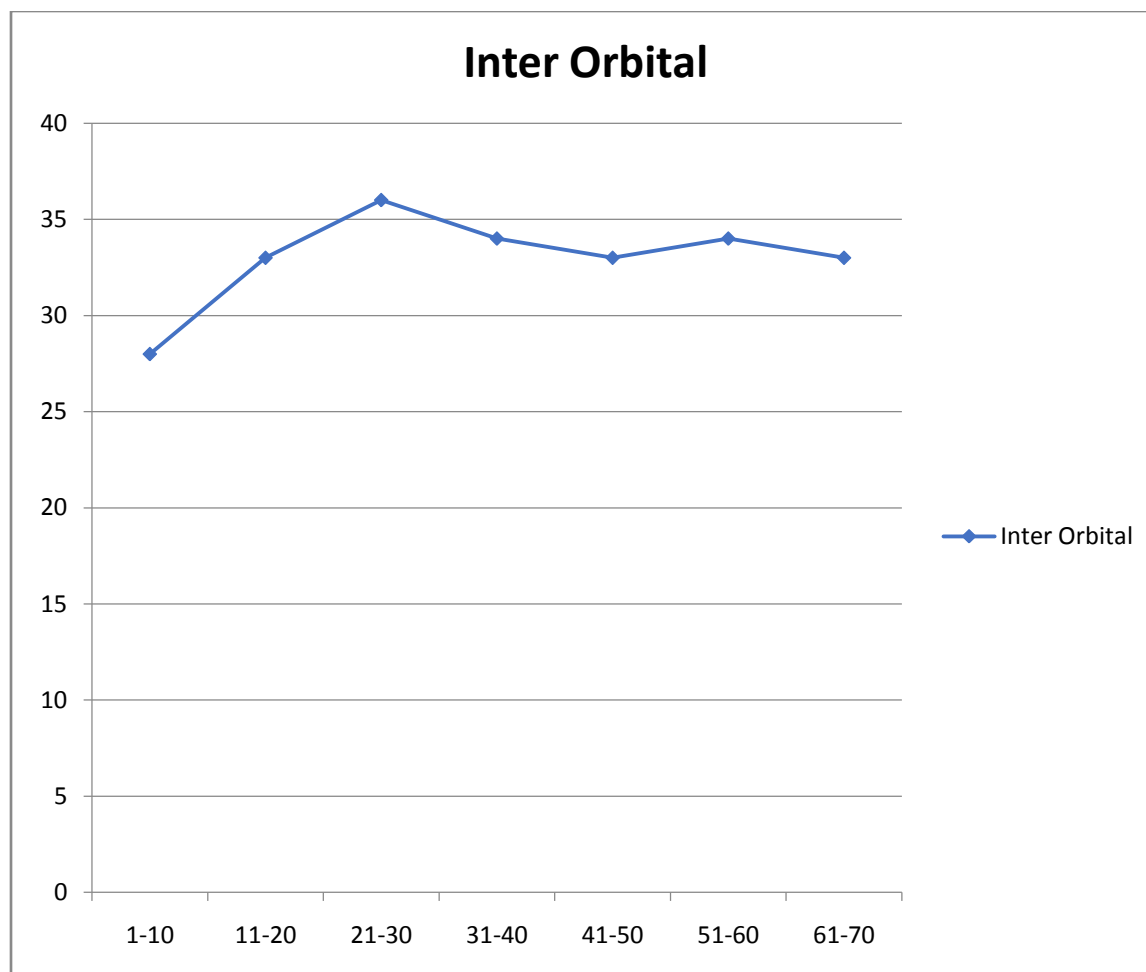


Figure 7: Graphical Representation of the Mean Interorbital Width in Relation to Age Groups.

DISCUSSION

Previous studies on the assessment of the orbital dimensions were done directly either on dry skulls or living beings or cadaveric bodies^{1,5,8,9}. Radiographic studies were also employed where plain radiographs were used as well as Ultrasonography, Digital Imaging, Conventional Tomographic Scans, Computed Tomographic Scans, Magnetic Resonance Imaging, Contrast Studies, and Colour Doppler⁸. This current study assessed the dimension and normal variants of the anatomical features of the orbit from normal anteroposterior plain skull radiographs of subjects as was applied by Lloyd and Glyn.

The mean value of the orbital heights of all the subjects for the right and left orbits found in this study were 35.70 ± 8.37 on the right and 35.50 ± 8.05 on the left and the minimum range of the heights was 19.00mm on the right and 18.00mm on the left. The maximum height was

58.00mm on the right and 68.00mm on the left. Thus, there is a slight increase in the range of the left orbital heights as compared to that of the right. However, the difference is not statistically significant. **The above findings were similar but higher than the findings of Khwaja *et. al* which was carried out in Asian Populations¹⁰.**

The mean value of the orbital widths of all the subjects under study were 40.53 ± 5.23 on the right and 41.04 ± 5.53 on the left and the minimum range of values for the width was 26.00mm on both sides. The maximum ranges of the orbital widths were 54.00mm on the right and 55.00mm on the left virtually no difference between the two sides and no statistically significant difference of significance between the two sides.

In the measurements of the interorbital distance, it was found to steady rise in the distance until the third decade of life when it maintained a plateau with a minimum value of 28.59 ± 4.2 mm at the age group of 1-10years and the maximum value of 35.00 ± 6.3 mm attained at the age group of 31-40 years.

The orbital dimensions of the subjects used in this study in relation to their age groups revealed a steady rise in the dimensions with the increase in age until the age range of 51-60 years when it reaches the peak value and then gradually declines. In the measurement of the interorbital distance in relation to age, it was similarly found to increase with increasing age of the subjects however reaching its peak at the age range of 31-40 years then gradually dropping.

CONCLUSIONS

The study reported that the orbital dimensions rise steadily with an increase in age and the measurements of the left were slightly higher than those of the right. However, the differences were not statistically significant.

Recommendations

It is essential to do more on the Cephalometry of the orbit in Nigerian subjects or blacks of African descent on a larger scale to generate baseline data for reference. More studies can also be done to identify the likely differences in dimensions, size, and shape of the orbit that may exist between the diverse groups in Nigeria and other African countries. Comparative studies can be carried out to compare plain radiographic measurement of the orbit with studies using more modern equipment such as Computerized Tomography and Magnetic Resonance Imaging.

ETHICAL CONSIDERATION

Ethical clearance for the study was obtained from the Ethical Committee of the Radiology Department of Usmanu Danfodiyo University Teaching Hospital Sokoto, Nigeria, with the ethical clearance number UDUTH/HREC/2010/NO.827.

REFERENCES

1. Umar, M.B.T. Singh, S.P., Shugaba, A.I. (2005): Orbital Measurements among the Ethnic Groups of Plateau State, Nigeria, Highland Medical Research Ltd. July-December; Bol. 3. 2: 26-28.
2. Westcott, D.K and Jantz, R.L (1999) Anthropometric Variation Between the Sixious and Assiniboine. Human Biology (United States), 71(5): 877-888.
3. Wade N.: 2002. A New Look at Old Data May Discredit a Theory on Race. New York Times. 8 October.
4. Zurifa A, Uzeir A, Lejla D, Haris H, Alma V, (2023) A Geometric Morphometrics Approach for Sex Estimation Based on the Orbital Region of Human Skulls from Bosnian Population. Hindawi Scanning Volume 2023, Article ID 2223138, 9 pages <https://doi.org/10.1155/2023/2223138>.
5. Karakas, P., Bozkir, M. and Oguz, O Morphometric Measurements from Various Reference Points in the Orbit of Male Caucasians. Surgical and Radiologic Anatomy, 2002, Vol. 24, No.6 P 358-362.
6. Moore, Keith L., Arthur F. Dalley, and Anne Agur. (2014). *Clinically Oriented Anatomy*. 7th ed. Philadelphia, PA: Lippincott Williams and Wilkins.
7. Williams, P.L; Bannister, L.H; Berry M.M; Collins, P.; Dyson, P; Dussek, J.E. Ferguson, M.W.J: Gray's Anatomy in: Skeletal System Edited by Soames, R.W. Churchill Livingstone, Edinburgh, London. 555-560. 1999.
8. Lloyd M.A., Glynn A.S (1973) Radiology of the Orbit, W.B. Saunders, and Company Ltd London. 1st Edition 1-29.

9. Manorama, B. Sudha, S. Veena, C. *et al.*, (2006): Diagnosis Radiology. Neuroradiology including Head and Neck Imaging. Jaypee Brothers Medical Publishers (p) Ltd 2nd Edition 19:437-457.
10. Khwaja MJ, Shaikh SH, Hiware SD, et al. Morphometric Assessment of Orbit in the Human Skull. *J Evolution Med Dent Sci* 2020;9(48):3623-3627, DOI: 10.14260/jemds/2020/796.
1. Blodi, F.C (1975). Developmental anomalies of the skull affecting the eye. *Archives of Ophthalmology*.**57**: 593-610.
2. Helmy, I. D Tadros, A.A., and Michael, M. A (1969). The Anatomical Basis of Medical Practical Practice. The Human Skeleton. Alexandria 1st Edition 194-196.
3. Hogan, M.J., and Zimmerman, L.E: Ophthalmic Pathology, Ed.2, Philadelphia, 1962, W.B. Saunders and Co.
4. Lombardi, G. (1971). Orbitography. In Newton, T.H and Potts, D.G: Radiology of the Skull and Brain. St. Louis, C.V Mosby Co.
5. Newton, T.H and Potts, D.G (1971) (Editors) Radiology of the Skull and Brain, the Skull: Volume 1, Book 2. 20(5) 463-486.
6. Saddler, T.W: Langman's Medical Embryology; Lippincott Williams & Wilkins Co. India. 10th Edition. 9:125-132. 2006.
7. Santo Neto, H: Penteado, C.V: de Carvath, V.C (1985): Presence of a Groove in the lateral wall of Human Orbit. *Journal of Anatomy*.**138**: 631.
8. Susan, S. Harold E *et al.*, (2005). Gray's Anatomy. The Anatomical Basis of Clinical Practice. Elsevier Churchill Livingstone. 39th Edition. 27: 487-489; 28:493-495; 48:688-690.
9. Zizmor, J: Atlas of Orbital Radiography (Section One). Birmingham Alabama: Aesculapius. 1973.