

# Evaluation of Injectable Platelet-Rich Fibrin (i-PRF) As an Endogenous and Autologous Tissue Regenerator

## ABSTRACT

**Introduction:** Cutaneous ageing, an inherent process with advancing time, often detrimentally impacts self-esteem due to manifestations like wrinkles, blemishes, dehydration, sagging, and reduced tissue vitality. A contemporary trend seeks natural approaches to facial rejuvenation. Injectable Platelet-Rich Fibrin (i-PRF) emerges as a noteworthy solution owing to its biological origin and autologous nature. **Materials and Methods:** Evaluating i-PRF's efficacy in counteracting ageing signs, we employed a 16 MHz high-frequency ultrasound device and meticulous photographic documentation. 26 females, aged 35-55, underwent three i-PRF sessions. Statistical scrutiny utilised a paired t-test ( $\alpha = 0.05$ ) to assess dermal modifications. Self-Perception Index scores underwent Wilcoxon testing ( $\alpha = 0.05$ ) for significant enhancements. Comparisons of newly captured frontal and profile photographs (D and E) with initial images aided visible change assessment. **Results and Discussion:** Compelling data analysis evidenced a notable dermal thickness increase post-intradermal i-PRF application. P-values for examined regions were: glabella ( $P < .00269$ ), frontal D ( $P < .00018$ ), frontal E ( $P < .00014$ ), cheek D ( $P < .00709$ ), and cheek E ( $P < .0008$ ). These results underscore substantial dermal thickness alterations. Statistical examination of the Self-Perception Index yielded a P-value  $< .0001$ , signifying significant self-perception change post-treatment. **Conclusion:** Intradermal i-PRF application markedly increased dermal thickness, endorsing its potential for dermal restructuring. Furthermore, this approach presents an accessible, cost-effective, and unbiased alternative for facial rejuvenation.

*Keywords: Platelet-Rich Fibrin, ageing, rejuvenation, ultrasound.*

## 1. INTRODUCTION

The skin, comprising 16% of body weight, is essential for protection, nourishment, pigmentation, insulation, and sensory functions [1]. Collagen, an insoluble fibrous protein in the connective tissue, imparts strength and resilience [2]. Constituting 25-30% of body proteins, collagen maintains skin elasticity [3]. Collagen production declines with age, leading to cutaneous aging [4].

Cutaneous ageing results from intrinsic and extrinsic factors [5]. Intrinsic factors involve cellular wear and tear, while extrinsic factors encompass UV exposure, pollution, smoking, alcohol, and lifestyle choices [5]. This process leads to morphological, physiological, and molecular changes at cellular, histological, and anatomical levels [6].

Excessive sun exposure degrades collagen, causing wrinkles [7]. The Telomere hypothesis links cellular ageing to fibroblast telomere loss [8,9].

Aesthetic practices often fall short [13]. Platelet concentrates with abundant growth factors aids tissue repair and rejuvenation. Platelet-derived growth factors trigger fibroblast activities [14].

Platelet-Rich Plasma (PRP) aids regeneration [6,16,17]. PRP is obtained through double centrifugation, but limited leukocytes impede healing [15]. Platelet-Rich Fibrin (PRF) enhances PRP, devoid of chemicals [22].

PRF, a second-gen platelet concentrate, supports tissue engineering [22]. Known as L-PRF, it provides cells, growth factors, and a scaffold [22]. High-force centrifugation yields a dense fibrin matrix [25,26]. A-PRF utilises low force, producing a porous matrix [28,29].

iPRF was introduced by Mourão et al. (2015), and comprehensively explained by Miron et al. (2017) and Wang et al. (2018). Plastic tubes, and centrifugation modifications slow coagulation [25,31]. i-PRF, suitable for facial rejuvenation, allows extended working time [32,33].

Fibrin matrix captures and releases growth factors for tissue healing [14,25,34]. Fibrin's sustained action leads to increased growth factor concentrations [35]. i-PRF from autologous blood enhances safety [25].

Blood centrifugation activates platelets, releasing growth factors for cell migration and proliferation [36]. Transforming growth factor-beta 1 (TGF-1), platelet-derived growth factor (PDGF), and others contribute to regeneration [22,37].

i-PRF reported in various healthcare fields [13,38,39]. Limited data exist on i-PRF in facial rejuvenation [13,40]. This study assesses i-PRF's impact on facial rejuvenation using objective analysis, self-perception, and photos.

Facial aesthetics benefit from platelet concentrate growth factors, promoting skin rejuvenation [40]. This study evaluates i-PRF's intradermal application for dermal restructuring and aesthetic enhancement across the face.

## **2. MATERIAL AND METHODS**

The study protocol received approval from the Research Ethics Committee of the University of Vale do Paraíba [Opinion 4,930,500/CAAE 48019521.5.0000.5503], aligning with the guidelines set forth by the National Health Council through resolution 466/2012. Informed consent was obtained from all participants after providing comprehensive information about the procedures.

Inclusion criteria focused on females aged 35 to 55 exhibiting signs of facial ageing such as wrinkles, sagging, radiance loss, and dermal thinning. Exclusion criteria comprised conditions like pregnancy, allergies to pre-procedure ointment (dermomax), lactation, neoplasms, anaemia, diabetes, deep venous thrombosis, autoimmune diseases, infections, recent botulinum toxin or filler use, dermatological conditions at the treatment site, tanned skin, recent surgeries (within 30 days), and use of NSAIDs, antibiotics, or anticoagulants.

The study involved 26 participants at the University of Vale do Paraíba and Ciclo Oral Odontologia Ltda clinic from November 2021 to August 2022. The study adhered to WHO's COVID-19 protocols, ensuring safety measures like mask usage, hand hygiene, disinfecting with 70% alcohol, and temperature screening.

Participants received three intradermal i-PRF sessions spaced 21 days apart. Standardised photographs captured frontal and profile views. A self-perception questionnaire gauged skin quality and improvement perception. A Self-Perception Index assigned values (0 or 1) to responses, with a score range of zero to four, evaluating improvements.

Ultrasound examined facial areas using a 16 MHz linear transducer to measure dermal thickness. Initial and final measurements were analysed.

Participants applied Dermomax anaesthetic cream before venous puncture. Six tubes of whole blood were collected and processed by centrifugation (2700 rpm/700g RCF, 3 min). The “buffy coat” area (1.5 ml/tube) was collected, yielding 9 ml. Infiltrate (i-PRF) was isolated, transferred, and face-treated using intradermal injections (1 ml/region).

Post-procedure instructions included area manipulation avoidance for 12 hours, sun/temperature exposure for seven days, and no anti-inflammatory drugs for seven days. SPF 30 sunscreen use for 30 days, makeup abstention for 24 hours, and other recommendations were advised.

After the final session, ultrasound measured dermal thickness after 21 days. Paired t-tests analysed measurements; the Wilcoxon test evaluated Self-Perception Index scores. New photographs were compared with the initial ones, assessing outcomes through visual and graphical analysis.

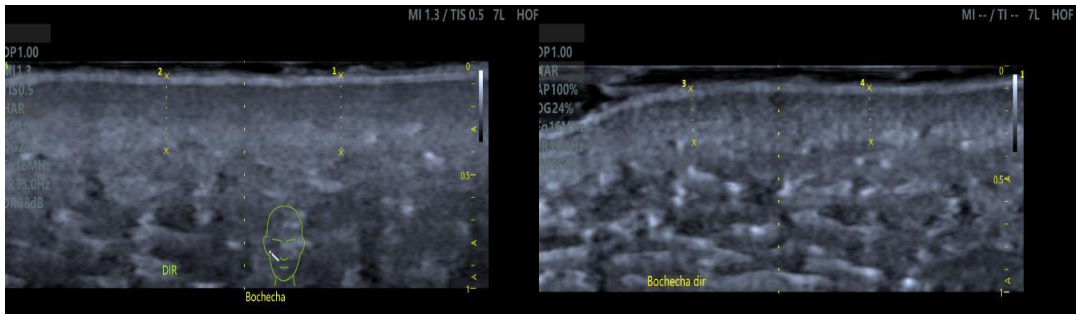
### **3. RESULTS AND DISCUSSION**

The participants underwent the described procedures without experiencing any complications during the treatment.

Dermal thickness measurements were conducted using a 16 MHz ultrasound in the glabella, right (R) and left (L) frontal regions, and from the tragus to the corner of the mouth (cheek) on the right (R) and left (L) sides. These measurements were taken before initiating the treatment and 21 days after the third session. Figures 1A and 1B visually display the increase in superficial dermal thickness, appearing as hypoechoic (grey), and deep dermal thickness, appearing as hyperechoic (white). All the areas measured and analysed are presented in Tables 1 and 2. A paired t-test was applied for statistical analysis using the initial value (dermal thickness before the treatment) and the final value (dermal thickness 21 days after the third session). The null hypothesis (H0) assumed no difference in dermal thickness before and after the application, while the alternative hypothesis (H1) indicated a significant change in dermal thickness 21 days after the third session. The paired t-test assumes a normal distribution of values and employs a two-tailed model with a significance level set at  $P < .05$ . The test results ( $P$ -values) for the glabella region ( $P < .00269$ ), right frontal area ( $P < .00018$ ), left frontal region ( $P < .00014$ ), tragus to the corner of the mouth (cheek) on the right side ( $P < .00709$ ) and left side ( $P < .0008$ ) indicate highly significant alterations in dermal thickness in these regions.

Furthermore, the statistical analysis conducted on the Self-Perception Index yielded a  $P$ -value of less than .0001, indicating a highly significant change in participants' self-perception after the treatment.

Figures 1A and 1B present the results of the ultrasonography measurements. In Figure 1A, the dermal thickness measured before the start of the treatment was 2.41 mm, while in Figure 1B, the dermal thickness measured 21 days after the third treatment session increased to 3.35 mm. The observed increase in dermal thickness indicates a positive response to the treatment, as visually depicted in the images.



**Figures 1A and 1B : Results of the ultrasonography measurements**  
 Source: The author (2022)

Table 1: Glabella measurements, right frontal(D) and left (E)

	Pre-application mm	Post-application mm	Variation	%	Pre-application mm	Post-application mm	Variation	%	Pre-application mm	Post-application mm	Variation	%
1	2,13	3,84	1,71	0.8	1,93	2,43	0,50	0.26	1,69	2,22	0,53	0.31
2	2,24	2,39	0,15	0.07	1,94	2,08	0,14	0.07	1,77	2,05	0,29	0.16
3	1,92	2,56	0,64	0.33	1,79	2,45	0,66	0.37	1,66	2,22	0,56	0.34
4	1,60	3,02	1,42	0.89	1,74	2,45	0,71	0.41	1,64	2,05	0,42	0.25
5	1,89	3,02	1,13	0.6	1,85	2,24	0,39	0.21	1,18	1,76	0,58	0.49
6	2,29	3,45	1,16	0.51	2,26	2,54	0,28	0.12	2,52	2,40	-0,12	-0.05
7	2,08	2,23	0,15	0.07	2,12	1,86	-0,26	-0.12	1,92	2,19	0,27	0.14
8	1,87	2,57	0,7	0.37	1,75	1,69	-0,06	-0.04	1,38	1,70	0,32	0.23
9	1,52	2,95	1,43	0.94	1,26	2,28	1,02	0.81	1,25	2,62	1,37	1.1
10	1,68	2,51	0,83	0.49	1,67	1,90	0,23	0.13	1,97	2,42	0,45	0.23
11	1,85	2,97	1,12	0.61	1,49	2,01	0,52	0.35	1,69	1,93	0,24	0.14
12	1,76	2,33	0,57	0.32	1,80	2,27	0,47	0.26	1,67	2,06	0,39	0.23
13	2,13	2,26	0,13	0.06	1,47	1,91	0,44	0.3	1,83	2,23	0,40	0.22
14	2,05	1,98	-0,07	-0.03	1,77	2,04	0,27	0.15	1,79	1,92	0,13	0.07
15	2,05	2,13	0,08	0.04	1,48	1,78	0,30	0.2	1,83	1,66	-0,17	-0.09
16	2,44	2,61	0,17	0.07	1,92	1,98	0,06	0.03	1,76	1,88	0,12	0.07
17	2,48	2,24	-0,24	-0.1	1,72	2,37	0,65	0.38	1,75	1,76	0,01	0.01
18	2,29	2,21	-0,08	-0.03	1,78	1,74	-0,04	-0.02	1,51	1,67	0,16	0.11

19	1,98	1,83	-0,15	-0,08	1,54	1,82	0,29	0,19	1,60	1,74	0,14	0,09		
20	2,53	2,18	-0,35	-0,14	1,65	1,98	0,33	0,2	1,49	1,96	0,47	0,32		
21	2,33	1,98	-0,35	-0,15	1,84	1,85	0,01	0,01	1,69	1,69	0,00	0		
22	2,1	2,51	0,41	0,2	1,97	2,16	0,20	0,1	1,98	2,22	0,24	0,12		
23	2,26	1,9	-0,36	-0,16	2,08	1,89	-0,19	-0,09	2,05	1,85	-0,20	-0,1		
24	2,01	2,28	0,27	0,13	2,15	2,08	-0,07	-0,03	1,92	2,02	0,10	0,05		
25	1,7	1,72	0,02	0,01	1,74	1,99	0,26	0,15	1,46	1,68	0,22	0,15		
26	2,38	2,31	-0,07	-0,03	2,36	2,21	-0,16	-0,07	1,90	2,12	0,22	0,12		
<b>Average</b>			<b>0,40</b>	<b>22%</b>	<b>Average</b>			<b>0,27</b>	<b>17%</b>	<b>Average</b>			<b>0,27</b>	<b>18%</b>
<b>Variance</b>			<b>0,38</b>	<b>11%</b>	<b>Variance</b>			<b>0,10</b>	<b>4%</b>	<b>Variance</b>			<b>0,10</b>	<b>5%</b>
<b>DP</b>			<b>0,61</b>	<b>33%</b>	<b>DP</b>			<b>0,31</b>	<b>20%</b>	<b>DP</b>			<b>0,31</b>	<b>23%</b>

Source: The author (2022)

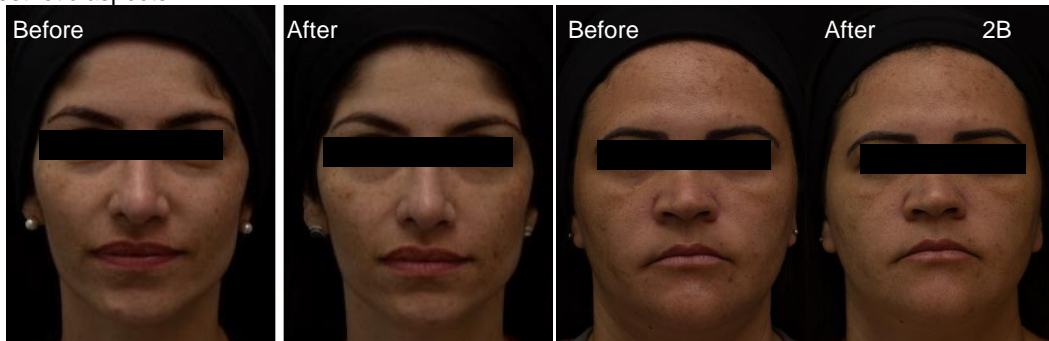
Table 2: Tragusmouth corner (cheek), right (D) and left (E)

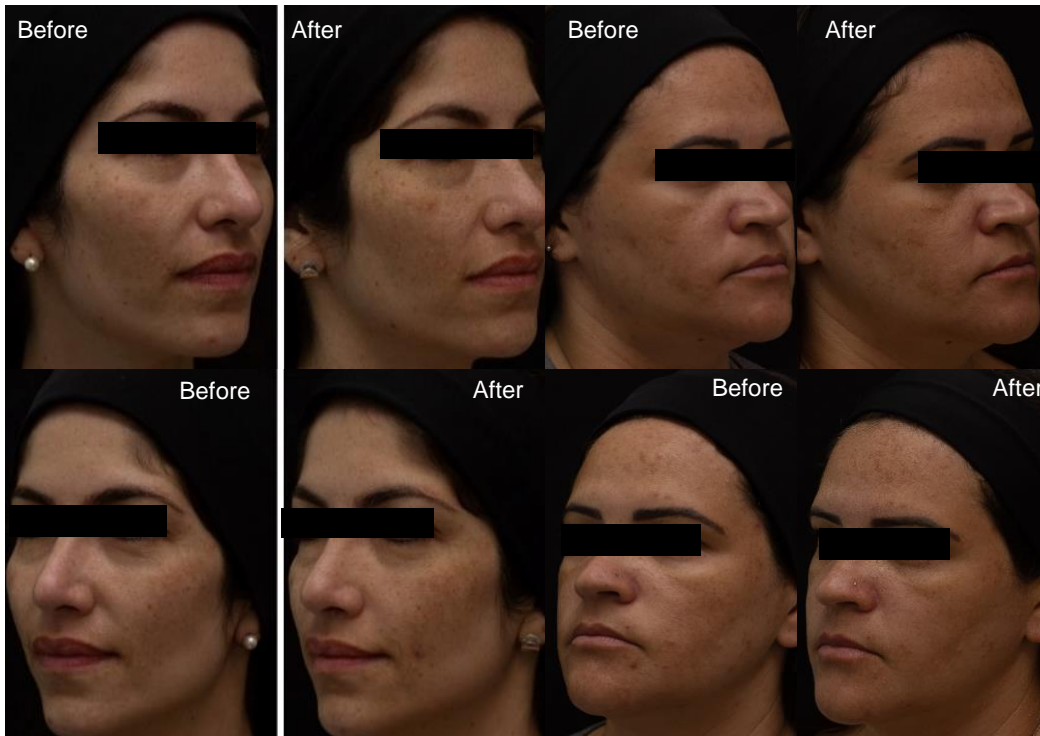P	Right Mouth Tragus				Left Mouth Tragus			
	Pre-application mm	Post-application mm	c	%	Pre-application mm	Post-application mm	Post-application mm	%
1	2,46	3,09	0,64	26%	2,63	3,24	0,62	23%
2	1,74	1,65	-0,09	-5%	1,95	1,99	0,03	2%
3	1,94	2,27	0,33	17%	1,79	2,30	0,51	28%
4	2,41	3,35	0,94	39%	2,00	3,18	1,18	59%
5	1,40	1,70	0,30	21%	1,55	1,92	0,37	24%
6	2,72	2,91	0,19	7%	2,35	3,20	0,85	36%
7	2,07	2,23	0,16	8%	1,84	2,17	0,33	18%
8	1,54	1,81	0,28	18%	1,62	1,99	0,37	23%
9	1,61	2,21	0,61	38%	1,64	2,43	0,79	48%
10	1,79	1,96	0,17	9%	1,84	2,02	0,18	10%
11	1,58	2,04	0,47	30%	1,69	2,28	0,60	35%
12	1,76	2,05	0,29	16%	1,40	2,15	0,75	54%
13	2,08	2,45	0,37	18%	1,84	1,86	0,02	1%
14	2,47	2,52	0,05	2%	2,36	2,10	-0,27	-11%

15	2,00	2,17	0,17	8%	1,74	1,99	0,26	15%
16	2,34	1,86	-0,48	-20%	1,86	1,99	0,14	7%
17	2,13	2,62	0,49	23%	2,35	2,19	-0,16	-7%
18	2,22	2,07	-0,15	-7%	2,12	1,93	-0,20	-9%
19	1,88	1,96	0,08	4%	2,03	1,96	-0,07	-3%
20	2,23	2,07	-0,16	-7%	2,03	2,17	0,14	7%
21	2,22	2,02	-0,20	-9%	2,12	2,24	0,12	6%
22	2,60	2,35	-0,25	-10%	2,18	2,34	0,16	7%
23	1,93	1,96	0,03	2%	2,24	2,04	-0,20	-9%
24	2,03	1,97	-0,07	-3%	2,30	2,50	0,20	8%
25	1,75	1,94	0,19	11%	1,50	1,63	0,13	8%
26	1,84	2,14	0,30	16%	1,82	1,99	0,18	10%
<b>Average</b>		<b>0,18</b>	<b>10%</b>		<b>Average</b>	<b>0,27</b>	<b>15%</b>	
<b>Variance</b>		<b>0,10</b>	<b>2%</b>		<b>Variance</b>	<b>0,13</b>	<b>4%</b>	
<b>DP</b>		<b>0,31</b>	<b>15%</b>		<b>DP</b>	<b>0,36</b>	<b>19%</b>	

Source: The author (2022)

The photographic documentation provided a subjective visual assessment of the treatment's efficacy in addressing various signs of ageing, including wrinkles, sagging, loss of radiance, reduction in pore size, and overall skin quality. Figures 2A and 2B illustrate the observed improvements in these aesthetic aspects.



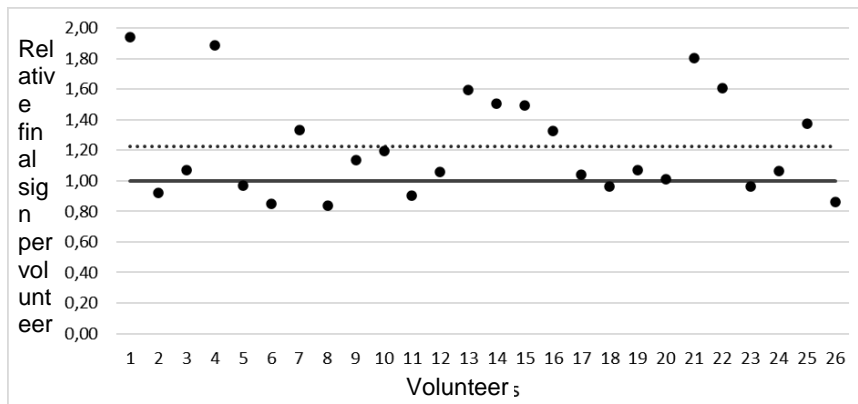


**Figures 2A and 2B illustrate the observed improvements in these aesthetic aspects**

Source: The author (2022)

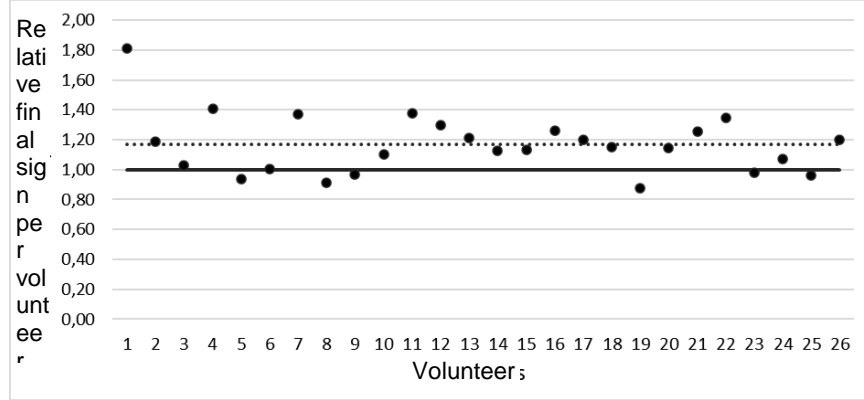
The graphical representations of the relative final signals in the analysed areas (Figures 3 to 7) precisely visualise the treatment's effectiveness by quantifying the increase in dermal thickness. These graphs display the relative final signal for each participant, obtained by dividing the last signal by the initial signal, along with a visual guideline at a value of 1 and a dashed line representing the final normalised average value for the entire participant group. Based on the comprehensive analysis, it was observed that the administration of three sessions of intradermal i-PRF resulted in a significant increase in dermal thickness and an overall improvement in skin condition.

Figure 3. Relative final signs of the Glabella region before and after the procedure. The straight line represents the normalised initial signal (value 1), and the dotted line is the corresponding average final signal for each volunteer (value 1.22); the points represent the normalised final signal for each volunteer.



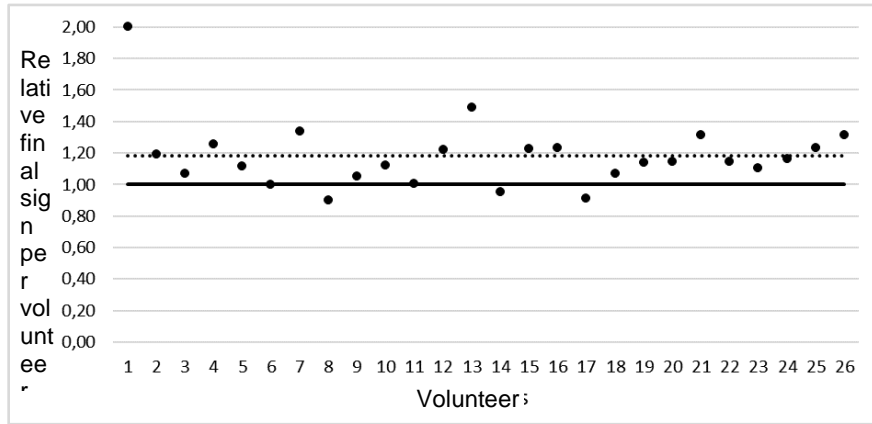
**Figure 3 :. Relative final signs of the Glabella region before and after the procedure**  
 Source: The authors (2022)

Figure 4. Relative final signs of the R frontal region before and after the procedure. The straight line represents the initial normalised signal (value 1), the dotted line the corresponding average final signal for each volunteer (value 1.17), and the points represent the normalised final signal for each volunteer.



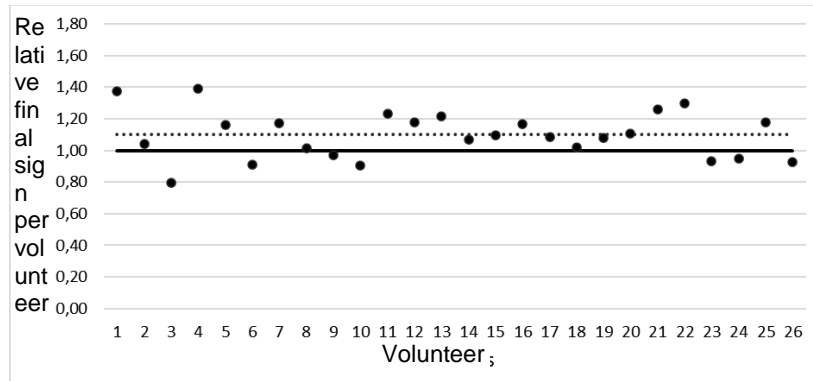
**Figure 4. Relative final signs of the R frontal region before and after the procedure**  
 Source: The authors (2022)

Figure 5: Relative final signs of frontal region E before and after the procedure. The straight line represents the initial normalised signal (value 1), and the dotted line is the corresponding average final signal for each volunteer (value 1.18); the points represent the normalised final signal for each volunteer.



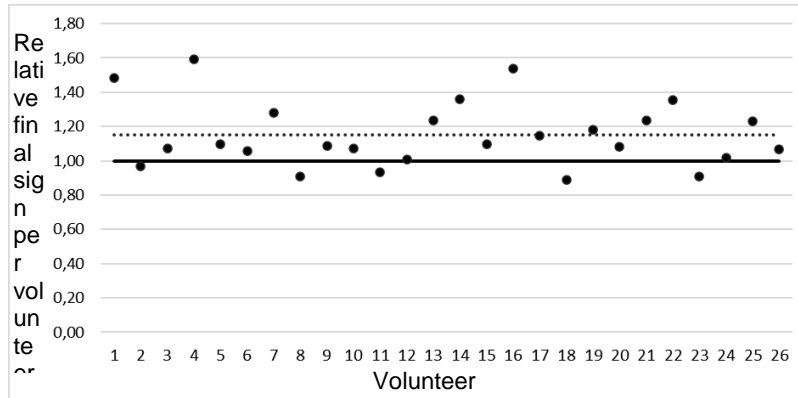
**Figure 5: Relative final signs of frontal region E before and after the procedure**  
 Source: The authors (2022)

Figure 6: Relative final signs from the tragus region to the corner of the mouth D before and after the procedure. The straight line represents the initial normalised signal (value 1), and the dotted line is the corresponding average final signal for each volunteer (value 1.10); the points represent the normalised final signal for each volunteer.



**Figure 6: Relative final signs from the tragus region to the corner of the mouth D before and after the procedure**  
Source: The authors (2022)

Figure 7: Relative final signs from the tragus region to the corner of the mouth E before and after the procedure. The straight line represents the normalised initial signal (value 1), and the dotted line is the corresponding average final signal for each volunteer (value 1.15); the points represent the normalised final signal for each volunteer.



**Figure 7: Relative final signs from the tragus region to the corner of the mouth E before and after the procedure**  
Source: The authors (2022)

The data reveals that dermal thickness increased across studied regions, with variable response magnitudes, suggesting potential lifestyle influence on i-PRF efficacy. Monitoring inflammatory markers and modulating variables could optimise therapy outcomes. Limited studies on intradermotherapy via i-PRF exist; however, this study's promising outcomes underscore its proper dermal depth functionality. Dhurat's findings suggest that large component size may compromise post-micro-needling platelet concentrate application[42].

Results affirm i-PRF's potential in attracting fibroblasts for dermal restructuring, supported by growth factor presence. Vascular endothelial growth factor (VEGF) fosters restructuring through angiogenesis [22,36,37,43]. i-PRF-driven rejuvenation yielded volume effects, angiogenesis, collagen and fibronectin production [44]. Fibroblast division, migration, adhesion, gene expression, and growth factor activation were evidenced.

Tables 1 and 2 data reveal some negative outcomes, possibly linked to pre-existing subclinical inflammation, subsequently reduced by i-PRF, or ultrasound measurement variability due to evaluator pressure or gel thickness. Evaluators received training to mitigate bias. Visual outcomes in photos (e.g., Figure 2B, patient 22) require multifactorial analysis, considering subcutaneous layers, inflammation, and skin type.

Although i-PRF intradermotherapy seems promising, standardised protocols and comparative effectiveness studies are lacking. The debate on high vs. low-force PRF protocols persists [25,28,29,31,32,45]. Our high-force i-PRF protocol yielded favourable results, warranting further comparative investigations.

This research employed varied assessment techniques: ultrasonography, photography, and self-perception questionnaires. Ultrasonography demonstrated increased dermal thickness post-treatment, correlating with improved texture, wrinkles, and radiance. Analysis of ultrasonographic data 21 days after treatment revealed enhanced dermal thickness. Participant responses underscored treatment satisfaction, crucial for clinical efficacy evaluation.

Treatment displayed minimal complications—transient oedema and occasional hematomas, resolving within a week. Pain during application was manageable. Future investigations could enhance comprehension by incorporating biochemical, haematological, and lifestyle analyses.

#### **4. CONCLUSION**

The application of three sessions of high-force centrifugation i-PRF via intradermotherapy significantly increased dermal thickness, proving to be an effective dermal restructurer and a cost-effective alternative accessible to all. The results of i-PRF bio-stimulation are short-term but rather progressive. The positive evaluation from the self-perception questionnaire demonstrated the significant importance of clinical analysis and should be associated with the positive outcomes of increased dermal thickness. Further standardisation of the technique for different clinical scenarios is still necessary.

#### **ACKNOWLEDGEMENTS**

This work was carried out in collaboration among all authors.

## **COMPETING INTERESTS**

The authors have declared that no competing interests exist.

## **AUTHORS' CONTRIBUTIONS**

FPB conceived the study, drafted the project, actively participated in data collection, and contributed significantly to the RPG conceived the study, actively participated in data collection, and contributed significantly to the writing of the article. JCP provided guidance throughout the study. CMMDM actively participated in data collection. PRB and ACOCD actively participated in the statistical analyses of the study. GRDF, KLB and MFC, alongside the other authors, reviewed, revised, refined, read and approved the final manuscript.

## **CONSENT (WHEREEVER APPLICABLE)**

All authors declare that 'written informed consent was obtained from the patient (or other approved parties) for publication of this case report and accompanying images. A copy of the written consent is available for review by the Editorial office/Chief Editor/Editorial Board members of this journal.

## **ETHICAL APPROVAL (WHEREEVER APPLICABLE)**

All authors hereby declare that all experiments have been examined and approved by the appropriate ethics committee and have therefore been performed in accordance with the ethical standards laid down in the 1964 Declaration of Helsinki.

## **REFERENCES**

1. MOORE, K. L; DARLLY AF. Anatomia orientada para a clínica. 4. Rio de Janeiro: Guanabara; 2001.
2. Poon F, Kang S, Chien AL. Mechanisms and treatments of photoaging. *PhotodermatolPhotoimmunolPhotomed* [Internet]. 2015 Mar;31(2):65–74. Available from: <https://onlinelibrary.wiley.com/doi/10.1111/phpp.12145> 14
3. Visnardi AR. Efeito do ultra-som de baixa intensidade no colágeno da pele sadia de ratos [Internet]. [São Carlos]: Universidade de São Paulo; 2007. Available from: <http://www.teses.usp.br/teses/disponiveis/82/82131/tde-14022008-105151/>
4. Anunciato TP. Nutricosméticos [Internet]. [Ribeirão Preto]: Universidade de São Paulo; 2011. Available from: <http://www.teses.usp.br/teses/disponiveis/60/60137/tde-20092011-210914/>
5. Ortolan MCAB, Biondo-Simões M de LP, Baroni E do RV, Auersvald A, Auersvald LA, Montemor Netto MR, et al. Influência do envelhecimento na qualidade da pele de mulheres brancas: o papel do colágeno, da densidade de material elástico e da vascularização. *Rev Bras Cir Plástica* [Internet]. 2013 Mar;28(1):41–8. Available from: [http://www.scielo.br/scielo.php?script=sci\\_arttext&pid=S1983-51752013000100008&lng=pt&nrm=iso&tlng=en](http://www.scielo.br/scielo.php?script=sci_arttext&pid=S1983-51752013000100008&lng=pt&nrm=iso&tlng=en)
6. I EJMR, Yadira D, Corrales M. Bioestimulación facial con plasma rico en plaquetas. *Arch Médico Camagüey*. 2015;19(2):167–78.

7. Sataloff RT, Johns MM, Kost KM. ENVELHECIMENTO CUTÂNEO: TEORIA DOS RADICAIS LIVRES E TRATAMENTOS VISANDO A PRESERVAÇÃO E O REJUVENECIMENTO. *Rev Uningá*. 2010;24.
8. Gava AA, Zanoni JN. Envelhecimento Celular. *Arq Ciências da Saúde da UNIPAR [Internet]*. 2005;9(1):41–6. Available from: <http://revistas.unipar.br/saude/article/view/218/192>
9. Naveilhan P, Baudet C, Jabbour W, Wion D. A theory that may explain the Hayflick limit — a means to delete one copy of a repeating sequence during each cell cycle in certain human cells such as fibroblasts. *Mech Ageing Dev [Internet]*. 1994 Sep;75(3):205–13. Available from: <https://linkinghub.elsevier.com/retrieve/pii/0047637494900108>
10. Borson LAMG, Romano LH. REVISÃO: O PROCESSO GENÉTICO DE ENVELHECIMENTO E OS CAMINHOS PARA A LONGEVIDADE. *Rev Saúde em Foco – Edição no 12 – Ano 2020 [Internet]*. 2020;239–44. Available from: <https://portal.unisepe.com.br/unifia/wp-content/uploads/sites/10001/2020/08/REVISÃO-O-PROCESSO-GENÉTICO-DE-ENVELHECIMENTO-E-OS-CAMINHOS-PARA-A-LONGEVIDADE-239-a-244.pdf>
11. Castelo-Branco C. *Envejecimiento de la piel y las mucosas*. Madrid, Espanha; 2010.
12. Silva WJM da, Ferrari CKB. Metabolismo mitocondrial, radicais livres e envelhecimento. *Rev Bras Geriatr e Gerontol [Internet]*. 2011;14(3):441–51. Available from: [http://www.scielo.br/scielo.php?script=sci\\_arttext&pid=S1809-98232011000300005&lng=pt&tlng=pt](http://www.scielo.br/scielo.php?script=sci_arttext&pid=S1809-98232011000300005&lng=pt&tlng=pt) 15
13. Nacopoulos C. Uso da Fibrina Rica em Plaquetas na Estética e no Rejuvenescimento Facial. In: *FIBRINA RICA EM PLAQUETAS NA ODONTOLOGIA REGENERATIVA E ESTÉTICA : BASES BIOLÓGICAS E APLICAÇÕES CLÍNICAS*. 2018th ed. São Paulo: Quintessence Editora; 2018. p. 215–35.
14. Takamori ER, Teixeira MVT, Menezes K, Carias RBV, Borojevic R. Fibrina rica em plaquetas: preparo, definição da qualidade, uso clínico. *Vigilância Sanitária em Debate*. 2018;6(1):118.
15. Hassan H, Quinlan DJ, Ghanem A. Injectable platelet-rich fibrin for facial rejuvenation: A prospective, single-centre study. *J CosmetDermatol [Internet]*. 2020 Dec 23;19(12):3213–21. Available from: <https://onlinelibrary.wiley.com/doi/10.1111/jocd.13692>
16. Di Matteo B, Filardo G, Kon E, Marcacci M. Platelet-rich plasma: evidence for treating patellar and Achilles tendinopathy—a systematic review. *MusculoskeletSurg [Internet]*. 2015 Apr 17;99(1):1–9. Available from: <http://link.springer.com/10.1007/s12306-014-0340-1>
17. Gholami M, Ravaghi H, Salehi M, AbediYekta A, Doaee S, Jaafaripooyan E. A systematic review and meta-analysis of the application of platelet-rich plasma in sports medicine. *Electron Physician [Internet]*. 2016 May 25;8(5):2325–32. Available from: <http://www.ephysician.ir/index.php/browse-issues/2016/5/372-2325>
18. Sclafani AP. Platelet-rich fibrin matrix for improvement of deep nasolabial folds. *J CosmetDermatol [Internet]*. 2010 Mar;9(1):66–71. Available from: <https://onlinelibrary.wiley.com/doi/10.1111/j.1473-2165.2010.00486.x>

19. Whitman DH, Berry RL, Green DM. Platelet gel: An autologous alternative to fibrin glue with oral and maxillofacial surgery applications. *J Oral Maxillofac Surg* [Internet]. 1997 Nov;55(11):1294–9. Available from: <https://linkinghub.elsevier.com/retrieve/pii/S0278239197901877>
20. Marx RE, Carlson ER, Eichstaedt RM, Schimmele SR, Strauss JE, Georgeff KR. Platelet-rich plasma. *Oral Surgery, Oral Med Oral Pathol Oral RadiolEndodontology* [Internet]. 1998 Jun;85(6):638–46. Available from: <https://linkinghub.elsevier.com/retrieve/pii/S1079210498900294>
21. Anitua E. Plasma rich in growth factors: preliminary results of use in the preparation of future sites for implants. *Int J Oral Maxillofac Implants* [Internet]. 1999;14(4):529–35. Available from: <http://www.ncbi.nlm.nih.gov/pubmed/10453668>
22. Fujioka-Kobayashi M, Miron RJ. Biological Components of Platelet Rich Fibrin: Growth Factor Release and Cellular Activity. In: *Platelet Rich Fibrin in Regenerative Dentistry: Biological Background and Clinical Indications* [Internet]. Oxford, UK: John Wiley & Sons, Ltd; 2017. p. 15–31. Available from: <https://onlinelibrary.wiley.com/doi/10.1002/9781119406792.ch2>
23. Choukroun J. Une opportunité en paro-implantologie: le PRF. *Implantodontie*. 2001;42(55):e62.
24. Dohan DM, Choukroun J, Diss A, Dohan SL, Dohan AJJ, Mouhyi J, et al. Platelet-rich fibrin (PRF): A second-generation platelet concentrate. Part I: Technological concepts and evolution. *Oral Surgery, Oral Med Oral Pathol Oral RadiolEndodontology* [Internet]. 2006 Mar;101(3):e37–44. Available from: <https://linkinghub.elsevier.com/retrieve/pii/S107921040500586X>
25. Miron RJ, Fujioka-Kobayashi M, Hernandez M, Kandalam U, Zhang Y, Ghanaati S, et al. Injectable platelet rich fibrin (i-PRF): opportunities in regenerative dentistry? *Clin Oral Investig* [Internet]. 2017 Nov 2;21(8):2619–27. Available from: <http://link.springer.com/10.1007/s00784-017-2063-9>
26. Miron RJ, Choukroun J. FIBRINA RICA EM PLAQUETAS NA ODONTOLOGIA E MEDICINA REGENERATIVA E ESTÉTICA: BASES BIOLÓGICAS E APLICAÇÕES CLÍNICAS. 2018th ed. São Paulo: Quintessence Editora; 2018.
27. Cortellini S, Castro AB, Temmerman A, Van Dessel J, Pinto N, Jacobs R, et al. Leucocyte- and platelet-rich fibrin block for bone augmentation procedure: A proof-of-concept study. *J Clin Periodontol* [Internet]. 2018 May;45(5):624–34. Available from: <https://onlinelibrary.wiley.com/doi/10.1111/jcpe.12877>
28. Ghanaati S, Booms P, Orlowska A, Kubesch A, Lorenz J, Rutkowski J, et al. Advanced Platelet-Rich Fibrin: A New Concept for Cell-Based Tissue Engineering by Means of Inflammatory Cells. *J Oral Implantol* [Internet]. 2014 Dec 1;40(6):679–89. Available from: <https://meridian.allenpress.com/joi/article/40/6/679/6702/Advanced-PlateletRich-Fibrin-A-New-Concept-for>
29. El Bagdadi K, Kubesch A, Yu X, Al-Maawi S, Orlowska A, Dias A, et al. Reduction of relative centrifugal forces increases growth factor release within solid platelet-rich-fibrin (PRF)-based matrices: a proof of concept of LSCC (low-speed centrifugation concept). *Eur J*

Trauma Emerg Surg [Internet]. 2019 Jun 21;45(3):467–79. Available from: <http://link.springer.com/10.1007/s00068-017-0785-7>

30. Mourão CF de AB, Valiense H, Melo ER, Mourão NBMF, Maia MD-C. Obtention of injectable platelets rich-fibrin (i-PRF) and its polymerization with bone graft: technical note. *Revista do Colégio Brasileiro de Cirurgiões* [Internet]. 2015 Dec;42(6):421–3. Available from: [http://www.scielo.br/scielo.php?script=sci\\_arttext&pid=S0100-69912015000700421&lng=en&tlng=en](http://www.scielo.br/scielo.php?script=sci_arttext&pid=S0100-69912015000700421&lng=en&tlng=en) 17

31. Wang X, Zhang Y, Choukroun J, Ghanaati S, Miron RJ. Effects of an injectable platelet-rich fibrin on osteoblast behavior and bone tissue formation in comparison to platelet-rich plasma. *Platelets* [Internet]. 2018 Jan 2;29(1):48–55. Available from: <https://www.tandfonline.com/doi/full/10.1080/09537104.2017.1293807>

32. Wang X, Yang Y, Zhang Y, Miron RJ. Fluid platelet-rich fibrin stimulates greater dermal skin fibroblast cell migration, proliferation, and collagen synthesis when compared to platelet-rich plasma. *J Cosmet Dermatol* [Internet]. 2019 Dec 16;18(6):2004–10. Available from: <https://onlinelibrary.wiley.com/doi/10.1111/jocd.12955>

33. Miron RJ, Horrocks NA, Zhang Y, Horrocks G, Pikos MA, Sculean A. Extending the working properties of liquid platelet-rich fibrin using chemically modified PET tubes and the Bio-Cool device. *Clin Oral Investig* [Internet]. 2022 Mar 23;26(3):2873–8. Available from: <https://link.springer.com/10.1007/s00784-021-04268-x>

34. Dohan DM, Choukroun J, Diss A, Dohan SL, Dohan AJJ, Mouhyi J, et al. Platelet-rich fibrin (PRF): A second-generation platelet concentrate. Part II: Platelet-related biologic features. *Oral Surgery, Oral Med Oral Pathol Oral Radiol Endodontology* [Internet]. 2006 Mar;101(3):e45–50. Available from: <https://linkinghub.elsevier.com/retrieve/pii/S1079210405005871>

35. Sclafani AP, Saman M. Platelet-Rich Fibrin Matrix for Facial Plastic Surgery. *Facial Plast Surg Clin North Am*. 2012;20(2):177–86.

36. Antônio Colussi da Silva J, Giacomini M, Warmeling M, Miranda Pagnoncelli R. Uso do hormônio do crescimento associado à fibrina rica em plaquetas e leucócitos injetável (I-PRF). *Rev da Fac Odontol - UPF*. 2019;24(2):309–15.

37. Rodríguez Flores J, Palomar Gallego MA, Torres García-Denche J. Plasma rico en plaquetas: fundamentos biológicos y aplicaciones en cirugía maxilofacial y estética facial. *Rev Española Cirugía Oral y Maxilofac* [Internet]. 2012 Jan;34(1):8–17. Available from: <https://linkinghub.elsevier.com/retrieve/pii/S113005581100102X>

38. İzol BS, Üner DD. A New Approach for Root Surface Biomodification Using Injectable Platelet-Rich Fibrin (I-PRF). *Med Sci Monit* [Internet]. 2019 Jun 26;25:4744–50. Available from: <https://www.medscimonit.com/abstract/index/idArt/915142>

39. Ozsagir ZB, Saglam E, SenYilmaz B, Choukroun J, Tunali M. Injectable platelet-rich fibrin and microneedling for gingival augmentation in thin periodontal phenotype: A randomized controlled clinical trial. *J Clin Periodontol* [Internet]. 2020 Apr;47(4):489–99. Available from: <https://onlinelibrary.wiley.com/doi/10.1111/jcpe.13247>

40. Nacopoulos C, Vesala A. Lower facial regeneration with a combination of 18

platelet-rich fibrin liquid matrices based on the low speed centrifugation concept-Cleopatra technique. *J CosmetDermatol* [Internet]. 2020 Jan;19(1):185–9. Available from: <https://onlinelibrary.wiley.com/doi/10.1111/jocd.13196>

41. Cortellini S, Castro AB, Temmerman A, Van Dessel J, Pinto N, Jacobs R, et al. Leucocyte- and platelet-rich fibrin block for bone augmentation procedure: A proof-of-concept study. *J ClinPeriodontol*. 2018;45(5):624–34.

42. Dhurat R, Sharma A, Goren A, Daruwalla S, Situm M, Kovacevic M. Mission impossible: Dermal delivery of growth factors via microneedling. *Dermatol Ther* [Internet]. 2019 May 22;32(3). Available from: <https://onlinelibrary.wiley.com/doi/10.1111/dth.12897>

43. Choi SW, PANGENI R, Jung DH, Kim SJ, Park JW. Construction and Characterization of Cell-Penetrating Peptide-Fused Fibroblast Growth Factor and Vascular Endothelial Growth Factor for an Enhanced Percutaneous Delivery System. *J NanosciNanotechnol* [Internet]. 2018 Feb 1;18(2):842–7. Available from: <http://www.ingentaconnect.com/content/10.1166/jnn.2018.14864>

44. Wang X, Zhang Y, Choukroun J, Ghanaati S, Miron R. Behavior of Gingival Fibroblasts on Titanium Implant Surfaces in Combination with either Injectable-PRF or PRP. *Int J Mol Sci* [Internet]. 2017 Feb 4;18(2):331. Available from: <http://www.mdpi.com/1422-0067/18/2/331>

45. Tovar N, Benalcázar Jalkh EB, Ramalho IS, Rodriguez Colon R, Kim H, Bonfante EA, et al. Effects of relative centrifugation force on <scp>L-PRF</scp> : An in vivo submandibular boney defect regeneration study. *J Biomed Mater Res Part B ApplBiomater* [Internet]. 2021 Dec 3;109(12):2237–45. Available from: <https://onlinelibrary.wiley.com/doi/10.1002/jbm.b.34885>