

# A rare case of osteosarcoma metastasizing to the heart in a 30-year-old woman: About a case

### Abstract:

**Background:** Cardiac metastases are among the rarest in oncology, usually silent and rarely attracting clinical attention, often discovered at autopsy.

Osteosarcoma is the most common malignant bone tumor, and its usual metastatic sites are the lung, bone, brain, soft tissue, and lymph nodes.

Cardiac metastases from osteosarcoma are exceptional.

**Case presentation:** We report a rare case of cardiac metastases discovered in the presence of progressively worsening dyspnea, motivating the realization of transthoracic echocardiography, which revealed two large intracardiac masses located in the right cavities, with extensive thrombosis of the inferior vena cava.

A thoracic-abdominal-pelvic CT scan revealed a right coxo-pelvic mass suggestive of osteosarcoma. Ultrasound-guided biopsy with an anatomopathological study of the mass confirmed the diagnosis of chondroblastic osteosarcoma.

After neoadjuvant chemotherapy and surgical excision of the primary bone tumor and cardiac metastases, the anatomopathological study of the cardiac masses confirmed the same histological nature as the coxo-pelvic tumor. The patient was subsequently referred to the oncology department for adjuvant chemotherapy and further management. The evolution was marked by a multifocal cardiac and pulmonary recurrence, 10 months after surgical excision. The patient died 5 months later.

**Conclusions:** Most malignant tumors can metastasize to the heart. In cancer patients, a transthoracic echocardiogram should be performed in the presence of any cardiac warning sign, including dyspnea, chest pain, or a new heart murmur, in order to diagnose any cardiac metastasis that may worsen the patient's prognosis and contribute to the mechanism of death.

### keywords:

Cardiac metastases, chondroblastic osteosarcoma, cardiac masses.

### ABBREVIATIONS:

CT: Computed tomography

## **1. INTRODUCTION:**

Osteosarcoma is a malignant bone tumor with a dark prognosis, known to be particularly aggressive with high metastatic potential(1-2). It is the most common primary bone tumor; its incidence reaches 0.3/100,000/year. It mainly affects adolescents with a peak frequency between 15 and 19 years, but there is a second significant peak in the seventh and eighth decades of life. There is a male predominance with a male/female ratio of 1.4:1(3-4).

The most common metastatic sites of osteosarcoma are the lung, bone, and brain. Cardiac metastases are very rare.

In descending order of frequency, cardiac metastases affect the pericardium, myocardium, and endocardium. The partial or total intra-cavitary growth of cardiac metastases is very rare (5).

Cardiac metastases are generally silent and are very rarely the mode of revelation of the primary tumor (6), however, they are strongly incriminated in the mechanisms of death in patients.

Today, transthoracic echocardiography greatly facilitates the detection of heart involvement in cancer diseases. Diagnostic certainty is provided by pathological examination.

Reporting a rare case of metastatic intracardiac masses revealing chondroblastic osteosarcoma in a 30-year-old woman, with a literature review.

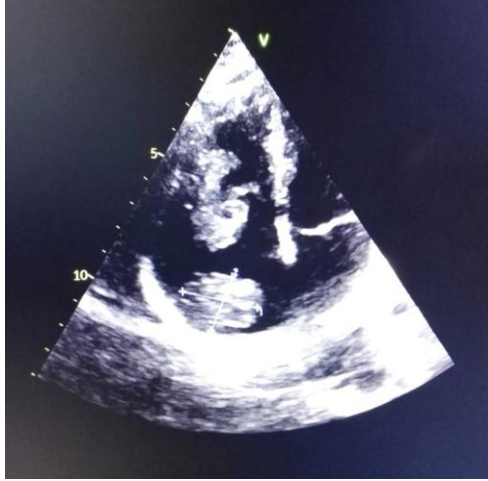
## **2. CASE PRESENTATION:**

We report a case of a 30-year-old ethnic Moroccan woman, without any particular pathological history, who consults in the emergency department for progressive dyspnea becoming increasingly important with a marked limitation of daily activities.

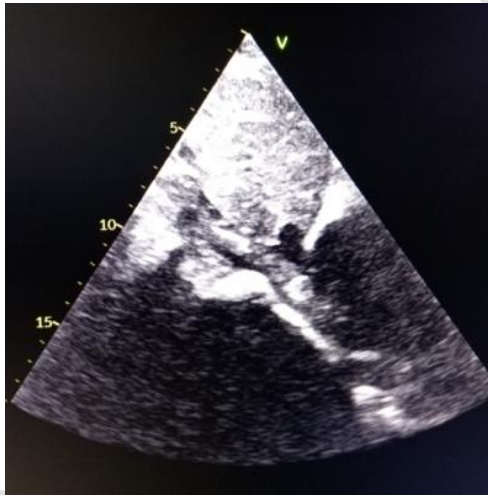On clinical examination, the patient was eupneic at rest, her blood pressure was 123/68 mm Hg, and her heart rate was 80beats/min. Cardiopulmonary auscultation was normal.

A complete blood analysis was carried out on the patient which was normal.

Transthoracic ultrasonography performed in the presence of dyspnea at the slightest effort revealed two intracardiac masses located in the right cavities, the first mass is heterogeneous, with a fairly regular outline, measuring 20x14 mm, developed at the depends of the right atrium, the second mass is heterogeneous, with an irregular outline, measuring 27x22 mm, developed at the depends of the right ventricle, associated with thrombosis of the inferior vena cava.



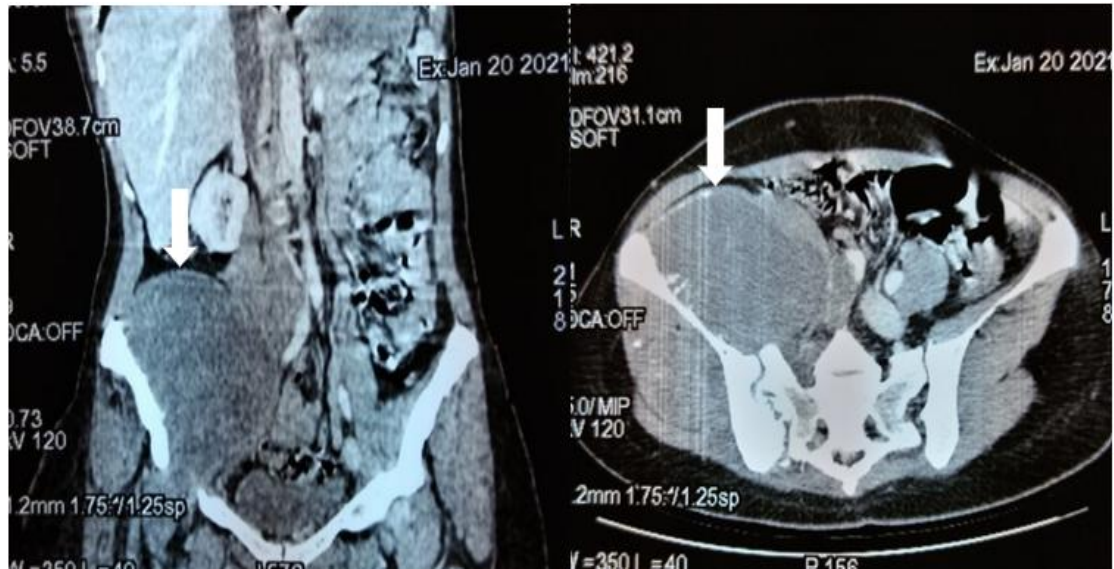
**Figure 1: Two intracardiac masses in the dilated right cavities.**



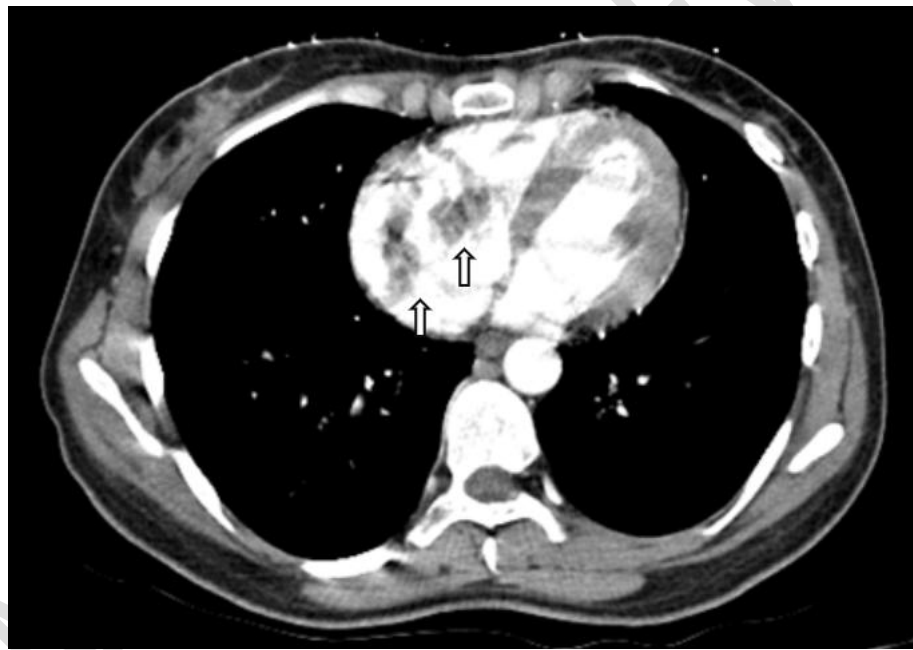
**Figure 2: Extensive thrombosis of the inferior vena cava.**

The chest angioscan performed did not show any pulmonary embolism.

In view of her highly suspicious intracardiac masses, an abdominopelvic CT scan was carried out in search of primary neoplasia, which revealed in addition to the two cardiac masses, a right coxo-pelvic mass with a speckled appearance of the iliac crest and extension to the sacroiliac, suggestive of osteosarcoma.



**Figure 3: CT image showing a right coxo-pelvic mass with a speckled appearance of the iliac crest and extension to the sacroiliac, suggestive of Osteosarcoma.**



**Figure 4: CT image showing intracardiac metastatic masses in dilated right cavities.**

An ultrasound-guided biopsy of the coxo-pelvic mass was performed. Anatomopathological study of the mass revealed sarcomatous proliferation in diffuse sheets and nodules with a significant high-grade cartilaginous component, myxoid remodeling, and highly atypical cells surrounded by osteoid substance at the periphery, suggestive of chondroblastic osteosarcoma.

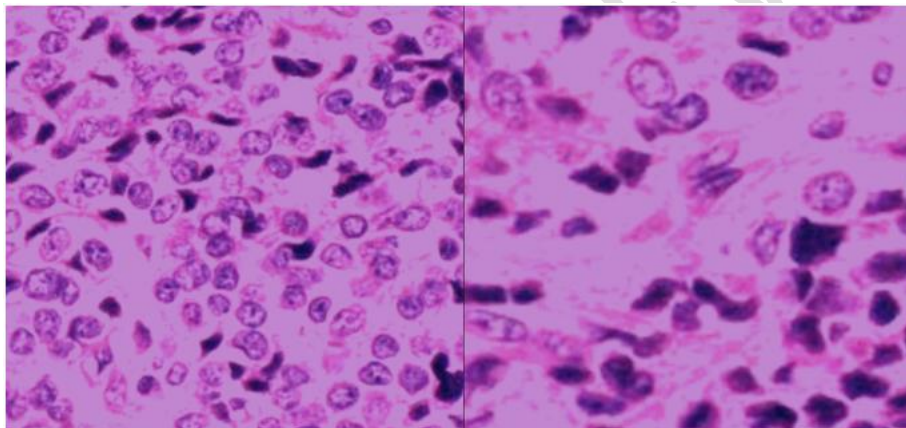
**After multidisciplinary consultation, six courses of neoadjuvant chemotherapy based on Cisplatin, Doxorubicin, and Ifosfamide were administered. At the end of this chemotherapy, a reduction in the size of the primary and secondary tumor masses was observed. Complete**

surgical excision of the persistent bone tumor was performed six weeks after the end of chemotherapy.

Given the high risk of cardiac cavities obliteration and embolic dissemination related to residual metastatic heart masses and the general good condition of the patient, it is decided to perform surgical excision of both intracardiac masses one month after excision of the primary tumor.

A sterno-pericardiotomy approach under extracorporeal circulation, with right atriotomy and ventriculotomy and longitudinal opening of the anterior face of the inferior vena cava, enabled excision of both tumor masses, with removal of intra-parietal tumor tissue and endovascular material. Macroscopically, the tumor masses were whitish, with a fairly regular contour, bumpy surface, and cartilaginous consistency.

Anatomopathological study of the cardiac masses revealed a cellular proliferation of cartilaginous differentiation, made up of ovoid or rounded cells with hyperchromatic nuclei, showing certain patterns of mitosis. These cells elaborate a chondroid substance, confirming the diagnosis of chondroblastic osteosarcoma metastasis.



**Figure 4: Microscopic appearance of cardiac masses showing sarcomatous proliferation with a cartilaginous component confirming their metastatic nature.**

After surgery, the patient was referred to the oncology department for adjuvant chemotherapy and further management.

The evolution was marked by a multifocal cardiac and pulmonary recurrence, 10 months after surgical excision, put on palliative treatment with cyclophosphamide without success. The patient died 5 months later.

### **3. DISCUSSION:**

Cardiac metastases are 20 to 40 times more frequent than primary cardiac tumors; their frequency is underestimated with a reported incidence of 1.5-20% in autopsies of cancer patients (7-8). However, they are among the least known and among the most debated in oncology.

All malignant tumors can metastasize to the heart, with the exception of central nervous system tumors, which have not been shown to metastasize to the heart. The most common

tumors to metastasize to the heart are lung, breast, and esophagus carcinomas, malignant lymphomas, leukemias, and malignant melanomas (9). Cardiac metastases of osteosarcoma are exceptional. Preferred metastatic sites for osteosarcoma are lung, bone, brain, and with less frequency, soft tissue and lymph nodes (10).

Our case report demonstrates the need to think about cardiac metastasis even in the presence of malignant tumors least likely to metastasize to the heart.

Cardiovascular metastases can be detected at the time of initial diagnosis of osteosarcoma. A retrospective study by Yedururi S et al evaluating imaging results and clinical characteristics of 20 patients with osteosarcoma cardiovascular disease found cardiac metastasis at initial diagnosis in 35% of patients (11). This also occurred in our patient who had cardiovascular metastases at the time of diagnosis of coxo-pelvic osteosarcoma.

Cardiac metastases are most often asymptomatic and may not manifest clinically until several years after the diagnosis of cancer. They very rarely constitute the mode of revelation of primitive neoplasia and are the predominant clinical discovery in only a few isolated cases (12). In our case, the discovery of intracardiac masses was the mode of revelation of osteosarcoma.

Metastatic cancer cells may reach the myocardium by direct extension from neighboring organs such as the lung, esophagus, or mediastinum, or by lymphatic or hematogenous routes. Propagation to the heart may also occur via the pulmonary vein or vena cava (13-14). In our case, dissemination occurred from the inferior vena cava to the right atrium and then the right ventricle.

In order of frequency, cardiac metastases involve the pericardium, myocardium, epicardium, and endocardium. An autopsy study by Butany et al (15), reported that among 193 cases of cardiac metastases, the pericardium was involved in 127 cases (65.8%), the myocardium in 56 cases (29.0%), the epicardium in 48 cases (24.9%) and the endocardium in 6 cases (3.1%). In our patient, the endocardium was the tunica concerned by metastatic dissemination.

In most cases, cardiac metastases are clinically silent. The clinical picture is dominated by generalized tumor spread, with only one-tenth of patients with cardiac neoplastic dissemination presenting with suggestive symptoms. The most common telltale signs of cardiac metastases are heart failure, particularly dyspnea, atrial or ventricular rhythm disturbances, conduction disorders, and cardiomegaly due to pericardial effusion (12-16). In the case of our patient, the revealing symptom that motivated the consultation was the dyspnea of progressive aggravation, becoming at the slightest effort.

There is no strong parallelism between the extent of cardiac lesions and clinical manifestations. In many cases, post-mortem findings show more extensive metastatic cardiac involvement than clinical symptomatology would suggest (12).

In the case of intravenous tumor dissemination through the superior or inferior vena cava, as in our patient's case, a metastatic extension may lead to obstruction of the right atrium or blockage of tricuspid valve mobility, resulting in adiasstole. Another major complication is the release of metastatic emboli into the pulmonary circulation (17).

Endocardial metastases of the left heart also carry the risk of valvular obstruction, with the possibility of systemic embolism in one in ten cases; most often this is a transient ischemic attack or stroke, but metastatic emboli can also affect the arteries of the limbs and, more rarely, the coronary arteries, resulting in acute coronary syndrome (18).

In most cases, treatment of cardiac involvement is limited to palliative measures, with surgical resection indicated only in patients with a relatively good prognosis and intracardiac masses at risk of intracavitary obliteration or valvular obstruction.

Post-operative mortality of complete resection is high, but surgical excision of cardiac metastases invading the right atrium by intravenous means has been performed successfully in a large number of cases (19-20).

In primary metastatic osteosarcoma, patients can be treated with curative intent following the same principles as applied to non-metastatic osteosarcoma. Patients may have a prognosis very similar to that of localized disease, provided that surgical removal of all known metastatic deposits is feasible(21-22).

This was the case for our patient, who underwent neoadjuvant chemotherapy followed by excision of the cardiac metastatic masses. The postoperative follow-up to cardiac surgery was uncomplicated, and the patient maintained a good quality of life for 10 months, later complicated by the development of multifocal cardiac and pulmonary metastases.

#### **4. CONCLUSIONS:**

Osteosarcoma is an aggressive tumor with high metastatic potential that mainly affects adolescents and young adults, raising the interest of early diagnosis and close follow-up of patients to detect early secondary localization.

Intracardiac metastases of osteosarcoma are exceptional, they are most often silent and rarely constitute the mode of revelation of the primary tumor. Despite its insidious nature, the neoplastic cardiac invasion strongly contributes to the mechanisms of death of affected patients.

Prognosis is conditioned by early diagnosis and adapted multidisciplinary management involving an oncologist, cardiologist, cardiovascular surgeon, radiologist, and psychologist.

Transthoracic echocardiography can detect cardiac metastatic dissemination and should be performed in the presence of any cardiac warning sign, particularly dyspnea, chest pain, a new heart murmur, a rhythm or conduction disorder, or cardiomegaly on radiology.

#### **DECLARATIONS:**

- Ethics approval and consent to participate

This case report was conducted in accordance with the declaration of Helsinki. The collection and evaluation of all protected patient health information was performed in a health insurance

portability and accountability Act. we know of no conflicts of interest associated with this publication.

- Consent for publication:

"Written informed consent was obtained from the patient for publication of this case report and any accompanying images. A copy of the written consent is available for review by the Editor-in-Chief of this journal."

- Availability of data and material: non-applicable

## **References:**

1. Pinder M, Eddine CA, Parnell SA, Bardino JD, Knudson DJ. Osteosarcoma with cardiac metastases in a 22-year-old man: about a case and review of cardiac tumors. *Congenitalheartdisease*. September-October2014;9(5):E147-52.
2. Robert Hartemayer, Christopher Kuo, Paul Kent. Métastases d'ostéosarcome avec invasion cardiaque directe : à propos d'un cas et revue de la littérature pédiatrique. *J PediatrHématolOncol*. Avril 2017;39(3):188-193.
3. De Pinieux G. Karanian M. Le Loarer F. et coll. Nationwide incidence of sarcomas and connective tissue tumors of intermediate malignancy over four years using a network of pathology experts. *PLoS Un*. 2021 ; 16 ( e0246958 )
4. Gatta G. Capocaccia R. Botta L. et coll. Burden and centralized treatment of rare tumors in Europe: results of RARECAREnet, a population-based study.*Lancette Oncol*. 2017 ; 18 : 1022-1039
5. Mac Gee W. Metastatic and invasive tumors involving the heart in a geriatric population: an autopsy study.*Virchows Arch Un PatholAnatHistol*. 1991; 419 : 183-189
6. O. Leone et al.2011 consensus statement on endomyocardial biopsy from the Association for European Cardiovascular Pathology and the Society for Cardiovascular Pathology *Cardiovasc Pathol* (2012)
7. FURBER A., PRUNIER J., DE BRUX J.L. et GESLIN P. Cardiopericardialtumors. *Encycl. Méd. chir (Elsevier, Paris), Cardiologie-Angéiologie*,11-028-A-10, 1999, 10p.
8. I. Burazor et al.Metastatic cardiac tumors: from clinical presentation to diagnosis and treatment*Cancer BMC*(2018)
9. Burk A. Virmani R. Tumors of the cardiovascular system, Atlas of tumor pathology, 3rd series. Fascicule. 16. Armed Forces Institute of Pathology, Washington, DC 1996
10. Ndour O., Alumeti D., Fall M et al. 2013. Aspects épidémiologiques, diagnostiques et thérapeutiques des ostéosarcomes de l'enfant. *J. Pan. Afr. Med*. 14; 104-114.
11. Yedururi S, et al. Cardiovascular involvement by osteosarcoma: an analysis of 20 patients. *PediatrRadiol*. 2016 Jan;46(1):21-33. doi: 10.1007/s00247-015-3449-y. Epub 2015 Sep 28. PMID: 26411434; PMCID: PMC4707059.
12. K. Reynen, U Kockeritz, R Hstrasser .Metastases to the heart. *Annals of oncology*. 2004;S0923-7534(19)64134-7
13. Ruba Murad, RimaaBakkar, Rehab Sukkar, Fadi Mahmoud, Alwaleed Al-Dairy M. A case of Ewing's sarcoma with cardiac metastases . *World Journal of Pediatric and Congenital Cardiac Surgery*.2019;10(5):632-634.
14. Aaron Goldberg D, Blankstein R, Padera FR. Metastatic tumors of the heart. *Circulation*. 15 October 2013;128(16):1790-4.

15. Butany J, Leong SW, Carmichael K, Komeda M. A 30-year analysis of cardiac neoplasms at autopsy. *Can J Cardiol.* 2005; 21: 675–680.
16. Osati E, Kaijage A, Muta R, Muhoka P, Mango M, Kisenge P *et al* . Ostéosarcome du membre inférieur métastaté au septum et au côté droit du cœur : à propos d'un cas. *Journal des rapports de cas médicaux.* 13 juin 2017;11(1):156.
17. Robert Hartemayer, Christopher Kuo, Paul Kent. Métastases d'ostéosarcome avec invasion cardiaque directe : à propos d'un cas et revue de la littérature pédiatrique. *J PediatrHématolOncol.* Avril 2017;39(3):188-193.
18. Piazza N, Chughtai T, Toledano K, Sampalis J, Liao C, Morin J. Primary cardiac tumors: eighteen years of surgical experience on 21 patients. *Can J Cardiol.* 2004;20:1443-8
19. L. Polastro , N. de Saint Aubain , M. Lemort , F. Delhayé et A. Awada. Cardiac metastase of a soft tissue sarcoma : a case report and a review of the literature. *Rev Med Brux – 2014* p :501.
20. Azzakhmam, M., Elmenaoui, O., Allaoui, M., Chahdi, H., Albouzidi, H., &Oukabli, M. (2020). Unusual metastatic tumor in the heart: report of an exceptional case with review of the literature. *PAMJ Clinical Medicine.*
21. Ferrari S.Briccoli A.Mercuri M.et coll.Post-relapse survival in extremity osteosarcoma: prognostic factors for long-term survival.*J Clin Oncol.* 2003 ; 21 : 710-715
22. Strauss, S. J., Frezza, A. M., Abecassis, et coll. Bone sarcomas : ESMO–EURACAN–GENTURIS–ERNPaedCan Clinical Practice Guideline for diagnosis, treatment and follow-up. (2021). *Annals of Oncology*

UNDER