

Furosemide reduces TNF levels and increases antioxidant activity in animal models of Nephrotic Syndrome

ABSTRACT

Nephrotic syndrome (NS) is a renal condition characterized by proteinuria, edema formation, hypoalbuminemia and dyslipidemia. Evidence indicates that the immune response plays a fundamental role in disease evolution and maintenance. Although diuretics are used in the NS treatment, it is not known whether they have any effect on immune and redox responses. Therefore, the aim of the present study was to evaluate the furosemide effects in the inflammatory and redox responses in a doxorubicin-induced NS model. Eighteen male adult Wistar rats were divided into 3 groups: Control (n = 6) - received intravenous injection of saline solution; DOXO (n = 6) - received intravenous injection of doxorubicin (7.5 mg/kg); DOXO-F (n = 6) - received intravenous injection of doxorubicin (7.5 mg/kg) and were later treated with furosemide by gavage (5.0 mg/kg). At the end of 36 days of treatment were evaluated: urine protein concentration, blood leukocyte count, kidney histology, cytokine levels (TNF- α , INF- γ and TGF- β), antioxidant levels (FRAP) and enzyme activity (CAT and SOD), besides markers of oxidative stress (TBARS and protein carbonyl) in renal tissue. Data were analyzed with ANOVA and Tukey test when necessary ($p < 0.05$). Furosemide, at the dosage used in this study, promoted increased in global blood leukocytes and reduced lymphocyte blood count. It was also observed that furosemide reduced TNF- α and increased TGF- β levels in renal tissue. In addition, furosemide increased the levels of oxidative stress markers (TBARS and protein carbonyls) and the activity of antioxidant enzymes (SOD and CAT). Thus, furosemide showed anti-inflammatory effects in rats with nephropathy, by reducing TNF- α levels and increasing antioxidant activity in kidney tissue.

.

Keywords: Nephrotic Syndrome. Furosemide. Animal model. Cytokines. Redox status

1 INTRODUCTION

Nephrotic syndrome (NS) is one of the commonest renal conditions in the world (Eddy, Symons, 2003, Menon, 2019, Watanabe, A., 2023). The global incidence of NS can range from 1.2/100,000 to 4.71/100,000 among children aged 1 to 18 years (Eddy, Symons, 2003, Banh, et al., 2016, Franke, et al., 2017), with a higher incidence in females (Franke, et al., 2017). In adults, a higher incidence has been reported in men, and increased with age to 11.77 per 100,000 person-years (Viborg et al., 2023). In a study carried out in Brazil, the average age for the manifestation of NS was 2.9 years, and in 13.8% of these cases it occurred in the first year of life (Watanabe, A., 2023).

The NS is caused by primary kidney diseases or induced by secondary causes, such as diabetes mellitus, lupus erythematosus, bacterial infections or medications (Nazaré, 2017; Troncoso et al., 2018). Clinically, NS is characterized by intense proteinuria, edema formation, hypoalbuminemia and dyslipidemia (Wang and Greenbaum, 2019). These conditions develop from the increased permeability of the renal glomerular membrane, leading mainly to urinary elimination of massive amounts of proteins and other complications (Wang and Greenbaum, 2019).

Although the NS mechanism is not fully understood, evidence indicates that the immune system plays a fundamental role in the disease evolution. For example, immuneresponse may cause the disruption of the glomerular filtration barrier, which would be a major factor in the clinical manifestations of the primary or secondary NS (Daehn and Duffield, 2021). Also, inflammatory infiltrates of macrophages and T lymphocytes were observed in the tubulointerstitial zone in NS early stages (Araya et al., 2009). In addition, other studies show that cytokines and reactive oxygen species can alter the permeability of the glomerular capillary wall (Al-Eisa et al., 2017; Colucci et al., 2018; Ece et al., 2004). Aggravatingly, proteinuria provides the recruitment of more macrophages, prolonging the inflammatory response in the interstitium (Abreu et

al.,2017;WANG et al., 2001).

Regarding NS treatment, in patients with greater renal impairment, loop diuretics are used to contain the disease evolution (Fallahzadeh et al., 2017; Mahmoodpoor et al., 2020). The oral treatment with furosemide reduces edema formation and controls blood pressure through its natriuresis and diuresis mechanisms (Fallahzadeh et al., 2017; Kallash and Mahan, 2021; Mahmoodpoor et al., 2020; Varghese and Majumdar, 2021). Additionally, furosemide also showed anti-inflammatory and antioxidant effects when using other experimental models (Arumugam et al., 2014; Bryniarski et al., 2021; dos Santos et al., 2018), suggesting that this drug could also have an effect on NS inflammatory and oxidant responses.

In this context, it remains to be explored whether furosemide has any action on inflammatory and redox state markers in NS. Therefore, the aim of the present study was to evaluate the effects of furosemide on proteinuria, leukocyte response, production of the cytokines TNF, IFN and TGF, redox response, as well as on histological alterations, in an experimental model of NS.

2 MATERIALS AND METHODS

2.1 Ethical statement

All experimental procedures were approved by the Ethics Committee on the Use of Animals of Federal University of Jequitinhonha and Mucuri Valleys-UFVJM (protocol number 001/2019) and occurred according to the ethical principles of animal use (CONCEA, 2016). Eighteen male Wistar rats were obtained from Experimental Physical Training Laboratory/UFVJM and kept under controlled environmental conditions, with free access to food (Nuvilab[®] CR-1) and potable water.

2.2 Experimental design

On the first day of the experiment (D0), 18 male Wistar rats (six-week-old) were randomly placed in three groups: Control (n = 6) - received intravenous injection

of saline solution (isotonic and pyrogen-free sodium chloride solution 0.9%); DOXO (n = 6) and DOXO-F (n = 6) - received intravenous injection of doxorubicin hydrochloride (7.5 mg/kg of body weight) (Pereira et al., 2015a).

The furosemide administration (5.0 mg/kg of body weight) occurred by gavage only for the DOXO-F group, from the seventh day (D7) onwards (D36). The Control and DOXO groups received potable water under the same conditions. The treatments were performed daily until the day of euthanasia (D36).

2.3 Protein evaluation

Protein levels were measured using 24-hour urine samples, collected weekly in metabolic cages (Insight[®], Ribeirão Preto, São Paulo, Brazil) on D0 (before doxorubicin injection), D7, D14, D21, D28 and D35 (after doxorubicin injection). First, the urine samples (24 hour) were diluted in the proportion of 100 microliters of the sample for each 9.9 mL of deionized water (Gomes et al., 2017). Proteinuria analysis was carried out by colorimetric Bradford assay (Bradford, 1976).

2.4 Euthanasia and sample collection

On D36, the animals were anesthetized (xylazine 8 mg/kg; ketamine 60 mg/kg) and euthanized by exsanguination process. The blood was collected to perform blood leukocyte count. The left kidney was removed and sectioned for histological analysis, in addition to cytokines and redox state evaluations.

2.5 Blood Leukocyte Count

For global leukocyte count, 10 µL of the blood sample from each animal was diluted in 190 µL of Turkey's solution (red cell lysis) and counted in a Neubauer hemocytometric chamber (Neubauer Improved[®], Marienfeld – Germany) under light microscopy (Olympus Optical Co., Ltd. Microscope – BX41 TF – Japan). Differential white blood cell counts were performed in blood smears using an optical microscope (Olympus-

BX41TF, Japan) after May-Grunwald-Giemsastaining (Pereira et al., 2015a).

2.6 Histological analysis

The left kidney was segmented into coronal sections, fixed and stained with hematoxylin and eosin (HE) and Masson's Trichrome (MT) for the analysis of morphological changes and kidney fibrosis, according to Pereira et al., 2015a. Histological images were analyzed using light microscopy (Microscope Olympus Optical CO. Ltd – BX41 TF-Japan) and scanned by a camera (NIKON, Eclipse E220) attached to the microscope. The ImageJ[®] (ImageJ, U. S. National Institutes of Health, Bethesda, Maryland, USA) software was used for the analysis.

2.7 Cytokine analyses

For cytokine analyses, renal samples were homogenized in the extraction solution (0.4 M NaCl, 0.05% Tween 20, 0.5% bovine serum albumin (BSA), 0.1 mM phenylmethylsulfonyl fluoride, 0.1 mM benzethonium chloride, 10 mM EDTA, and 20 kIU aprotinin) prepared in PBS. The homogenates were centrifuged at $10,000 \times g$ for 10 min at 4 °C. Tumor necrosis factor- α (TNF- α), Interferon- γ (INF- γ) and Transforming growth factor- β (TGF- β) levels were measured in duplicate using an enzyme-linked immunosorbent assay (ELISA) according to the manufacturer's instructions (R&D Systems[®]) and as previously described (Rocha-Gomes et al., 2022). TGF- β /TNF- α ratio was calculated and classified as an anti-inflammatory marker (Babania et al., 2021).

2.8 Redox state

For tissue preparation, the kidney was homogenized in cold PBS (50 mM, pH 7.0), and centrifuged at 750 g for 10 min at 4 °C, as previously described (Rocha-Gomes et al., 2021).

The total antioxidant capacity was evaluated using the ferric reducing antioxidant power (FRAP) method, monitored at 550nm, with FeSO₄ used as standard (Benzie and Strain, 1996; Rocha-Gomes et al., 2021). For the activity of the antioxidant enzyme superoxide dismutase (SOD), the pyrogallol oxidation method was used. The oxidation process was measured at 420nm for 250s at intervals of 10s and 37°C (MARKLUND and MARKLUND, 1974; Rocha-Gomes et al., 2021). Catalase (CAT) activity was assessed by metabolizing hydrogen peroxide. The readings were performed in a microplate reader every 15 seconds for 1 minute at 25°C (Nelson and Kiesow, 1972; Rocha-Gomes et al., 2021).

The lipid peroxidation evaluation was performed using the thiobarbituric acid reactive substances (TBARS) method with malondialdehyde (MDA; 1,1,3,3-tetramethoxypropane) as the standard, being monitored at 532nm using (Ohkawa et al., 1979; Rocha-Gomes et al., 2021). Protein carbonyls were evaluated in pellets from the homogenates and were determined using the 2,4-dinitrophenylhydrazine (DNPH) method, monitored at 370 nm (Levine et al., 1990; Rocha-Gomes et al., 2021).

Protein content was quantified using BSA (1 mg/mL) as the standard (Bradford, 1976). The results of the redox state were corrected for the amount of protein in the samples. All redox analyses were performed in triplicate, using a plate reader (UV/visible U-200 L Spectrophotometer).

2.9 Statistical analyses

Analyses were performed using the GraphPad Prism 8.0 (GraphPad, La Jolla, California, USA). The results were expressed as mean and standard deviation (SD), with a significance level of 95% ($p < 0,05$). According to normality, the data were analyzed using the one-way or two-way analysis of variance (ANOVA), with Tukey

posthoc test or Kruskal Wallis test. Area under the curve (AUC) were recalculated from the baseline using the trapezoidal method in the GraphPad Prism 8.0.

3 RESULTS

Significant differences were observed in the protein levels of the DOXO group from D21 and in the DOXO-F group from D14 both compared to the Control group (Figure 1A). AUC analysis showed that the DOXO and DOXO-F groups had higher proteinuria compared to the Control group (Figure 1B).

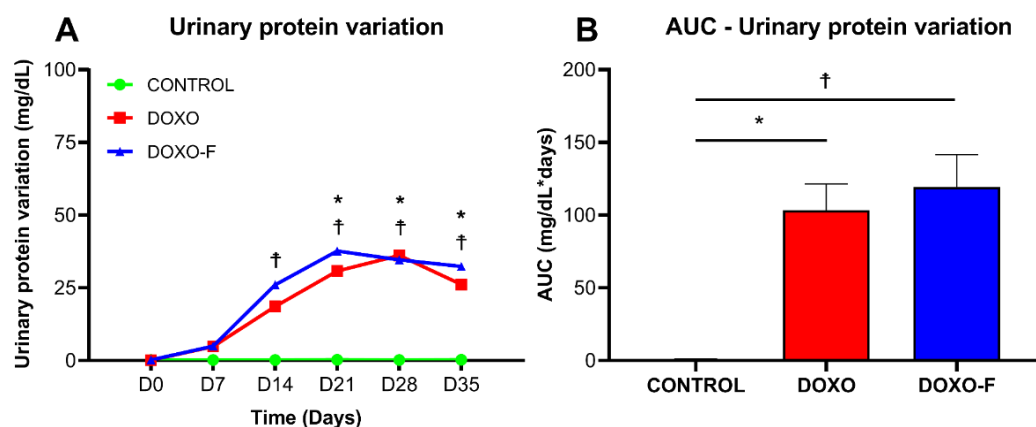


Figure 1. Urinary protein variation (A) and its respective area under the curve (B) from rats with doxorubicin-induced NS. Data are represented as mean \pm SD. CONTROL – Negative Control Group (no nephropathy and no treatment). DOXO – Positive Control Group (with nephropathy and no treatment). DOXO-F – Test Group (with nephropathy and treatment with oral Furosemide). Data presented as mean \pm SD. Urinary protein variation was analyzed by two-way ANOVA and area under the curve (AUC) by one-way ANOVA, both with Tukey post-test. $n=6$; * $p<0.05$ DOXO vs. CONTROL groups; † $p<0.05$ DOXO-F vs. CONTROL groups.

Histological evaluation by HE staining showed a reduction in the number of glomeruli, increased hyalinization of the renal parenchyma and interstitial cellularity, indicative of an inflammatory infiltrate in DOXO group compared to Control. In the DOXO-F group, more glomeruli count and mild atrophy were observed compared to the DOXO group (Figure 2).

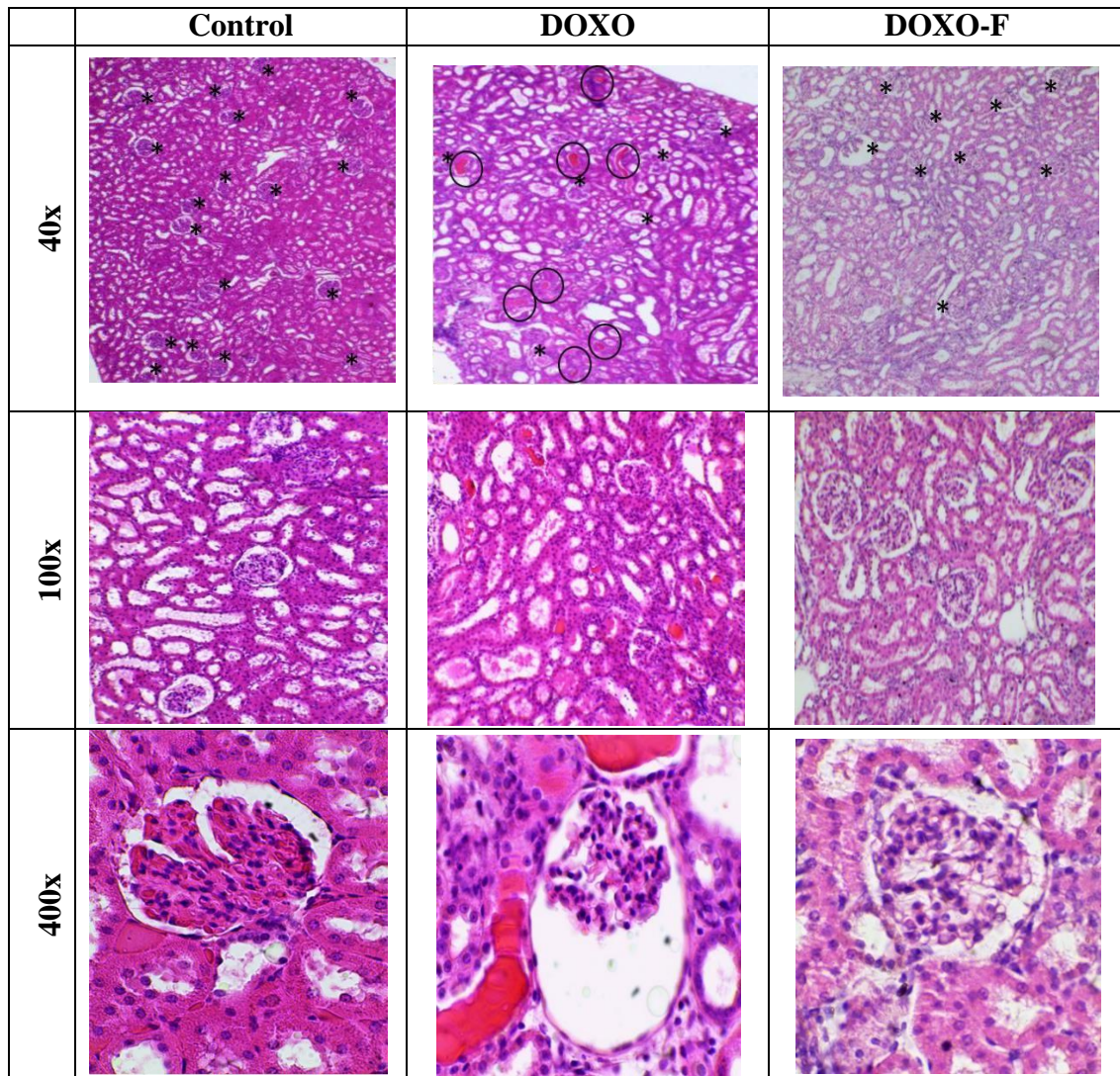


Figure 2. Renal histology from rats with doxorubicin-induced NS. Control – NegativeControl Group (no nephropathy and no treatment). DOXO – Positive Control Group (with nephropathy and no treatment). DOXO-F – Test Group (with nephropathy and treatment with oral Furosemide). The circled areas represent hyaline formations, while the * shows the presence of glomeruli. The photomicrographs are presented in H&E staining at 40x, 100x and 400x.

MT staining of kidney sections revealed an accumulation of collagen fibers among glomerular capillaries in the Bowman's capsule of the glomeruli in the DOXO group. The DOXO-F group was more similar to the control group and showed a slight deposition of collagen fibers in the glomeruli (Figure 3).

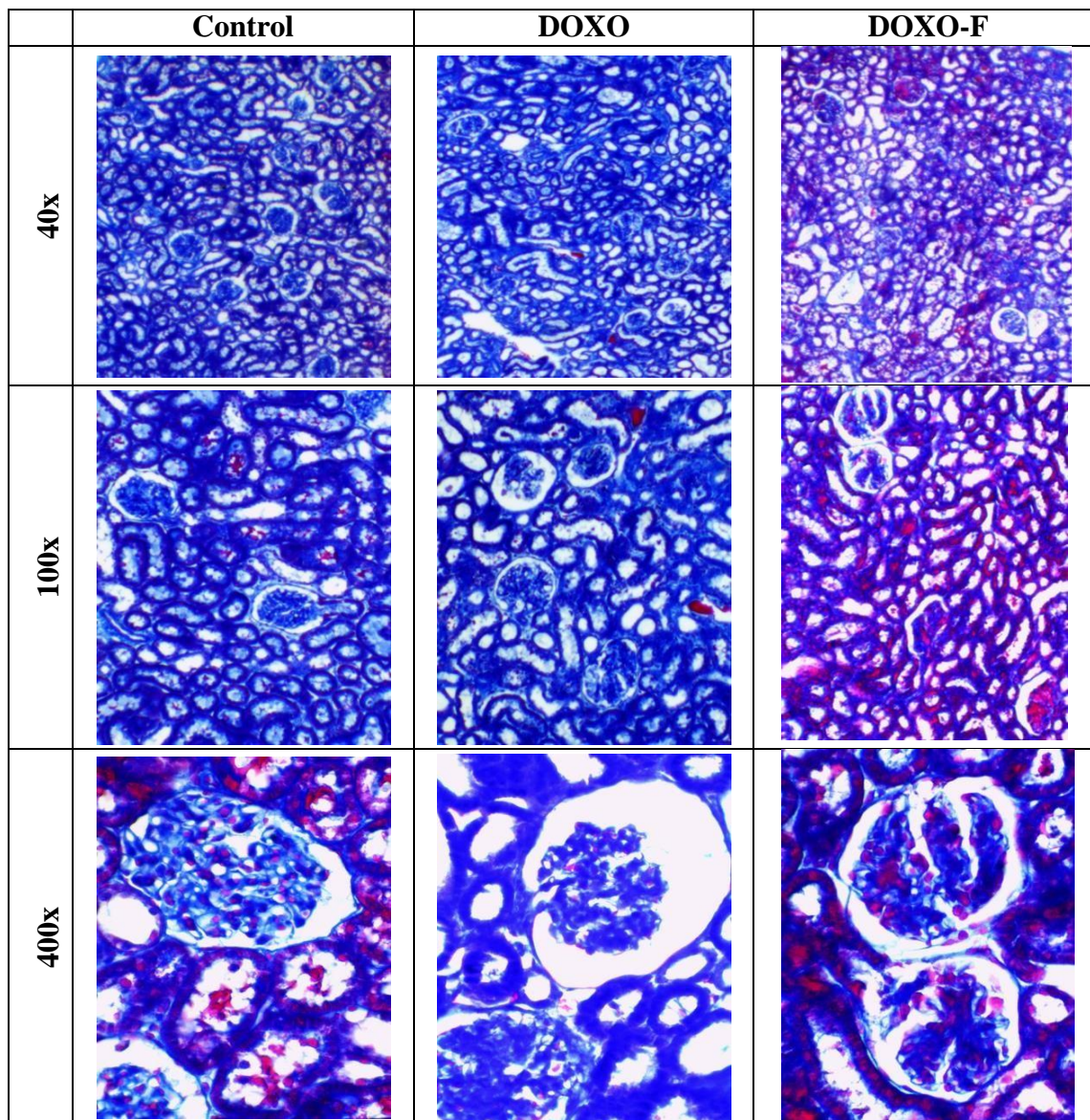


Figure 3. Renal histology from rats with doxorubicin-induced NS. Control – NegativeControl Group (no nephropathy and no treatment). DOXO – Positive Control Group (with nephropathy and no treatment). DOXO-F – Test Group (with nephropathy and treatment with oral Furosemide). The photomicrographs are presented in MT staining at 40x, 100x and 400x.

The DOXO-F group had high values in the global leucocyte count when compared to the DOXO and CONTROL groups (Figure 4). Regarding the percentage of lymphocytes, the DOXO and DOXO-F groups presented lower values compared to the CONTROL group (Figure 4). It was also observed that the DOXO-F group had a lower percentage of lymphocytes than the DOXO group. Furthermore, the DOXO-F group presented a higher percentage of monocytes compared to the DOXO group (Figure 4).

Regarding the neutrophils number, higher amounts of these cells were observed in the DOXO-F group (Figure 4).

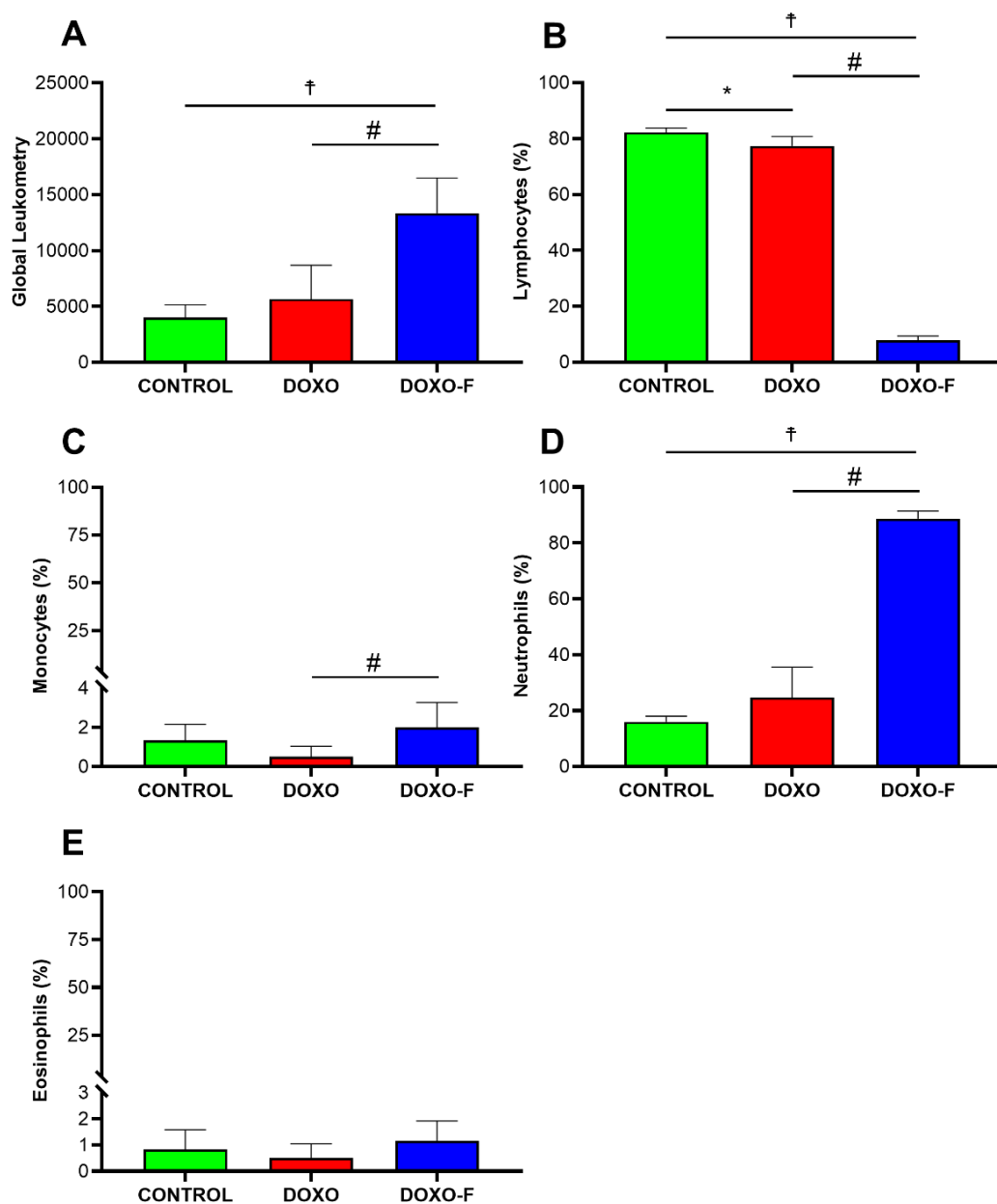


Figure 4. Global leukocyte count (A); percentage of lymphocytes (B), monocytes (C), eosinophils (D) and neutrophils (E) in the blood of rats with doxorubicin-induced NS. Data are presented as mean \pm SD. Control – Negative Control Group (no nephropathy and no treatment). DOXO – Positive Control Group (with nephropathy and no treatment). DOXO-F – Test Group (with nephropathy and treatment with oral Furosemide). Data presented as mean \pm SD. Data were analyzed by one-way ANOVA with Tukey post-test. $n = 6$; * $p < 0.05$ DOXO vs. Control groups; † $p < 0.05$ DOXO-F vs. Control groups; # $p < 0.05$ DOXO vs. DOXO-F groups.

Significant increase in the renal concentration of TNF- α were showed in DOXO and DOXO-F groups when compared to the CONTROL group. In addition, the DOXO group had higher concentration of this cytokine compared to the DOXO-F group (Figure 5).

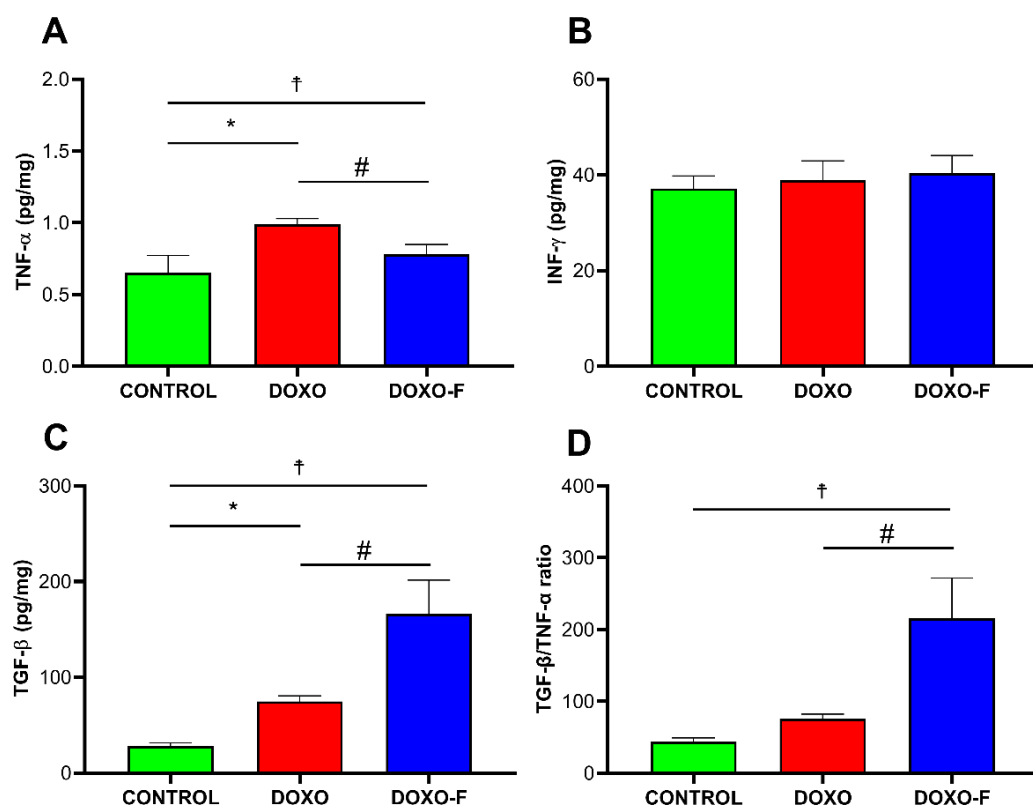


Figure 5. Renal levels of TNF- α (A), INF- γ (B), TGF- β (C) and TGF- β /TNF- α ratio from rats with doxorubicin-induced NS. Data are presented as mean \pm SD. Control – Negative Control Group (no nephropathy and no treatment). DOXO – Positive Control Group (with nephropathy and no treatment). DOXO-F – Test Group (with nephropathy and treatment with oral Furosemide). Data presented as mean \pm SD. Data were analyzed by one-way ANOVA with Tukey post-test. n=6; *p<0.05 DOXO vs. Control groups; †p<0.05 DOXO-F vs. Control groups; # p<0.05 DOXO vs DOXO-F groups.

The renal concentration of TGF- β was significantly higher in the DOXO and DOXO-F groups compared to the CONTROL group. There was also increase in TGF- β in DOXO-F group compared to the DOXO group. Furthermore, DOXO-F group showed a higher TGF- β /TNF- α ratio compared to DOXO and CONTROL groups. No difference was showed for the INF- γ renal levels (Figure 5).

Regarding FRAP levels, a higher antioxidant capacity was showed in the DOXO-F group compared to the DOXO and CONTROL groups. In addition, the activities of SOD and CAT enzymes were higher in DOXO-F and CONTROL groups compared to the DOXO group (Figure 6).

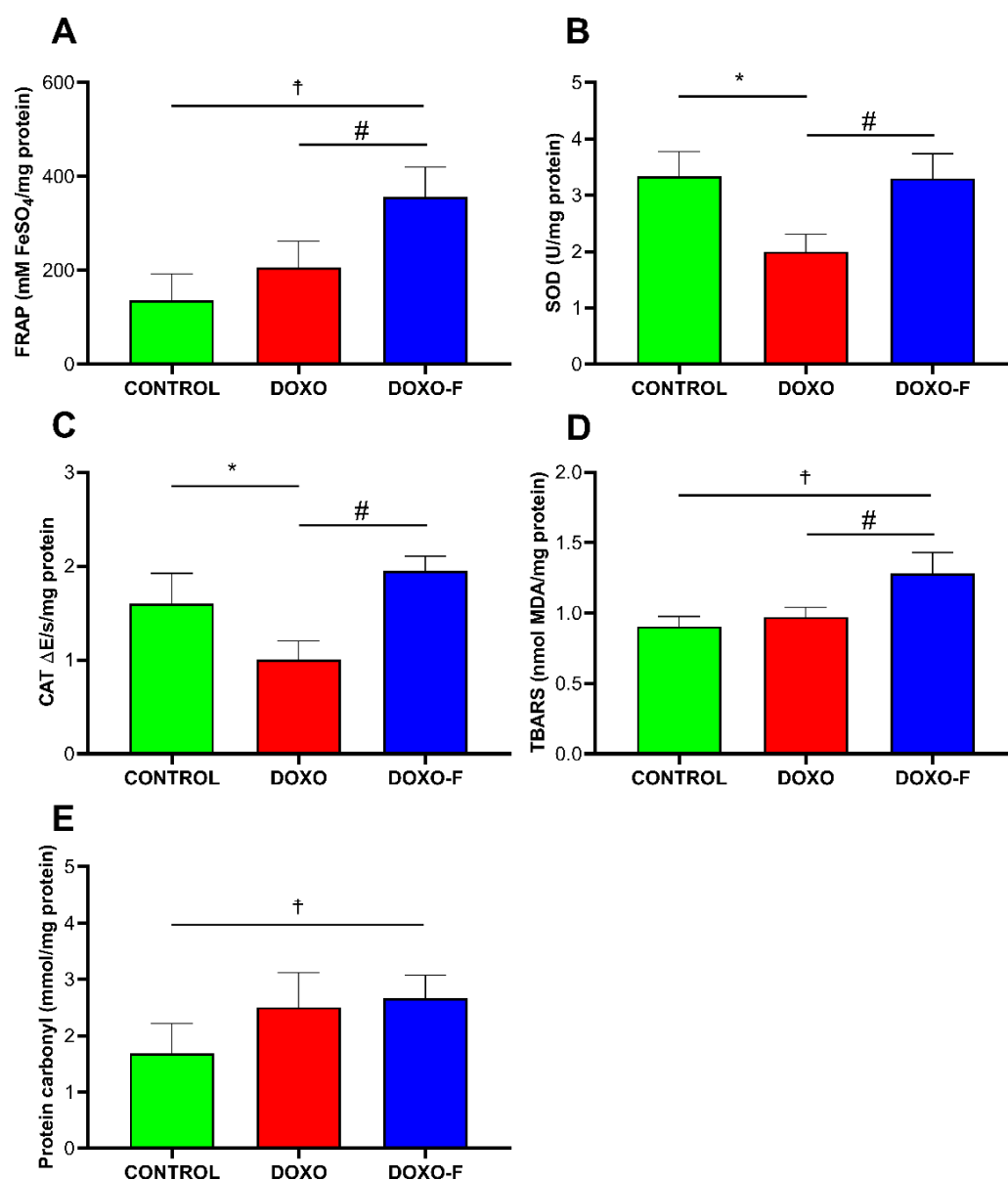


Figure 6. Renal FRAP total antioxidant capacity (A); SOD (B) and CAT (C) activity; TBARS (D) and protein carbonyl (E) concentrations from rats with doxorubicin-induced NS. Data are presented as mean \pm SD. Control – Negative Control Group (non-nephropathy and no treatment). DOXO – Positive Control Group (with nephropathy and no treatment). DOXO-F – Test Group (with nephropathy and treatment with oral Furosemide). Data presented as mean \pm SD. Data were analyzed by one-way ANOVA with Tukey post-test. n=6; *p<0.05 DOXO vs. Control groups; †p<0.05 DOXO-F vs. Control groups; # p<0.05 DOXO vs. DOXO-F groups.

DOXO-F group showed an increase in TBARS levels compared to the CONTROL and DOXO groups. Also, there was an increase in the expression of the protein carbonyl in the DOXO-F group compared to the CONTROL group (Figure 6).

4 DISCUSSION

The use of diuretics has been recognized as one of the main treatments for primary or secondary NS, mainly due to their benefits in reducing body edema (Fallahzadeh et al., 2017; Mahmoodpoor et al., 2020). Furthermore, some studies have demonstrated possible anti-inflammatory action of furosemide (Yuengsrigul; Chin; Nussbaum, 1999, Hofbauer et al., 2002, Prandota, 2002), however, none of these studies, regarding anti-inflammatory action of furosemide was carried out in an experimental model of Nephropathy.

Here, it was shown that the doxorubicin-induced NS model (DOXO and DOXO-F groups) led to proteinuria and high glomerular damage, both characteristic conditions in NS. Additionally, the DOXO group showed increased levels of inflammatory cytokines and low activity of antioxidant enzymes in renal tissue. In contrast, furosemide (DOXO-F group) reduced the damage caused by doxorubicin, promoted an anti-inflammatory response and increased activity of antioxidant enzymes in the kidney.

The presence of proteinuria is considered an expressive marker of kidney damage and is part of the NS diagnosis (Kopp et al., 2020). Proteinuria occurs due to increased protein filtration by glomeruli and a reduction in the rate of tubular reabsorption, causing podocyte and tubular lesions, interstitial changes, edema formation, fibrosis and inflammatory cell infiltrates (Ogawa-Akiyama et al., 2020; Tapia and Bashir, 2021). Corroborating other studies, the groups that received the doxorubicin injection (DOXO and DOXO-F) showed an increase in protein concentration in the urine (Elsherbini and Ebrahim, 2020; Pereira et al., 2015b), confirming the effectiveness of the model in inducing NS.

The use of doxorubicin is also linked to glomerular atrophy and increased capillary

permeability, factors that are associated with the proteinuria (Xiang et al., 2021). This condition can be observed in the histological analysis of the present study, in which the DOXO and DOXO-F groups showed a reduction in the glomeruli number in relation to the CONTROL group. However, it is important to highlight that the furosemide administration attenuated glomeruli loss in relation to the DOXO group, which may suggest an improvement in the NS pathophysiological evolution.

The increase in the leukocytes migration in animals with nephropathy may be related to an exacerbated immune response, also described using other experimental nephropathy models (Kelly et al., 2009; Kitamoto et al., 2009). Therefore, the lower levels of blood lymphocytes presented by the DOXO-F group are suggestive of the migration of these cells to the renal tissue, since lymphocytes are one of the several cells responsible for the TGF- β production (Lvet et al., 2018; Stolfi et al., 2020).

Several studies have identified the role of inflammation in the development and NS evolution (Colucci et al., 2018; Daehn and Duffield, 2021; Pereira et al., 2015a). In the present study, the DOXO and DOXO-F groups showed an increase in the levels of renal TNF- α . This is one of the main cytokines involved in the inflammatory processes, being released by activated mast cells and macrophages, also stimulating other cells of the immune system (Mehaffey and Majid, 2017). Hence, it is possible to assume that the elevation of TNF- α is linked to the doxorubicin injection and NS development, with consequent inflammatory response and tissue damage (Suranyi, Guasch, Hall, Myers, 1993, Bryniarski et al., 2021, Mariani, L.H, Eddy, S., AlAkwa, F.M, et al. 2023).

Interestingly, the DOXO-F group had lower levels of renal TNF- α compared to the DOXO group. Some studies had already shown anti-inflammatory action of furosemide in vitro using human peripheral blood mononuclear cells, reporting reduction of cytokines, such as IL-6, IL-8 and TNF- α (Bryniarski et al., 2021; Yuengsrigul et al., 1999). In addition, the DOXO-F group had higher concentrations of renal TGF- β and a greater TGF- β /TNF- α ratio compared to the other groups. TGF- β has an important role in the regulation of processes such as tissue

repair and apoptosis, besides acting in the control of immune system homeostasis and inflammation (Teicher, 2021). To the best of our knowledge, this is the first study to show that the furosemide application can reduce renal levels of pro-inflammatory cytokine (TNF- α) and increase the concentration of one involved in tissue repair (TGF- β). These data suggest an anti-inflammatory role in renal tissue promoted by furosemide, with a consequent attempt to return to homeostasis.

The increase in reactive oxygen and nitrogen species can lead to oxidative stress, causing damage to proteins and lipids, raising the level of TBARS and carbonyl derivatives in proteins. In contrast, to contain tissue oxidative stress advance, there is an increase in the production of antioxidant enzymes to maintain the redox state homeostasis (Bakunina et al., 2015). In the present study, the DOXO-F group showed an increase in the expression of TBARS and carbonyl protein, but also an elevation in the activity of SOD and CAT enzymes, as well as in the FRAP levels. The renal oxidative stress has been shown in other studies that used doxorubicin or different models of kidney injury (Boonsanit et al., 2006; Khajevand-Khazaei et al., 2019). Furthermore, patients with NS have a strong correlation between oxidative stress and disease progression (Daenen et al., 2019). However, the increased activity of antioxidant enzymes in the DOXO-F group suggests that furosemide may trigger a response to contain oxidative damage (Arumugam et al., 2014; Bryniarski et al., 2021). These results reinforce those observed in cytokine levels, indicating an anti-inflammatory and antioxidant action of furosemide.

Some limitations were noted in this study. For a better understanding of the anti-inflammatory action of furosemide on renal tissue, other inflammatory markers, as well as evaluation at different timepoints are necessary. In addition, the direct dosage of reactive species, evaluation of Nrf2 (nuclear erythroid factor 2-related factor 2) and the markers of its pathway expression, could be key elements to further understand the interaction of the redox state with the NS evolution. Finally, the need for future studies with other doses of furosemide and longer exposure time is evident.

The present study showed that the use of furosemide can attenuate the NS progression, possibly through an anti-inflammatory and antioxidant action. These findings are important to increase the discussion around NS therapy, since in some cases corticosteroids and immunosuppressants are used, which have serious long-term adverse effects (Chin et al., 2021; Zhao and Liu, 2020). Hence, the demonstration of the anti-inflammatory properties of furosemide may be useful for discussing new clinical approaches.

5 CONCLUSION

Furosemide reduced TNF α levels and increased antioxidant activity in the renal tissue of rats with doxorubicin-induced nephropathy, thus demonstrating a beneficial effect in attenuating the inflammatory response in an experimental model of nephropathy.

ETHICS APPROVAL

This study was previously approved by the Animal Ethics Committee of Federal University of Jequitinhonha and Mucury Valleys (UFVJM) regarding the Guiding Principles in the Care and Use of Animals, with an approved protocol number of 001/19.

ACKNOWLEDGMENTS

This study was supported by the Universidade Federal dos Vales do Jequitinhonha e Mucuri (UFVJM) and by the following Brazilian research agencies: Fundação do Amparo a Pesquisa do Estado de Minas Gerais (CBB-APQ-01219-14), Conselho Nacional de Desenvolvimento Científico e Tecnológico (439373/2018-2), and Coordenação de Aperfeiçoamento de Pessoal de Nível Superior.

COMPETING INTERESTS

Authors have declared that no competing interests exist.

6 REFERENCES

- Abreu, T.T., Neves, N.C.S., Alves, L.F., Otoni, A., 2017. Lesão Renal Glomerular: Processo Inflamatório E O Papel Das Quimiocinas Tt- Glomerular Kidney Injury: the Inflammatory Process and the Role of Chemokines. *Arq. ciências saúde UNIPAR* 21, 131–136.
- Al-Eisa, A.A., Al Rushood, M., Al-Attiyah, R.J., 2017. Urinary excretion of IL-1 β , IL-6 and IL-8 cytokines during relapse and remission of idiopathic nephrotic syndrome. *J. Inflamm. Res.* 10, 1–5. <https://doi.org/10.2147/JIR.S124947>
- Araya, C., Diaz, L., Wasserfall, C., Atkinson, M., Mu, W., Johnson, R., Garin, E., 2009. Tregulatory cell function in idiopathic minimal lesion nephrotic syndrome. *Pediatr. Nephrol.* 24, 1691–1698. <https://doi.org/10.1007/s00467-009-1214-x>
- Arumugam, S., Sreedhar, R., Miyashita, S., Karuppagounder, V., Thandavarayan, R.A., Giridharan, V.V., Pitchaimani, V., Afrin, R., Harima, M., Suzuki, K., Watanabe, K., 2014. Comparative evaluation of torasemide and furosemide on rats with streptozotocin-induced diabetic nephropathy. *Exp. Mol. Pathol.* 97, 137–143. [https://doi.org/https://doi.org/10.1016/j.yexmp.2014.06.007](https://doi.org/10.1016/j.yexmp.2014.06.007)

- Babania, O., Mohammadi, S., Yaghoubi, E., Sohrabi, A., Sadat Seyedhosseini, F., Abdolahi, N., Yazdani, Y., 2021. The expansion of CD14+ CD163+ subpopulation of monocytes and myeloid cells - associated cytokine imbalance; candidate diagnostic biomarkers for celiac disease (CD). *J. Clin. Lab. Anal.* 35, e23984. <https://doi.org/10.1002/jcla.23984>
- Bakunina, N., Pariante, C.M., Zunszain, P.A., 2015. Immune mechanisms linked to depression via oxidative stress and neuroprogression. *Immunology* 144, 365–373. <https://doi.org/10.1111/imm.12443>
- Banh, T.H.M., Hussain-Shamsy N., Viral Patel, V., et al., 2016. Ethnic Differences in Incidence and Outcomes of Childhood Nephrotic Syndrome. *Clin J Am Soc Nephrol.* Oct 7; 11(10): 1760–1768. doi: 10.2215/CJN.00380116: 10.2215/CJN.00380116
- Benzie, I.F.F., Strain, J.J., 1996. The Ferric Reducing Ability of Plasma (FRAP) as a Measure of “Antioxidant Power”: The FRAP Assay. *Anal. Biochem.* 239, 70–76. <https://doi.org/10.1006/abio.1996.0292>
- Boonsanit, D., Kanchanapangka, S., Buranakarl, C., 2006. L-carnitine ameliorates doxorubicin-induced nephrotic syndrome in rats. *Nephrology (Carlton)*. 11, 313–320. <https://doi.org/10.1111/j.1440-1797.2006.00592.x>
- Bradford, M.M., 1976. A rapid and sensitive method for the quantitation of microgram quantities of protein utilizing the principle of protein-dye binding. *Anal. Biochem.* 72, 248–254. <https://doi.org/10.1006/abio.1976.9999>
- Bryniarski, P., Nazimek, K., Marcinkiewicz, J., 2021. Anti-inflammatory activities of captopril and diuretic on macrophage activity in mouse humoral immune response. *Int. J. Mol. Sci.* 22. <https://doi.org/10.3390/ijms222111374>
- Chin, H.J., Chae, D.W., Kim, Y.C., An, W.S., Ihm, C.G., Jin, D.C., Kim, S.G., Kim, Y.L., Kim, Y.S., Kim, Y.G., Koo, H.S., Lee, J.E., Lee, K.W., Oh, J., Park, J.H., Jiang, H., Lee, H., Lee, S.K., 2021. Comparison of the efficacy and safety of tacrolimus and low-dose corticosteroid with high-dose corticosteroid for minimal change nephrotic syndrome in adults. *J. Am. Soc. Nephrol.* 32, 199–210. <https://doi.org/10.1681/ASN.2019050546>
- Colucci, M., Corpetti, G., Emma, F., Vivarelli, M., 2018. Immunology of idiopathic nephrotic syndrome. *Pediatr. Nephrol.* 33, 573–584. <https://doi.org/10.1007/s00467-017-3677-5>
- CONCEA, C.N. de C. de E.A., 2016. Diretrizes brasileira para o cuidado e a utilização de animais em atividade de ensino ou de pesquisa científica, Resolução Normativa nº 30 (2016).
- Daehn, I.S., Duffield, J.S., 2021. The glomerular filtration barrier: a structural target for novel kidney therapies. *Nat. Rev. Drug Discov.* 20, 770–

788.<https://doi.org/10.1038/s41573-021-00242-0>

Daenen, K., Andries, A., Mekahli, D., Van Schepdael, A., Jouret, F., Bammens, B., 2019. Oxidative stress in chronic kidney disease. *Pediatr. Nephrol.* 34, 975–991.<https://doi.org/10.1007/s00467-018-4005-4>

Dos Santos, L.R.S.S.R., de Freitas Santos, A., das Graças Andrade Korn, M., 2018. Effects of furosemide administration on the concentration of essential and toxic elements in Wistar rats by inductively coupled plasma optical emission spectrometry. *J. Trace Elem. Med. Biol.* 48, 25–

29.<https://doi.org/https://doi.org/10.1016/j.jtemb.2018.02.029>

Ece, A., Atamer, Y., Gürkan, F., Bilici, M., Koçigit, Y., 2004. Anti-oxidant status in relation to lipoproteins, leptin and pro-inflammatory cytokines in children with steroid-sensitive nephrotic syndrome. *Nephrology* 9, 366–

373.<https://doi.org/https://doi.org/10.1111/j.1440-1797.2004.00340.x>

Eddy A.A, Symons J.M, 2003 Nephrotic syndrome in childhood. *Lancet* 362:629–39. doi: [10.1016/S0140-6736\(03\)14184-0](https://doi.org/10.1016/S0140-6736(03)14184-0)

Elsherbini, D.M.A., Ebrahim, H.A., 2020. Effect of meloxicam (cyclooxygenase-2 inhibitor) versus vitamin D3 (cholecalciferol) as a meliorating agent of progressive doxorubicin-induced nephrotoxicity in rats. *Anat. Cell Biol.* 53, 169–182.<https://doi.org/10.5115/acb.19.231>

Fallahzadeh, M.A., Dormanesh, B., Fallahzadeh, M.K., Roozbeh, J., Fallahzadeh, M.H., Sagheb, M.M., 2017. Acetazolamide and Hydrochlorothiazide Followed by Furosemide Versus Furosemide and Hydrochlorothiazide Followed by Furosemide for the Treatment of Adults With Nephrotic Edema: A Randomized Trial. *Am. J. Kidney Dis.* 69, 420–427.<https://doi.org/https://doi.org/10.1053/j.ajkd.2016.10.022>

Franke, I., Aydin, M., Lopez, C.E.L., Kurylowicz L., Ganschow, R., Lentze, M., Born, M., 2017. The incidence of the nephrotic syndrome in childhood in Germany. *Clin Exp Nephrol*, doi [10.1007/s10157-017-1433-6](https://doi.org/10.1007/s10157-017-1433-6)

Gomes, P.M., Sá, R.W.M., Aguiar, G.L., Paes, M.H.S., Alzamora, A.C., Lima, W.G., de Oliveira, L.B., Stocker, S.D., Antunes, V.R., Cardoso, L.M., 2017. Chronic high-sodium diet intake after weaning lead to neurogenic hypertension in adult Wistar rats. *Sci. Rep.* 7, 5655.<https://doi.org/10.1038/s41598-017-05984-9>

Hofbauer, R. et al., 2002. Furosemide and spironolactone reduce transmigration of leukocytes through endothelial cell monolayers. *Journal of Toxicology and Environmental Health - Part A*, v. 65, n. 9, p. 685–693.

Kallash, M., Mahan, J.D., 2021. Mechanisms and management of edema in pediatric nephrotic syndrome. *Pediatr. Nephrol.* 36, 1719–1730.<https://doi.org/10.1007/s00467-020-04779-x>

- Kelly, K.J., Burford, J.L., Dominguez, J.H., 2009. Postischemic inflammatory syndrome: a critical mechanism of progression in diabetic nephropathy. *Am. J. Physiol. Physiol.* 297, F923–F931. <https://doi.org/10.1152/ajprenal.00205.2009>
- Khajevand-Khazaei, M.-R., Azimi, S., Sedighnejad, L., Salari, S., Ghorbanpour, A., Baluchnejadmojarad, T., Mohseni-Moghaddam, P., Khamse, S., Roghani, M., 2019. S-allyl cysteine protects against lipopolysaccharide-induced acute kidney injury in the C57BL/6 mouse strain: Involvement of oxidative stress and inflammation. *Int. Immunopharmacol.* 69, 19–26. <https://doi.org/10.1016/j.intimp.2019.01.026>
- Kitamoto, K., Machida, Y., Uchida, J., Izumi, Y., Shiota, M., Nakao, T., Iwao, H., Yukimura, T., Nakatani, T., Miura, K., 2009. Effects of liposome clodronate on renal leukocyte populations and renal fibrosis in murine obstructive nephropathy. *J. Pharmacol. Sci.* 111, 285–292. <https://doi.org/10.1254/jphs.09227FP>
- Kopp, J.B., Anders, H.-J., Susztak, K., Podestà, M.A., Remuzzi, G., Hildebrandt, F., Romagnani, P., 2020. Podocytopathies. *Nat. Rev. Dis. Prim.* 6, 68. <https://doi.org/10.1038/s41572-020-0196-7>
- Levine, R.L., Garland, D., Oliver, C.N., Amici, A., Climent, I., Lenz, A.G., Ahn, B.W., Shaltiel, S., Stadtman, E.R., 1990. Determination of carbonyl content in oxidatively modified proteins. *Methods Enzymol.* 186, 464–478. [https://doi.org/10.1016/0076-6879\(90\)86141-h](https://doi.org/10.1016/0076-6879(90)86141-h)
- Lv, W., Booz, G.W., Wang, Y., Fan, F., Roman, R.J., 2018. Inflammation and renal fibrosis: Recent developments on key signaling molecules as potential therapeutic targets. *Eur. J. Pharmacol.* 820, 65–76. <https://doi.org/10.1016/j.ejphar.2017.12.016>
- Mahmoodpoor, A., Zahedi, S., Pourakbar, A., Hamishehkar, Hamed, Shadvar, K., Asgharian, P., Shahabi, F., Hamishehkar, Hadi, 2020. Efficacy of furosemide-albumin compared with furosemide in critically ill hypoalbuminemic patients admitted to intensive care unit: a prospective randomized clinical trial. *DARU J. Pharm. Sci.* 28, 263–269. <https://doi.org/10.1007/s40199-020-00339-8>
- Mariani, L.H., Eddy, S., AlAkwa, F.M., et al. 2023. Precision nephrology identified tumor necrosis factor activation variability in minimal change disease and focal segmental glomerulosclerosis. *Kidney Int.* 103(3):565–579. doi:10.1016/j.kint.2022.10.023
- Marklund, S., Marklund, G., 1974. Involvement of the Superoxide Anion Radical in the Autoxidation of Pyrogallol and a Convenient Assay for Superoxide Dismutase. *Eur. J. Biochem.* 47, 469–474. <https://doi.org/10.1111/j.1432-1033.1974.tb03714.x>
- Mehaffey, E., Majid, D.S.A., 2017. Tumor necrosis factor- α , kidney function, and hypertension. *Am. J. Physiol. Physiol.* 313, F1005–F1008. <https://doi.org/10.1152/ajprenal.00535.2016>

Menon S, 2019. Acute Kidney Injury in Nephrotic Syndrome. *Front. Pediatr.* 6:428. doi: 10.3389/fped.2018.00428

Nazaré, A. F. P. D. A., 2017. Resistência à Corticoterapia no Síndrome Nefrótico Pediátrico. [s.l.] Faculdade de Medicina da Universidade de Coimbra.

Nelson, D.P., Kiesow, L.A., 1972. Enthalpy of decomposition of hydrogen peroxide by catalase at 25 degrees C (with molar extinction coefficients of H₂O₂ solutions in the UV). *Anal. Biochem.* 49, 474–478. [https://doi.org/10.1016/0003-2697\(72\)90451-4](https://doi.org/10.1016/0003-2697(72)90451-4)

Ogawa-Akiyama, A., Sugiyama, H., Kitagawa, M., Tanaka, K., Kano, Y., Mise, K., Otaka, N., Tanabe, K., Morinaga, H., Kinomura, M., Uchida, H.A., Wada, J., 2020. Podocyte autophagy is associated with foot process effacement and proteinuria in patients with minimal change nephrotic syndrome. *PLoS One* 15, 1–15. <https://doi.org/10.1371/journal.pone.0228337>

Ohkawa, H., Ohishi, N., Yagi, K., 1979. Assay for lipid peroxides in animal tissues by thiobarbituric acid reaction. *Anal. Biochem.* 95, 351–358. [https://doi.org/10.1016/0003-2697\(79\)90738-3](https://doi.org/10.1016/0003-2697(79)90738-3)

Pereira, W. de F., Brito-Melo, G.E.A., Carneiro, C.M., Melo, D. de S., Costa, K.B., Guimarães, F.L.T., Rocha-Vieira, E., Vieira, É.L.M., Simões e Silva, A.C., 2015a. Increased Migratory and Activation Cell Markers of Peripheral Blood Lymphocytes in an Experimental Model of Nephrotic Syndrome. *Mediators Inflamm.* 2015, 209764. <https://doi.org/10.1155/2015/209764>

Pereira, W. de F., Brito-Melo, G.E.A., de Almeida, C.A.S., Moreira, L.L., Cordeiro, C.W., Carvalho, T.G.R., Mateo, E.C., Simões e Silva, A.C., 2015b. The experimental model of nephrotic syndrome induced by Doxorubicin in rodents: an update. *Inflamm. Res. Off. J. Eur. Histamine Res. Soc.*... [et al.] 64, 287–301. <https://doi.org/10.1007/s00011-015-0813-1>

Prandota, J. 2002. Furosemide: progress in understanding its diuretic, anti-inflammatory, and bronchodilating mechanism of action, and use in the treatment of respiratory tract diseases. *American journal of therapeutics*, v. 9, n. 4, p. 317–328.

Rocha-Gomes, A., Teixeira, A.E., de Oliveira, D.G., Santiago, C.M.O., da Silva, A.A., Riul, T.R., Lacerda, A.C.R., Mendonça, V.A., Rocha-Vieira, E., Leite, H.R., 2021. LPS tolerance prevents anxiety-like behavior and amygdala inflammation of high-fat-fed dams' adolescent offspring. *Behav. Brain Res.* 411, 113371. <https://doi.org/10.1016/j.bbr.2021.113371>

Rocha-Gomes, A., Teixeira, A.E., Santiago, C.M.O., Oliveira, D.G. de, Silva, A.A. da, Lacerda, A.C.R., Riul, T.R., Mendonça, V.A., Rocha-Vieira, E., Leite, H.R., 2022. Prenatal LPS exposure increases hippocampus IL-10 and prevents short-

- termmemory loss in the male adolescent offspring of high-fat diet fed dams. *Physiol.Behav.*243, 113628. <https://doi.org/10.1016/j.physbeh.2021.113628>
- Souto,M.F.O.,Teixeira,A.L.,Russo,R.C.,Penido,M.-G.M.G.,Silveira,K.D.,Teixeira, M.M., Simões E Silva, A.C., 2008.Immune Mediators in IdiopathicNephroticSyndrome:EvidenceforaRelationBetweenInterleukin8andProteinuria.*Pediatr.Res.*64,637–642.<https://doi.org/10.1203/PDR.0b013e318186ddb2>
- Stolfi, C., Troncone, E., Marafini, I., Monteleone, G., 2020. Role of TGF-Beta andSmad7inGutInflammation,FibrosisandCancer.*Biomolecules*11,17.<https://doi.org/10.3390/biom11010017>
- Suranyi, M.G, Guasch, A, Hall,B.M, Myers, B.D. Elevated levels of tumor necrosis factor-alpha in the nephrotic syndrome in humans*Am J Kidney Dis.* 1993 Mar;21(3):251-9.[https://doi:10.1016/s0272-6386\(12\)80742-6](https://doi:10.1016/s0272-6386(12)80742-6).
- Tapia,C.,Bashir,K.,2021.NephroticSyndrome.Treasure Island(FL).
- Teicher,B.A.,2021.TGFβ-DirectedTherapeutics:2020.*Pharmacol.Ther.*217, 107666. <https://doi.org/https://doi.org/10.1016/j.pharmthera.2020.107666>
- Troncoso, A. T. et al. Um Aspecto Fisiopatológico Da Síndrome Nefrótica. *Cadernos da Medicina - UNIFESO*, v. 1, n. 1, p. 66–74, 2018
- Varghese,R.,Majumdar,A.,2021.CurrentTherapiesinNephroticSyndrome:HDAC inhibitors,anEmergingTherapyforKidneyDiseases.*Curr.Res.Biotechnol.*3,182–194.<https://doi.org/https://doi.org/10.1016/j.crbiot.2021.05.007>
- Viborg, V.S; Henrik, B; Kok, J.S; Toft, S.H.; Dorothea, N; Fynbo, C.C, 2023.Twenty-four-Year Trends in Incidence and Mortality of Nephrotic Syndrome: A Population-Based Cohort Study. *Epidemiology* 34(3):p 411-420, doi: 10.1097/EDE.0000000000001576
- Wang,C.-S.,Greenbaum,L.A.,2019.NephroticSyndrome.*Pediatr.Clin.NorthAm.* 66,73–85.<https://doi.org/10.1016/j.pcl.2018.08.006>
- Wang,S.-N.,LAPAGE,J.,HIRSCHBERG,R.,2001.LossofTubularBone MorphogeneticProtein—7inDiabeticNephropathy.*J.Am.Soc.Nephrol.*12,2392LP – 2399. <https://doi.org/10.1681/ASN.V12112392>
- Watanabe, A., 2023. Patogênese genética-molecular da síndrome nefrótica córtico-resistente, síndrome nefrótica congênita e glomeruloesclerose segmentar e focal: realidade e contribuições da análise de uma população pediátrica brasileira. DoctoralThesis, Faculdade de Medicina, Universityof São Paulo, São Paulo. doi:10.11606/T.5.2023.tde-03052023-121121. Retrieved 2023-09-01, from www.teses.usp.br
- Xiang,C.,Yan,Y.,Zhang,D.,2021.Alleviationofthedoxorubicin-inducednephrotoxicitybyfasudilin vivoandin vitro.*J.Pharmacol.Sci.*145,6–

15.<https://doi.org/https://doi.org/10.1016/j.jphs.2020.10.002>

Yuengsrigul, A., Chin, T.W., Nussbaum, E., 1999. Immunosuppressive and cytotoxic effects of furosemide on human peripheral blood mononuclear cells. *Ann. Allergy, Asthma Immunol.* 83, 559–

566.<https://doi.org/https://doi.org/10.1016/S1081->

1206(10)62870-0

Zhao, J., Liu, Z., 2020. Treatment of nephrotic syndrome: going beyond immunosuppressive therapy. *Pediatr. Nephrol.* 35, 569–579.<https://doi.org/10.1007/s00467-019-04225-7>