

Case report

INTRAHEPATIC GALL BLADDER WITH CHOLEDOCHAL CYST WITH MALROTATION OF GUT – A RARE ASSOCIATION

Abstract

Choledochal Cysts are rare cystic dilatory conditions of the biliary tree with malignant tendency. These are more frequently reported in children. Surgical removal of these cysts can significantly reduce the risk of malignancy and also reduce the associated complications. However, Choledochal Cysts have been paid lesser attention in adults. Choledochal Cysts associated with Intrahepatic gall bladder and Malrotation of the gut have rarely been reported. We herein report a case of a 15-year-old female patient with Type 4a Choledochal cyst associated with intrahepatic gall bladder and mal-rotation of the intestine which was incidentally found at surgery. The patient underwent Excision of Choledochal cyst with Cholecystectomy with Appendicectomy with Hepatico-jejunostomy with Jejunio-jejunostomy, and Ladd's procedure was simultaneously performed for asymptomatic Intestinal Malrotation.

Keywords: Choledochal cyst, Intrahepatic gall bladder, Malrotation of the gut, Hepaticojejunostomy, Jejunio-jejunostomy, Ladd's procedure

Introduction: Choledochal cyst is a relatively rare bile duct abnormality, which is predominantly characterized by cystic dilatation of the biliary tract. There are five different types of CC as described in the Todani classification system [1,2], among which type 1 and 4 cysts are more prevalent in Asian populations [3]. There is a high rate of incidence of malignancy in choledochal cysts. The cancer risk increases significantly with age and is higher in those with type 1 and 4 cysts [3,4]. "Intestinal Malrotation(IM) is an important surgical disease and is well known to be incidentally associated with other surgical abdominal diseases" [5]. However, choledochal cysts associated with Intrahepatic gallbladder and IM have rarely been reported. We here present a case of a 15-year-old female patient with type 4a choledochal cyst, with incidentally found malrotation of the intestine and intrahepatic gallbladder, intraoperatively.

Case Presentation: A 15-year-old female patient presented with pain in the abdomen with on-and-off episodes of vomiting for 6 months. The pain was aggravated with heavy fatty meals. There was a history of similar complaints in the past, and the patient was managed conservatively at a local hospital. On examination, there was mild tenderness in the right hypochondrium, with no guarding, rigidity, or distension. On admission, the patient was stable vitally, with normal blood counts, normal liver enzymes, and serum electrolytes. Ultrasonography was suggestive of fusiform dilatation of CBD, left and right hepatic ducts. CECT abdomen and MRCP were done which were suggestive of "Fusiform dilatation of entire CBD with normal distal most CBD. Significant dilatation of right and left hepatic ducts with dilatation of intrahepatic biliary channels. Gall bladder well distended with 6mm. sized non-obstructive calculi with no changes of cholecystitis. (Fig 1,2,3)

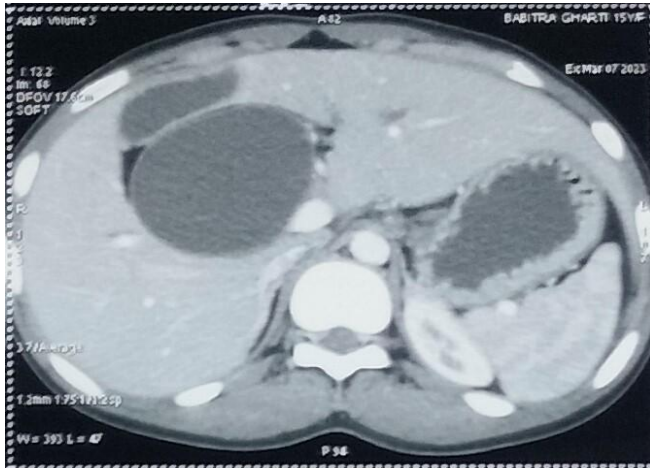


Fig 1: CECT transverse section showing choledochal cyst

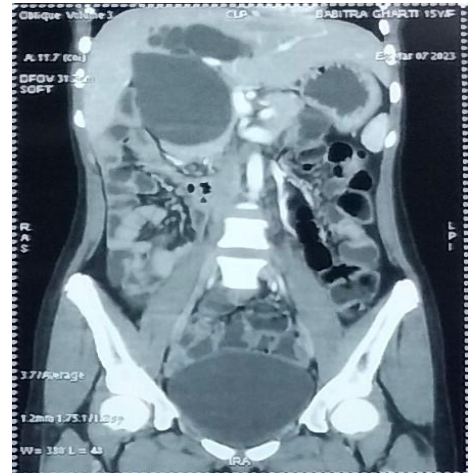


Fig 2: CECT sagittal section showing dilated intrahepatic and extrahepatic bile ducts

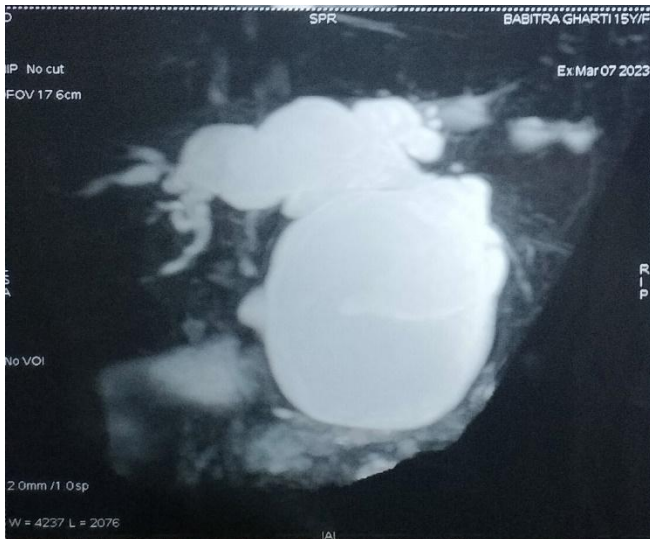

Fig 3: MRCP showing dilated intrahepatic and extrahepatic bile ducts

The patient was planned for OT and with Right subcostal incision "Excision of Choledochal cyst with Cholecystectomy with Appendicectomy with Hepatico-jejunostomy with Jejun-jejunostomy with Ladd's procedure for malrotation of the gut was done". The postoperative period was uneventful, and Ryle's tube was removed on POD-3, Sips orally was started on POD-7, and the patient was discharged with stable vitals on POD-10. On follow-up in OPD after 1 month, the patient was stable with no complaints.

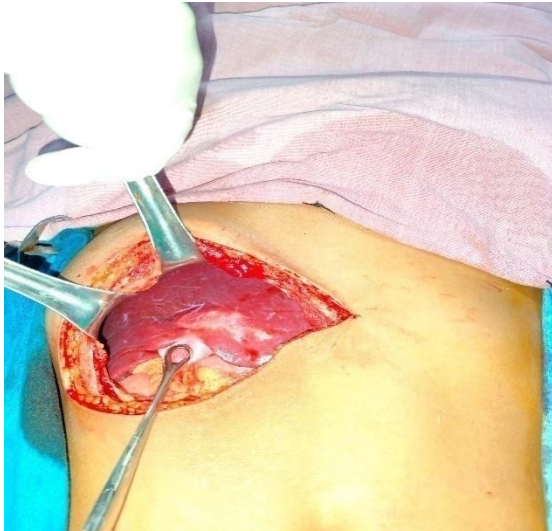


Fig 4: Intraoperative picture showing “Intrahepatic gall bladder”

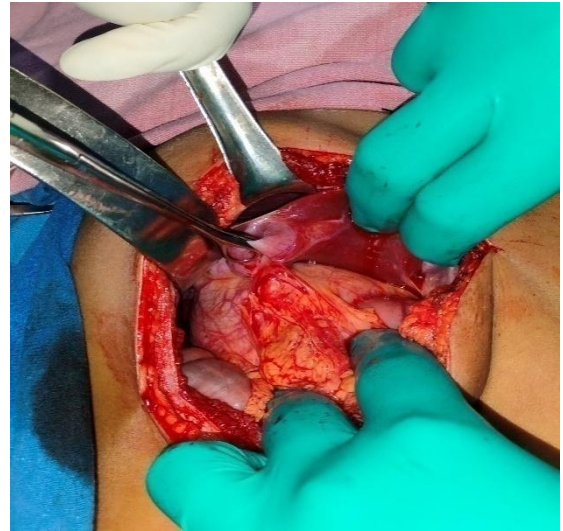


Fig 5: Intraoperative picture showing “Intrahepatic gall bladder”

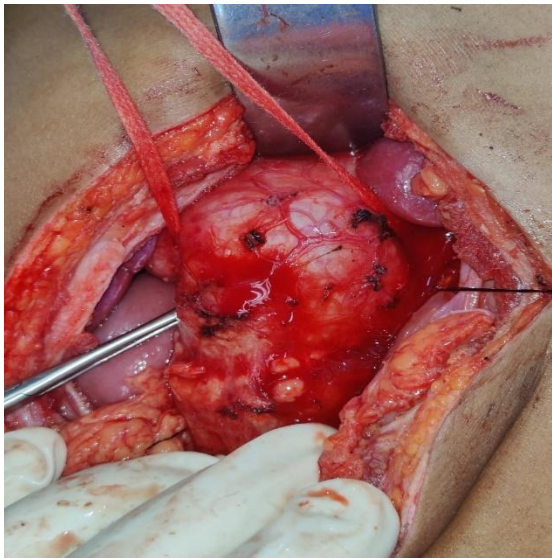


Fig 6:Choledochal cyst exposed

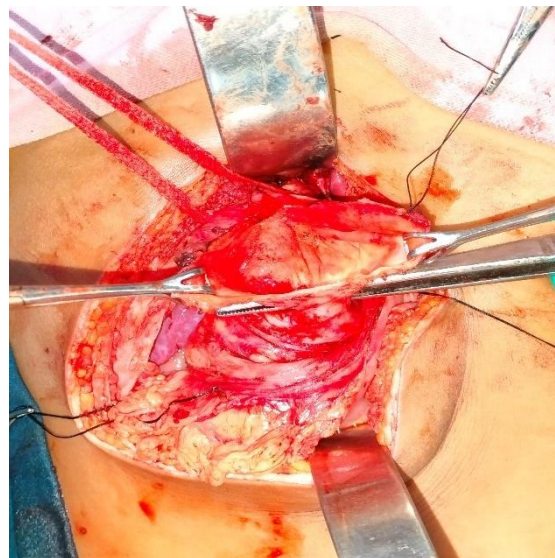


Fig 7: Opening of choledochal cyst

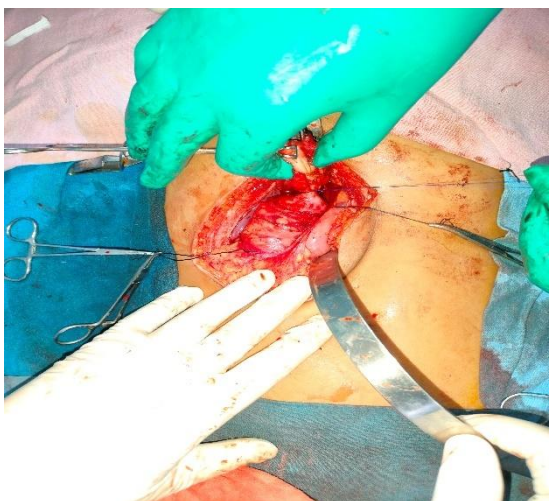


Fig 8: Excision of Choledochal cyst

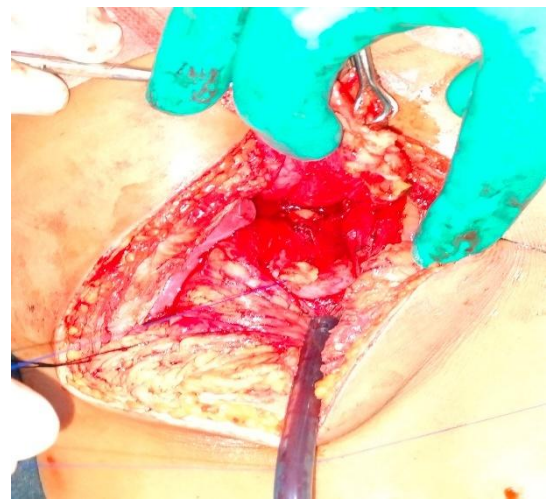


Fig 9: Intraoperative picture after excision of choledochal cyst

Discussion: "Choledochal cysts are focal or diffuse dilatations of the biliary tree. Choledochal cysts can occur as single or multiple cysts throughout the extrahepatic or intrahepatic bile ducts. The cysts can predispose patients to recurrent cholangitis or pancreatitis, choledocholithiasis, secondary biliary cirrhosis, biliary stricture, and malignancy. Approximately 80% of choledochal cysts are diagnosed in children and 20% of cases present in adults. There are a few case reports of choledochal cysts occurring within families, but generally, they do not have a recognized hereditary pattern" [8].

Todani and colleagues have classified the choledochal cysts into 5 categories based on anatomy. Traditionally, the classic and the most common choledochal cyst is the type I disease with cystic, saccular, or fusiform dilatation of the extrahepatic biliary tree. "Type II cysts are simple diverticula of the common bile duct, which are usually extrahepatic, supraduodenal, and saccular. A type III cyst, also known as choledochoceles, is a focal cystic dilatation of the most distal segment of the bile duct. Multiple dilatations of the intrahepatic and extrahepatic biliary tree are known as type IV cysts. Type V cyst, Caroli disease, is confined to the entire liver or a solitary lobe, usually on the left" [2,8].

"The most common proposed theory for choledochal cyst formation is related to pancreaticobiliary maljunction. Pancreaticobiliary maljunction is defined as an extramural junction of the pancreatic and biliary ducts in the duodenum beyond the intramural sphincter function and is characterized by a long common channel" [7,8]. "Pancreaticobiliary maljunction is also thought to be a significant risk factor for the development of cholangiocarcinoma in the biliary cyst, as well as the development of gallbladder cancer" [6,8].

Conclusion

The association of Intrahepatic gall bladder, Choledochal cyst, and Malrotation of the gut is very rare, and a high index of suspicion is needed while encountering any such congenital conditions, both intraoperatively and while preoperatively evaluating the patients. When such an association is incidentally encountered, we must carefully choose the surgical strategy for the excision of the CBD and consider the possibility of postoperative adhesive intestinal obstruction after Ladd's procedure.

Ethical Approval:

As per international standard or university standard written ethical approval has been collected and preserved by the author(s).

Consent

As per international standard, parental written consent has been collected and preserved by the author(s).

References:

1. Jianchun Xiao, Minting Chen, Tao Hong, Qiang Qu, Binglu Li, Wei Liu, Xiaodong He, "Surgical Management and Prognosis of Congenital Choledochal Cysts in Adults: A Single Asian Centre Cohort of 69 Cases", *Hindawi J. of Oncology*, vol. 2022, no. 9930710.
2. T. Todani, Y. Watanabe, A. Toki, and Y. Morotomi, "Classification of congenital biliary cystic disease: special reference to type 1c and 4a cysts with primary ductal stricture," *J. of Hepato-Biliary-Pancreatic Surgery*, vol. 10, no. 5, pp. 340-344, 2003.
3. G. N. Baison, M. M. Bonds, W. S. Helton, and R. A. Kozarek, "Choledochal cysts: similarities and differences between Asian and Western countries," *World J. of Gastroenterology*, vol. 25, no. 26, pp. 3334-3343, 2019.
4. K. Soreide and J. A. Soreide, "Bile duct cyst as a precursor to biliary tract cancer," *Annals of Surgical Oncology*, vol. 14, no. 3, pp. 1200-1211, 2007.

5. Takeshi Shirai, Yoshinori Hamada, Hiroshi Hamada, Tatsuma Sakaguchi, Takashi Doi, Mitsugu Sekimoto, "Congenital biliary dilatation associated with intestinal malrotation", *J. of Pediatric Surg Case Reports*, 53/101367, 2020.
6. *Maingots Abdominal Operations*, 13th edition, Michael J. Zinner, Stanley W. Ashley, O. Joe Hines, ISBN: 978-0-07-184429-1, MHID: 0-07-184429-5
7. Waiun Lei, Jiayu Yan, Tingchong Zhang, Lu Liu, Yajun Chen, Pancreaticobiliary maljunction and pancreas divisum accompanied with intestinal malrotation: a case report. *BMC Pediatr* 22, 110 (2022).
8. Do, R.K., Boll, D.T. (2023). Diseases, of the Gallbladder and the Biliary Tree. In: Hodler, J., Kubik-Huch, R.A., Roos, J.E., von Schulthess, G.K. (eds) *Diseases of the Abdomen and Pelvis 2023-2026*.
9. Noor Badrawi, Shaikh Sayeed Iqbal, Ayoub Ahmed, Usama Albastaki, "Intrahepatic gallbladder mimicking a cystic liver lesion *Radiology case reports*, Vol. 16, no. 9, pp. 2746-2748, 2021.