

Functional outcome of clavicular shaft fractures fixation by clavicular lockingplate in adults

ABSTRACT

Background and Aim: The clavicular fracture is one of the most frequent bone fractures in people. It is typically treated non-surgically. The goal of the current study was to assess the features of surgical treatment of recently dislocated clavicular fractures using compression plates and screws.

Methods: This prospective study was conducted at the Department of Orthopedic Surgery and Therapeutics, Popular Medical College and Hospital, Dhaka during November 2020 to June 2022. The study included a total of 20 patients with midline fractures of the clavicle; 14 of them were men and 06 were women, with an average age of 33.35 years. Then, plate fixation was used to treat every case. Following surgery, patients were followed up at 1.5, 3, and 6 months. Clinical and radiological evaluations were performed during the observation period.

Results: Of the 20 clavicle fracture patients, who had plate fixation, 15 patients (75%) showed excellent outcomes whereas 5 patients (25%) had good functional outcomes. The typical radiological union took 10.21 weeks to complete.

Conclusion: In terms of pain alleviation, daily activities, and range of motion, plate fixation of clavicle fractures produces better functional results.

Keywords: Functional outcome, clavicular shaft fractures, fixation, clavicular compression locking plate

INTRODUCTION

The clavicle, the S-shaped neck bone that connects the upper part of the body to the trunk and keeps it in line, is crucial to the movement and integrity of the upper part of the body. Clavicle fractures, which account for 5% of all bone fractures and 44% of all shoulder fractures, are common injuries in adults.¹ Most bone fractures are caused by a direct impact on the shoulder or a fall on an outstretched arm. More than two-thirds of these injuries in adults occur at the level of the diaphysis, and the probability for displacement is higher than the fracture of the medial and lateral thirds.² Fractures of the clavicle are typically treated conservatively, with documented non-union rates of less than 1%. But there is growing evidence suggest that non-surgical management of displaced clavicle fractures results in an increased risk of non-union and also in the reduction in the flexibility and endurance of the shoulder muscles. On the other hand, the surgical repair of fractured clavicle has yielded positive outcomes involving substantial union rates and minimal complication rates of displaced clavicle fractures. Due to decreased incidences of non-union and higher patient satisfaction, it is now recommended that surgical intervention for these fractures should be regarded as the first choice.³ Clavicle fractures can be treated surgically using either open reduction with plate fixation or open or closed reduction with intramedullary nail placement. Specially in badly dislocated or shattered bones, plate fixation can aid in achieving a significant anatomic reduction. These two operative strategies outperform conservative management, as demonstrated by various studies. Compression of the brachial plexus, compression or laceration of the major arteries, trachea, or esophagus, damage to the neurovascular bundle and the pleural dome, poor physical appearance, and pneumothorax are all connected with a delayed or non-union of the clavicle.⁴ Therefore, the current study's objective was to examine surgical therapy and evaluate its functional results in newly dislocated clavicular fractures.

METHODOLOGY

This prospective study was conducted at the Popular Medical College and Hospital's Department of Orthopedic surgery and Therapeutics from November 2020 to June 2022. Adult male and female patients within the age group of 18-60 years with displaced clavicle fractures were included in this study. Patients with open fractures, pathological fractures, associated head injuries, neurovascular injuries, acromioclavicular joint dislocation, specified non-union from prior fracture, any medical conditions that could hinder surgery or general anesthesia (heart conditions, renal failure, active chemotherapy), and patients who refused to consent to surgery were excluded from this study.

Preoperative management: After receiving the patients at Emergency Department; the name, age, sex, occupation, and address were recorded as general information. Then, information about the manner of injury, such as a fall onto the shoulder, a road traffic accident, a direct injury to the shoulder, and a fall onto an outstretched hand, was retrieved. Family history and previous medical conditions were also noted. The patients' physical condition, including their bloodpressure, pulse, and respiratory rate was assessed. The cardiovascular and respiratory systems were checked for

any abnormalities. The affected extremities underwent another thorough examination, which was followed by a local examination and a radiological evaluation. A clavicle brace and arm sling were used to immobilize the injured limb, and the patient was screened during pre-operative check-up before the surgical management.

Surgical Procedure: A sand bag was positioned between the medial border of the ipsilateral scapula and the spine while the patient was kept in a supine or propped up (45 degree) position. The entire upper limb was prepared and draped, from the neck's base to the hand. A 7 to 10 cm incision that centered the clavicle over the fracture was made. Through the platysma, the skin incision was widened to reach the clavicle's subcutaneous boundary. Next, the periosteum and fascia overlaying it were separated. The superior aspect of the clavicle was covered with a plate after the fracture pieces were reduced. The inferior surface of the clavicle is revealed where the medial & middle thirds connect, allowing for the insertion of a safety tool during drilling to guard against damage to the neurovascular structure beneath. With locking screws or cortical screws, the locking compression plate was fastened to the medial and lateral fragments, with at least three screws being used in each. After rigorous hemostasis and sterile dressing were used, the wound was closed in layers.

Postoperative management: An elbow bag was used to immobilize the patient following surgery. After that, an additional X-ray was taken to confirm fixation and alignment. The following day, the patient was released. In the initial phase, gentle pendulum workouts were permitted for up to two weeks. Active range of motion of the afflicted shoulder was advised for 4 to 6 weeks, although overhead abduction was not allowed. Active range of motion in all planes is permitted between 6 and 8 weeks. Every four weeks for the first three months and once after six months, patients were routinely followed up with.

On each subsequent visit, a clinical and radiographic evaluation of the fracture was conducted in order to check union, implant and to detect complications. According to the stages of fracture and time since surgery, the injured extremity underwent rehabilitation. Patients were evaluated every six months. We employed the constant Murley score developed by Murley to assess the functional result.⁵

Data Analysis: The study's data were all entered into Microsoft Excel (version 2013). Following the export of the data into SPSS version 20, statistical analysis was performed. Continuous data are given as means with their standard deviation, and categorical variables were described in terms of frequencies and percentages.

RESULTS

The study comprised 20 individuals with recent clavicular fractures in total. All of the patients received surgical treatment using locking plates and screws, and they all attended the outpatient department (OPD) for follow-up visits. There were scheduled interval follow-up visits for the following six weeks. The results were evaluated both clinically and radiologically. The mean age was 33.35 ± 10.07 years ranging from 19 to 59 years. Among the study population, 14 (70%) were male and 06 (30%) were female. The majority of the study population (60%) suffered injuries from road traffic accidents (RTA). In this study, every patient obtained union of the bones. The mean clinical union was found during 8.45 ± 2.17 weeks in the study population (95% CI- 7.43 to 9.47) and the mean radiological union was observed during 10.21 ± 1.93 weeks in the study population (95% CI- 9.31 to 11.11). In the study population, the mean overall Murley Score was 92.63 ± 7.15 ; the lowest level was 68, and the highest level was 100. The majority of trial participants got outstanding results (Table 3). In this study of all patients, 2 (10%) experienced postoperative stiffness. On the first day following surgery, all patients were instructed how to execute self-assisted circumduction exercises and pendulum exercises, however some patients were non-compliant, and two of them had stiffness. Both of these individuals responded well to the physiotherapy we performed on them. No patients reported any acromioclavicular joint pain following implant removal. We did not discover any other postoperative issues, such as an acromial fracture or infection, except from shoulder discomfort.

Table-1: Distribution of patients according to age and sex.

Characteristics	No. of affected patients
Sex	
Female	06 (30%)
Male	14 (70%)
Total	20
Age (in years)	
18-29	07 (35%)
30-39	08 (40%)
40-49	03 (15%)

50-60	02 (10%)
Total	20
Mean Age (years)	33.35± 10.07

Table-2: Summary of Injury Patterns of Study Population (n=20).

Injury Mode	No. of affected patients
Fall from height/vehicles	03 (15%)
Road traffic accident	09 (60%)
Sports accident	02 (10%)
Outstretched hand fracture	06 (30%)
Total	20

Table-3: Analysis of Murley's score in the study population (n=20).

Total score	Frequency	Percentage
Good	5	25%
Excellent	15	75%

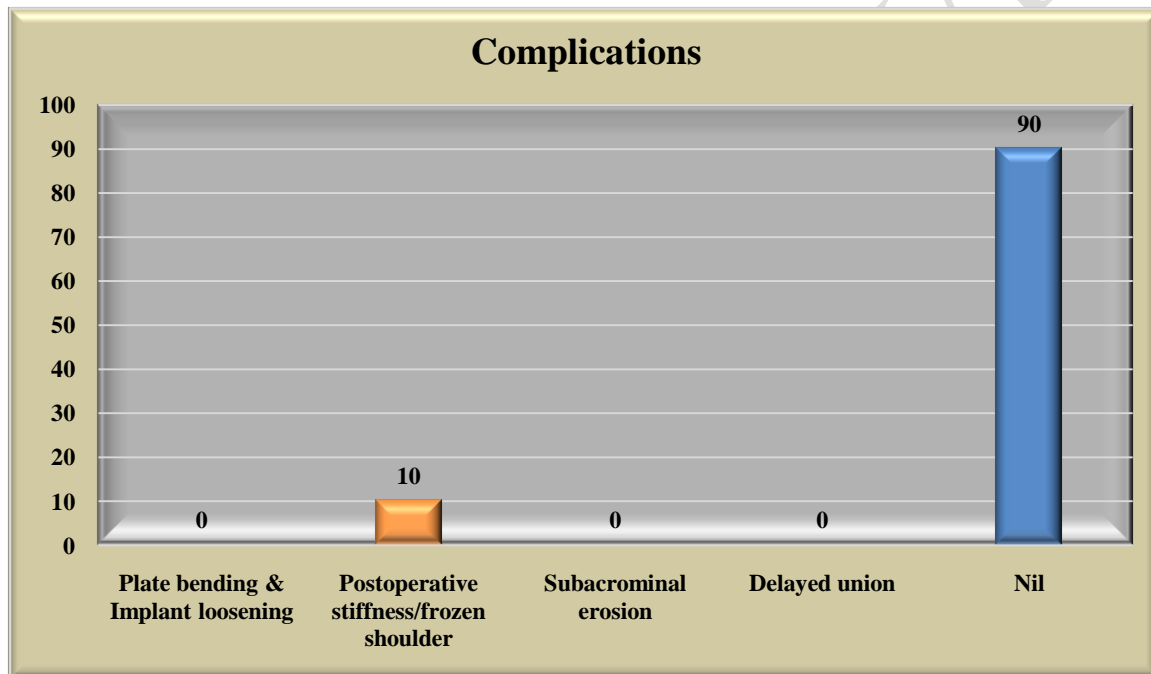


Figure 1: Complications in the study population (n=20).

DISCUSSION

Clavicle fracture is an increasingly prevalent injury around the shoulder joint. Due to increasing road traffic accidents and sports activities, the frequency of clavicle fractures is rising day by day. The mainstay of clavicle fracture treatment for a very long time was conservative management. According to several recent researches, non-operative therapy is less effective in producing the best results; specially in young populations. This study's objectives were to assess the clinical results of displaced clavicle fractures treated with open reduction and internal fixation using a clavicle hook plate. The findings of this study demonstrate positive clinical and radiologic outcomes following surgery. In this study, the population had a mean age of 33.35±10.07 years, with a minimum age of 19 and a maximum age of 60 years. In a different study by Ebrahim et al., patients' ages ranged from 19 to 59 years, with an average age of 37.37 years.⁶ In this study, sample size was made up of 14 (70%) men and 6 (30%) women in contrast to Böstman et al.'s study, which included 76 male patients (73.79%) and 27 female patients (26.21%).⁷ The study population's mean radiological union during our investigation was 10.21±1.93 weeks. According to the study done by Lazarus, radiological union was found between 6 and 12 weeks.⁸ In another study conducted by Cho et al. reported that the bone union time for locking compression plates was 13.2 weeks and 14.6 weeks for reconstruction plates.⁹ In this study, 2 individuals (10%) experienced shoulder discomfort following surgery, which went away with physiotherapy. As a

postoperative complication, plate bending and implant loosening were found in 3 (5.9%) patients and 4 (7.8%) patients, respectively, according to the study by Ebrahim et al.⁶ In a related investigation, Nayak and Khandelwal discovered that 2 patients (10%) experienced delayed union due to a dislocated butterfly fragment which, after 16 weeks, fused with the main fragment.¹⁰ In our study population, the mean total Murley score was 92.63 ± 7.15 , which was remarkably comparable to the study by Ebrahim et al., who discovered a mean score of 94.24 ± 6.32 in their study population.⁶ In a different study, Good et al. found that the mean constant score for all patients was 83.8, indicating that the majority of patients had excellent results. In their study, the best outcomes (mean constant score of 98) were obtained when the hook plate is removed immediately before 6 months.¹¹ In a similar study by Verborgt et al. found 23 patients (76.6%) had excellent functional outcomes, 5 patients (16.6%) had good functional outcomes, and 2 patients (6.6%) had fair functional outcomes.¹²

CONCLUSION

Our research demonstrates that ORIF with the clavicular compression locking plate is an effective treatment for displaced clavicular fractures. Young males who experience high energy trauma are more likely to develop clavicle fractures, and those fractures that undergo plate fixation have superior functional outcomes in terms of discomfort alleviation, routine tasks, and flexibility in movement.

Ethical Approval:

As per international standard or university standard written ethical approval has been collected and preserved by the author(s).

Consent

As per international standard or university standard, patient(s) written consent has been collected and preserved by the author(s).

REFERENCES

1. Toogood P, Horst P, Samagh S, Feeley BT. Clavicle fractures: a review of the literature and update on treatment. *Phys Sportsmed*. 2011;39(3):142-50
2. Boehme D, Curtis RJ Jr, DeHaan JT. Nonunion of fractures of the mid-shaft of the clavicle: treatment with a modified Haigie intramedullary pin and autogenous bone- grafting. *J Bone Joint Surg Am*. 1991;73(8):1219-26.
3. Robinson CM, Court-Brown CM, McQueen MM, Wakefield AE. Estimating the risk of nonunion following nonoperative treatment of a clavicular fracture. *J Bone Joint Surg Am*. 2004;86(7):1359-65.
4. Mosley HF. The Clavicle: its anatomy and function. *Clin Orthop*. 1968;58:17-27.
5. Yian EH, Ramappa AJ, Arneberg O. The Constant Shoulder Score. *J Shoulder Elbow Surg*. 2005;14:128-33.
6. Ebrahim J, Variyathodi AA, Mohamed Shakeeb Kannan Thody Uppil Thody, Chandrasekharan N. Functional outcome of displaced mid shaft clavicular fractures treated by plate fixation: A prospective observational study. *International Journal of Research in Orthopaedics*. 2021;7(5):996-1000.
7. Böstman O, Manninen M, Pihlajamäki H. et al. Complications of plate fixation in fresh displaced midclavicular fractures. *J Trauma*. 1997 Nov;43(5):778-83.
8. Lazarus MD. Fracture of clavicle. In: *Journal of shoulder and elbow surgery*. 15(2):191-4
9. Cho CH, Song KS, Min BW, Bae KM, Lee KJ. Reconstruction Plate Versus Reconstruction Locking Compression Plate for Clavicle Fractures. *Clinics in Orthopedic Surg*. 2010;2:154-9
10. Nayak A.J., Khandelwal M. Management of midshaft clavicular fracture with help of locking plates: a prospective study. *Surgical Update: Int J surg Orthopedics*. 2019;5(2):74- 79.doi:10.17511/ ijoso. 2019.i2.02.
11. Good DW, Lui DF, Leonard M, Morris S, McElwain JP. Clavicle hook plate fixation for displaced lateral-third clavicle fractures (Neer type II): a functional outcome study. *Journal of shoulder and elbow surgery*. 2012 Aug 1;21(8):1045-8.
12. Verborgt O, Pittoors K, Van Glabbeek F, Declercq G, Nuyts R, Somville J. Plate fixation of middle-third fractures of the clavicle in the semi-professional athlete. *Acta Orthop Belg*. 2005 Feb 1;71(1):17-21.