

## **CASE REPORT**

### **BILATERAL UPPER LIMB AMELIA IN A NEONATE IN NORTH-WESTERN NIGERIA: CASE REPORT AND REVIEW OF LITERATURE**

**Abstract:** Amelia affects approximately 0.05 to 0.09 out of every 10,000 newborn babies. The complete absence of a limb may occur in isolation or as a part of multiple congenital malformations. The condition is uncommon and very little is known with certainty about the etiology, It could also be sporadic and can be caused by teratogens such as thalidomide, alcohol, vascular compromise by amniotic bands and maternal diabetes mellitus. Amelia's genesis has also been linked to various types of heredity.

We report a term female neonate delivered by a healthy 30-year-old primipara in North-Western Nigeria, with the two upper limbs completely missing at birth, other parts of the body were essentially normal. The maternal history revealed no known identifiable risk factor for Amelia. We are reporting this case because of the rarity of this congenital defect.

**Keywords:** Bilateral, upper limb, Amelia, North-western

#### **Introduction**

The complete absence of a limb may occur in isolation or as a part of multiple congenital malformations [1]. Amelia affects approximately 0.05 to 0.09 out of every 10,000 newborn babies [2], while the prevalence of stillbirth is 1.41 in 100,000 [3]. The condition occurs due to the interruption of the development of

limb buds between 24 and 36<sup>th</sup> days of fertilization [4]. Amelia is uncommon and very little is known with certainty about the etiology. It could be sporadic [2] and can also be caused by teratogens such as thalidomide, alcohol, vascular compromise by amniotic bands and maternal diabetes [5]. Amelia's genesis has also been related to various types of heredity, including the autosomal dominant, autosomal recessive, and X-linked dominant modes of inheritance, indicating this condition's genetic heterogeneity [6]. In most cases, even though the etiology remains unidentified, a defect in the WNT3 gene located at 17q21 which regulates the development of limbs and other organs can lead to this anomaly [7]. Abnormalities associated with Amelia include severe defects of the lungs, vertebrae, heart, internal and external genital system, and anus [8].

We are reporting this case because of the rarity of this congenital defect. There is a paucity of data on Amelia probably due to underreporting, under registration of birth defects and because of most pregnancies with Amelia end up as stillbirth [3].

## **Case report**

### **Patient history**

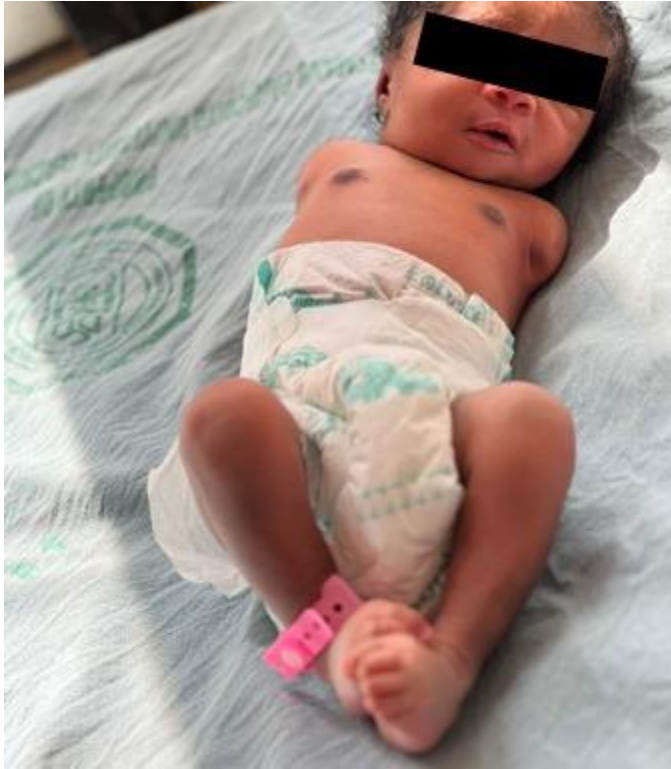The baby was a term female neonate, the first child of a 30-year-old healthy primipara and 36 years old father. The pregnancy was desired and spontaneously conceived, booked in our tertiary health facility at 3 months of gestation, pregnancy was uneventful and the mother was regular with ANC visits, she had IPT for malaria, tetanus toxoid, folic acid and folate during pregnancy. The mother had 3 antenatal scans, one scan each in the first, second and third trimester of pregnancy that revealed no fetal abnormality. The mother however ingested un-prescribed ibuprofen bought from a chemist when she had a fever in the first

trimester of pregnancy. No maternal history of cigarette smoking, consumption of alcohol, or any known teratogenic drug or traditional medicine during pregnancy, nor was she exposed to radiation during the first trimester of pregnancy. The mother was not diabetic, had no history of chronic drug use during pregnancy and had no prenatal invasive procedure. The mother was negative for Hepatitis B and human immune-deficiency virus. There was no history of maternal febrile illness, trauma to the abdomen or vaginal bleeding during pregnancy, and no family history of similar illness or consanguinity in the parents. Delivery was via EMLS CS due to failed induction of labour, post-dates and fetal distress. The baby cried immediately after birth, and APGAR scores were 7 and 9 at 1 and 5 minutes respectively. Meconium was passed within an hour of delivery.

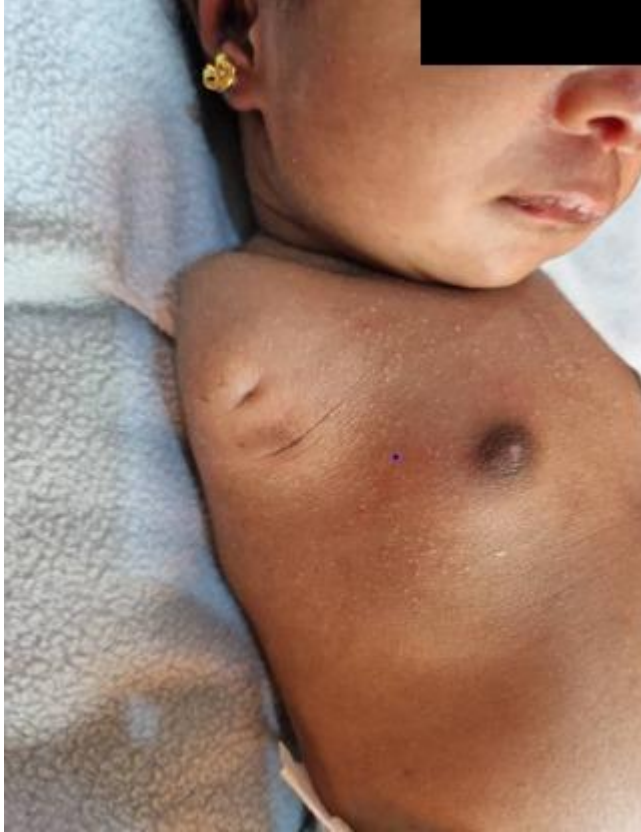Both parents had tertiary level of education and are secondary school teachers in a private school; the family's monthly income is N50,000.

### **Clinical findings**

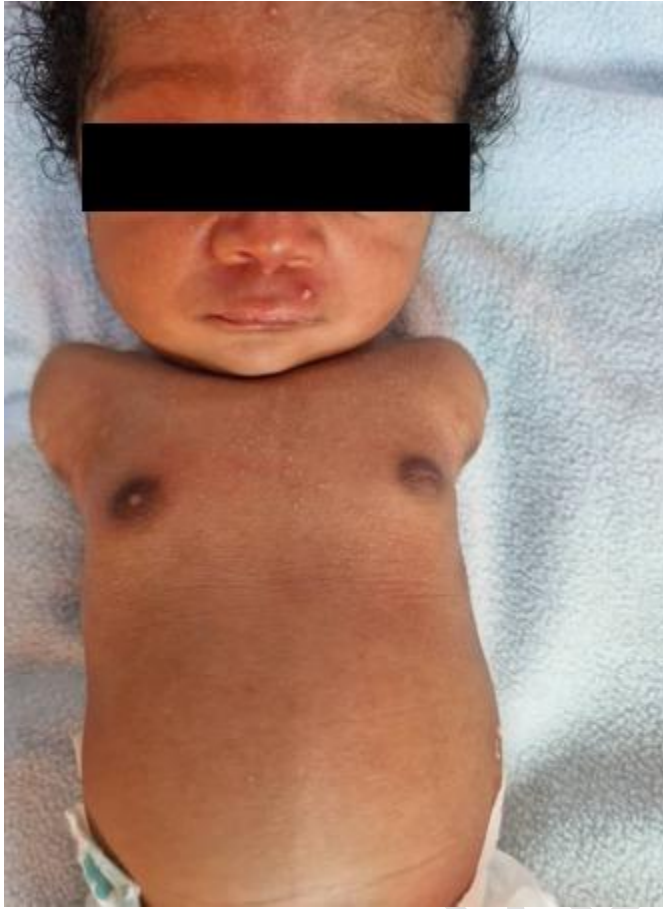Examination findings revealed a neonate that is not in respiratory distress, with no cardiac murmur or dysmorphic features. The weight, Length and occipitofrontal circumference were 2.3 kg, 47.5cm and 35cm respectively. The neonate was otherwise healthy-looking except for the two upper limbs that were completely missing with a dimpling in both armpits noticed at birth, with normal lower limbs and female external genitalia, there were no other gross abnormalities on examination.



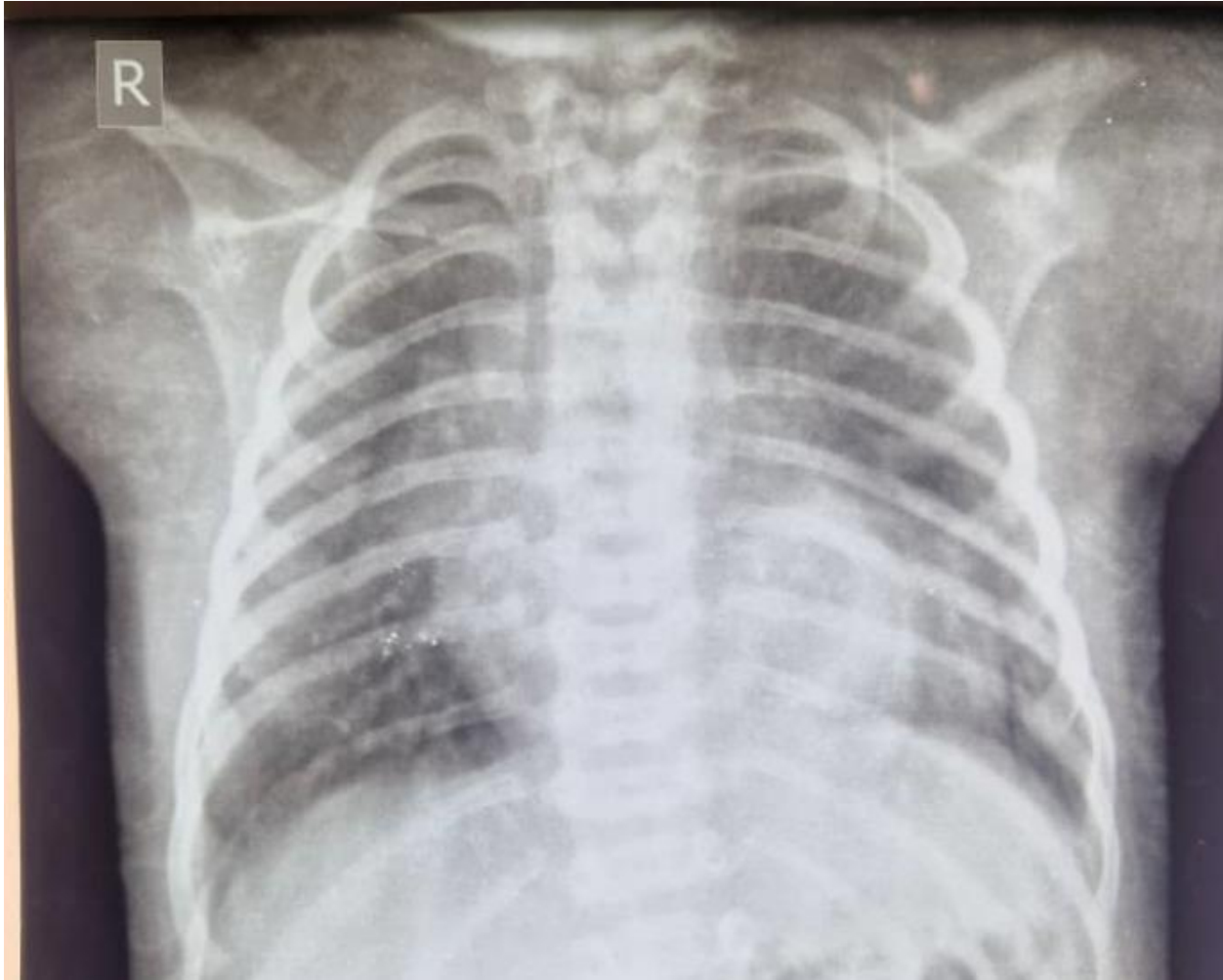
**Figure 1: Clinical image of the neonate showing complete absence of both upper limbs and normal lower limbs**



**Figure 2: Clinical image showing the complete absence of both upper limbs and a dimple in the right armpit**



**Figure 3: Clinical image of the neonate showing complete absence of both upper limbs**



**Figure 4: X-ray of the chest and both shoulders showing bilateral upper limb Amelia**

The abdominal ultrasound and Echocardiography revealed normal findings.

The neonate had uneventful nursery care for evaluation and was discharged on day five after delivery, while the baby was on admission the parents were unwilling to see the baby and were also very worried about the deformity of their child and afraid of the child being stigmatized.

The parents had several counselling sessions and were also advised to continue with follow-up visits with the paediatricians, orthopaedic surgeon and social welfare. The neonate was referred to an orthopaedic surgeon in view of the need for prostheses as the child develops.

## **Discussion**

There are few case reports on Amelia in Nigeria; Benjamin et al [1] in Zaria, Nigeria reported the absence of the upper left arm and forearm, a fusion of both big and middle toes and the absence of the entire small toe on the left foot. In a 12-week-old male child delivered by a 26-year-old mother with associated unilateral left cleft lip and palate. Also, Dalvi et al [2] in Nagpur, India, reported a complete absence of the right lower limb and the left lower limb was hypoplastic and bilateral renal agenesis, absence of both anus and genitalia in an abortus, delivered by a 30-year-old mother in good health, with no consanguinity or significant family history.

In IR Iran Eghbalian et al [5] reported a male neonate with the right arm completely missing with a cherry-sized skin bulging on the lateral end of the right clavicle and imperforate anus, the first child of a 22-year-old father and 26-year-old mother. Pakkasjarvi et al [9] in Finland reported a total of 30 cases of amelia and phocomelia, of which 23 had amelia, and 7 were cases of phocomelia. Of the 23 patients with amelia, 10 were boys and 10 were girls, and the gender was unknown in three cases. Thalidomide was not an etiological factor in any of the cases. In Pakkasjarvi et al [9] report, amelia affected the lower limbs in 70% of the case, 69% of the patient with amelia associated with urinary tract abnormality, 63% with axial skeletal abnormality, 56% with abdominal wall defect, 56% sexual

differentiation abnormality, 50% with gastrointestinal abnormalities. Unlike in their reports [1, 2, 5, 9], our patient had no other associated abnormality.

It is worthy of note that in most of the reports [1,3,5,9] and ours the mothers were observed to be young. The reason why the condition is commoner in children of young mothers is not known. Risk factors for amelia and studies remain mostly uncharacterized [9]. Also in some of the reports [1, 5] the neonates were males, this is in not in tandem with our report that is a female, while another study [9] reported equal gender predilection.

Singhal et al [10] reported bilateral upper limb Amelia in a male neonate whose mother was on Anti-tuberculous drugs but however ingested herbal medication in the first trimester of pregnancy due to a desire of having a male child, this is unlike our report in which there is no identifiable risk factor.

Similarly, Ohro et al [11] reported a 46 XY phenotypic female infant with an absent uterus and bilateral upper amelia. This is in agreement with our report except for the absence of other abnormalities as seen in their patient.

In our report the neonate had a congenital deficiency of both upper limbs, this corroborates the finding of a multicenter study that observed that the upper limbs were more involved than the lower limbs [3], but in contrast to the finding of Pakkasjarvi et al [9] that reported that the lower limbs were commonly affected than the upper limbs.

In this index case, the mother had three antenatal scans, one scan each in the first, second and third trimester of pregnancy that revealed no fetal abnormality. Likewise, Richmand et al [12] reported that 3 out of 4 cases of amelia were not diagnosed inutero.

The parents of this neonate were unwilling to see their baby while on admission in the neonatal unit for the first few days due to fear and guilt, a sense of loss and denial. When a child is born with congenital limb deficiency it affects not only the child, but also the parents, family and friends, parents experience grief with the birth of a child with any deformity [13]. Hence parents need support and guidance from health care providers.

One huge challenge in this patient with bilateral upper limb Amelia is the accessibility and cost of a prosthesis that is as functional and cosmetically pleasing as possible in a resource constraint setting like ours and also having indigent parents. The functional use of prostheses is a skill which many amputees do not have the patience, intelligence, or motivation to learn [1]. However, this child is yet to be fitted prosthesis for Amelia. However, we believe that when fitted at the appropriate age it will help the child's body image and may be essential for normal neuromuscular function and development.

## **Conclusions**

Our patient had a sporadic form of Amelia. Further studies are necessary to find out the exact aetiology and risk factors of Amelia. Antenatal screening, karyotyping analysis, and genetic counselling are recommended to reduce the risk of such congenital anomalies.

## **Ethical Approval:**

As per international standard or university standard written ethical approval has been collected and preserved by the author(s).

## consent

Consent was obtained from the parents to publish the images and other clinical information of the patient.

## References

1. Benjamin F, Adebayo ET, Mohammed R, Adekeye EO. Facial cleft with Amelia: A Nigerian case report. *Ann Afr Med* 2013; 12:49-52
2. Dalvi V, Dhok A, Onkar P, Mitra K, Ladke P. Fetal Amelia With Hypoplastic Tibia and Terminal Fibular Hemimelia: A Case Report With Review of the Literature. *Cureus* 2022; 14(12): e32849.
3. Bermejo-SE, Cuevas L, Amar E, Bakker MK, Bianca S, Bianchi F, Canfield MA, Castilla EE, Clementi M, Cocchi G, Feldkamp ML, Landau D, Leoncini E, Li Z, Lowry RB, Mastroiacovo P, Mutchinick OM, Rissmann A, Ritvanen A, Scarano G, Siffel C, Szabova E, Martínez-Frías ML. Amelia: a multi-center descriptive epidemiologic study in a large dataset from the International Clearinghouse for Birth Defects Surveillance and Research, and overview of the literature. *Am J Med Genet C Semin Med Genet*. 2011; 15; 157C (4):288-304.
4. Gupta S, Soni RK, Agrawal V, Agrawal P, Garg P. As rare hen's teeth tetra – amelia syndrome. *J Clin Neonatol* 2017; 6: 103-5

5. Eghbalian F, Sharif A, Monsef A R. Amelia: A Case Report and Literature Review. *Iran J Pediatr.* 2015; 25(6):e4114.
6. Morey MA, Higgins RR: Ectro-amelia syndrome associated with an interstitial deletion of 7q. *Am J Med Genet.* 1990, 35:95-9
7. Niemann S, Zhao C, Pascu F, Stahl U, Aulepp U, Niswander L, *et al.* Homozygous WNT3 mutation causes tetra-amelia in a large consanguineous family. *Am J Hum Genet* 2004; 74:558-63.
8. Sousa SB, Pina R, Ramos L, Pereira N, Krahn M, Borozdin W, *et al.* Tetra-amelia and lung hypo/aplasia syndrome: new case report and review. *Am J Med Genet A.* 2008; 146A (21): 2799 -803
9. Pakkasjarvi N, Syvaney J, Wiros, MK, Virta, E. Amelia & Phocomelia in Finland: Characteristics and prevalence in a nation-wide population –based study. *Birth defects Research, Wiley Online Library.* 2022;114(20)-1427-1433.
10. Singhal SR, Agrawal U, Sharma D. Outcome of gender bias: Isolated bilateral upper limb Amelia. *The Journal of Obstetrics and Gynecology of India.* 2011; 61:441-2
11. Ohro YI, Suzuki Y, Tsutsumi Y, Ogata T. Female external genitalia, absent uterus, and probable gonadism in a 46, XY infant with bilateral upper amelia. *Clinical genetics* 1998; 54(1):52-5.
12. Richmond S, Atkins JA, Population based study of the prenatal diagnosis of congenital malformation over 16 years. *BJOG* 2005; 112(10):1349-1357.

13. Quinn M, Mahat G. congenital Upper Limb Deficiency: A case Report. Contemp Ped J 2019;36(3).

UNDER PEER REVIEW