

## *Original Research Article*

# **COMPARISON OF PREVALENCE OF OXIS CONTACT IN PRIMARY MAXILLARY AND MANDIBULAR TEETH: A RETROSPECTIVE COHORT STUDY**

### **ABSTRACT**

#### **AIM**

The purpose of the present study was to evaluate four different types of OXIS contact areas (open [O], point [X], straight [I], and curved [S]) in primary teeth using cone beam computed tomography (CBCT) among 3- to 9-year-old children.

#### **METHODS**

A retrospective cohort study was performed using cone-beam computed tomography images of children, available from January 1, 2022, to July 31, 2023 in Mathura district showing the presence of caries-free contact area between primary right maxillary and mandibular 1<sup>st</sup> and 2<sup>nd</sup> molar. In this study, 65 selected contacts using OXIS criteria from the occluso-cervical and axial view at coronal level using CBCT.

#### **RESULT**

Based on the shapes observed, the results showed four distinct types of contact regions between the primary molars, namely, O type, X type, I type, and S type; hence, the suggested categorization is known as OXIS. I type was the most prevalent pattern in the maxilla (47.06%), while O type was the most prevalent pattern in the mandible (50%).

## CONCLUSION

There are four types of intact interproximal contact areas between primary molars, which can be evaluated in three dimensions. These types are O, X, I and S. In maxilla, pattern was I > O > X > S whereas in mandible pattern was O > X > I = S.

Keywords: OXIS contact, Primary Maxillary, Mandibular Teeth, Retrospective Cohort

## INTRODUCTION

The proximal heights of the contour on the mesial and distal surfaces of the tooth are referred to as the "contact area" in this context.<sup>1</sup> "For the preservation of the stability and integrity of the dental arches and the health of the supporting tissues, the anatomical and morphologic configurations of a tooth, notably a broad, flat proximal contact area, are essential".<sup>2</sup> It might be difficult to diagnose caries in the vicinity until apparent cavitation symptoms appear. Compared to the contact sites between permanent molars, primary molar contact regions are wider, flatter, and more gingivally positioned<sup>1</sup>. "Basically, the wider proximal contact areas seen in primary teeth are believed to enhance caries susceptibility, since the restricted mobility would impede the self-cleansing activity, resulting in more plaque formation"<sup>1</sup>.

"Contact areas can be open and close type. Studies which were done previously concluded that the risk for proximal caries in the posterior primary dentition is increased if contact points are closed rather than open"<sup>1-2</sup>. It is sense to think that lack of interdental space or tight contacts might increase a child's risk of developing caries since these conditions can result in food and plaque impaction, microbial colonization, and the subsequent formation of carious lesions<sup>3-4</sup>. One recent longitudinal study identified "four approximate variants: (1) concave-concave; (2) concave-convex; (3) convex-concave; and (4) convex-convex"<sup>5</sup>. This study evaluated "the predictive value of the morphology of the distal surface of primary first molars and the mesial surface of primary second molars for the development of caries in young children. The morphology of approximal surfaces in primary molar teeth, particularly when both surfaces were concave, significantly influenced the risk of caries development in future"<sup>5</sup>.

A Cross-sectional research (2018) that looked at "the types of interproximal contact areas of primary molars identified four different types of contact areas: open (O), point (X), straight (I), and curved (S). Hence, the OXIS classification was proposed" (Kritiga M. et al.)<sup>1</sup>. Subsequently, several studies have used "the OXIS classification to evaluate the contact types of

primary molars and the role of OXIS contacts is significant to an understanding of the mechanism of proximal caries”<sup>4-5</sup>.

“Cone-beam CT is an exciting new addition to the imaging armamentarium which has the potential to transform practically all aspects of dental imaging. The field of view (FOV) options offered by CBCT allow dentists to target a specific region of interest while minimizing exposure to adjacent tissues. This reduces the radiation dosage dramatically”<sup>6-7</sup>. Accuracy is another advantage of CBCT, it has higher resolution than traditional computed tomography scans<sup>7</sup>. The use of CBCT imaging showed contact point at an occluso-cervical and axial level, which was required for current study.

Thus, the aim of the present study was undertaken to evaluate the types of interproximal contact areas of caries free primary molars in children using existing cone beam computed tomography (CBCT) images.

## **MATERIALS & METHOD**

### **Participants-**

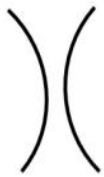


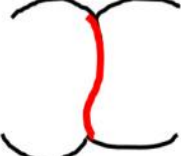
The study was designed with CBCT images of patients who presented at institution for various dental problems between 2022 to 2023. After an initial screening, 75 CBCT images selected by means of convenience sampling. Children with significant medical requirements and children whose teeth had dental caries, fillings, or crowns were not included in the research. Study subjects will comprise of patients having valid diagnostic reasons or treatment in anterior region of primary maxillary and mandibular right quadrant and should be caries free. The final samples were 34 CBCT images of maxillary right quadrant and 31 CBCT images of mandibular right quadrant of patients aged between 3 and 9 years.

### **Measurement-**

This study was done with the help of a pediatric dentist and a radiologist. Radiologist who specializes in oral and maxillofacial imaging performed the calibration procedure. Before the study began, the program consisted of theoretical discussions about CBCT image evaluation, followed by practical sessions where participants learned how to evaluate CBCT images. To ensure that the measurements were consistent, the inter-examiner variability was assessed before and after the data collection period. A single device (Planmeca ProMax® 3D Mid) was used to

capture all CBCT images, and the parameters were as follows: field of view = 80 mm 80 mm, voxel size = 0.40 mm, kV = 90, mA = 12, exposure length = 12 s, and slice thickness = 0.4 mm. The shapes of the contact regions between the primary molars on the mandible and maxilla that were free of caries were next analyzed. Examination of shape was carried out in occluso-cervical and axial level at coronal third of teeth with the help of CBCT and scoring criteria shown in **Figure 1** in both maxillary and mandibular arch. Finally, Depending on CBCT images at coronal level, highest percentage of contact pattern was evaluated in both maxilla and mandible respectively.

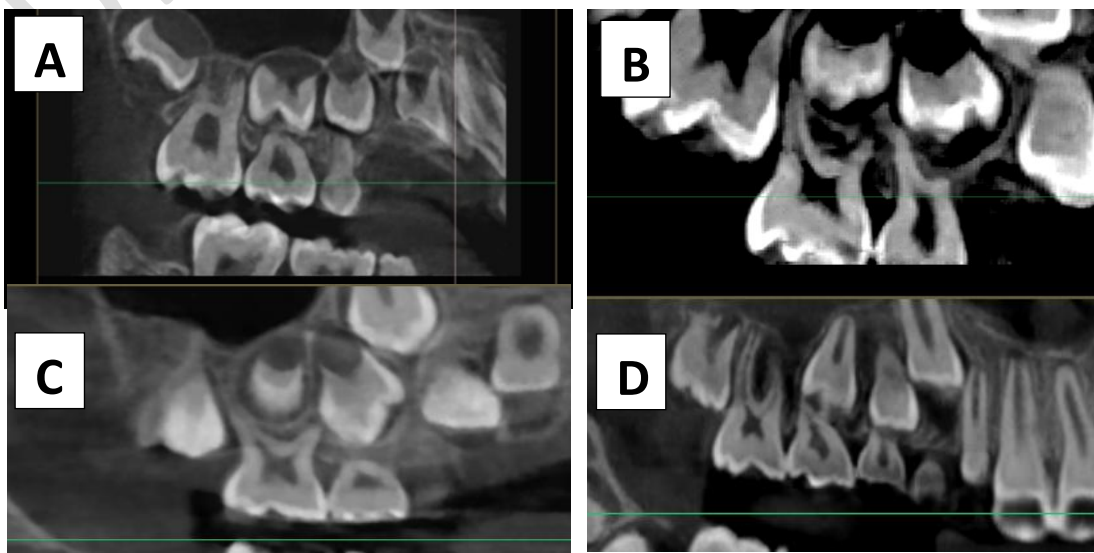
**Statistical Analysis** -- The data were tabulated in Microsoft excel and analyzed with SPP V.24 software. The continuous variable was presented with mean and standard deviation. The categorical variables were presented with frequency and percentage. In this study chi-square test was used for statistical analysis. The p-value <0.05 is considered statistically significant.

S N	Diagrammatic representation	Criteria	Type of contact
1		When there is no contact between the primary molars.	Open contact
2		When there is a point of contact ( $\leq 1.5$ mm) between the primary molars.	X-shaped contact
3		When there is a straight contact ( $\geq 1.5$ mm) between the primary molars.	I-shaped contact
4		When there is a straight contact ( $> 1.5$ mm) between the primary molars.	S-shaped contact

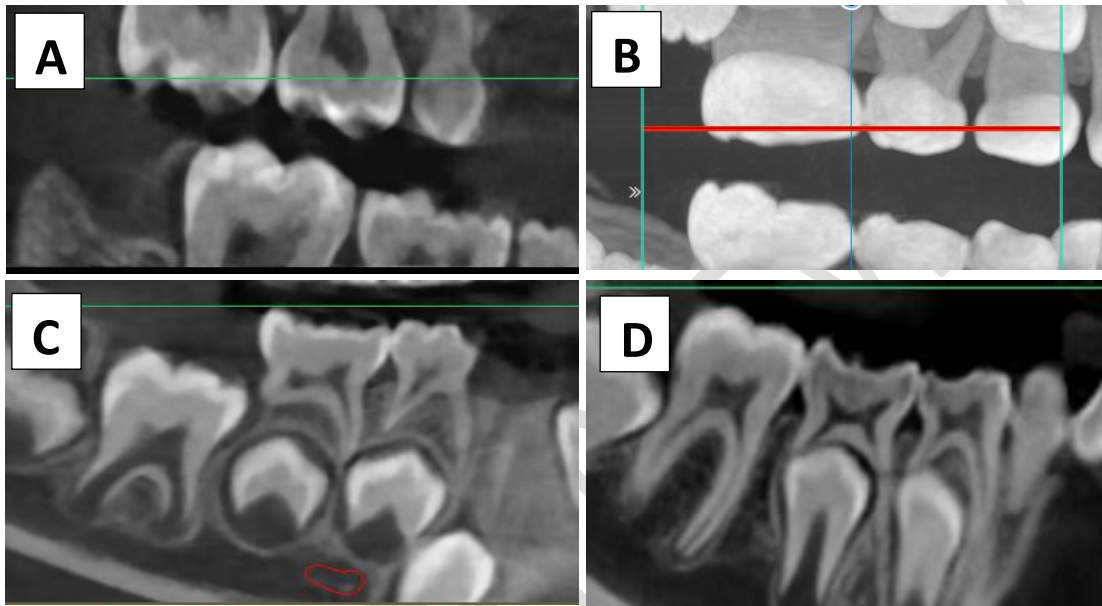
**FIGURE 1. Diagrammatic representation of the type of contact according to the OXIS scoring criteria. (Krithiga M. et. Al.)**

## RESULT

In present study, total of 65 CBCT images were included., 34 interproximal contacts of primary right maxillary molars and 31 interproximal contacts of primary right mandibular molars were evaluated by using CBCT. Among 34 interproximal contacts of right maxillary primary molars evaluated, **O** type was in 20.59% cases, **X** type in 17.56%, **I** type in 47.06% and **S** type in 14.71% cases. [Fig. 2] Among 31 interproximal right mandibular primary molars evaluated, **O** type was in 45.16% cases, **X** type in 29.03%, **I** type in 12.9% and **S** type in 12.9% cases. [Fig. 3] So, among the different types of contacts, the most common contact in the maxilla was **I** (47.06%) followed by **O** type, **X** type and **S** type respectively and which was statistically significant. In the mandible, the most common were **O** (50%) followed by **X**, **I**, **S**, respectively and which was statistically non-significant.



**Fig. 2A:** CBCT image showing ‘O’ type; **2B:** ‘X’ types; **2C:** ‘X’ type; **2D:** ‘S’ type of contact areas between upper primary molars



**Fig. 3A:** CBCT image showing ‘O’ type; **3B:** ‘X’ types; **3C:** ‘X’ type; **3D:** ‘S’ type of contact areas between upper primary molars

TYPES OF CONTACT	MAXILLA RIGHT QUADRANT			MANDIBLE RIGHT QUADRANT		
	N	%	P VALUE	N	%	P VALUE
O	7	20.59		14	45.16	.058
X	6	17.56		9	29.03	
I	16	47.06		4	12.9	

			.007			
S	5	14.71		4	12.9	

**Table 1: Incidence of different types of interproximal contacts in between primary maxillary and mandibular molars**

## DISCUSSION

The OXIS classification is proposed based on the current study's use of CBCT scans for the preliminary assessment of the contact regions of primary molars in a retrospective manner.<sup>3</sup> As an emerging technology, CBCT has a lower radiation dose and a higher resolution than traditional computed tomography scans. The types of proximal contacts between primary molars can be visualized clearly in occlusal and axial view at coronal level. The interproximal contacts were named according to the shape in which they were observed i.e., when there was no contact between the primary molars – it was called **open contact**, [Fig 2A] when there was point of contact ( $\leq 1.5$ ) between primary molars – it was called **X** [Fig 2B]shaped contact, when there was a straight contact ( $\geq 1.5$ ) between primary molars – it was called **I** [Fig 2C]shaped contact and when there was a straight contact ( $> 1.5$ ) – it was called **S** [Fig 2D]shaped contact.<sup>1</sup> Thus, a new classification for non-carious interproximal contacts of primary molars has been proposed by Krithiga M. et al<sup>1</sup>. OXIS classification was developed based on observations of interproximal contacts in primary molars using cone-beam computed tomography (CBCT) and found that the most common type of contact in primary molars was I (straight contact), followed by S (curved contact), O (open contact), and X (point contact)<sup>1</sup>. In our study also for maxilla contact area type **I** was more as compared to other contact types with **S** being the least. In one of the previous studies given by Walia T et al, it was found that **I-type** contact was more as compared to other contacts in maxilla and the least common contacts observed in this study were ‘S’ and ‘X’<sup>2</sup>. In another study given by Birgi C et al, the similar result for maxilla was observed<sup>5</sup>.

For mandible, in our study contact type **O** [Fig 3A] was more as compared to other contact types with **I** and **S** being the least. In the previous study given by Walia T et al and another study given by Birgi C et al, it was observed that in the two groups taken in their studies, contact type **I** [Fig 3C] was common for both the groups with contact type **X** [Fig 3B]to be least in one group and contact type **S** [Fig 3D] being least in another group<sup>4,5</sup>.

In another study given by Walia T et al. two centres 1- Ajman & centre 2 -Puducherry were chosen and comparison were made between centres with respect to contact areas and it was found that **I** and **X** contact were common for both maxilla and mandible in centre 1 whereas in centre 2 **I** and **S** contact were common for both maxilla and mandible. This difference was due to geographic variations between the two centres<sup>2</sup>. Arthi J et al. also conducted a study and found that **O** contact was more common in both maxillary and mandibular canine as compared to other contacts<sup>6</sup>.

In other studies, done by Muthu MS et al.<sup>4</sup>, Walia T et al.<sup>5</sup>, coronal, middle and apical level were examined in occlusal section to find about contact types between caries free primary molars. According to Krithiga M. et al., in all the contacts studied, the type of contact area at the occlusal third coincided with the overall score, indicating that the contact area existed only at the occlusal third of the tooth surface.<sup>1</sup> Hence, in this study, occlusal and axial level was examined in CBCT.

“The most significant clinical implication of the type of contact area is that it could be a risk factor for the occurrence of proximal caries between the primary molars and hence should be included in the caries risk assessment for children”<sup>2</sup>. “Another significant implication is that, knowledge of the variations in contact can aid the clinician in restoring complex contacts to more favorable ones thus reducing plaque accumulation and caries”<sup>6</sup>. Recording the initial contacts of teeth can help clinicians identify the surfaces that are most at risk for developing caries<sup>6</sup>. “The dynamic changes in the establishment of a contact area with changes in arch length as children age should also be studied”<sup>5</sup>.

## **CONCLUSION**

In conclusion, the contact areas vary as four different types, namely Open, X-shaped, I-shaped, and S-shaped. Further, the three-dimensional evaluation of intact caries free interproximal contact areas revealed that in maxilla ‘**I**’ contact type was common followed by **O** type, **X** type and **S** type respectively whereas in mandible ‘**O**’ contact type was common among all other types followed by **X** type and **I** & **S** type respectively.

## **LIMITATION OF THE STUDY**

The present study confirmed OXIS contacts between primary molars, although with considerable differences in frequency. The reason behind that may be due to geographical

variations. Future studies should use a standardized methodology to address the prevalence of OXIS contacts due to less sample size in present study.

## **ETHICAL APPROVAL**

The study is approved by the Institutional Ethics Committee, K. D. Dental College & Hospital, Mathura.

## **CONSENT**

As per international standard, parental written consent has been collected and preserved by the author(s).

## **REFERENCES**

1. Kirthiga M, Muthu MS, Kayalvizhi G, Krithika C. Proposed classification for interproximal contacts of primary molars using CBCT: a pilot study. *Welcome open research*. 2018;3.
2. Walia T, Kirthiga M, Brigi C, Muthu MS, Odeh R, Mathur VP, Rodrigues S. OXIS contact areas of primary molars—a two center cross-sectional study [version 1; peer review: 2 approved].
3. Cho VY, King NM, Anthonappa RP. Role of Marginal Ridge Shape and Contact Extent in Proximal Caries Between Primary Molars. *Journal of Clinical Pediatric Dentistry*. 2021 Apr 1;45(2):98-103.
4. Muthu MS, Kirthiga M, Lee JC, Kayalvizhi G, Mathur VP, Kandaswamy D, Jayakumar N. OXIS contacts as a risk factor for approximal caries: A retrospective cohort study. *Pediatric dentistry*. 2021 Jul 15;43(4):296-300.
5. Walia T, Kirthiga M, Brigi C, Muthu MS, Odeh R, Mathur VP, Rodrigues S. Interproximal contact areas of primary molars based on OXIS classification—a two centre cross sectional study. *Version 2 Welcome Open Research*. 2020;5.
6. Aarthi J, Muthu MS, Kirthiga M, Kailasam V. Modified OXIS classification for primary canines. *Welcome Open Research*. 2022;7.
7. Adibi S, Zhang W, Servos T, O'Neill PN. Cone beam computed tomography in dentistry: what dental educators and learners should know. *Journal of dental education*. 2012 Nov;76(11):1437-42.
8. Allison PJ, Schwartz S. Interproximal contact points and proximal caries in posterior primary teeth. *Pediatric Dentistry*. 2003 Aug;25(4):334-40.
9. Kirthiga M, Muthu MS, Lee JJ, Kayalvizhi G, Mathur VP, Song JS, Shin K, Praveen R. Prevalence and correlation of OXIS contacts using Cone Beam Computed Tomography (CBCT) images and photographs. *International Journal of Paediatric Dentistry*. 2021 Jul;31(4):520-7.
10. Alamri HM, Sadrameli M, Alshalhoob MA, Alshehri MA. Applications of CBCT in dental practice: a review of the literature. *General dentistry*. 2012 Sep 1;60(5):390-400.
11. Kirthiga M, Tejasvi R, Srivarshani S, Muthu MS. Assessment of OXIS contacts-a comparison of three methods. *European Archives of Paediatric Dentistry*. 2023 Jun 14:1-5.

UNDER PEER REVIEW