

## **Case report**

### **Pedunculated Focal Nodular Hyperplasia adherent to the Gall bladder: A Case Report**

#### **Abstract**

Background: Focal Nodular Hyperplasia (FNH) is a benign hepatic neoplasm commonly occurring in women of the reproductive age group. The pedunculated form is a rare entity that occurs in 3% of the cases. A case of pedunculated FNH adherent to the gallbladder is reported.

Case: A 33-year-old woman with a mass in the right upper quadrant of the abdomen associated with intermittent pain and was found to have pedunculated focal nodular hyperplasia adherent to the gallbladder. She underwent laparotomy with cholecystectomy and wide resection of segments V and VI of the liver.

Conclusion: Early diagnosis is imperative in cases of pedunculated FNH to guide the plan of treatment so as to minimize the risk of complications. It must therefore be kept in mind as a differential in cases of liver masses, especially in young women of the reproductive age group.

#### **Introduction**

Focal Nodular Hyperplasia is a benign tumor of hepatic origin, only second in prevalence to cavernous hemangiomas [1-3]. FNH typically occurs in females of the reproductive age group [1]. It is asymptomatic in most cases but can rarely arise as a pedunculated mass- that is more likely to be associated with complications and hence requires surgical treatment. Adherence of the tumor to the gallbladder creates additional challenges in terms of resection. We report a case of a 33-year-old woman with a mass in the right upper quadrant of the abdomen associated with intermittent pain diagnosed as pedunculated focal nodular hyperplasia of the liver.

Keywords- focal nodular hyperplasia, liver tumor, liver resection, laparotomy

#### **Case Presentation**

A 33 year-old woman presented with complaints of a mass in the right upper quadrant of her abdomen since 1 year, associated with intermittent pain. She has no other complaints and there was no history of use of oral contraceptive pills. On physical examination, the patient's vitals were stable. An 8 cm x 6 cm mass was palpated in the right hypochondrium in the midclavicular line, 3 cm below the costal margin with well-defined borders and an irregular surface which moved with respiration. On percussion, a dull note was heard over the mass, continuous with

liver dullness. Liver serology was negative. Ultrasonography (USG) of the abdomen showed a well-defined oval isoechoic solid lesion of 7.5 cm x 5.8 cm in the right lobe of the liver with no calcification or cavitation. Computed Tomography (CT) of the abdomen revealed an exophytic mass of 7.1 cm x 7.3 cm x 9.5 cm arising from the inferior right lobe of the liver with prominent arterial recruitment as shown in figures 1-4.

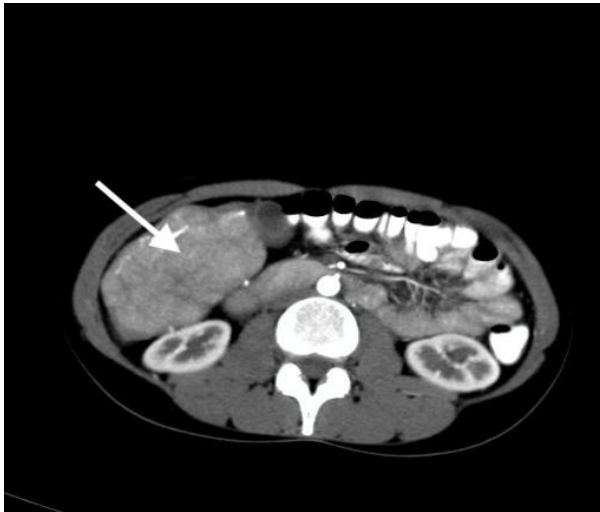

Fig.1: Axial section of CECT showing the lesion (as indicated by arrow)

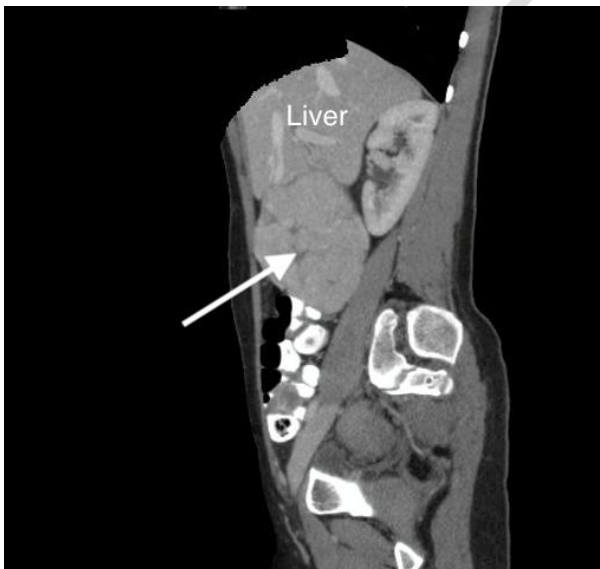

Fig.2: Sagittal section showing tumor (as indicated by arrow) arising from liver.

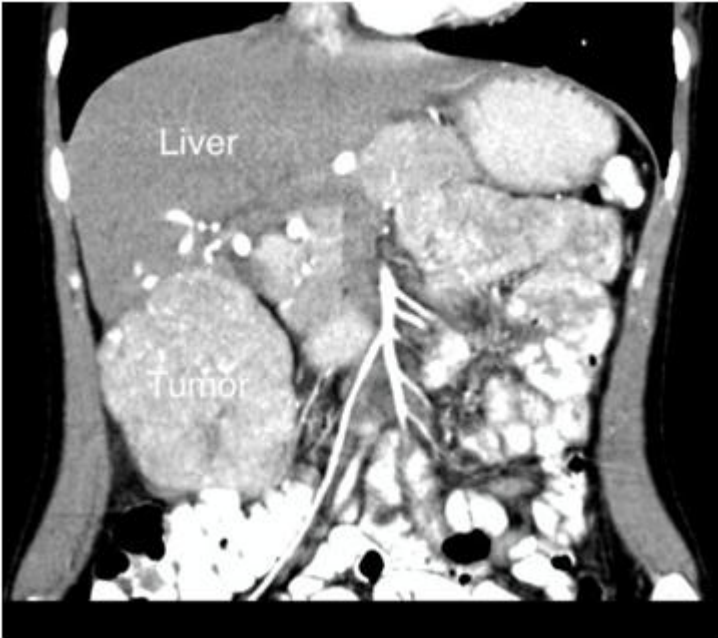

Fig.3: Coronal Section showing the tumor arising from the inferior right lobe of liver

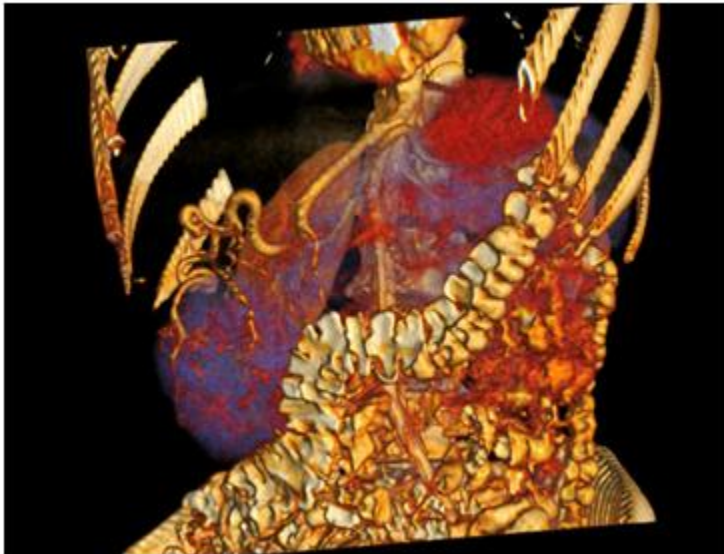


Fig.4: 3D Reconstructed Image showing a mass arising from the inferior right lobe of the liver with prominent arterial recruitment.

Patient underwent a laparotomy with cholecystectomy and wide resection of segments V and VI of the liver. Intraoperatively, a 10 cm x 8 cm vascular fibrous pedunculated growth arising from segment V and VI of the liver and adherent to the gallbladder was noted as shown in figure 5.

Dilated lymphatics were also noted around the gallbladder. Remaining liver parenchyma appeared grossly normal.

Macroscopic examination of the respected specimen showed a nodular external surface and the cut section showed a well circumscribed solid lesion with a central area of gray white stellate scarred tissue. Microscopically, hepatic tissue characterized by prominent nodules separated by fibrous septae with plenty of thick-walled blood vessels was noted suggestive of focal nodular hyperplasia of liver.

UNDER PEER REVIEW

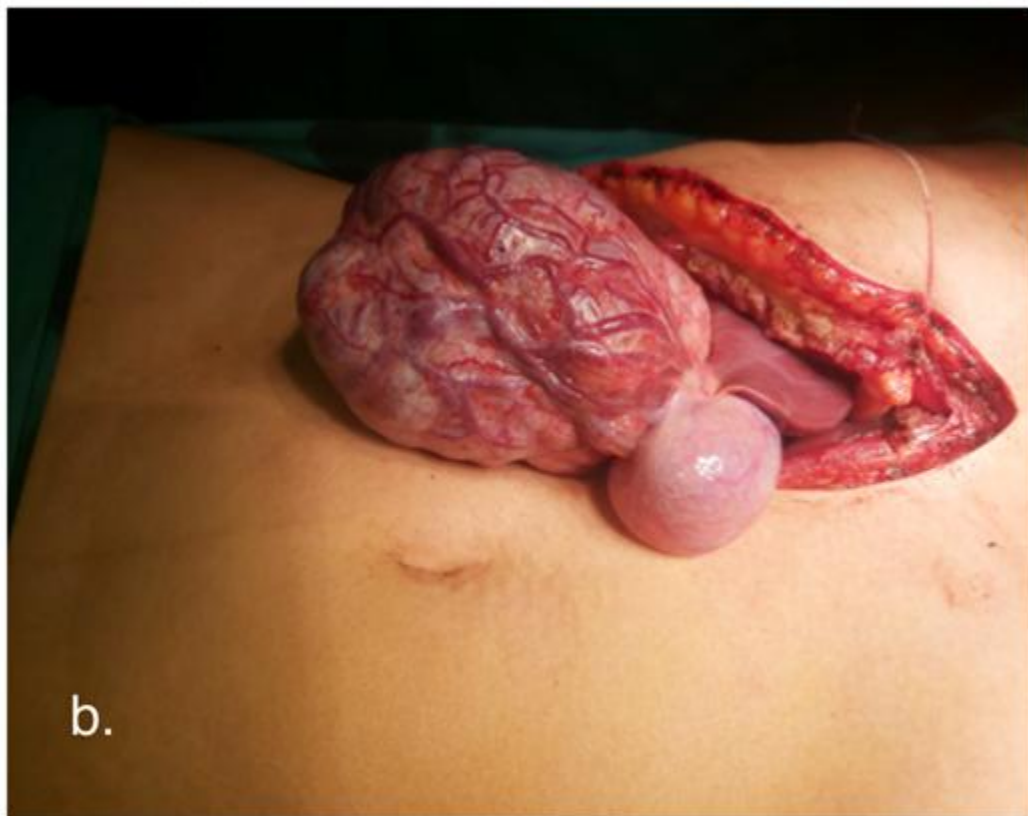
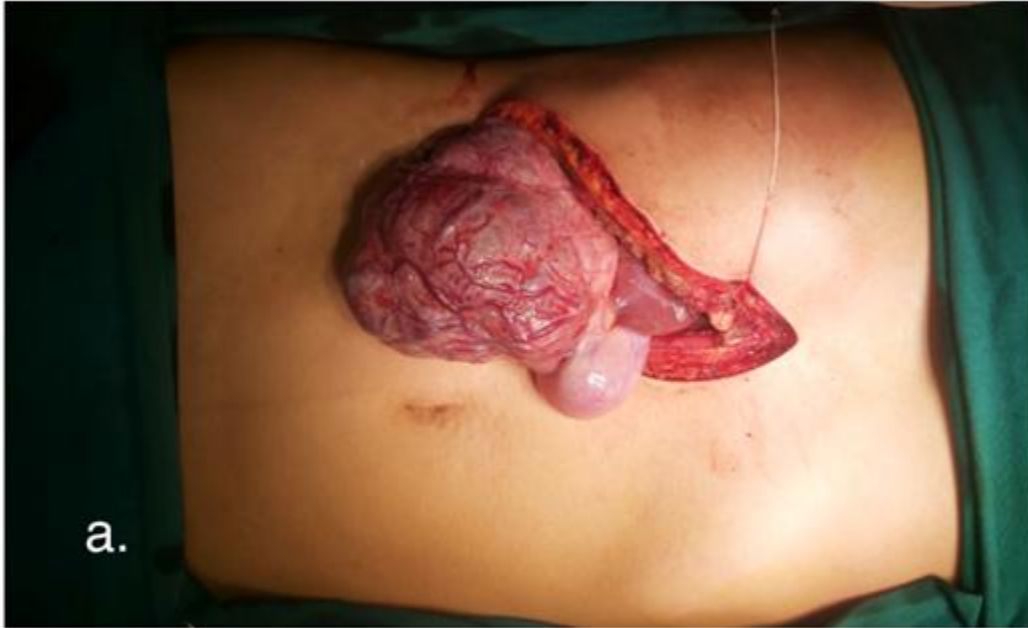

Fig.5: Intraoperative images showing a large vascular fibrous pedunculated growth arising from segment V and VI of the liver that is adherent to the gallbladder .

## Discussion

Focal Nodular hyperplasia is the second most common benign liver tumor after cavernous hemangiomas [1-3]. It has an estimated prevalence of 0.9% in the general population [1]. It commonly occurs in young women [1] and is associated with the use of oral contraceptive pills [4-5], although cases have been reported in children [6] as well as in men [7]. Pedunculated variety accounts for only 3% of the cases of FNH [8]. As per a report by Ismail et al [9], only 10 cases of pedunculated FNH had been reported until 2020. FNH typically has a size less than 5 cm and only 3% of the cases have a size greater than 10cm [3]. FNH is mostly asymptomatic but a pedunculated form can result in complications such as gastric outlet obstruction precipitated from tumors of segments 2-5, compression of surrounding vessels, hemorrhage from the vessels of the stalk and most significantly, torsion of the pedicle leading to infarction of the tumor [9, 10].

Diagnosis of FNH is often incidental and made with imaging modalities such as MRI which shows a hypo/iso-intense mass on T1-weighted images and hyper/iso-intense mass on T2-weighted images with arterial phase enhancement [11]. Ultrasound and Computed Tomography can also be used but have a lower sensitivity and specificity. Definitive diagnosis is made with histopathology.

Management of FNH is mostly conservative, involving cessation of oral contraception and routine follow up. Resection is indicated in symptomatic or atypical cases, ideally using a laparoscopic approach wherever feasible [9]. Embolization of the feeding vessel can also be performed [10]. FNH does not have malignant potential and resection ensures lasting relief of symptoms.

## Conclusion

Early diagnosis is imperative in cases of pedunculated FNH to guide the plan of treatment so as to minimize the risk of complications. It must therefore be kept in mind as a differential in cases of liver masses, especially in young women of the reproductive age group.

Patient Consent: Written informed consent taken

## References

1. Vilgrain V. Focal nodular hyperplasia. Eur J Radiol [Internet]. 2006 [cited 2023 Feb 24];58(2):236–45. Available from: <https://pubmed.ncbi.nlm.nih.gov/16414229/>
2. Kerlin P, Davis GL, McGill DB, Weiland LH, Adson MA, Sheedy PF 2nd. Hepatic adenoma and focal nodular hyperplasia: clinical, pathologic, and radiologic features.

- Gastroenterology [Internet]. 1983 [cited 2023 Feb 24];84(5 Pt 1):994–1002. Available from: <https://pubmed.ncbi.nlm.nih.gov/6299876/>
3. Ishak KG, Rabin L. Benign tumors of the liver. *Med Clin North Am* [Internet]. 1975;59(4):995–1013. Available from: <https://www.sciencedirect.com/science/article/pii/S0025712516319988>
  4. Herman P, Pugliese V, Machado MA, Montagnini AL, Salem MZ, Bacchella T, et al. Hepatic adenoma and focal nodular hyperplasia: differential diagnosis and treatment. *World J Surg* [Internet]. 2000;24(3):372–6. Available from: <http://dx.doi.org/10.1007/s002689910059>
  5. Pain JA, Gimson AE, Williams R, Howard ER. Focal nodular hyperplasia of the liver: results of treatment and options in management. *Gut* [Internet]. 1991 [cited 2023 Feb 24];32(5):524–7. Available from: <https://gut.bmj.com/content/32/5/524>
  6. Franchi-Abella S, Branchereau S. Benign hepatocellular tumors in children: focal nodular hyperplasia and hepatocellular adenoma. *Int J Hepatol* [Internet]. 2013 [cited 2023 Feb 24];2013:215064. Available from: <https://pubmed.ncbi.nlm.nih.gov/23555058/>
  7. Luciani A, Kobeiter H, Maison P, Cherqui D, Zafrani E-S, Dhumeaux D, et al. Focal nodular hyperplasia of the liver in men: is presentation the same in men and women? *Gut* [Internet]. 2002 [cited 2023 Feb 24];50(6):877–80. Available from: <http://dx.doi.org/10.1136/gut.50.6.877>
  8. Schild H, Thelen M, Paquet KJ, Biersack HJ, Janson R, Bücheler E, et al. Fokal noduläre Hyperplasie. *Rofo* [Internet]. 1980;133(4):355–64. Available from: <http://dx.doi.org/10.1055/s-2008-1056744>
  9. Ben Ismail I, Zenaidi H, Jouini R, Rebi S, Zoghlami A. Pedunculated hepatic focal nodular hyperplasia: A case report and review of the literature. *Clin Case Rep* [Internet]. 2021 [cited 2023 Feb 24];9(6):e04202. Available from: <http://dx.doi.org/10.1002/ccr3.4202>
  10. Zeina A-R, Glick Y. Pedunculated hepatic focal nodular hyperplasia. *Ann Hepatol* [Internet]. 2016;15(6):929–31. Available from: <https://www.sciencedirect.com/science/article/pii/S1665268119311214>
  11. Chavhan GB, Mann E, Kamath BM, Babyn PS. Gadobenate-dimeglumine-enhanced magnetic resonance imaging for hepatic lesions in children. *Pediatr Radiol* [Internet]. 2014;44(10):1266–74. Available from: <http://dx.doi.org/10.1007/s00247-014-2975-3>