

Compound odontome at angle of mandible: an unusual case report

Abstract :

Rationale: A neoplastic cyst like lesion which resembles a tumor and arises from tooth forming tissues. Patient reported with rocky hard swelling of left lower jaw leading to difficulty in mouth opening, facial deformity and consistent mild pain. **Diagnosis:** compound odontome usually based on clinical and radiological findings. **Treatment :** unilateral hard mass was surgically removed from mandible and reconstruction plate were placed. on separation specimen yielded 17 teeth like structure. **Result:** outcomes as we see histologically multiple small teeth like structures are surgically removed under general anesthesia and reconstructed with titanium plates.

Keywords: odontoma, complex, compound, histopathology, reconstruction, outcome

INTRODUCTION :

“Term Odontome is defined as any tumor-like lesion, which has similarity to neoplastic cyst that arises from tooth forming tissues”. [1] “These are like hamartomas of terminated tooth formation which accounts for 22% of the odontogenic tumor”. [2] “Paul Broca gave this term ‘odontome’ in 1867 and he defined the term as tumors formed by the overgrowth or transition of complete dental tissue”. [3] “According to many researches 10% of all odontogenic tumors of the jaws are approximately compound odontomas”. [4] “The usual incidence of compound odontome ranges between 9 and 37% and the complex odontoma is between 5 and 30%. The etiology behind this tumor may be unknown till now”. [5] “The majority of odontomas in the anterior segment of the jaws are compound composite in type (61%), whereas the majority in the posterior segment is complex composite in type (34%). Usually both the type of odontomas are found more frequently on the right side of the jaw than on the left, (compound 62%, complex 68%)”. [6] “It is associated to various pathological conditions, like local

trauma, inflammatory diseases and/or infectious processes, mature ameloblasts, cell rests of Serres (dental lamina remnants) or due to hereditary anomalies such as (Gardner's syndrome, Hermann's syndrome). This leads to alterations in the genetic components and that will be responsible for controlling dental development".[7]

UNDER PEER REVIEW

CASE REPORT:

A 24 year old female patient have been referred to the oral and maxillofacial unit with a chief complaint of large and rocky hard swelling of left lower jaw, causing difficulty in mouth opening, showing facial deformity and constant mild pain since 3 year. Her medical and family history was non significant. On extraoral examination a hard swelling of approx. size 3.5 X 4 cm size on left side of angle of mandible which on palpation found to be non mobile, non pulsatile, non tender and non ulcerative in nature. [fig 1] Mouth opening was mildly reduced. On intra oral examination a unilateral hard swelling was palpable with obliteration of buccal vestibule. The orthopantomogram radiographic view appeared as a bunches of multiple irregular masses of calcified material surrounded by a thin radiolucent area with smooth periphery of size 3.5 cm × 4 cm approx., involving the angle of the mandible. [fig 2] The coronal and sagittal sections of contrast-enhanced computed tomography revealed unilateral multiple large nonspecific, disorganised, irregular radio-opaque masses with varying densities. [fig 3] Extended Risdon's extraoral surgical approach was surgically intervened and unilateral hard tissue masses were analyzed. [fig 4] The hard tissue masses were gently chiseled from both buccal and lingual site on the left side, while removing the hard tissue mass, the angle of mandible along with body appears weak for which a titanium plate placed. [fig 5] [fig 6] Specimen collected was fluctuating chunks of hard tissue masses which resembles tooth-like structures initially, further on fine separation yielded nearly 17 small teeth-like structures. [fig 7]

The histopathological section shows multiple small teeth-like structures arranged haphazardly where central fibrofatty pulpal stroma surrounded by well-formed dentin showing dentinal tubules and empty areas representing decalcified enamel matrix, which established a diagnosis of compound odontome. [fig 8] [fig 9]

A follow up of 3-month showed uneventfully healed surgical site without any jaw deformity and radiologically firm shape of mandible of left side. [fig 10]

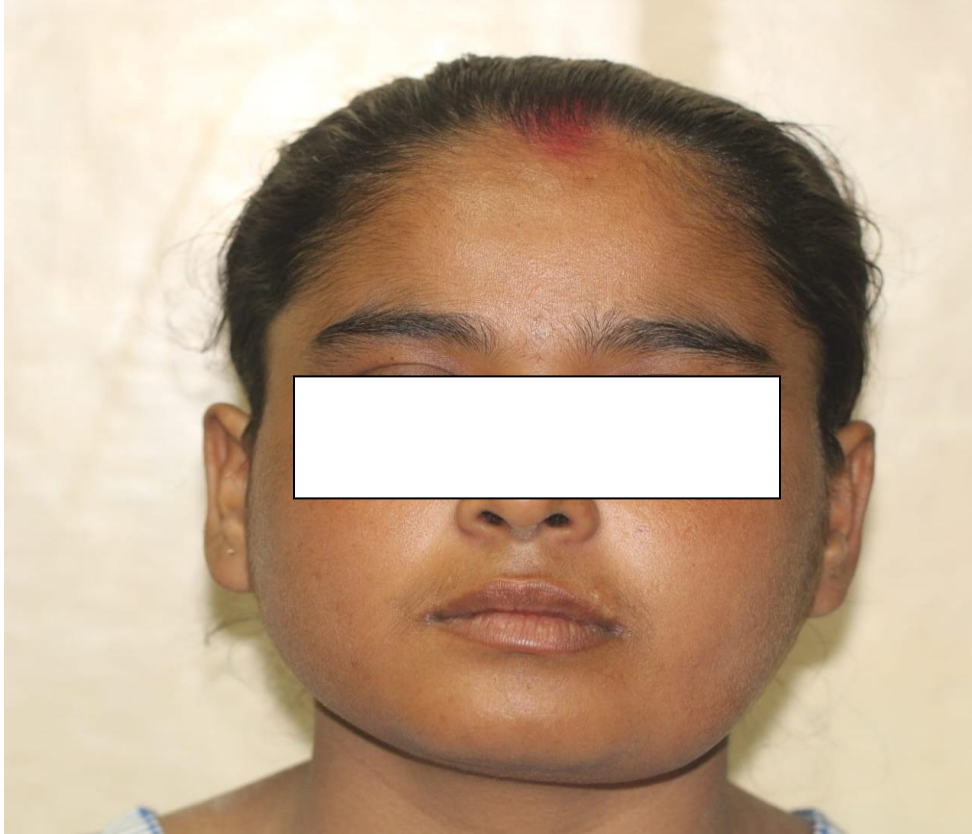

FIG 1 : Unilateral rocky hard swelling in left side of mandible

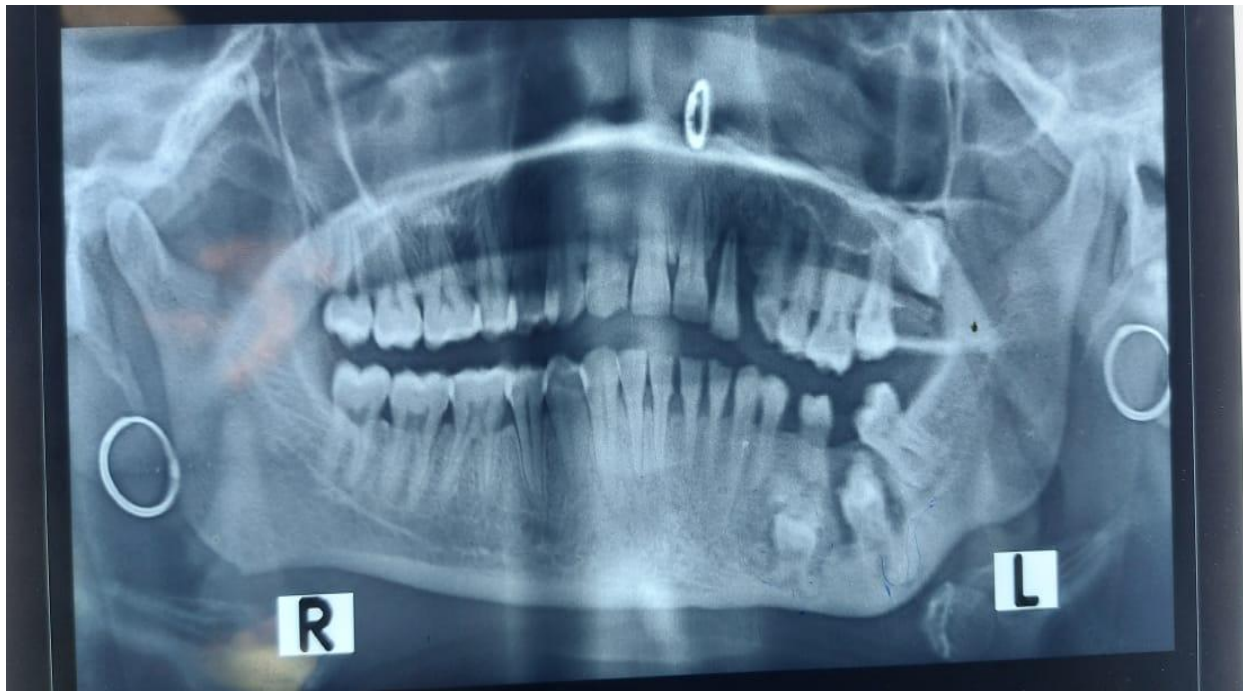

Fig 2 :Orthopantomograph shows irregular lesion of radiopacity similar to calcified mass along with impacted tooth at left side of angle of mandible

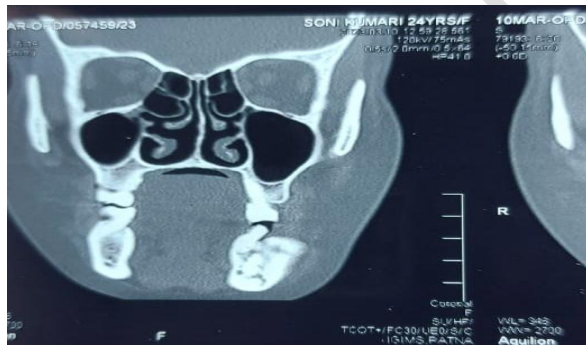


Fig 3 a] The coronal sections of contrast-enhance computed tomography shows left side radiopacity with thin radiolucent rim surrounds it

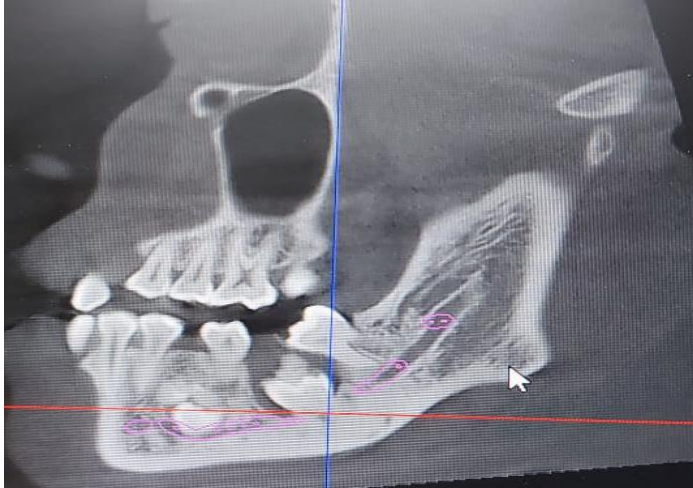


Fig 3:b] sagittal sections of computed tomography depicting unilateral multiple small and large nonspecific, disorganised, irregular radio-opaque mass with varying densities.

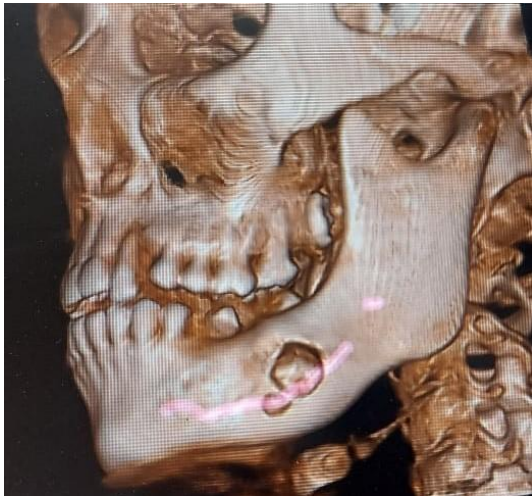

Fig 3[c] 3 Dimensional reconstruction view of left side mandible shows lesion with mass of odontoma.

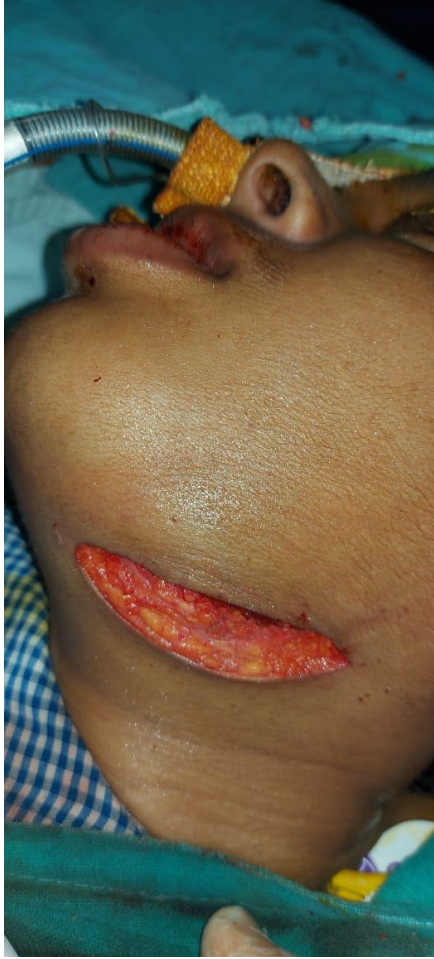

Fig 4: Extended risdons approaches

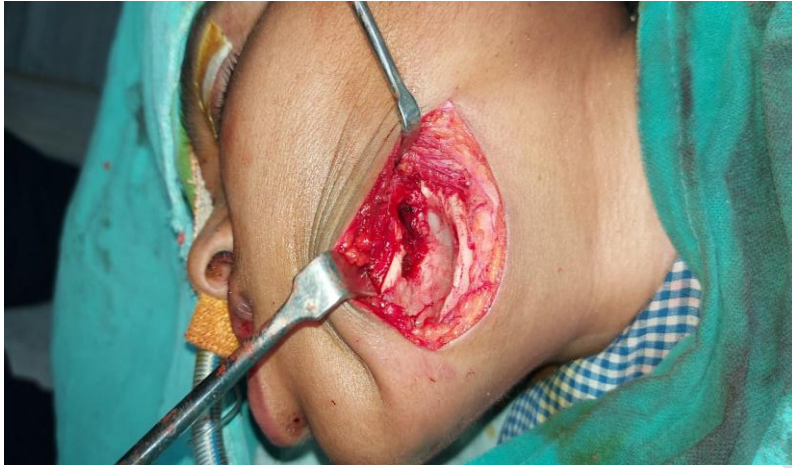

Fig 5 :Surgical site after removal of hard tissue masses were from both buccal and lingual site on the left side of mandible

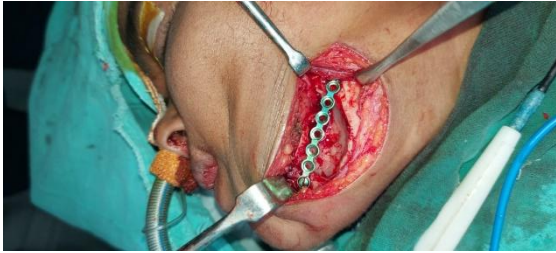

Fig 6: Defect at surgical site is reconstructed with titanium miniplates to avoid possible chances of iatrogenic fracture

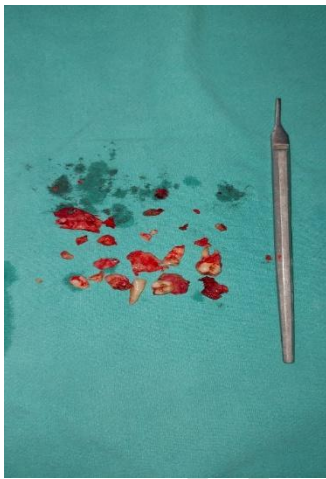


Fig 7: Specimen shows small chunks of hard tissue masses with resemblance to tooth-like structures in it

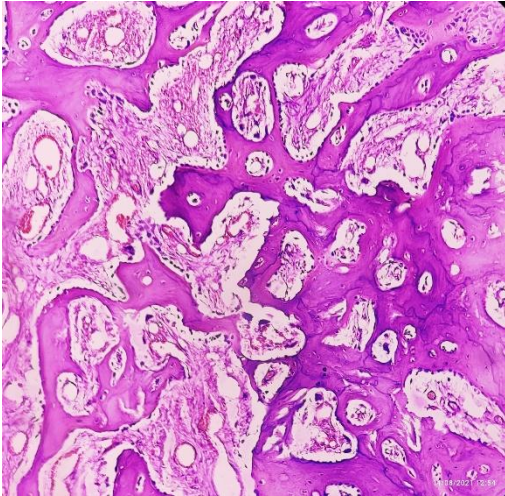


Fig 8 :H and E staining shows multiple small and large tooth like structure arranged haphazardly with central pulp stroma surrounded by dentinal tubules

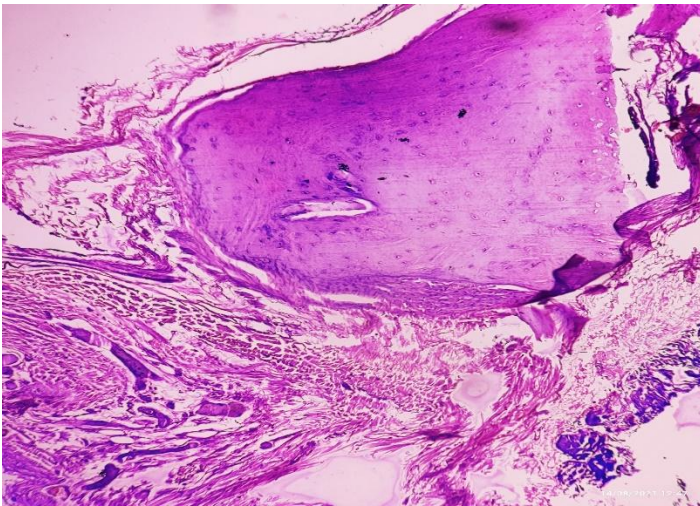


Fig 9 :An increase in the width of the regional periodontium.

Histopathological section shows an empty areas representing decalcified enamel matrix which is surrounded by fibrovascular stroma at the periphery

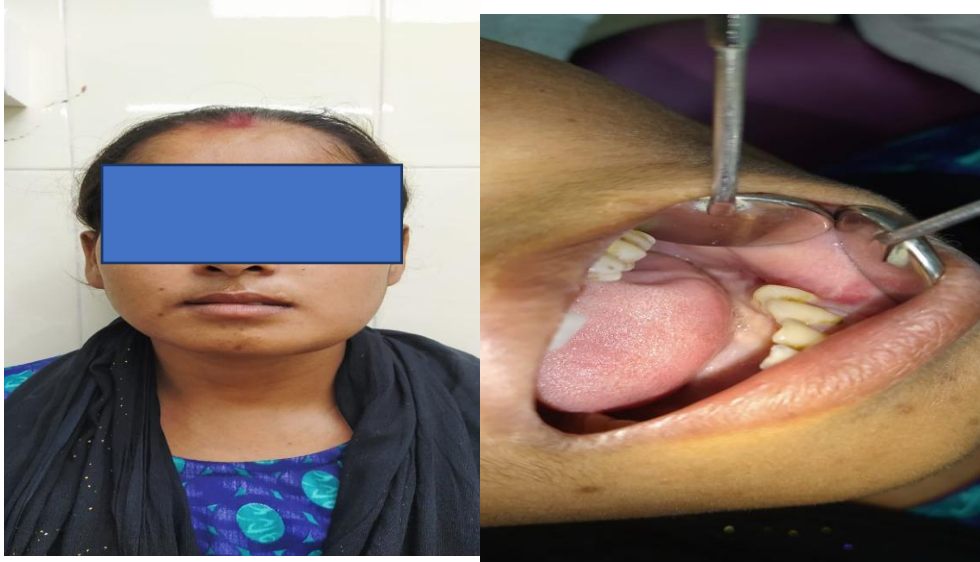


Fig 10; post op picture of patient after 3 months and intra oral shows healing without any jaw deformity.

DISCUSSION :

J M Wright explained Compound odontoma is a rare case seen on left side of angle of mandible.[8]“According to J C Park sComplex odontomas usually occur in the posterior most region of the jaw and compound types are more common in the anterior maxilla”. [9] Although they are commonly known to be asymptomatic, but clinical indications of odontoma may have retention of deciduous teeth, having pain, expansion of the cortical bone and tooth displacement. “When comparison is being established between radiographic findings of both the lesions must allow the clinician to differentiate between these two diseases, which have divergent behavior and prognosis. An increase in the width of the regional periodontium may appear. In addition, peripheral sunburst pattern developed due to periosteal reactions”. [10]

Early planning with established diagnosis will have better prognosis and prevents from any future craniofacial developmental issues.

The surgical approaches for removal of odontoma is fine resection of affected side.

UNDER PEER REVIEW

CONCLUSION :

Diagnosis of both complex and compound odontoma needs clinical expertise and surgical approaches of fine resection is only treatment mode if reported early. Chances of recurrence is minimal and no gross jaw deformity seen.

Consent

As per international standard or university standard, patient(s) written consent has been collected and preserved by the author(s).

Ethical Approval:

As per international standard or university standard written ethical approval has been collected and preserved by the author(s).

UNDER PEER REVIEW

REFERENCES:

1. Maltagliati, A.; Ugolini, A.; Crippa, R.; Farronato, M.; Paglia, M.; Blasi, S.; Angiero, F. Complex odontoma at the upper right maxilla: Surgical management and histomorphological profile. *Eur. J. Paediatr. Dent.* 2020, 21, 199–202.
2. Bueno, N.P.; Bergamini, M.L.; Elias, F.M.; Braz-Silva, P.H.; Ferraz, E.P. Unusual giant complex odontoma: A case report. *J. Stomatol. Oral Maxillofac Surg.* 2020, 121, 604–607, Epub 2 January 2020.
3. Singh P, Iqbal J, Imam ZS, Biswas KP, Singh N, Mishra N. Bilateral massive complex composite odontomass of the mandible: A rare case report. *Ann Maxillofac Surg* 2022;12:87-90
4. SharifiRayeni A, Samieirad S, Mianbandi V, Saghravanian N, Tohidi E. A rare case of maxillary compound odontoma with an unusual large number of denticles. *JDMT.* 2019;8(2):101–6.
5. Van HA, Nguyen TT, Vo NQ, Vo TH, Chansomphou V, Pham NT, Trinh CT, Aiuto R. Giant compound odontoma of the mandible in an adolescent. *J PediatrSurg Case Rep.* 2021;65:101755
6. Lekshmy J, Padmashree S, Pandeshwar P. Unerupted Complex Odontoma of the Posterior Mandible: A case report. *Int J Maxillofac Imaging.* 2021;2(3):110–2
7. Kasami N, Popovski V. Giant Complex Odontoma of the Mandible: A case report and literature review. *ActaMedicaBalkanica.* 2020;5(9-10):58–64
8. Wright JM, Vered M. Update from the 4th Edition of the World Health Organization Classification of Head and Neck Tumours: Odontogenic and Maxillofacial Bone Tumors. *Head Neck Pathol.* 2017;11(1):68–77
9. Park JC, Yang JH, Jo SY, Kim BC, Lee J, Lee W. Giant complex odontoma in the posterior mandible: A case report and literature review. *Imaging Sci Dent.* 2018;48(4):289–293

10. Saravanan R, Sathyasree V, Manikandhan R, Deepshika S, Muthu K. Sequential Removal of a Large Odontoma in the Angle of the Mandible. *Ann Maxillofac Surg.* 2019;9(2):429–433

;

UNDER PEER REVIEW