

Morphological Changes of Meibomian Gland in Anophthalmic Patients Wearing PMMA Prosthetic Eyes

ABSTRACT

Background

Chronic ocular discomfort represents one of the most common adverse events referred to patients with long-standing ocular prosthesis wearing. **Aim and Objectives:** The current work aimed to evaluate the morphological changes of meibomian gland in unilateral anophthalmic patients wearing PMMA prosthetic eyes in relation to contralateral normal eye. **Subjects and methods:** This work has been performed upon 40 eyes of patients with anophthalmic socket wearing PMMA prosthetic eye completed a questionnaire designed to identify MGD-related ocular symptoms. Both eyelids of each patient underwent slit lamp examination, meibography imaging, and microbiological assessment. Intra-individual comparison of main outcome measures between the eyelids of a prosthetic eye and paired normal eyelids was performed using Wilcoxon signed-rank test. A linear mixed model was employed to evaluate the relationship between ocular symptoms and meibomian gland/tear characteristics.

Results: The eyelids with an ocular prosthesis exhibited significantly higher scores for ocular symptoms, lid margin abnormality, meibomian gland expression, and meibography compared to the normal eyelids ($p < 0.01$ for all scores). The meibography score was significantly positively connected with the ocular symptom score and negatively correlated with tear parameters ($p < 0.01$ for all parameters, linear mixed model).

Conclusions: With a prosthetic eye, meibomian glands of the eyelids are more likely to be lost. Accordingly, deterioration and loss of normal anatomical structures might lead to obstructive MGD, which was strongly associated with dry eye ocular symptoms.

These findings suggest that patients with prosthetic eyes, particularly those experiencing ocular discomfort, may benefit from clinical screening and care recommendations for MGD.

Keywords: Anophthalmic Patients, Meibomian Gland, Meibography.

INTRODUCTION

Anophthalmia is a severe form of ocular malformation characterized by the complete absence of an eye.^[1] “Surgical anophthalmia results from either enucleation or evisceration. In enucleation surgeon removes the whole eyeball, whereas in evisceration sclera and extraocular muscle are left intact and is mostly accounted as a cosmetic procedure”.^[2]

“The loss of an eye represents severe emotional stress so, the use of an ocular prosthesis to improve cosmetic appearance, as well as ameliorating social acceptance”.^[3]

“The principal causes for the need of an ocular prosthesis comprise defects and malformations, irreparable trauma, end-stage eye diseases, and severe ocular disease associated with uncontrolled pain, such as neovascular glaucoma, or an unattractive appearance, such as phthisis bulbi”.^{[4] [5]}

“Meibomian gland dysfunction (MGD) is defined as a chronic, diffuse abnormality of the meibomian glands and a major cause of dry eye disease”.^[6]

Ocular symptoms of MGD are irritation, foreign body sensation, itching, stinging, blurred vision, light sensitivity, and glued eye lids. These symptoms can impact the quality of life of the patients.

Recent studies also confirmed “the relationship between MGD and ocular prosthesis wear, demonstrating a larger grade of Meibomian gland loss and alterations compared with normal paired eyelids”.^{[7] [8]}

“Numerous mechanisms were suggested, such as the infection of the anophthalmic socket, glutinous surface deposits and a roughened prosthesis”.^{[9] [10]}

“Noncontact meibography is a recently developed noninvasive method that allows relatively rapid imaging of meibomian glands”^[11]. It is now widely adopted in clinical practice for evaluation of meibomian gland-related diseases.

Our aim was to evaluate the morphological changes of meibomian gland in unilateral anophthalmic patients wearing PMMA prosthetic eyes in relation to contralateral normal eye.

MATERIALS AND METHODS

Patients

Patients with unilateral ocular prosthesis were recruited from the outpatient clinic in the Department of Ophthalmology Tanta University Hospitals, Egypt from December 2020 to December 2021. Each patient was asked questions regarding their demographic status and duration of prosthesis use, type of ophthalmic surgery, such as evisceration or enucleation. Our inclusion criteria was: Patients with unilateral anophthalmic socket wearing PMMA prosthesis for more than one year, and exclusion criteria: Patients wearing prosthesis for less than 1 year, complications of prosthesis such as infection, implant exposure, or contraction, Lid abnormalities such as entropion, ectropion, or retraction, Patients with symptoms of dry or watery eye on the normal side.

Method

Ocular discomfort symptoms were assessed in all patients using a five-point categorical scale^[8] of the following frequencies: patients who didn't have these symptoms took the score (0), those who suffered some of the time took the score (1), those who suffered half of the time took the score (2), those who suffered most of the time took the score (3), and those who suffered all of the time took the score (4).

Lid margin abnormalities were scored from 0 to 4 based on the presence or absence of the following parameters: irregular lid margin, plugging of meibomian gland orifices, vascular engorgement, or a shift in the mucocutaneous junction. If any of these signs was present, one point was assigned for each item^[12]. Lash position and lid margin position were noted. Entropion and ectropion and were excluded.

“MG expression techniques were done to assess alterations of the MG secretions. It was assessed by assigning grades for clarity and ease of meibum expression: clear meibum and easy expression (grade 1), cloudy in response to mild pressure (grade 2), cloudy in response to moderate pressure (grade 3), and no expression in response to hard pressure (grade 4)”^[8].

The socket was evaluated for inflammation, excessive mucous, and pyogenic granulomas. Palpebral conjunctiva in both normal eye and prosthetic eye was examined for any abnormalities or signs of any inflammations, scars, or giant papillary conjunctivitis under the upper eyelid.

“Meibography imaging was performed and Meiboscore was done using the following four grade scale, grade 0 (no loss of meibomian glands), grade 1 (meibomian gland area loss < 25%), grade 2 (meibomian gland area loss was greater than 25% and < 50%) grade 3 (meibomian gland area loss was greater than 50% and < 75%), and grade 4 (meibomian gland loss > 75%)”^[13]. Meiboscores for the upper and lower eyelids were done.

Microbiological assessment was done to explore the relationship between conjunctival flora and comfort of the socket in anophthalmic patients. specimens were taken from the lower conjunctival sac of both normal eye and prosthetic eye

Data analysis

The used tests were:-

1 - McNemar Test

Used to analyze the significance between the different stages

2 –Wilcoxon signed ranks test

For abnormally distributed quantitative variables, to compare between two periods

Level of significance:

Significance test results are quoted as two-tailed probabilities.

For all the above-mentioned tests, the level of significance was tested, expressed as the probability of (p-value) and the results were explained as following:

- Non-significant if the p value is > 0.05
- Significant if the p value is ≤ 0.05 .
- Highly significant if the p value < 0.001 .

RESULTS

In total, 40 patients (male, n=17; female, n=23) were eligible for the study. Patient demographics are summarised in table 1. The mean patient age was 38.18 ± 18.59 years (range, 10 to 78 years), and mean duration the prosthesis had been worn was 10.20 ± 7.18 years (range, 2 to 25 years). The most common cause of blindness was trauma (72.5%). Evisceration was the most common type of eye removal surgery (92.5%); table (1).

Regarding to **5 point categorical scale** : 5 cases (12.5%) are suffering from discomfort, FB sensation, excessive blinking and discharge some of time of the day and 12 cases (30%) are suffering half of time and 13 cases (32.5%) are suffering most of time and lastly 10 cases (25%) are suffering all time of the day

Slit lamp examination was used to clinically assess the lid margin. The scores derived from this examination, such as lid margin abnormality score and meibomian gland expression score, were significantly higher in the eyelids of a prosthetic eye compared with the normal eyelids $p < 0.001$. (table 2). Furthermore, meibography scores were significantly higher in the eyelids of a prosthetic eye (median meibography score in normal eye for the upper and lower lid was 1 and 2 respectively compared to the score in prosthetic eye for the upper and lower lid that was 3 in both of them $p < 0.001$ (table 2). No statistically significant differences were seen between the meibography scores of the upper and lower eyelid of prosthetic eyes. figure (1)

Regarding lid examination and meibomian gland expression in prosthetic eye in the groups categorized by duration of the prosthesis use (< 10 years and ≥ 10 years): there was more affection in prosthetic eye in patients who wore prosthetic eye ≥ 10 years than those who wore prosthetic eye < 10 years (p value 0.023 and 0.001) respectively. table (3,4).

We also compared meibography scores between the two groups categorized based on the duration of prosthesis use. To assess the degree of meibomian gland loss, we determined the median value of the sums of upper and lower eyelid meibography scores in each group. The patients who had worn an ocular prosthesis longer than 10 years had a significantly greater degree of meibomian gland loss compared to those who had worn the prosthesis less than 10 years (> 10 years, score=6 vs < 10 years, score=5; $p < 0.001$. table (5) figure (2).

DISCUSSION

Using a non-contact meibographic approach, we examined the morphologic changes of the meibomian glands brought on by the use of a prosthetic eye. Compared to the normal paired eyelids, the findings showed that eyelids with an ocular prosthesis were substantially related with a larger degree of meibomian gland loss. Eyelids of a prosthetic eye seem particularly prone to obstructive MGD, which may serve as one of the mechanisms underlying prosthetic eye-related dry eyes. In our clinic practice, a majority of the patients wearing prosthetic eyes report varying degrees of dryness and discomfort. In our study, there is higher female predominance which came in agreement with **Jang S.Y et al** [8]. **Ekin M A et al** [7] reported that trauma (38.2%) was the most common cause of blindness followed by malignancy (21.8%). In ours, trauma (72.5%) was the most common cause, then absolute glaucoma (15%) and (12.5%) of cases due to other causes as perforated ulcers, endophthalmitis and tumors

In our study, evisceration was the most common procedure (92.5%) then enucleation (7.5%). And this was the same in **Ekin M A et al**.^[7] and in **Meduri A et al**^[14], But in **Rokohl A et al**^[15] enucleation was performed in 82% of patients and, evisceration was in 10% of the cases, and 8% had no operation but a phthisis.

We thought that the decrease in eyelid blinking or incomplete closure of eyelids might decrease meibum secretion and irritate the posterior lid margin, eventually causing obstruction of meibomian orifices. In addition, this might also cause increased evaporation of tears, which would contribute to the results showing decreased tear meniscus parameters. We found that there is incomplete eye closure in anophthalmic side in 14 prosthetic eyes (35.0 %) in relation to normal side which came in agreement with **Redlich et al**^[16] who reported “the difference of electronic potentials during lid blinking between the anophthalmic side and the normal side. Electronic potentials from electroencephalography were almost absent in the anophthalmic side, whereas those on the normal side were observed as normal. Slit lamp examination was used to clinically assess the lid margin and MG expression”. The scores derived from this examination, were significantly higher in the eyelids of a prosthetic eye compared with the normal eyelids as in **Meduri A et al**^[14] and **Ekin M A et al**^[7]. In addition In our study, We Compared Score of lid examination and MG expression in prosthetic eye in the groups categorized by duration the prosthetic eye had been worn (<10 years and ≥10 years) and found a positive correlation between duration of prosthesis and lid examination score.

We used CSO SIRIUS® corneal topographer in meibography, which was the same in **Ekin M A et al**^[7] who used the same device. While **Meduri A et al**^[14] used Keratograph 5M (Oculus, Wetzla Germany). In our study, Both upper and lower eye lid of prosthetic eyes were equally affected and this was not the same in **Jang S.Y et al**^[8] who found that upper eye lid was worse affected than lower.

We also compared meibography scores between the two groups categorized by duration the prosthetic eye had been worn ≥10 years as in case [1] figure (3) and <10 years as in case [2] figure (4) and found a positive correlation between duration of prosthesis and meibography score which came in agreement with **Jang S.Y et al**^[8]. We also did microbiological assessment of normal eye and prosthetic eye and found that most cases had negative swabs and cultures and positive for *S. aureus* in (15%) of prosthetic eyes while in **Toribio A et al**^[17], The most commonly isolated species, in both healthy eyes and sockets, was *S. epidermidis*, followed by *S. aureus*.

CONCLUSION

The results of this study demonstrated that the meibomian glands of eyelids with a prosthetic eye are more likely to be lost. As a result, deterioration and loss of normal anatomical structures may result in obstructive MGD, which has been significantly linked to dry eye ocular symptoms.

Ethical Approval:

As per international standard or university standard written ethical approval has been collected and preserved by the author(s).

Consent

As per international standard or university standard, patient(s) and parental written consent has been collected and preserved by the author(s).

REFERENCES

1. **FitzPatrick DR and van Heyningen V.** Developmental eye disorders. Current opinion in genetics & development. 2005;15(3):348-53.
2. **Kitzmann AS, Weaver AL, Lohse CM et al.** Clinicopathologic correlations in 646 consecutive surgical eye specimens, 1990-2000. 2003;119(4):594-601.
3. **McBain HB, Ezra DG, Rose GE et al.** Appearance Research Collaboration (ARC). The psychosocial impact of living with an ocular prosthesis. Orbit 2013, 33, 39–44.
4. **Modugno A, Mantelli F, Sposato S et al.** Ocular prostheses in the last century: A retrospective analysis of 8018 patients. Eye 2013, 27, 865–870.
5. **Zigiotti GL, Cavarretta S, Morara M et al.** Standard enucleation with aluminium oxide implant (bioceramic) covered with patient’s sclera. Sci. World J. 2012, 2012, 481584.

6. **Del Castillo JMB, Kaercher T, Mansour K et al.** Evaluation of the efficacy, safety, and acceptability of an eyelid warming device for the treatment of meibomian gland dysfunction. *Clinical Ophthalmology (Auckland, NZ)*, 2014, 8, 2019.
7. **Altin ME, Karadeniz SU, Kahraman HG et al.** Meibomian Gland Dysfunction and Its Association with Ocular Discomfort in Patients with Ocular Prosthesis. *Eye Contact Lens* 2019,46(5),285-290
8. **Jang SY, Lee SY and Yoon JS.** Meibomian gland dysfunction in longstanding prosthetic eye wearers. *Br. J.Ophthalmol.* 2013, 97, 398–402
9. **Jones CA and Collin JR.** A classification and review the causes of discharging sockets. *Trans. Ophthalmol. Soc. UK* 1983, 103, 351–353.
10. **Malhotra, R.** Ocular prostheses: Not quite an eye for an eye. *Br. J. Ophthalmol.* 2013, 97, 383–385.
11. **Arita R, Itoh K, Inoue K et al.** Noncontact infrared meibography to document age-related changes of the meibomian glands in a normal population. *Ophthalmology* 2008, 115, 911–915.
12. **Sajjad A.** Ocular prosthesis-a simulation of human anatomy: a literature review. *Cureus.* 2012;4(12).
13. **Pult H and Riede-Pult B.** Comparison of subjective grading and objective assessment in meibography. *Contact Lens and Anterior Eye.* 2013;36(1):22-7
14. **Meduri A, Frisina R, Rechichi M et al.** Prevalence of Meibomian Gland Dysfunction and Its Effect on Quality of Life and Ocular Discomfort in Patients with Prosthetic Eyes. *Prosthesis.* 2020;2(2):91-9.
15. **Rokohl AC, Adler W, Koch KR, et al.** Cryolite glass prosthetic eyes-the response of the anophthalmic socket. *Graefes Arch ClinExpOphthalmol.* 2019;257(9):2015-23.
16. **Redlich FC, Callahan A and Schmedtje JF.** Electrical potentials from eye movements. *The Yale journal of biology and medicine.* 1946;18(4):269.
17. **Toribio A, Marrodán T, Fernández-Natal I, et al.** Conjunctival flora in anophthalmic patients: microbiological spectrum and antibiotic sensitivity. *Int J Ophthalmol.* 2019;12(5):765-73.

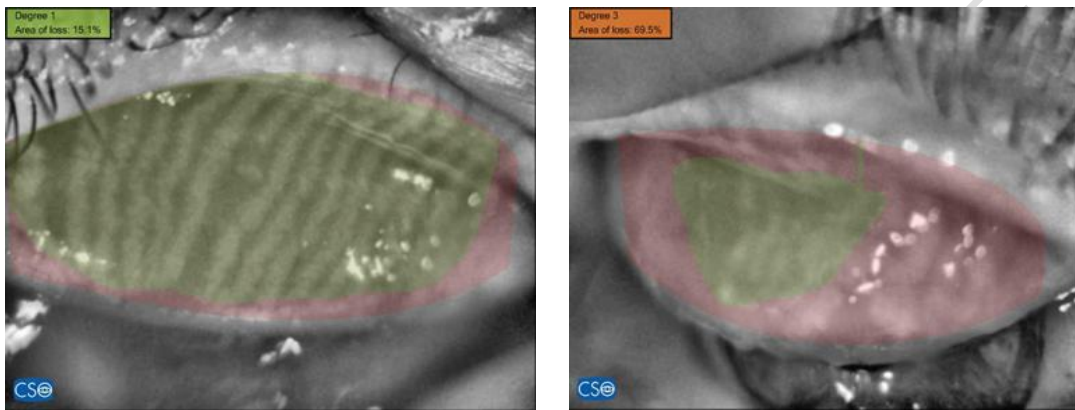


Figure (1): Meibography of upper eye lid in normal eye and prosthetic eye respectively in the same patient

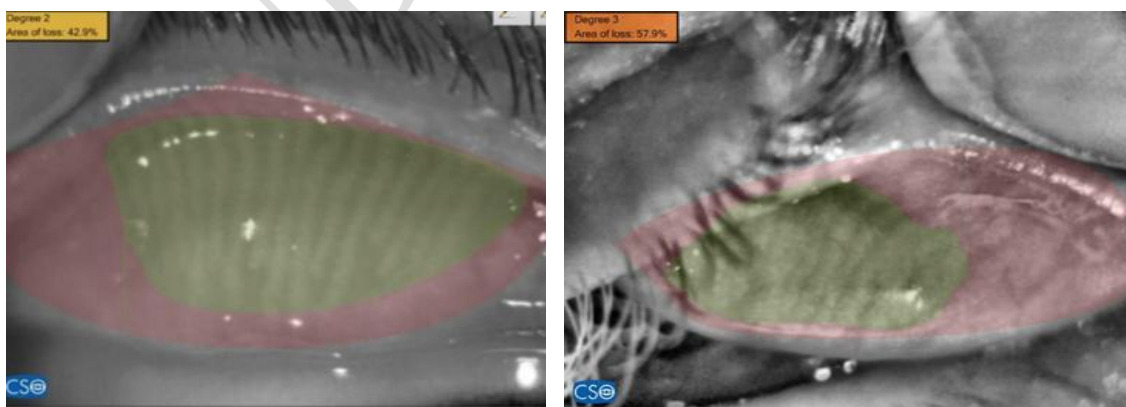


Figure (2): Meibography of upper eye lid in prosthetic eye <10 years and >10 respectively in different patients

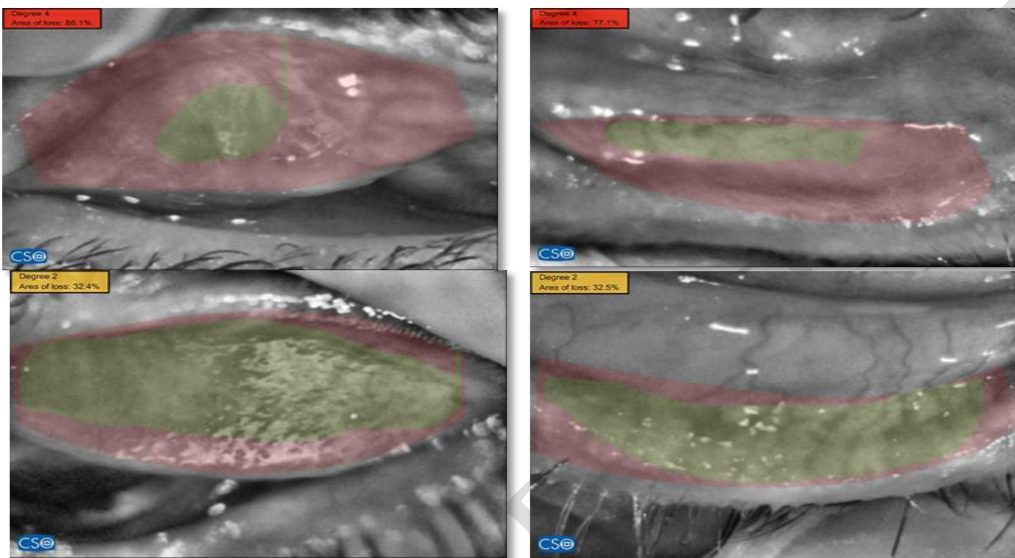


Figure (3) : Case 1. male patient aged 55 years old underwent evisceration surgery in his right eye because of trauma 15 years ago and wore PMMA prosthetic eye after that. Meibography imaging was done to prosthetic eye and normal eye respectively.

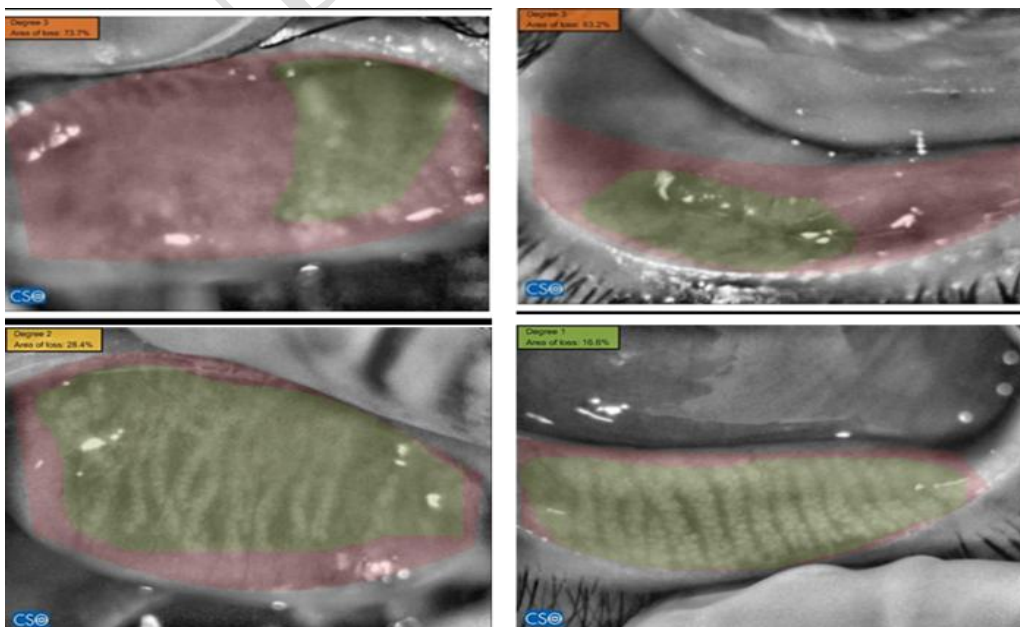


Figure (4) : case 2. Representative photographs showing Female patient aged 45 years old underwent evisceration surgery in her right eye 9 years ago and wore PMMA prosthetic eye.

Table 1: Demographic Data

Demographic Data	
Age	38.18 ± 18.59
Sex	Male 17 Female 23
Cause of eye removal, number of patients (%)	Trauma 72.5 % Absolute glaucoma 15.0 % Other diseases 12.5 %
Type of operation, number of patients (%)	Evisceration 92.5 % Enucleation 7.5 %
Duration of prosthesis (years)	<10 years 52.5 % ≥10 years 47.5 % 10.20 ± 7.18

Table 2: Comparison of structural changes in the meibomian gland between eyelids with an ocular prosthesis and paired normal eyelids:

	Normal eye	Prosthetic eye	p value
Lid margin abnormality score			
Upper lid	0.65 ± 0.86	1.58 ± 1.22	<0.001 *
Lower lid	0.73 ± 0.96	1.73 ± 1.18	<0.001 *
Meibomian gland expression			
Upper lid	1.0 (1.0 – 2.0)	2.50 (1.0 – 4.0)	<0.001 *
Lower lid	2.0 (1.0 – 3.0)	3.0 (1.0 – 4.0)	<0.001 *

Meibography score			
Upper lid	1.0 (1.0 – 2.0)	3.0 (1.0 – 4.0)	<0.001*
Lower lid	2.0 (1.0 – 3.0)	3.0 (1.0 – 4.0)	<0.001*

Table 3 :Comparison of score of lid examination in prosthetic eye in the groups categorised by duration of the prosthesis use (<10 years and ≥10 years)

Duration of prosthetic eye had been worn	<10 years (n=21)	≥10 years (n=19)	U	p
Score of lid exam				
Upper lid				
Min. – Max.	0.0 – 4.0	0.0 – 4.0		
Mean ± SD.	1.14 ± 1.15	2.05 ± 1.13	113.50*	0.019*
Median (IQR)	1.0 (0.0–2.0)	2.0 (1.0–3.0)		
Lower lid				
Min. – Max.	0.0 – 4.0	1.0 – 4.0		
Mean ± SD.	1.33 ± 1.11	2.16 ± 1.12	125.0*	0.044*
Median (IQR)	1.0 (0.0–2.0)	2.0 (1.0–3.0)		
Sum of upper and lower lid				
Min. – Max.	0.0 – 8.0	1.0 – 8.0		
Mean ± SD.	2.48 ± 2.20	4.21 ± 2.23	116.50*	0.023*
Median (IQR)	2.0 (0.0–4.0)	4.0 (2.0–6.0)		

Table 4: Comparison of Meibomian gland expression score in the groups categorized by duration of prosthesis use (<10 years and ≥10 years)

Duration of prosthesis use	<10 years (n=21)	≥10 years (n=19)	U	p
Meibomian gland expression score				
Upper lid				
Min. – Max.	1.0 – 4.0	2.0 – 4.0		
Mean ± SD.	1.95 ± 1.02	3.0 ± 0.88	92.50*	0.003*

Median (IQR)	2.0 (1.0–3.0)	3.0 (2.0–4.0)		
Lower lid				
Min. – Max.	1.0 – 4.0	2.0 – 4.0		
Mean ± SD.	2.48 ± 0.68	3.32 ± 0.67	83.500*	0.001*
Median (IQR)	2.0 (2.0–3.0)	3.0 (3.0–4.0)		
Sum of upper and lower lid				
Min. – Max.	2.0 – 8.0	4.0 – 8.0		
Mean ± SD.	4.43 ± 1.50	6.32 ± 1.42	77.500*	0.001*
Median (IQR)	5.0 (3.0–5.0)	7.0 (5.0–7.50)		

Table 5: Comparison of Meibography score in the groups categorized by duration of the prosthesis use (<10 years and ≥10 years)

Duration of prosthetic eye had been worn	<10 years (n=21)	≥10 years (n=19)	U	p
Meibography score				
Upper lid				
Min. – Max.	1.0 – 4.0	2.0 – 4.0		
Mean ± SD.	1.95 ± 0.97	3.11 ± 0.81	79.0*	0.001*
Median (IQR)	2.0 (1.0–3.0)	3.0 (2.50–4.0)		
Lower lid				
Min. – Max.	1.0 – 4.0	2.0 – 4.0		
Mean ± SD.	2.48 ± 0.68	3.32 ± 0.67	83.50*	0.001*
Median (IQR)	2.0 (2.0–3.0)	3.0 (3.0–4.0)		
Sum of upper and lower lid				
Min. – Max.	2.0 – 8.0	4.0 – 8.0		
Mean ± SD.	4.43 ± 1.50	6.42 ± 1.39	69.0*	<0.001*
Median (IQR)	5.0 (3.0–5.0)	6.0 (5.50–8.0)		