

Original Research Article

**EFFECT OF AQUEOUS EXTRACT OF CANNABIS SATIVA ON THE HISTOLOGY
OF THE CEREBRAL CORTEX OF ADULT ALBINO RAT**

ABSTRACT

Cannabis sativa, also known as weed, hemp or marijuana is a drug made from the plant sativa. The effect of aqueous extract of *cannabis sativa* on the histology of the cerebral cortex of the adult Wistar rats is the subject of this study. Twenty male Wistar rats were divided into 4 groups (A-D). Group A served as Control and received food and water. Group B, C and D received 500mg/kg, 750mg/kg and 900mg/kg of the extract per body weight respectively for 28 days. The rats' weights were taken initially and at the end. Rats were sedated by chloroform vapour and blood was collected via ocular puncture. Animals were sacrificed and the brains harvested and fixed in Bouin's solution for histological studies using H&E. Histological observation showed that the cerebral cortex of the control group showed normal molecular and granular layers with normal pyramidal cells. Rats treated with 500mg/kg extract of cannabis sativa showed lymphocytic cuffing and neuroglial spacing and congestion of vascular channels. Rats treated with 750mg/kg extract of cannabis sativa showed multi-focal congestion of vascular channels. The rats treated with 900mg/kg of the extract of cannabis sativa showed perivascular congestion and lymphocytic infiltration. Hematological analysis showed a significant decrease of the white blood cells in the experimental animals than in the control with $p < 0.05$. Other haematological parameters were not significantly different in the experimental groups compared to the control. The result showed that the consumption of cannabis sativa lowered white blood cell count and impaired the histoarchitecture of the cerebral cortex.

Keywords: Cannabis sativa, Cerebral cortex, weed, haematology, marijuana

INTRODUCTION

Cannabis sativa also known as weed, hemp, blow, pot, grass, puff, marijuana among many others refers to a number of preparations of *cannabis sativa* intended for use as a psychoactive drug (John, 2010). The typical form of herbal cannabis consists of the flowers and subtending leaves and stalks of the matured pistil female plant, while the resinous form of drug is known as hash (John, 2010). Marijuana is the common name of a crude drug made from the plant sativa. The main active ingredient in marijuana is THC known as the delta-9-tetrahydrocannabinol. The

amount of THC in the marijuana determines how strong its effects will be. Also, the type of plant, weather, the soil, the time of harvest and other factors ensures that the strength of today's marijuana is as much as ten times greater than the marijuana used in the early 1970s. This potent marijuana increases physical and mental effects and possibility of health problem for the users. (Matthew, 2007). Hashish or hash is made by taking the resin from the leaves and flowers of the marijuana plant and pressing it into cakes or slabs. Hash is usually stronger than the crude marijuana, and may contain five to ten times as much as THC.

Marijuana is the most widely used illegal drug in the world. It is a dry shredded green brown mix of flowers, stems, and leaves, of the plant *cannabis sativa*. It is typically smoked in cigarette hollowed out cigars (blunts), pipes (blows) or water pipes. Some people mix it with foods or brew it into tea (Matthew, 2007; Novak *et al*, 2001). The flowers and to a lesser extent the leaves, stem and seeds contain psychoactive and physiological active chemical compounds known as cannabinoids that are consumed for recreational, medicinal and spiritual purpose. When so used preparation derived from resinous extract is consumed by smoking, vaporizing and oil ingestion. Histological tinctures, teas and ointments have been commonly prepared with cannabis. The cannabis plant in the vegetative growth phase of life requires more than 12-13 hours of light per day to stay vegetative. In the soil the optimum PH for the plant is 6.3 to 6.8 in hydro panic growing the nutrient solution is best at 5.2 to 5.8 making cannabis well suited to hydroponics because PH range is hostile to most bacteria and fungi. (Novak *et al*, 2001). The flowers and to a lesser extent the leaves, stems, and seeds of *cannabis sativa* contain psychoactive and physiological active chemical compounds known as cannabinoids that are consumed for recreational, as medicine and for spiritual rituals (West, 1998). The medicinal use of this plant includes the treatment of glaucoma, depression and to relieve the nausea associated with the cancer treatment. (Foster *et al*, 1990).

Approximately 44% of the weight of the hempseed is healthy edible oils, containing 80% essentially fatty acids (line oleic acid, omega 6 of 55%, protein is the major component, its amino acid profile is close to complete when compared to more common source of protein such as meat, milk, egg and soy. It is an adequate source of dietary fiber, calcium, and contains antioxidants and chlorophyll. The whole seed are also good source of phosphorous, magnesium, zinc, copper, and manganese, in facts hemp foods has no known allergies (Van Roekele *et al*, 1994).

Life time cannabis use has been reported to be as high as 64.4% in patient with schizophrenia (Barnes *et al*, 2006; Loberget *al*, 2003). It was found out that 45% of schizophrenia patients participating in research studies had a history of previous cannabis use. Since cannabis may be a risk factor for schizophrenia mediated changes, cannabis may also have an effect on cognitive functioning in this patient group. Studies have reported an increase risk for schizophrenia and other psychoses after cannabis use (Andreasson *et al*, 1878) and (Zammit *et al*, 2002). In one study, cannabis use at age 18 and 21 led to 3.7 and 2.3 higher rates of psychotic symptoms respectively (Fergusson *et al*, 2003). The endogenous cannabinoid system interacts with the

dopaminergic system of the brain, and THC influences dopamine synthesis and uptake. Increased level of endogenous cannabinoids has been found in the frontal cortex. (Dean *et al*, 2001). In addition to elevated levels of endogenous cannabinoids in the cerebral spinal fluids (Leweke *et al*, 1999), a stronger relationship between adolescent cannabis use and psychosis or schizophrenia as compared to adult use has been reported (Caspier *et al*, 2005). Even though some of these findings can be explained by an increased cumulative exposure to cannabis with earlier onset of cannabis use, it may also suggest that a developing brain is more vulnerable to effects of cannabis than a matured brain.

General population epidemiological studies have consistently found that cannabis use increases the risk of developing psychosis disorder in a dose dependent manner while the epidemiological signal between cannabis and psychosis has gained considerable attention, the biological mechanism whereby cannabis increases risk for psychosis remain poorly understood. Animal research suggests that delta 9 tetrahydrocannabinol increases dopamine level in several regions of the brain, including striatal and prefrontal area. Since dopamine is hypothesized to represent a crucial final pathway between the brain biology and actual experience of psychosis, a focus on dopamine may initially be productive in the examination of the psychosomatic effects of cannabis. Therefore, this review examines the evidence concerning the interactions between THC, endocannabinoids and dopamine in the cortical as well as the sub cortical regions implicated in psychosis and considers dysregulation may give rise to delusions and hallucinations. (Kupper *et al*, 2010). It is concluded that further study of the mechanisms underlying the link between cannabis and psychosis may be conducted productively from the perspective of progressive developmental sensitization, resulting from gene environment interactions. (Kupper *et al*, 2010).

Cannabinoids derived from herbal cannabis interact with endogenous cannabinoid systems in the body. Actions on specific brain receptors cause dose dependent impairments of psychomotor performance with implications for car and train driving, aero plane piloting and academics performance. Other constituents of cannabis smoke carry respiratory and cardiovascular health risks similar to those of tobacco smoke (Heather *et al*, 2001).

The short term effects of cannabis manifest within seconds and are fully apparent within a few minutes. Some of the short term physical effects of cannabis ingestion include increase in heart rate, dry mouth, reddening of the eye, reduction in intraocular pressure, muscle relaxation, and a sensation of cold or heat on the hands and feet. However, chronic use is not associated with some cardiovascular risk factor such as blood triglycerides levels and blood pressure. The long term effects on memory is preliminary and hindered by confounding factors and the risk with long term use increase risk for schizophrenia, bipolar disorder and depression but the ultimate conclusion of these factors are disputed (Ranganathan *et al*, 2006). In 1990, the discovery of cannabinoid receptors located throughout the brain and the body, along with endogenous

cannabinoid neurotransmitters like anandamide, a lipid material derived ligand from arachidonic acid suggest that the use of cannabis affects the brain in the same manner as a naturally occurring brain chemical.

Cannabinoid receptors are of two types; CB1 and CB2. The CB1 is found in the brain and mediates the psychological effects of THC. The CB2 receptors are most abundantly (found on the cells of the immune system. Cannabinoids acts as immunomodulators at CB2 receptors. (Pertwee, 1997). The areas of the brain where the cannabinoid receptors are most prevalently located are consistent with the behavioral effects produced by cannabinoids. Brain regions in which cannabinoid receptors are very abundant are the basal ganglia, associated with the movement control, the cerebellum, associated with the body movement coordination; the hippocampus associated with learning, memory and stress control; the cerebral cortex associated with higher cognitive functions; and the nucleus accumbens, regarded as the reward as the reward centre of the brain. (Riedel *et al*, 2005). The feeling of increased appetite following the use of cannabis has been documented for hundreds of years, and is commonly known as 'munchies'. Clinical studies and survey have found that cannabis increases food enjoyment and interest in food. Scientists have attempted to explain what causes the increase in appetite, including how the action of endocannabinoids in the hypothalamus activates cannabinoid receptors that are responsible for maintaining food intake. Endogenous cannabinoids have recently been found in foods such as chocolate and human and bovine milk. It is possible that cannabinoid receptors in our body interact with the cannabinoids in milk to stimulate a suckling response in newborns so as to prevent growth failure (Moelker *et al*, 2008).

Marijuana is one of the most abused drugs all over the world by both youths and adults. However research report relating directly to the effect of marijuana to the cerebral cortex needs further investigation. Hence, this research is aimed at studying the effect of the aqueous extract of cannabis sativa on the histology of the cerebral cortex.

Comment [DAL1]: Very long Introduction!
Please give an essential information!

MATERIALS AND METHODS

Materials

Some materials used for the research include but not limited to; the plant material used for this research is cannabis sativa which was obtained from the locals in Nnewi North, Anambra state. Hematoxylin, eosin, glycerol, ethanol, xylene, Canada Balsam, Forceps, Scissors, Surgical blades, weighing balance, measuring cylinder, beakers, acetic acid picric acid, formaldehyde, hot air oven, microtome, hot plate, 1-mould plate, t-olympus, sample bottles, dissecting sets, glass

slides, coverslips, waterbath, refrigerator, oven, dissecting board, paraffin wax, sodium bicarbonate, hydrochloric acid, feeding/ intubating tube, beakers(5ml), anticoagulant bottles, cages , rats, towels, cannabis sativa, Bouin's fluid, automatic tissue processor, scott tap water, vital feeds, distilled water, turks solutions, neubal counting chamber, capillary tube, hematograde, centrifuge, reader, diferencia, leshmansten slides staining rack and calorimeter.

EXTRACTION OF CANNABIS SATIVA

297g of cannabis sativa was taken to the Human Anatomy, Histology Laboratory. It was grinded, yielding 292g to fine powder. The powdered form was soaked in a beaker and 2000ml (2litres) of water was added and vigorously shaken. The mixture was kept was 24 hours after which it was shaken intermittently for another 4 hours. The mixture was sieved using Whatman's No.1 filter paper into a round bottom flask and embedded in a hot water bath set at 63 °c to evaporate the water content. After successful evaporation, a gummy material weighing 27.2g was obtained. The stock solution was then prepared at the rate of 1mg/10ml of distilled water.

EXPERIMENTAL PROCEDURES

Twenty (20) male albino rats of the Wistarstrain weighing 110 – 230g were obtained from the animal farm of the department. They were assigned to 4 groups (A,B,C & D) of 5 rats each based to relativity to weight. They were housed in plastic cages under standard Laboratory condition. They were fed pelletized rat chow and tap water ad libitum throughout the period of the experiment and were initially to acclimatized for 14 days. Rats were fed with standard laboratory diet (vital feeds) which was obtained from grand cereals and oil mills limited a subsidiary of VACN vital feed contain ingredient like cereals/ Grains, Animals proteins, vegetable protein, Mineral salt, Essential amino acids, Antibiotic, Antioxidants, Vitamin premix. The constituents are crude protein (14.50%), fat (7.00%), crude fiber (7.20%), calcium (0.80%), available phosphorous (0.40%), metabolizable energy (2500k car/kg). Group A served as control while groups B-D served as the experimental groups and received 500, 750, and 900mg/kg respectively.

ADMINISTRATION OF EXTRACT

In the cause of this study oral administration was used based on their body weight. Twenty albino rats were used for this study the rats were grouped into four A-D of five each. Each rat was marked with picric acid for identification. Group A served as the control group and was feed with normal feed and distilled. Group B received 500mg/kg of cannabis sativa extract, Group Creceived 750mg/kg and Group Dreceived900mg/kg of the extract. Twenty four hours after the last administration, the rats were weighed and sedated by chloroform inhalation and blood

collected via ocular puncture. Afterwards, rats were sacrificed by cervical dislocation and the brain was harvested and immediately fixed in Bouin's solution for histological procedures using H&E.

STATISTICAL ANALYSIS

Numerical data obtained from this study were expressed as Mean \pm S.E.M for the Control and treated grouped using InStat 3 Graphed for the statistical analysis 1998 Version. A probability level of p greater than 0.05 ($P < 0.05$) was considered significant.

Comment [DAL2]: Where did you inspire? In the literature? Please indicate the authors!

RESULT

PHYSICAL OBSERVATION

During the administration of cannabis sativa, rats showed some physical changes such as hyperactivity, increased appetite and higher rate of food consumption. Animals in control did not show any of these physical changes.

Table 1 Effect of *Cannabis sativa* extract on the Mean Body Weight of Rat

GROUP	INITIAL BODY WEIGHT (g)	FINALBODY WEIGHT(g)	DIFFERENCEIN BODY WEIGHT
A	226.52 \pm 4.554	249.12 \pm 9.739	22.6
B	143.56 \pm 12.336	157.44 \pm 12.124	13.88
C	154.44 \pm 7.313	172.24 \pm 9.914	17.8
D	152.56 \pm 6.492	159.34 \pm 6.649	14.86

The result in table 3 showed that there is no significant difference in mean body weight of the rats treated with cannabis extract of 500, 750 and 900mg/kg, compared to the control with their p value= 0.5155 which shows $p > 0.05$.

HEMATOLOGICAL ANALYSIS

Table 2:RESULT OF HAEMATOLOGICAL PARAMETERS

GROUP	PCV	HB	WBC	NEUTROPHIL
A CONTROL	0.336±0.04632	11.88±1.624	9.22±1.325	63.4±2.713
B (500g)	0.452±0.01393	15.14±0.4792	14±0.7071	61.6±3.669
C (750g)	0.464±0.01806	15.28±0.5616	13.06±1.415	66.6±3.400
D (900g)	0.402±0.02131	13.54±0.6961	11.26±0.7250	65.6±2.315
P VALUE	0.5102 (NS)	0.0904 (NS)	0.0129 *	0.7035

* Indicates statistical significance NS indicates Not Significant

The result of the blood analysis shown in table 2 indicates no significance difference in the Packed Cell Volume (PCV) between the experimental groups and the control. The result also showed hemoglobin (HB) has no significant difference in the experimental groups compared to the control. The same can be said about neutrophil but not White Blood cells which showed a significant increase in the experimental groups compared to the control.

Table 3: Results of Lymphocytes, Monocytes, Basophil, and Eosinophil.

GROUP	LYMPHOCYTES	MONOCYTES	BASINOPHIL	ESINOPHIL
A CONTROL	35.8±2.375	1.4±0.2449	1.4±0.2449	1.4±0.2449
B (500g)	36.6±4.389	3.0±0.7071	1.4±0.2449	1.6±0.2449
C (750g)	33.2±3.262	1.6±0.2449	1.2±0.2000	1.4±0.5477
D (900g)	33.2±2.417	1.6±0.2449	1.6±0.2449	1.4±0.2449
P VALUE	0.8766 (NS)	0.0650 (NS)	0.999 (NS)	0.5796 (NS)

* Indicates statistical significance NS indicates Not Significant

The results in the table 3 showed no significant difference in the blood parameters neutrophils, lymphocytes, monocytes, basophil and eosinophils, in the experimental groups compared with the control with p value greater than 0.05($p > 0.05$).

4.3 HISTOLOGICAL OBSERVATION.

The histological observation showed that the nuclei stained blue black because of the haematoxylin and the cytoplasm gave a red color because of the stain of eosin. The cerebral cortex of rats treated with 500mg/kg of cannabis extract showed lymphocytic cuffing, neutrophil spacing, and congestion of vascular channel in Plates 1& 2. The rats treated with 750mg/kg cannabis sativa extract showed multi focal congestion of vascular channel as shown in Plate 4.

The rats treated with 900mg/kg of extract showed in Plate 4& 5 showed perivascular congestion and lymphocytic infiltration.

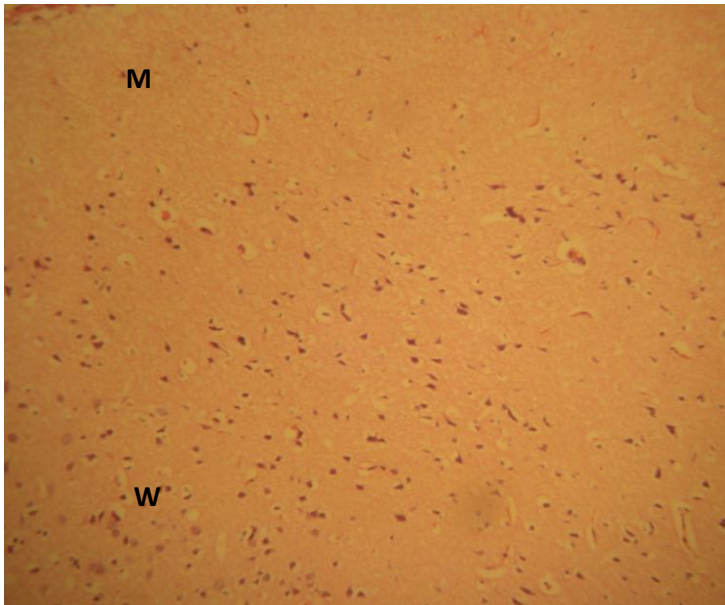


Plate 1: Photomicrograph of cerebral cortex of rats in control group At showing normal molecular layer (M) and granular layer (W) H&E x200.

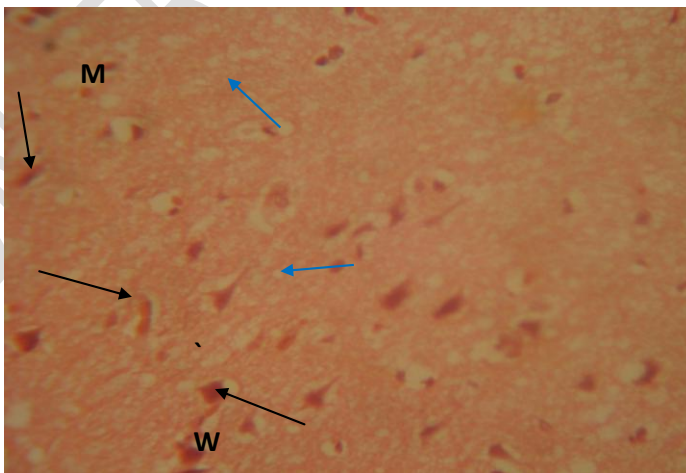


Plate 2: Photomicrograph of cerebral cortex of Control (higher magnification) showing normal molecular layer (M), granular player (W) with pyramidal cells (arrows) and neuroglial cell nucleus (Blue arrows) H&E x400.

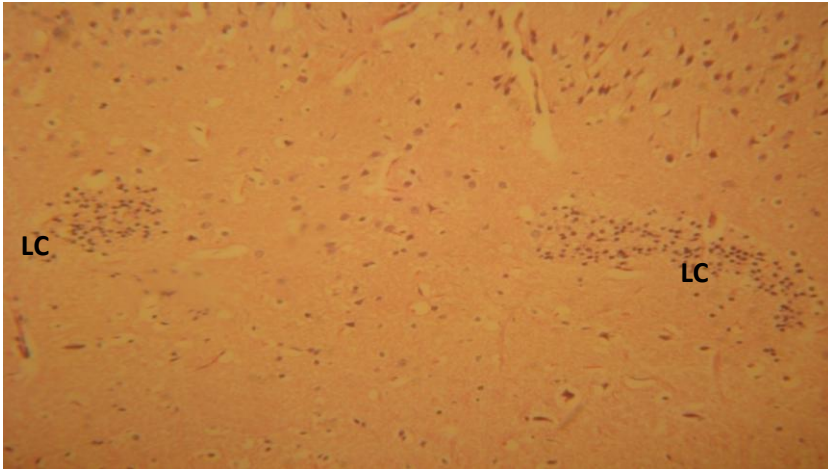


Plate 3: Photomicrograph of cerebral cortex of rat in group B showing lymphocytic cuffing (LC) H&E x100

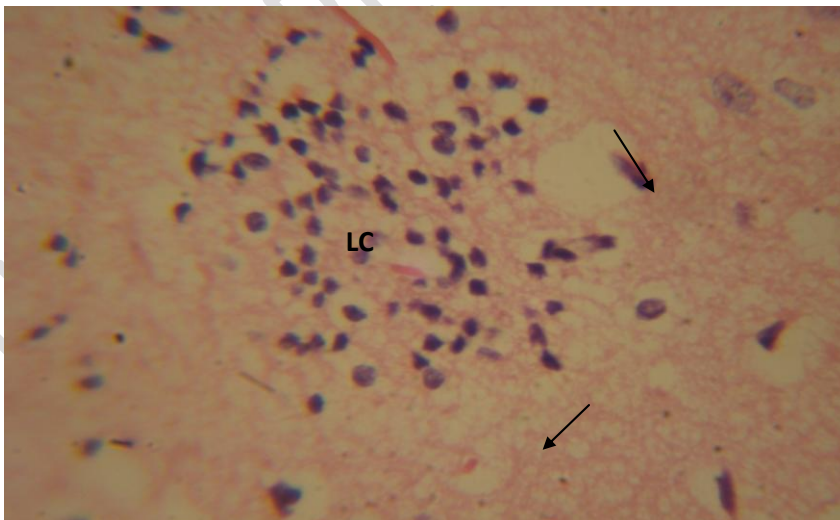


Plate 4: Photomicrograph of cerebral cortex of rat brain showing lymphocytic cuffing (LC) and neurophil space (arrows) H&E x100

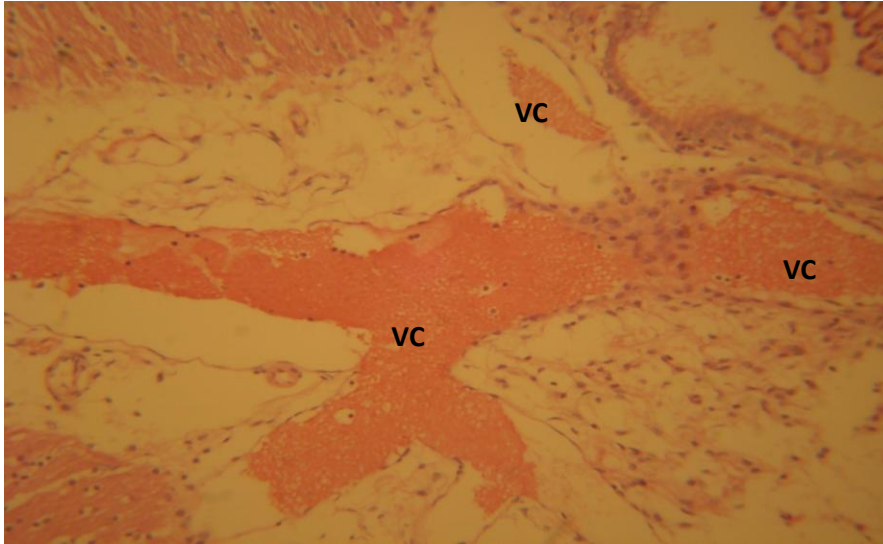


Plate 5: Photomicrograph of cerebral cortex of rat brain from group C showing multi-focal congestion of vascular channel (VC) H&E x400

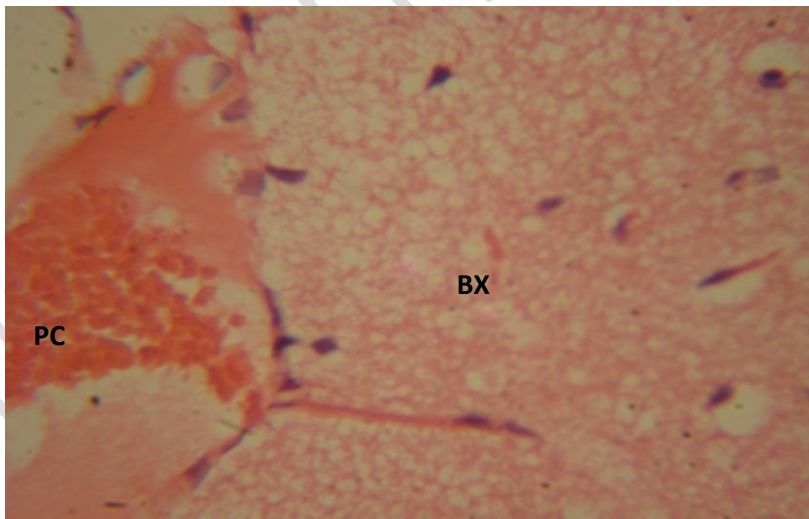


Plate 6: Photomicrograph of cerebral cortex of rat brain from group D showing perivascular congestion (PC) H&E x400.

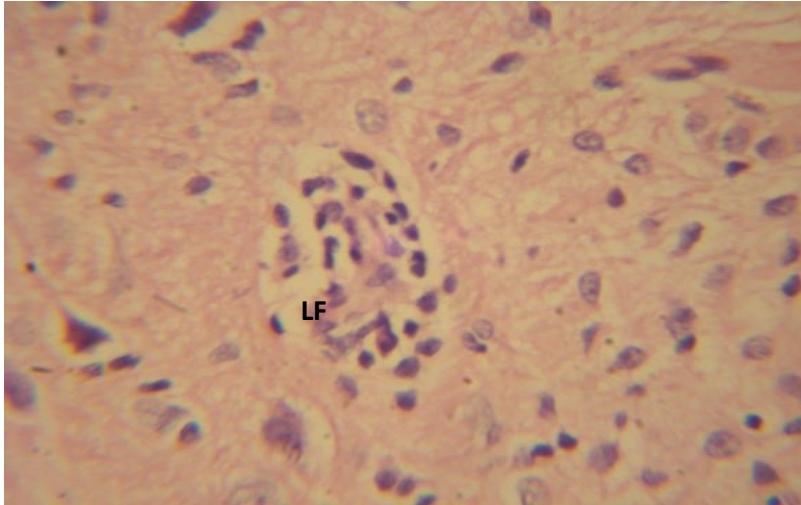


Plate 7: Photomicrograph of cerebral cortex of rat brain in group D (higher magnification) showing lymphocytic infiltration (LF) H&E x400

DISCUSSION AND CONCLUSION

The histological observation of the sectioned cerebral cortex showed that rats administered with 500mg/kg of the extract showed lymphocytic cuffing and that of medium dose group of 750mg/kg of extract showed multifocal congestion of vascular channel. The administration of 900mg/kg of the extract showed perivascular congestion as well as lymphatic infiltration. This study is in agreement with the study conducted by Unaet *al*, (1997) who reported that there were changes in the neurons in selected brain regions following exposure to cannabis. Andreas *et al*, (2005) also reported morphological distortion in the basal lamina of the brain of polyusers.

The lymphocytic cuffing is the accumulation of lymphocytes or plasma cells in a dense mass around a vessel which shows an indication of inflammation or of an immune reaction of the cerebral cortex. The multifocal congestion of vascular channel, also known as a progressive multifocal leukoencephalitis is a rare and usually fatal viral disease that is characterized by progressive damage or inflammation of the white matter of the brain at a multiple location of the white matter of the brain (multifocal). It occurs almost exclusively in people with severe immune deficiency (Jaime et al 2009).

The hematological analysis showed decrease in white blood cells count. A normal white blood cell count range from 4,500 to 10,000 cells per microliters of blood while any count below 2500

means that the body is at an increased risk of infection, disease or medication. That also makes the body become more vulnerable to bacteria and viruses (Amber, 2008). These findings have therefore revealed that administration of the aqueous cannabis extract could cause varying degrees of neurodegenerative changes in the cerebral cortex of albino rats.

5.2 CONCLUSION

Based on the above findings, it can therefore be concluded that consumption of cannabis sativa extract could cause severe damage to the cells in the cerebral cortex and impair blood cell count, especially the white blood cells.

REFERENCES

Andreas Butter, Claus Kroehling, Crita Mall, Randolph Penning and Serge well (2005). Institute of Legal Medicine Ludwig Maximilians University, Frauenlobstrasse 7a, 80337 Munich, Germany.

Andreasson, S. Albeck, P. Engstrom, A and Rydberg (1878) Cannabis and Schizophrenia. A longitudinal study of Sweden *Conscript Lancet* 2: 1483- 1486.

Arseneault, L. Williams, B. Bruithwaite, A. Poulton, R and Craig, i.w (2005). Moderation of the effects of adolescent onset cannabis use on adult psychosis by a functional polymorphism in the catechol-o-methyltransferase gene; Longitudinal evidence of a gene X- Environment Interaction *Biol psychiatry* 57: 1117-1127.

Barbara young, John W. Heath, Wheaters functional histology, (2006) 4th edition *Human Neuroanatomy*, 263-274.

Barnes, T. R. Mutsatsa, S. H. Hutton, S. B. Watt, H. C. and Joyce E. M. (2006) Comorbid substance use and agent of schizophrenia.

Chambers, R. A. Krystal, J. H. and Self D. W. (2001). A neurobiological Basis of substance abuse comorbidity in schizophrenia, *Biol psychiatry* 50: 71- 83.

C. Heather Aston FRCP, Emeritus Professor of clinical Psychopharmacokinetic (2001). University of Newcastle upon Tyne, Department of psychiatry, Royal Victoria Infirmary Newcastle 178: 101-106.

Dean B, Sundrams, Bradbury R, Scarr, E and Copolov D. (2001) studies on (L3H), CP- 55940 binding in the human Central nervous system: Regional specific changes in density of cannabinoid 1- receptors associated with schizophrenia and cannabis use. *Neuroscience* 103: 9-15

D'Souza, D,c, Abisaab, W. m Madonick, S, ForselusBielen
K. Doersch A. Braley G. GueorguievaR.cooperT.b and Kryatal J.H (2005)
Delta 9- tetrahydrocannabinol effects in schizophrenia implications of
cognitions psychosis and addiction Biol. Psychiatry 57: 594-608

Essential Oils of different cultivars of Cannabis Sativa L. and their antimicrobial
activity. Flavour and Fragrance Journal 16,14: (259-262). Florida 1996-2010

Fergusson, D.M Horwood, L.J and Swain Campbell, N.R(2003). Cannabis
dependence and psychotic symptoms in young people. Psycho Med 33: (15- 21).

Foster, Steven and Duke, James A. (1990) Boston Hough Mifflin ISBN 395-467. 225

Fusarpoli;P. cripa, J.A Bhattacharry, S. Borgwardt, S.J Allen, P Martin- Santos,
R. seal, M. surguladze, S.ao'carol, C. Atakan, Z. Zuarch, A.W and Mc

Guire, P.k (2009) Distinct effects of delta 9- tetrahydrocannabinol and
Cannabidiol on neuroactivation during emotional processing Arch gen
psychiatry 66: 95-105.

Inderbir Singh, G.P. Pal (2004) Human Embryology, 330-331

Inderbir Singh, (2006), 7th edition Human neuroanatomy, 263-74.

John H. wiersena. Cannabis sativa Information from NPGS/ GRIN Avs-grin. Gov.
Retrieved 2010.

Jaime M. Kean, Suchitra Rao, Micheal Wang and Robert L. Garcea (2009)
Seroedidermorlogy of human polymovirusphosepathog 5(3).

Kupper R, Morrison PD, van Os, J murray RM, Kennis G, Henquet C. (2010).
Department of psychiatry, EURON, maatrix University Medical Centre,
South Limburg Mental health Research and Teaching Network maastricht
Netherlands (121- 1-3):107-117.

Leweke, F.M, Giuffrida A. Wurster, U. Emrich H.M and Piomelli D, (1999).
Elevated Endogenous Cannabinoid in schizophrenia. Neuroreport 10, 1665-
1669

Linszen, D.H, Dingemans, P.M and Lemor, M.E (1994). Cannabis use and the
course of Recent onset schizophrenia disorder. Arch. Gen Psychiatry 51:
273-279.

Loberg, E.M, Jorgensen, H.A, and Hugdalie(2003). The effects of previous drug
abuse on neurocognition in schizophrenia Abstract J. Int. Neuropsychol.

Soc 9: 172

Matthew J. Atha (2001) Independent Drug Monitoring Unit. Types of cannabis Available.

Moelker, Wendy (9th September 2008). How does marijuana affect your body? What are the marijuana physical effects?

Morrison, P.D., Zois, V., Mckeown, D.A., Lee, T.D., Hoel, D.W., Powell, J.F., Kapur, S. and Murray, R.M. (2009). The acute effects of synthetic intravenous delta-9-tetrahydrocannabinol on psychosis and mood and cognitive functioning *psycho Med.* 39: 1607-1616.

Novak J, Zitter L, Egelseer K, Dean SG, Tranzcm (2001).

Pertwee, R. (1997), pharmacology of Cannabis CB1 and CB2 receptors: pharmacology and therapeutic 74:129-80.

Ranganathan, Mohini, D'souza, Deepak Cyril (2006), The acute effects of cannabinoids on memory in human *Review psychopharmacology* 188 (4). 425-44

Regier D.A., Farmer, M.E., Ral, D.s., Locke, B.Z., Keith, S.J., Judd, L.L. and Goodwin, F.K. (1990), Comorbidity of mental disorder with alcohol and other drug abuse Result from the epidemiological catchment area (ECA) study *JAMA* 264: 2511-2518.

Riedel, G., Davies S. N. (2005) cannabinoid function in learning, Memory and plasticity *Handbook of experimental pharmacology* 108: 445-477

Una D. McCann, Kelly A. Lowe and George A. R. Caurte. (1997) *Neuroscience Biological psychiatry branch Bethesda Maryland Department of Neurology John Hopkins Medical Institution Baltimore Maryland.*

Van Roekel, Gerijan J. (1994) Hemp pulp and paper Production *Journal of International Hemp Association (Wageningen).*

West. D.P. Ph.D. (2007) *Hemp and Marijuana Myths and Realities North American Industrial Hemp council.*

Zammit, s., Allebeck, P., Andreasson, S., Lundberg I and Lewis G. (2002), self reported cannabis use as a risk factor for schizophrenia in Swedish conscript of Historical cohort study *BMJ* 325, 1199.