

Case report

Intramuscular extravasation of vinblastine: a case report and review of literature

Abstract:

Extravasation accidents involving vesicant chemotherapy products can lead to severe local tissue damage and long-term functional impairment. Intramuscular (IM) extravasation is particularly concerning due to potential deep tissue damage and limited accessibility for treatment. We present a case report of an IM extravasation accident with vinblastine instead of asparaginase in a 15-year-old patient with acute lymphoblastic leukemia B. The patient did not report immediate symptoms, the MRI scans was not available immediately and the management lack of untoward recommendations. options include monitoring, saline flash out and surgical debridement. We opted for saline flash out due to the amount, the nature of the product and the location and risk of further damage. The patient showed successful recovery without further complications during a six-month follow-up. A review of the literature revealed limited number of cases reports of IM extravasation a 4 case reports in 06 patients not including our case. Treatment decisions depend on factors such as the extravasation location, drug amount, and patient health. Understanding the risk of IM extravasation and selecting appropriate management strategies are crucial for minimizing complications and promoting positive outcomes.

Keywords: Accidental, extravasation, vesicant chemotherapy, vinblastine, vincristine, intramuscular

Introduction

Extravasation accidents occur when vesicant chemotherapy products inadvertently leak into the surrounding tissue during administration. These incidents can result in severe local tissue damage, leading to delayed wound healing, necrosis, and long-term functional impairment [1]. Intramuscular extravasation accidents are particularly concerning due to the potential for deep tissue damage and the limited accessibility for decontamination and treatment. We present a case report of an intramuscular extravasation accident involving IM injection of 8 mg of vinblastine, a vesicant agent, instead of asparaginase in a 15-year-old patient with acute lymphoblastic leukemia B, along with a comprehensive review of the literature on similar cases.

Case Report

The patient was a 15-year-old girl who was diagnosed with acute lymphoblastic leukemia B 1 month prior to the incident. She was admitted to the hospital for her first course of chemotherapy. On the day of the incident, she was scheduled to receive an IM injection of asparaginase. However, due to a labeling error, the nurse accidentally injected 8 mg of vinblastine instead.

The patient did not report any pain or discomfort at the injection site 2 hours after the injection when we received her, however the IM injection was too deep to truly assess the consequences.

The patient had a thrombocytopenia due to her chemotherapy, requiring correction before any surgical intervention could be performed. After platelet transfusion, a deep intramuscular saline flush out at the site of extravasation was carried out 4 hours after the accident (Figure 1).

An MRI scan was performed 12 hours after the saline flush out and was not possible before that. The scan showed edema of the deep soft tissues within the femoral rectus muscle (Figure 2). There were also areas of defect in enhancement, which suggested that the muscle tissue had been damaged probably by the repeated passages of the cannula in the muscle during the saline flush out but also, we could

not eliminate the probability that it could be due to the vinblastine extravasation so we did close follow up and a control of the MRI two weeks later that showed that the lesions had not changed and 6 weeks later showed a regression of the lesions. The patient was followed up for 6 months and did not develop any further complications.

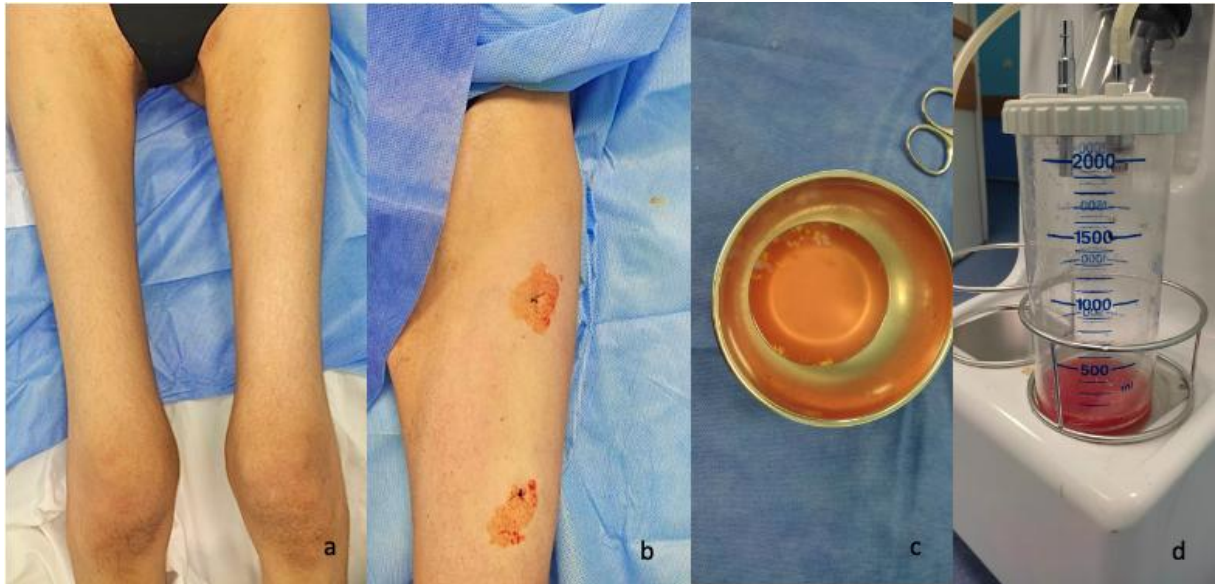

Figure 1:

a: 2 hours after the injection a 15-year-old girl admitted for her first course of chemotherapy after labeling error the nurse accidentally injected 8 mg of vinblastine into her right thigh and do not report any pain, oedema, or redness.

b: Saline flush out at the site of extravasation was carried out 4 hours after the accident deep into the femoral rectus muscle under local anesthesia.

c, d: saline flush out product

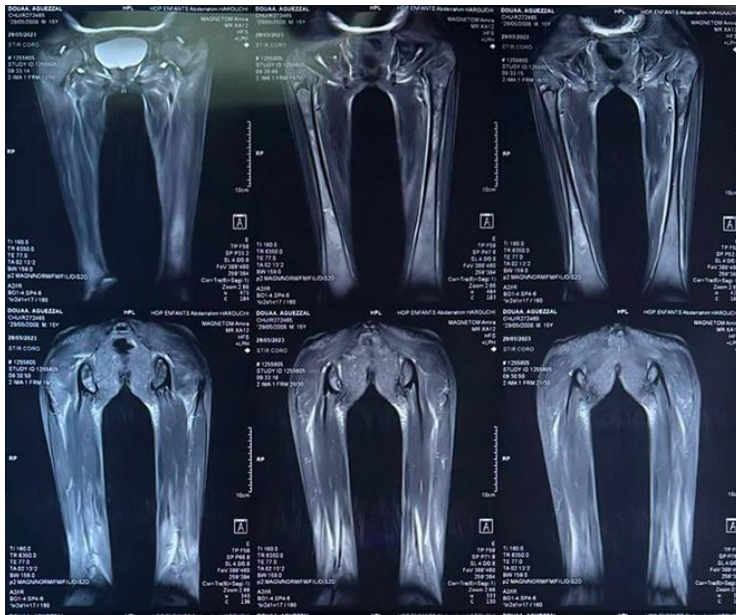


Figure 2 :MRI scan performed 12 hours after the saline flush outshowing edema of the deep soft tissues within the femoral rectus muscle.

Discussion

This case report demonstrates that IM extravasation of vesicant agents can occur, even when the drug is injected correctly. The patient in this case did not develop any immediate signs of extravasation, however, the IM injection was too deep to truly assess the immediate consequences and an MRI scan was not available at the moment.

The management of IM extravasation of vesicant agents can be similar to the management of IV extravasation. The first step is to stop the injection immediately. If the drug is still visible at the injection site, it should be aspirated, but this was not possible in this case. A cold compress should be applied to the area, and the patient should be monitored for signs of tissue damage[1].

There are three main treatments for IM extravasation of vesicant agents:

1. Wait and see with close monitoring: This is the least invasive treatment option. The patient is monitored for signs of tissue damage, and if any develop, more aggressive treatment may be necessary.
2. Saline flash out: This is a more invasive treatment option that involves injecting a large volume of saline into the area of extravasation. This helps to dilute the drug and reduce the amount of tissue damage. Saline flash out is typically performed under local anesthesia the first hours.
3. Surgical debridement: This is the most invasive treatment option and involves removing the damaged tissue. Surgical debridement is usually only necessary if the other treatment options have not been successful or if there is a significant risk of tissue loss[1].

The decision of which treatment to use depends on a number of factors, including the location of the extravasation, the amount of drug that extravasated, and the patient's overall health.

In the case of the patient in this report, the decision was made to use saline flash out because of the high amount of vinblastine injected (0.8 mg), the nature of the product injected (vesicant agent group Ib), and the extravasation occurred deep in the femoral rectus muscle, which is a large and important muscle. Surgical debridement of this muscle would have been a significant procedure, and the wait and see monitoring poses a high risk of developing complications later.

The decision to use saline flash out was a conservative approach, but it was ultimately successful. The patient did not develop any further complications.

Review of the Literature

There are a limited number of case reports in the literature describing IM extravasation of vesicant agents. In a review of the literature, we found only 04 case reports in 06 patients of IM extravasation of vincristine, vinblastine, the first one reported was in 1979 where a 50-

year-old woman with lymphosarcoma was given vincristine sulfate, 0.5 mg intramuscularly, in the right buttock by an allied health professional who mistook the drug for nandrolone phenpropionate [2].

in 1997 an accident exactly like ours was reported where Vincristine was inadvertently injected into a thigh of three children as a result of mixing syringes containing vincristine with a syringes of L-asparaginase which the patients were scheduled to receives on the same day [3].

In 2003 a seven-year-old boy with acute lymphoblastic leukemia received vincristine sulphate 1 mg, 1 ml intramuscularly, into his glutea, inadvertently, in the local hospital [4].

In 2012 an accidental IM administration of vincristine had been recognized 1 week after the first injection; and was continued for 4 consecutive days vincristine was been inadvertently administered both IM and overdose in this case [5].

The clinical presentation of extravasation of vesicant agents can vary. In some cases, patients may develop immediate signs of extravasation, such as pain, swelling, and redness. In other cases, patients may not develop any symptoms immediately [1].

The management IM extravasation of vesicant agents can be similar to the management of IV extravasation. The first step is to stop the injection immediately. If the drug is still visible at the injection site, it should be aspirated. A cold compress should be applied to the area, and the patient should be monitored for signs of tissue damage [1] sometimes depending on the location of the extravasation, the amount and nature of drug that extravasated or the patient's overall health a saline flash out or surgical debridement are proposed, the saline flash out is a less invasive procedure that involves injecting a large volume of saline into the area of extravasation. This helps to dilute the drug and reduce the amount of tissue damage. Saline flash out is typically performed under local anesthesia.

In our case we opted for saline flash out due to the amount, the vesicant nature of the drug and her location in deep femoral rectus

muscle a large and important muscle, but in our literature review no consensus were found of how to manage this accident but in the few cases reported it seem that overall, no major complications were described.

In the first case reported in 1979 Choy DS injected Within one to two minutes, through the same needle track and at the same depth, hydrocortisone, 100 mg. During the next four days, there was gradual disappearance of slight local discomfort. And on the fifth day, all signs and symptoms of this accident had disappeared [2].

Clark BS and where vincristine was inadvertently injected into a thigh of three children within minutes, each patient was treated topically with cold compresses and the area was infiltrated with a solution of 8.4% sodium bicarbonate. Only one patient had discomfort of the thigh after the injection, none of the patients have had any sequelae, either acute or delayed [3].

Olcay L, applied hot compresses for 16 hours, starting 6.5 hours after the injection. Then, she told, the slight pain and the reddened area which developed around the injection site disappeared completely and he turned back to his daily activities. His physical examination, 2 weeks after the injection and during his follow-up revealed no abnormality [4].

Patiroglu T et al, although the mistake was recognized late, a topical cold compress was applied. No Heat application or local administration of sodium bicarbonate was applied because of the prolonged period between IM injection and application [5].

conclusion

This case report highlights the potential risks of IM extravasation of vesicant chemotherapy agents.

Healthcare providers should be aware of these risks and take steps to prevent such accidents.

There are three main treatment options for IM extravasation: conservative wait and see, saline flash out, and surgical debridement.

The choice of treatment should be made on a case-by-case basis, taking into account the specific circumstances of each patient.

In our case we opted for saline flash out but in our literature review no consensus were found of how to manage this accident but in the few cases reported it seem that overall, no major complications were described.

Moreover, this report underscores the importance of sharing of similar cases in the literature to improve management protocols for IM extravasation events.

References:

[1] Pérez Fidalgo JA, García Fabregat L, Cervantes A, Margulies A, Vidall C, Roila FESMO Guidelines Working Group. Management of chemotherapy extravasation: ESMO-EONS Clinical Practice Guidelines Ann Oncol. 2012;23(Suppl 7):vii167–73.

[2] Choy DS. Effective treatment of inadvertent **intramuscular administration** of **vincristine**. JAMA. 1979 Feb 16;241(7):695.PMID: 762824.

[3] Clark BS, Gallegos E, Bleyer WA. Accidental **intramuscular vincristine**: lack of untoward effects and recommendations for management. Med Pediatr Oncol. 1997;28:314–5.

[4] Olcay L, Safak T. Inadvertent **intramuscular administration** of **vincristine**: lack of untoward effects without any treatment except **administration** of hot compresses. Pediatr Hematol Oncol. 2003;20:427–8.

[5] Patiroglu T, Unal E, Ozdemir MA, Karakukucu M, Mutlu FT. Accidental **intramuscular** overdose **administration** of **vincristine**. Drug Chem Toxicol. 2012;35:232–4.

UNDER PEER REVIEW