

*Case report*  
**Primary Mesenteric Hydatid cyst- A Rare Case report**

**Abstract**

Primary mesenteric hydatid cyst is very rare disease. Hydatid disease is most commonly caused by echinococcus granulosus in which humans are accidentally an intermediate host. The disease occurs in liver 75%, the lung 15% and 10% extrahepatic hydatid cysts at other sites such as spleen, kidney, pancreas, thyroid, brain, breast, ovary, mesentery, bones and soft tissue of body. These are rare lesions with incidence of 1:100000 in adults, and 1:20000 in children. Mesenteric hydatid cyst usually remains asymptomatic for many years. Peritoneal, mesenteric hydatid disease is a clinical challenge, presenting with cystic mass, especially in endemic areas. High resolution ultrasonography is the first line screening for mesenteric hydatid cyst. Imaging studies CT scan and ultrasonography showed a well-defined, double wall, anechoic or hypoechoic single or multiple small cyst with a honeycomb pattern with or without calcification. The best treatment modalities have been surgical excision of cyst with adjuvant Albendazole therapy is the gold standard treatment procedure.

We are reporting a 30 years old male patient complains of pain in abdomen and lump in right iliac fossa of size 10x8 cm. On ultrasonography diagnosed as a simple mesenteric cyst. On exploration, cyst was in the mesentery of small bowel and cyst completely excised. Histopathological examination showed a hydatid cyst with multiple daughter cyst inside the mother cyst.

**Keywords**

Hydatid cyst, Mesenteric cyst, Primary

**Introduction**

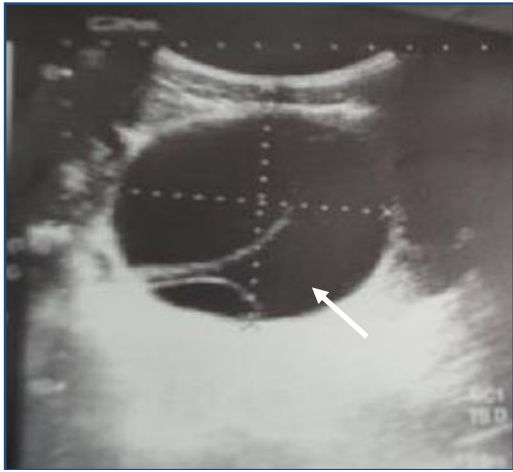
Intraperitoneal hydatid cyst secondary to rupture of primary hepatic hydatid cyst are more common. Primary mesenteric hydatid cyst is very rare. The most involved organ is liver, followed by lung, bones, kidney, spleen pancreas, skeletal muscles, peritoneal cavity, omentum and mesentery. All abdominal cystic lesion including mesenteric, pancreatic, gastrointestinal duplication cyst, ovarian cyst and lymphangioma, must be considered in the differential diagnosis. Any cyst or tumour in the mesentery can rotate and produce volvulus of the mesentery and small bowel obstruction. Clinically they may present with pain in abdomen and palpable lumps. Primary diagnosis has been done with ultrasonography and ELISA or casoni test. [1,2,7]

**Case Report**

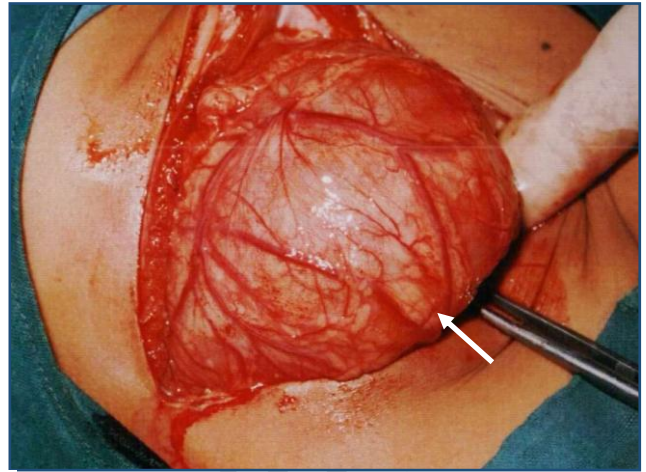
A 30 years old male patient was admitted to our centre on 10/12/2012, with complains of pain in abdomen and a palpable lump in right iliac fossa. Physical examination revealed a palpable. Intra-abdominal mass 10x8 cm in right iliac fossa, it moves perpendicular to the root of mesentery. High resolution ultrasonography revealed a well-defined cystic mass measuring 10x8 cm, cyst was anechoic, double wall cystic mass and diagnosed as mesenteric cyst of hydatid. Chest x-ray was normal. Serological casoni test was negative. Laboratory investigation were normal.

At laparotomy we noticed a cyst lesion size 10x8 cm and covered with omentum. Cyst was located in the small bowel mesentery 30 cm away from ileocecal junction. There was no hydatid cyst in the liver and spleen. We removed the adherent omentum over the cyst slowly and performed subtotal cystectomy without injury to mesentery vessels and small bowel. Through irrigation with 10% povidine iodine as a scolicidal agent was given and abdominal wound closed in layers. The cystic lesion was opened and to our surprise cyst containing white laminated membrane with multiple grapes like daughter cyst inside the mother cyst.

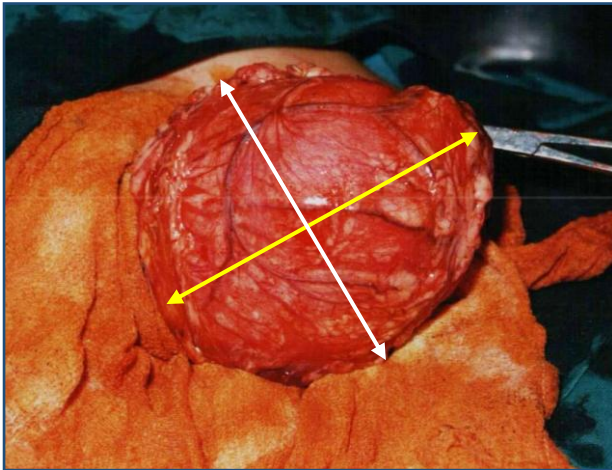
Histopathological examination revealed a primary hydatid cyst of the mesentery. The postoperative period was uneventful and patient was discharge after 8 days with Albendazole therapy for 6 months. No recurrence was noted after one year. (Fig 1-6)



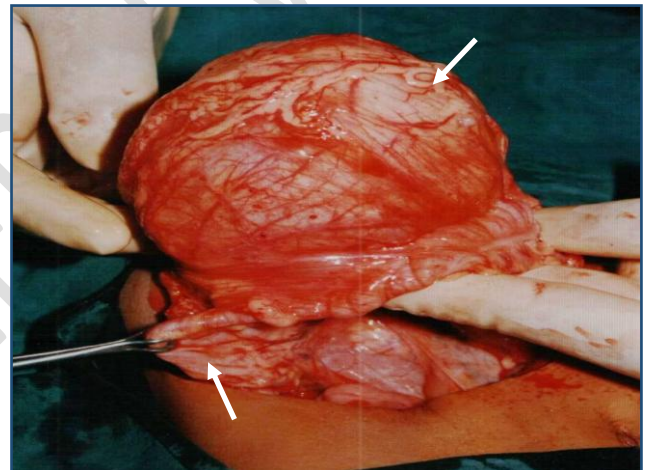
**Fig-1** Ultrasonography of showing well defined cystic lesion in the small bowel mesentery



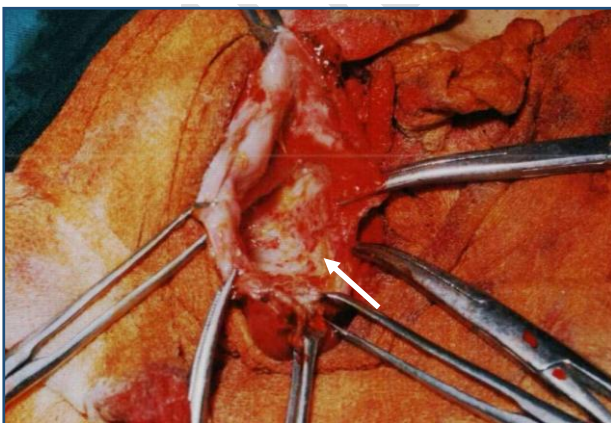
**Fig-2** Intraoperative photograph showing mesenteric cyst in right iliac fossa



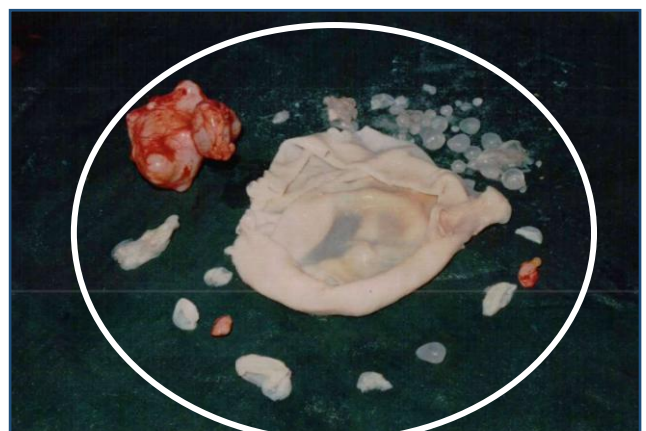**Fig-3** Intraoperative photograph showing mesenteric hydatid cyst of size 10x8 cm



**Fig-4** Intraoperative photograph showing mesenteric hydatid cyst



**Fig-5** Intraoperative photograph showing subtotal mesenteric cystectomy



**Fig-6** Cyst containing white laminated membrane with multiple grapes like daughter cyst inside the mother cyst.

Primary mesenteric hydatid cyst accounts for 2% of all abdominal hydatidosis during the last 20 years, there have been 49 reported cases of peritoneal, omental and mesenteric hydatid cyst in the English literature- Table I. [7]

<b>Country</b>	<b>Number</b>
India	24 <sup>2,8-28</sup>
Turkey	11 <sup>29-34</sup>
Iran	5 <sup>35-39</sup>
Greece	3 <sup>40</sup>
Morocco	2 <sup>41,42</sup>
Italy	1 <sup>43</sup>
Tunisia	1 <sup>44</sup>
USA (immigrant from Peru)	1 <sup>45</sup>
Pakistan	1 <sup>46</sup>
<b>Total</b>	<b>49</b>

Primary mesenteric hydatid cysts are usually solitary and it may be completely asymptomatic if they are small in size or they can be diagnosed as an abdominal mass, causing pain due to large size and pressure effect on the mesentery. Imaging and serology are the main diagnostic tool. Ultrasonography and CT abdomen are usually effective in diagnosing hydatid cyst in the abdomen. A single cyst in the mesentery can be considered as primary cyst only when no their cysts are present. In these cases, the embryo reaches the mesentery through a haematogenous or lymphatic route. Any cyst or tumour in the mesentery can rotate or twist and produce volvulus of mesentery and caused small bowel obstruction. Based on morphology the hydatid cysts are classified in to four different types. [2,4,7]

1. Types I – Simple cyst with no internal matrix
2. Type II – Cysts contain daughter cysts and internal matrix
3. Type III- Cysts are calcified cyst-wall
4. Type IV – Cyst is complicated cyst, may rupture, peritoneal seeding, infection of cysts. [9]

Careful and complete surgical excision is the gold standard treatment but sometimes in order to save other organs being injured, we can have performed subtotal or partial cystectomy. To prevent spreading, anaphylaxis and to kill the daughter cyst. Hypertonic saline or betadine and hydrogen peroxide can be used before opening the cyst to prevent the recurrence and the Albendazole therapy used as adjuvant therapy for 6 months. [1,3,7]

### **Conclusion**

Primary hydatid cyst of mesentery in extremely rare even in endemic regions. The treatment of choice is principally a careful and complete surgical excision; the partial or subtotal cystectomy can be performed to avoid adjacent organs injury. Albendazole are used a adjuvant therapy to surgery to prevent recurrence.

### **References**

1. Kushwaha JK, Gupta R, Mohanti S, Kumar S. Primary mesenteric hydatid cyst. *BMJ Case Rep.* 2012 Jul 9;2012:bcr0320125996. doi: 10.1136/bcr.03.2012.5996. PMID: 22778458; PMCID: PMC3417005.
2. Mohammad Asef Adelyar, Samea Hesham, Khalida Walizada, Ershad Ahmad Mushkani, Ramin Saadaat, Primary mesenteric hydatid cyst; a rare manifestation of hydatid disease through a case report and literature review, *International Journal of Surgery Case Reports*,

<https://doi.org/10.1016/j.ijscr.2022.107592>.

3. Kenana Tawashi, Yamama Tawashi, Salloum Naqoula, A hydatid cyst in mesentery complicated with appendicitis in nine-year-old child, *Journal of Pediatric Surgery Case Reports*, <https://doi.org/10.1016/j.epsc.2022.102520>.
4. Sheikh T, Hoogar MB, Sahu S et.al. Hydatid cyst in mesentery: rare and unusual site of occurrence. *Int J Health Sci Res*. 2019; 9(12):195-198
5. Urval M, Pai BS, Mulla SA. Primary hydatid cyst of the mesentery presenting as a small bowel volvulus. *Int Surg J* 2020;7:3490-2
6. Duzkoylu Y, Kucuk AI. A benign rare intraabdominal lesion: Primary giant mesenteric hydatid cyst. *J Clin Images Med Case Rep*. 2021; 2(2): 1040
7. Geramizadeh B. Isolated Peritoneal, Mesenteric, and Omental Hydatid Cyst: A Clinicopathologic Narrative Review. *Iran J Med Sci*. 2017 Nov;42(6):517-523. PMID: 29184259; PMCID: PMC5684372.
8. Reddy, Ravikanth. Concurrent Occurrence of Primary Mesenteric Hydatid Cyst with Multiple Calcified Splenic Granulomas: A Rare Presentation. *Apollo Medicine* 18(4):p 298-300, Oct–Dec 2021. | DOI: 10.4103/am.am\_50\_21
9. Singh BK. Mesenteric hydatid Cyst. *Nepalese Journal of Radiology* 2018;8(12):43-46. <https://doi.org/10.3126/njr.v8i2.22988>
10. Mehra BR, Thawait AP, Gupta DO, Narang RR. Giant abdominal hydatid cyst masquerading as ovarian malignancy. *Singapore Med Journal*. 2007;48:e284–e286. [PubMed] [Google Scholar]