

Case study

Congenital nasal pyriform aperture stenosis: A case report

Abstract:

Introduction: Congenital nasal pyriform aperture stenosis is a rare cause of neonatal respiratory distress.

Observation: A female neonate was born by cesarean section at 39 SA for hydramnios, triple scarred uterus and macrosomia. He was macrosomic and had no facial dysmorphia, he presented at H1 of life with respiratory distress and noisy mouth breathing. He cyanosed with each feeding attempt. On facial CT, the choanae were patent with a median central incisor and piriformis orifice stenosis. Nasal breathing gradually normalized. The hospitalization lasted 8 days with a good evolution.

Discussion: Congenital piriformis stenosis is a rare cause of congenital nasal obstruction. The association with median incisor syndrome is not exceptional. Diagnosis must be made early for proper management. Cyanosis and false airway can be life threatening. Associated abnormalities should be investigated by CT and MRI. Treatment is variable and may be surgical if the stenosis is severe. The prognosis is good in the absence of severe malformations or associated mental retardation.

Keywords: Stenosis, Nasal cavity, Congenital disorders

Introduction:

Congenital nasal pyriform aperture stenosis (CNPAS) is a rare cause of congenital upper airway obstruction. It results from an enlargement of the nasal processes of the jaw, which makes the nasal bone permeability precarious [1]. It was first identified in 1952 by Douglas and radiologically in 1988 by Ey et al [2]. The first clinical description was published by Brown et al [3] in 1989. It is a very rare cause of neonatal respiratory distress that can be life threatening for the newborn. This stenosis can be isolated or syndromic. It poses problems of management. We report this case of congenital stenosis of the piriformis orifice in order to illustrate the aspect and the value of imaging of the facial mass in the diagnostic assessment of this pathology.

Case report:

A female neonate was born by cesarean section at 39 SA for hydramnios, triple scarred uterus, and macrosomia. The parents were not consanguineous. The 26-year-old mother, G4 P3, had a history of unlabeled spontaneous abortion at 3 months. She had been followed for 5 years for type 2 diabetes on insulin. At birth, the Apgar score was unspecified but the mother reported the notion of immediate crying. The newborn was macrosomic with a birth weight of 4500 g, a height of 50 cm and a head circumference of 34 cm. There was no facial dysmorphia. At H1 of life he developed marked respiratory distress with generalized cyanosis. His mouth breathing was noisy. His distress increased with each feeding attempt with recoloration at the time of crying. Both nostrils were narrow and impermeable to a fine tube. Hemodynamically and neurologically he was stable. The rest of the examination was normal.

Choanal atresia was initially suspected. The neonate received Guedel's cannula placement which slightly improved his distress with saturation increased to 95% under cannula. He was fed by tube and treated with nasal decongestants. A nasal endoscopy was performed showing a complete stenosis at the entrance of the nasal cavity on the left with no access to the choana, on the right the stenosis was less important. A CT scan of the face (centered on the nasal cavity) was ordered for further management: the choanae were permeable with a median central incisor and stenosis of the piriformis orifice (fig. 1 and 2). The retained diagnosis was congenital piriformis stenosis in the context of single maxillary central incisor syndrome. Abdominal ultrasound and cardiac ultrasound showed no other abnormalities. The evolution after 8 days of hospitalization was marked by the progressive regression of the nostril edema, at the same time nasal breathing became possible. On the digestive level, the child begins to feed from the bottle without problem with a good tolerance.

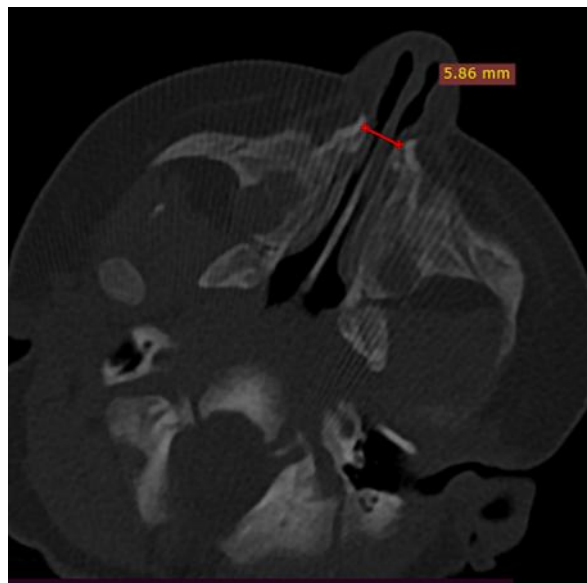


Figure 1: axial section of a CT scan of the facial bone in a bone window passing at the height of the choanae showing bilateral thickening of the nasal process of the maxillary bone reducing the lumen of the piriform orifices

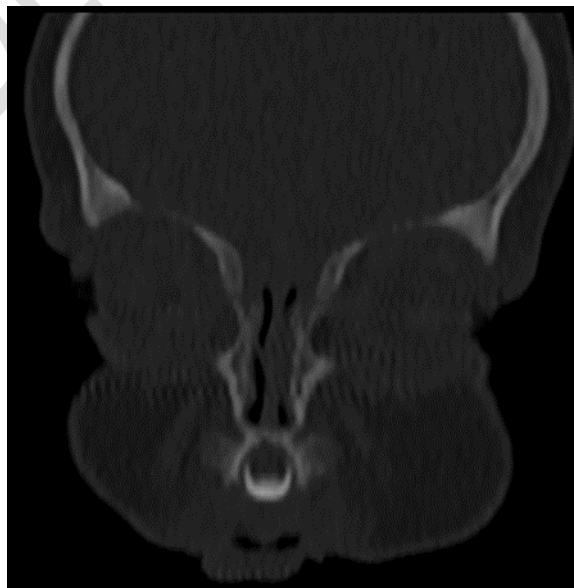


Figure 2: CT scan of the facial mass in coronal section in the bone window showing the presence of a central median incisor

Discussion :

Piriformis aperture stenosis is a rare cause of congenital nasal obstruction, with most cases related to choanal atresia. Since newborns and infants breathe exclusively through the nose, mouth breathing occurs between three and six months; this condition can be life-threatening for the baby with the rapid onset of severe respiratory distress when the piriform orifices are very narrow. The obstructive origin of this neonatal distress is suspected in the face of cyanosis that worsens during feedings and improves when crying [4]. In the face of this type of distress, it is important to locate the site of the obstruction. The level of stenosis differentiates the three causes of congenital nasal obstruction: choanal atresia, midnasal stenosis and congenital stenosis of the piriform nasal orifice [5–6]. CNPAS was first described by Brown et al. in 1989 [3].

CNPAS is usually bilateral and symmetrical and is caused by enlargement of the nasal processes of the jawbone as well as their medial displacement. It can be isolated or integrated into the Solitary Median Maxillary Central Incisor Syndrome (SMMCIS) comprising developmental abnormalities of the midline, associating in a variable way: short stature, holo-prosencephaly, hypopituitarism, microcephaly, mental retardation, a cardiac malformation, a cleft lip or palate, atresia of the esophagus, renal agenesis, a micro-penis and endocrine abnormalities such as diabetes insipidus, whether or not associated with an anterior pituitary gland insufficiency [5,7].

Clinically, in case of moderate stenosis, respiratory discomfort appears late, occurring most often during breastfeeding. For severe strictures, nasal obstruction and respiratory distress set in quickly at birth. Clinical examination of the nose, often using a small fibroscope, reveals a narrowing of the anterior part of the nasal cavity [8]. The diagnosis is then suspected in front of narrow nostrils with difficulty in passing a nasogastric tube or a fibroscope at the entrance to the nasal cavity. A complete physical examination of the body should be performed to look for other frequently associated malformative abnormalities. Flexible pediatric endoscopy can objectify the malformation if the stenosis is crossed [7].

CT of the facial bone is the best diagnostic means in front of any suspicion of CNPAS, allowing the diagnosis to be confirmed. Measurements are made on an axial section passing at the level of the internal nasal meatus [5]. They are standardized according to the age of the child. In the neonatal period, a width of less than 11 mm indicates severe stenosis. CT provides the differential diagnosis (essentially choanal atresia) and explores associated dental anomalies, in particular a single midline incisor present in nearly 50% of cases [5,9].

The management varies according to the severity of the symptoms and the dysmorphism. It is often difficult the first weeks of life, while waiting for the growth of the nasal bones. The newborn should be fed by gavage. It is necessary to fight against inflammation and local superinfection by humidification and nasal decongestion. Generally, the evolution is progressively favorable in parallel with the growth of the nasal bones and the spacing of the two bony processes at the origin of the stenosis [5].

Failing this, the treatment can be surgery, at any age [10]. It is all the more precocious as the stenosis is tight. [3,7]. It consists of resecting the excess bone via the upper vestibular route. The results are spectacular after a few months [7,10]. Postoperative anatomical results are assessed on CT [11].

Conclusion :

CNPAS is a very rare congenital nasal obstruction with a clinical presentation similar to that of choanal atresia. In case of neonatal respiratory distress, the CNPAS must be among the causes, a rapid diagnostic assessment and management are necessary. The diagnosis is confirmed by CT scan. Associated syndromic abnormalities should be sought by careful clinical examination and appropriate imaging (CT scan and MRI). The treatment is variable, can be conservative or surgical depending on the severity of the stenosis. This offers a good long-term prognosis in the absence of associated severe malformations.

References:

1. Sanal B, Demirhan N, Koplay M, Sadikoglu MY, Gurpinar A (2009) Congenital nasal piriform aperture stenosis: clinical and radiologic findings and treatment. *Jpn J Radiol.* 27: 389-391.
2. Ey EH, Han BK, Towbin RB, Jaun WK (1988) Bony inlet stenosis as a cause of nasal airway obstruction. *Radiology.* 168: 477-479.
3. Brown OE, Myer 3rd CM, Manning SC (1989) Congenital nasal pyriform aperture stenosis. *Laryngoscope.* 99: 86-91.
4. Daniel SJ. The upper airway: congenital malformations. *Paediatr Respir Rev* 2006;7(Suppl 1):S260-3.
5. Kuhn JP, Slovis TL, Haller JO. *Caffey's pediatric diagnostic imaging.* Radiography 2004;10(1).
6. Tagliarini JV, Nakajima V, Castilho EC. Congenital nasal pyriform aperture stenosis. *Braz J Otorhinolaryngol* 2005;246-9.
7. Shikowitz MJ (2003) Congenital nasal piriform aperture stenosis: diagnosis and treatment. *Inter J Pediatr Otorhinolaryngol.* 67: 635-639.
8. Trigui L, Ben thabet A, Gargouri A, Hmida N, Ben Hamad N, et al. (2010) Congenital stenosis of the piriform orifice. *Rev Stomatol Chir Maxillofac.* 111: 155-157.
9. Osovsky M, Aizer-Danon A, Horev G, Sirota L. Congenital pyriform aperture stenosis. *Pediatr Radiol* 2007;37:97-9.
10. Goga D, Fassio E, Bonin B, Durand JL, Sirinelli D. Sténose congénitale de l'orifice piriforme : une cause de détresse respiratoire du nouveau-né Revue de la littérature à propos de deux cas. *Rev Stomatol Chir Maxillofac* 1998;99:203-6.
11. Lee JC, Yang CC, Lee KS, Chen YC. The measurement of congenital nasal pyriform aperture stenosis in infant. *Int J Pediatr Otorhinolaryngol* 2006;70:1263-7.