

Case report

A Case Report of Bilateral Pneumothorax Associated with Marfan Syndrome

ABSTRACT:

Marfan syndrome is an inherited autosomal dominant multisystem connective tissue disorder that is the most common form of syndromic heritable thoracic aortic aneurysm disease which commonly involves skeletal, cardiovascular, and ocular systems with less frequent involvement of the pulmonary system.

Here we report a case of 17 years old male patient who presented with sudden onset shortness of breath over the last 12 hours. The patient was tall, thin built with long slender fingers. There were absent breath sounds over both sides of his chest with resonant notes on percussion. Chest X-Ray confirmed the presence of bilateral pneumothorax consistent with the clinical finding. Intercostal Chest Drain (ICD) insertion was done. Marfan syndrome was diagnosed. Computed tomography angiogram revealed focal ectasia at the distal arch of the aorta just proximal to the descending aorta measuring 3 cm in diameter without any aortic regurgitation on transthoracic echocardiography. This case suggests that spontaneous pneumothorax could be a pointer towards as well as an initial presentation of inherited connective tissue disorder like MARFAN syndrome.

KEYWORDS: Marfan Syndrome, Aneurysm, Pneumothorax, ICD (Intercostal Chest Drain), Ectasia,

INTRODUCTION:

Marfan syndrome is a rare connective tissue disorder that occurs in one out of 5000 individuals in the global population [1], resulting in a mutation in Fibrillin 1 gene, located at chromosome 15, which encodes for a microfibrillar glycoprotein fibrillin 1[2,3]. Any reduction of quantity or quality or both of fibrillin glycoprotein may reduce the tensile strength of connective tissue in stress response, which affects the skeleton, heart, lungs, eyes, and vascular system. Most common being the skeletal system, Marfan syndrome less frequently involves the pulmonary system. The most dreaded complication of Marfan syndrome is progressive aortic root dilation which may land up into aortic regurgitation, aortic dissection, and even aortic rupture [3]. Approximately 16% of patients with Marfan syndrome have pulmonary symptoms and pulmonary involvement may contribute to 10% of deaths in Marfan syndrome. The prevalence of pneumothorax in Marfan syndrome accounts for 4.8% to 11% [4]. Here we present a case of spontaneous bilateral pneumothorax as an initial diagnosis of Marfan syndrome.

CASE PRESENTATION:

A 17-year-old male patient without any comorbidities presented with sudden onset, progressive shortness of breath over the last 12 hours. The patient had no complaint of dimness of vision. On physical examination and general survey, the patient was dyspneic with a respiratory rate of 60 /min without any evidence of pallor with SpO₂ 90% with 15 liter/min O₂ via NRBM mask. The patient was hemodynamically stable with BP 110/70 mmHg in the supine position in the right upper arm. Tachycardia was noted with HR 110 beats/min. Multiple striae marks were over both shoulder blades and back [figure 1]. The patient was tall with a height of 182cm a thin build and long slender fingers [figure 2(A, B, C)]. The upper segment(82cm) to lower segment(100cm) ratio was found to be 0.82 which is below 2 standard deviations concerning age, sex, and race. There is an increased arm-to-height ratio. The Walker Murdoch wrist sign (that is overlapping of complete distal phalanx of thumb and little finger when wrapped around the opposite wrist) and Steinberg thumb sign (that is extension of the distal phalanx of thumb beyond the ulnar border of the hand when apposed across the palm) are found to be positive [figure 3A, B]. There is the presence of pes planus [figure 4]. Kyphosis or scoliosis was absent. There are no features of hyperextensible joints. There is the presence of dolichocephaly and down-slanting palpebral fissures, without any features of enophthalmos, malar hypoplasia, or retrognathia. There was the presence of a high-arched palate [figure 5]. There is no deformity of the chest wall with normal movement on both sides of the chest. There were absent breath sounds over both sides of his chest without any evidence of a rise in jugular venous pressure. Trachea was midline in position. On percussion of the chest wall, it was resonant on both sides, and on auscultation there were no breath sounds over all the areas of the chest wall. First and second heart sounds were audible without any evidence of murmur or any adventitious heart sounds. Other systemic examinations were unremarkable. An urgent chest X-ray was performed which revealed bilateral pneumothorax [figure 6]. An intercostal underwater seal drainage tube was inserted over the right hemithorax which relieved symptoms. On evaluation, the patient was found to have anemia which was a normocytic and normochromic pattern (Hemoglobin 12.1 gm/dl, TLC 8800 /mm³, Platelet 2.5 lakh/mm³) with raised inflammatory markers (ESR 17 mm 1st hour, CRP 59.6 mg/dl). Liver and renal function tests were normal. Trans thoracic 2D Echocardiography was performed which revealed mild mitral regurgitation with dilation of aortic root without any ominous sign of mitral valve prolapse or aortic regurgitation. Computed tomography angiogram of the thoracic and abdominal aorta was performed. The aorta is tortuous and there was a focal ectasia at the distal arch of the aorta, proximal to the descending aorta measuring 3 cm in maximum diameter [figure 7 (A, B, C)]. On slit lamp examination, no dislocation of the lens was observed with visual acuity 6/6 on both eyes, thus ruling out myopia. Genetic screening for FIBRILLIN 1 gene mutation was performed and the patient was found to be heterozygous for the pathogenic variant of the fibrillin 1 gene mutation. On day 2 of admission, the other Intercostal underwater seal drainage tube was inserted over the left hemithorax. A serial Chest X-Ray was done to assure the expansion of the collapsed lung. ICD of right and left-sided hemithorax was removed after day 7 and day 10 of admission, respectively. After that, the patient was advised to continue chest physiotherapy.

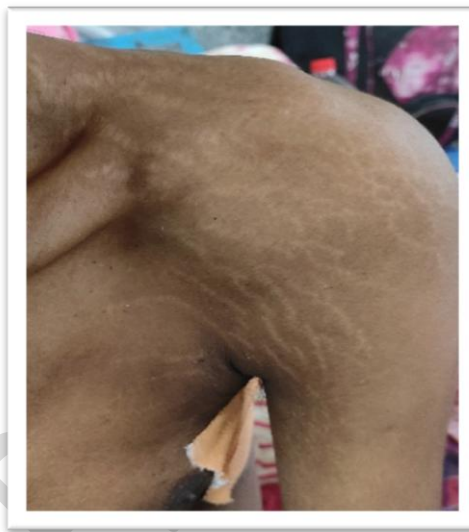
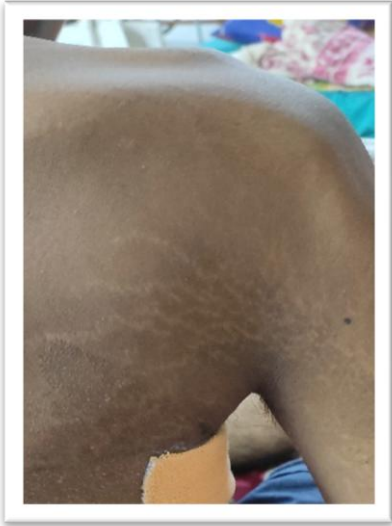
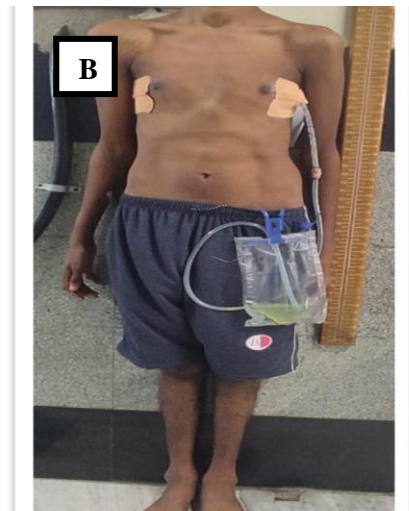
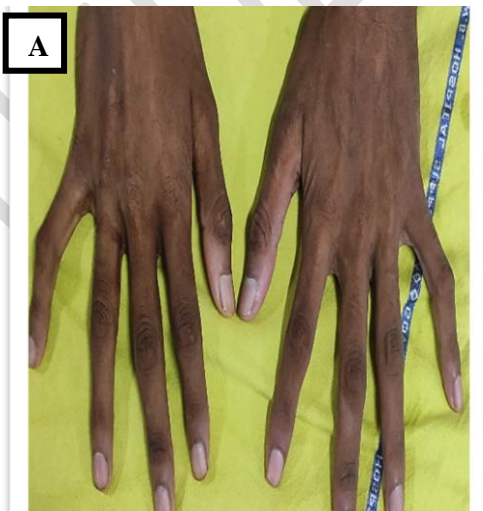

Figure 1: Striae marks over back and shoulder blades



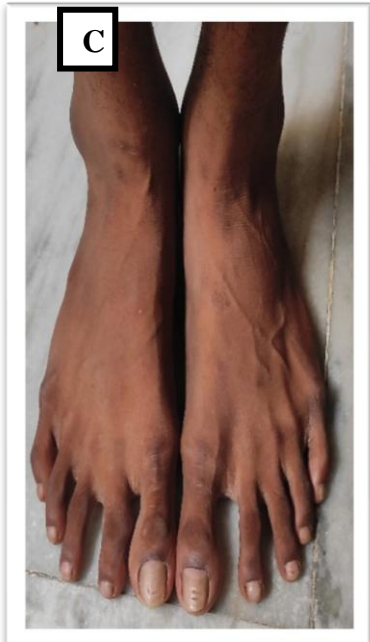


Figure 2 (A, B, C): Arachnodactyly with thin built and long slender fingers

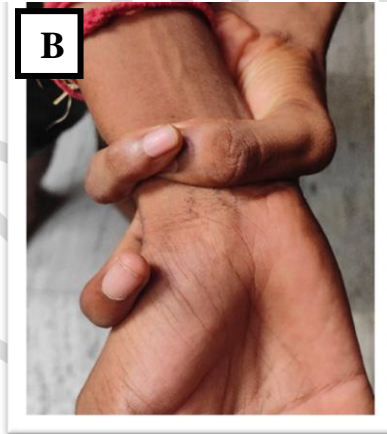
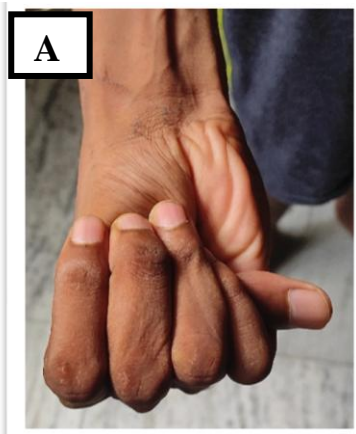
Figure 3 (A, B): Thumb Sign and Wrist Sign

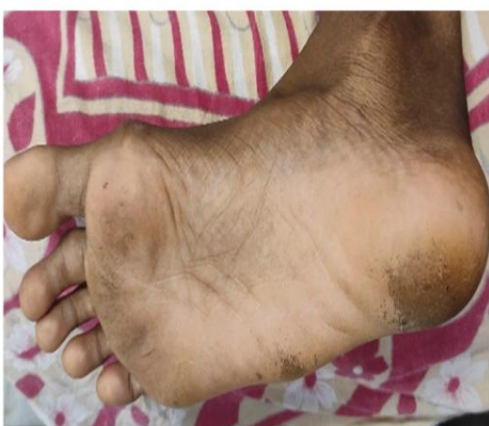

Figure 4: Pes Planus

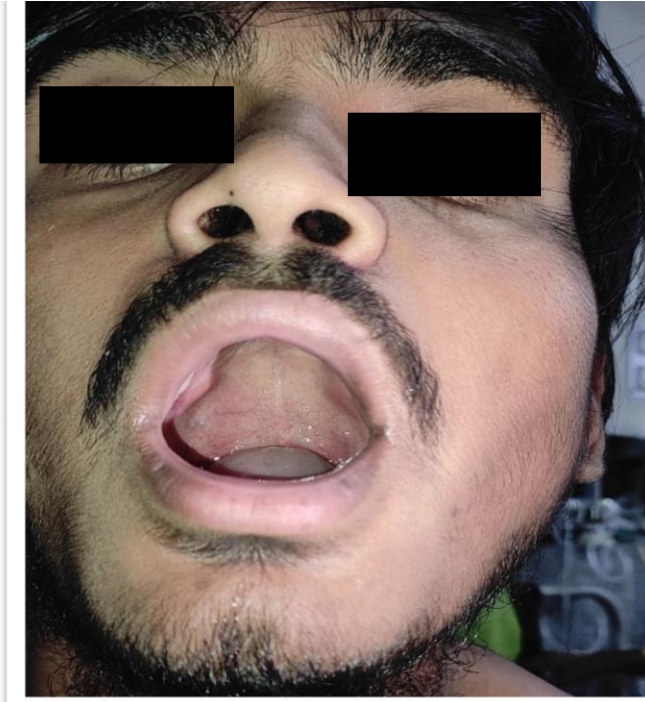

Figure 5: High-arched palate with downward slanting palpebral fissure

UNDER PEER REVIEW

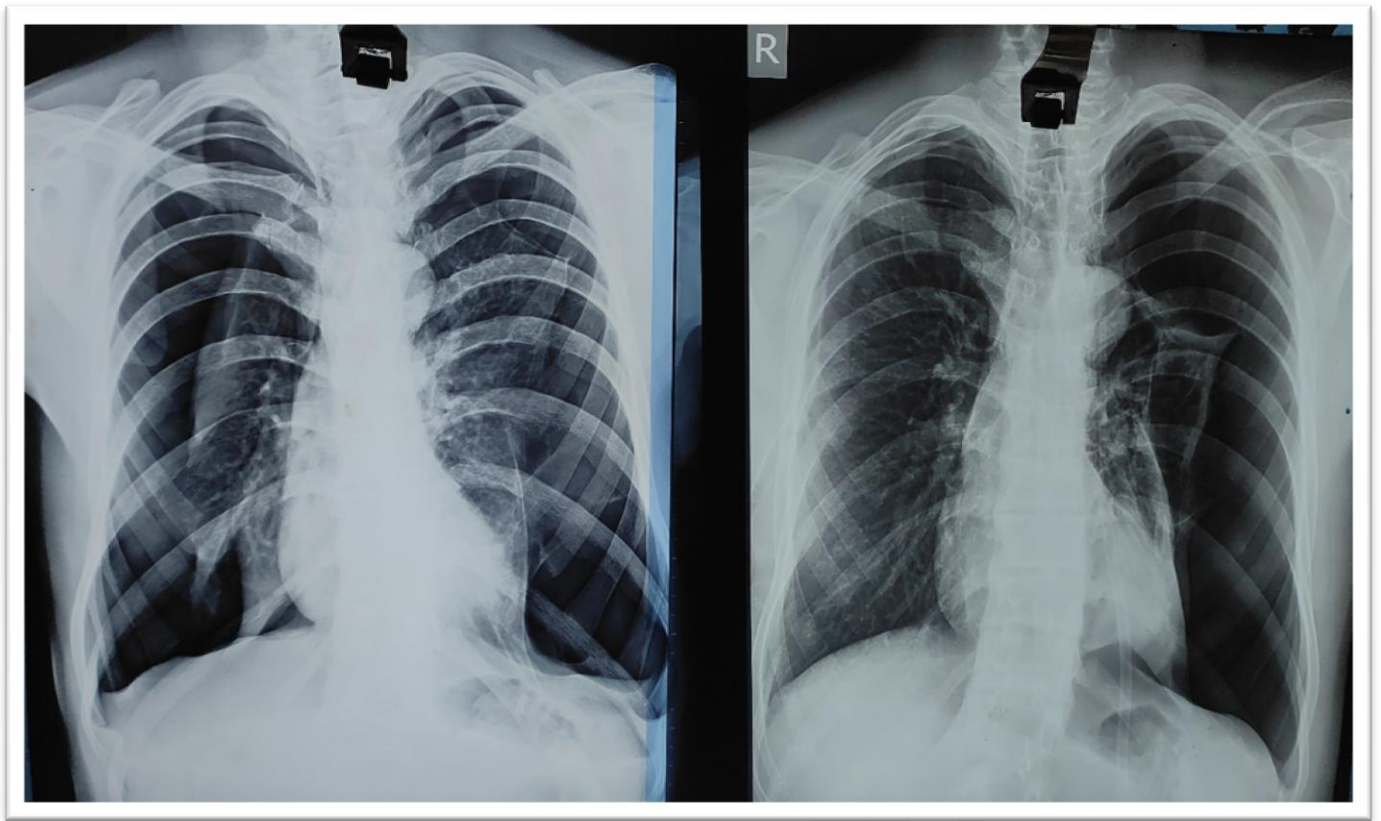


Figure 6: (Chest X-Ray PA View): Bilateral pneumothorax at time of presentation (left) and after insertion of intercostal underwater seal chest drain (right)

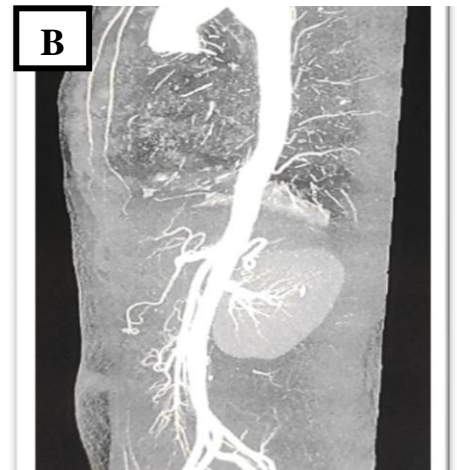
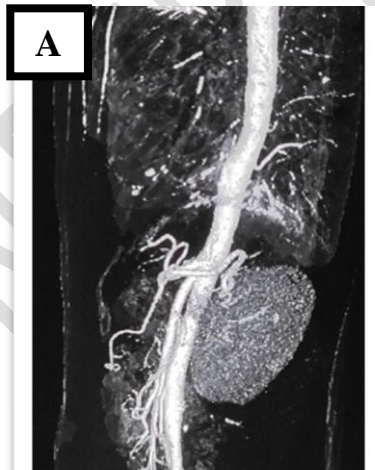
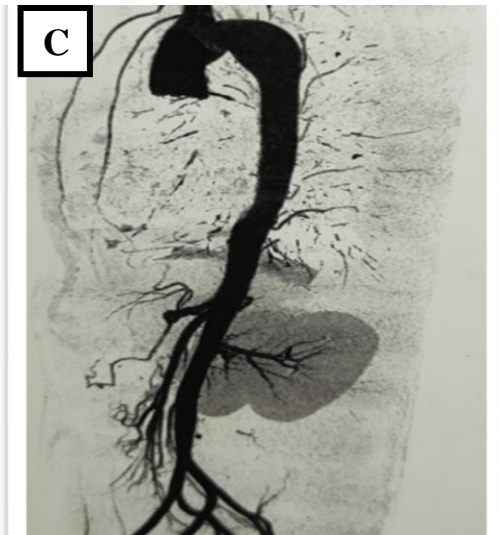



Figure 7 (A, B, C): CT Angiogram of abdominal and thoracic aorta

DISCUSSION:

Fibrillin 1 is a large glycoprotein that serves as a structural component of microfibrils that constitute elastic and nonelastic connective tissues throughout the body. These microfibrils provide resilience to tissues at times of stress [5,6]. Marfan syndrome is an inherited autosomal dominant connective tissue disorder resulting from a mutation in the Fibrillin 1 gene located on chromosome 15 which results in a reduction of Fibrillin 1 protein both in quality and quantity [2,3]. As a consequence, the tissues have a poor capacity to withstand stress as compared to that of normal tissue. Various organs of the musculoskeletal, cardiac, pulmonary, vascular, and ocular systems are involved frequently with varying degrees of penetrance and expressivity. The affected individuals, often described to have ‘Marfanoid habitus’ are tall, and slender with chest wall deformity either as pectus excavatum or carinatum, long thin extremities, long-slender-spiderly digits termed as arachnodactyly, joint instability, scoliosis and sometimes with visual disturbance in the form of myopia [7]. Due to the lack of any specific laboratory tools, the identification depends on a high degree of clinical suspicion and Revised Ghent criteria [8]. Early diagnosis is based upon atypical symptoms of Marfan syndrome like spontaneous pneumothorax, and bullae in young patients without any definite history of smoking or trauma and valvular abnormalities or aortic root dilation on screening echocardiography which raise the suspicion for inherited connective tissue disorder like Marfan syndrome and warrant for genetic screening. Other pulmonary lesions that could arise the possibility of Marfan syndrome range from cystic changes, emphysema, bronchiectasis, congenital pulmonary malformations (particularly middle lobe hypoplasia), and apical fibrosis [9]. The increased risk of pneumothorax can be attributed to apical blebs, bullae, abnormal connective tissue in the lung parenchyma, and undue

mechanical stress in the lung apices due to tall habitus [10]. Similarly, the aorta is rendered less distensible due to defective fibrillin 1 protein failing to return to its original form under high stress of lateral column of flow of blood [11,12] resulting in progressive dilation of aortic root, aortic regurgitation, and subsequently aortic dissection which is the main cause of death in Marfan syndrome accounting for 46% deaths [13]. Dilation of the aorta is found in 60% to 80% of adult patients [14]. With early diagnosis, early management of the complications of the disease leads to greater life expectancy and a reduction in the number of sudden cardiac deaths. As there is no definite cure for the inherited autosomal dominant disease, prevention in the form of physical and cardiovascular stress reduction with isometric exercise restriction and medical therapy is recommended. Current recommendations as per 2022 ACC/AHA Guidelines for the diagnosis and Management of Aortic diseases recommends Prophylactic beta-blockers, ACE inhibitor, and ARB or a combination of both beta blockers and ARB reduce either the progression of the aortic dilation or the occurrence of complications. Serial monitoring of cardiovascular system, specifically aortic dimensions via periodic serial transthoracic echocardiography and other cross sectional imaging modality like magnetic resonance imaging (MRI) as per recommendation of recent guidelines annually is the mainstay is recommended with aortic sinus diameter $> 50\text{mm}$ or $>45\text{mm}$ with other additional factors or a maximal cross section of aortic root area (cm^2) to height (m) of ratio >10 . Patients approaching surgical threshold with low surgical risk would benefit from valve sparing root replacement surgery (VSRR) (15).

CONCLUSION:

Early diagnosis of Marfan syndrome based on atypical symptoms like pneumothorax, proved to increase the life expectancy of patients with Marfan syndrome markedly. whenever any patient with Marfan's syndrome, presented with acute chest pain, with or without dyspnoea, Pneumothorax along with aortic dissection should be considered immediately.

ETHICAL APPROVAL:

As per international standard or university standard written ethical approval has been collected and preserved by the author(s).

CONSENT:

Written informed consent was obtained from the patient for the publication of this case report and accompanying images.

REFERENCES:

1. Pyeritz RE. Toward understanding the cause and pathogenesis of Marfan syndrome. In: Hetzer R, Gehle P, Ennker J, eds Cardiovascular aspects of Marfan syndrome. Darmstadt, Germany: Steinkopff Verlag, 1995:1–8
2. MARFAN SYNDROME. (2020). <https://medlineplus.gov/genetics/condition/marfan-syndrome/>.
3. Keane MG, Pyeritz RE: Medical management of Marfan syndrome. *Circulation*. 2008, 117:2802-13. 10.1161/CIRCULATIONAHA.107.693523
4. Chiu HH, Wu MH, Chen HC, et al. Epidemiological profile of Marfan syndrome in a general population: a national database study. *Mayo Clin Proc* 2014; 89:34-42. 10.1016/j.mayocp.2013.08.022
5. Biery NJ, Eldadah ZA, Moore CS, Stetten G, Spencer F, Dietz HC (February 1999). "Revised genomic organization of FBN1 and significance for regulated gene expression". *Genomics*. 56 (1): 70–7.
6. Faivre L, Gorlin RJ, Wirtz MK, Godfrey M, Dagonneau N, Samples JR, Le Merrer M, Collod-Beroud G, Boileau C, Munnich A, Cormier-Daire V (January 2003). "In frame fibrillin-1 gene deletion in autosomal dominant Weill-Marchesani syndrome". *Journal of Medical Genetics*. 40 (1): 34–6.
7. Pyeritz RE, Gasner C. *The Marfan syndrome*. 4th edition New York: The National Marfan Foundation, 1994
8. Ades L; CSANZ Cardiovascular Genetics Working Group Guidelines for the diagnosis and management of Marfan syndrome. *Heart Lung Circ* 2007; 16:28–30
9. Dyhdalo K, Farver C. Pulmonary histologic changes in Marfan syndrome: a case series and literature review. *Am J Clin Pathol* 2011; 136:857-63. 10.1309/AJCP79SNDHGKQFIN
10. Karpman C, Aughenbaugh GL, Ryu JH. Pneumothorax and bullae in Marfan syndrome. *Respiration* 2011; 82:219-24. 10.1159/000322958
11. Sulejmani F, Pokutta-Paskaleva A, Ziganshin B, Leshnowar B, Iannucci G, Elefteriades J, Sun W: Biomechanical properties of the thoracic aorta in Marfan patients. *Ann Cardiothoracic Surg*. 2017, 6:610-24.
12. Dean JC: Management of Marfan syndrome. *Heart*. 2002, 88:97-103. 10.1136/heart.88.1.97
13. Chiu HH, Wu MH, Chen HC, et al. Epidemiological profile of Marfan syndrome in a general population: a national database study. *Mayo Clin Proc* 2014; 89:34-42. 10.1016/j.mayocp.2013.08.022
14. Roman MJ, Devereux RB, Kramer-Fox R, et al. Comparison of cardiovascular and skeletal features of primary mitral valve prolapse and Marfan syndrome. *Am J Cardiol* 1989; 63:317-21.

15. Isselbacher E, Preventza O, et al. 2022 ACC/AHA Guideline for the Diagnosis and Management of Aortic Disease. J Am Coll Cardiol. 2022 Dec, 80 (24) e223–e393.<https://doi.org/10.1016/j.jacc.2022.08.004>

UNDER PEER REVIEW