

Hydatid cyst of the psoas: A report of 3 cases

ABSTRACT

Background: Hydatidosis is a frequent and benign disease that prevails in an endemic state and remains a real public health problem in our country, where breeding is still traditional. In countries with hydatid-endemic diseases, all locations are possible. Hydatidosis of the psoas muscle represents an exceptional location, observed in about 0.2 to 0.5% of cases.

The symptomatology is dominated by painful swelling in the right iliac fossa or right flank, which is the most common reason for consultation, occasionally developing in a febrile situation and being mistaken for a psoas abscess.

The abdominal computed tomography (CT) confirmed the diagnosis and allowed us to better specify the cyst's seat and its reports.

The treatment consists of a surgical excision by pericystectomy. The results were satisfactory in all cases, and no recurrence was reported in our series.

Prophylaxis is the best way to control this parasitosis in endemic areas.

Case reports: Our work is a retrospective study relating to three cases of hydatid cysts of the psoas muscle collected in the department of visceral surgery at Avicenne Military Hospital and Guelmim Military Hospital over 12 years (1998–2010). This work has allowed us to clarify the epidemiological, clinical, and laboratory aspects and the place of medical treatments—radical and conservative surgical—related to cysts

It allowed us to clarify the epidemiological, clinical, and laboratory features, as well as the role of medical therapies (radical and conservative surgery) for psoas muscle cysts. The disease is more common in men than women, with an average age of 35

Keywords: hydatid cyst, psoas, echinococcosis, infection, serology, albendazole.

1. INTRODUCTION

Hydatidosis, or echinococcosis, also called hydatid cyst or hydatid disease, is a cosmopolitan parasitosis widely spread worldwide. It is due to the presence and development, in humans, of the larval form of a cestode of the genus *Echinococcus granulosus* [1]. It is a cosmopolitan anthroponosis, especially in Mediterranean countries, North Africa, Latin America, Australia, New Zealand, and Central Europe [2].

In Morocco, it is still considered a severe public health problem because of its frequency, morbidity, and mortality, and it causes enormous economic losses [3]. It is a parasitic disease in which humans represent the accidental intermediate host.

Hydatidosis mainly affects the liver in 60 to 70% of cases; the lung comes second in 20 to 30%. It may also interest other locations (such as the spleen, kidneys, heart, bones, and central nervous system), but much less frequently. The retroperitoneal location of hydatid cysts is scarce, and there have been a few examples mentioned in the literature [2]. It represents 3% of muscle location [2, 4] and 5% of soft tissue involvement [2, 5]. The symptomatology remains non-specific [2, 6]. A febrile abdominal mass is an unusual mode of revelation, which poses a real problem for preoperative diagnosis.

The CT scan and serology are very useful in diagnosing.

The therapeutic means currently used are albendazole, percutaneous drainage, and surgery. [7]

Primary prevention remains the preferred way to control this endemic. [8]

Through three cases of hydatid cysts of the psoas, the authors raise diagnostic and therapeutic difficulties and discuss the interest of a CT scan in the preoperative diagnosis of this affection.

2. CASE REPORTS

CASE 1:

A 43-year-old male with no apparent significant medical history. He was admitted to service in 2003 for right flank pain.

The physical examination found a painless cystic mass on the right flank, movable relative to the deep plane.

The abdominal X-ray showed a loss of the right psoas shadow, while the ultrasound revealed a cystic mass of 15cm corresponding to the type III hydatid cyst (Figure 1). The CT scan specified the retroperitoneal location of the cyst in the right psoas (Figure 2).

Through an umbilical midline incision, the patient underwent an exploratory laparotomy, where the cyst was detached and exposed. The pericyst was left firmly implanted in the psoas after a partial pericystectomy that followed the standard approach for treating parasites.

Fortunately, the crural paralysis following the surgery resolved itself after six months.

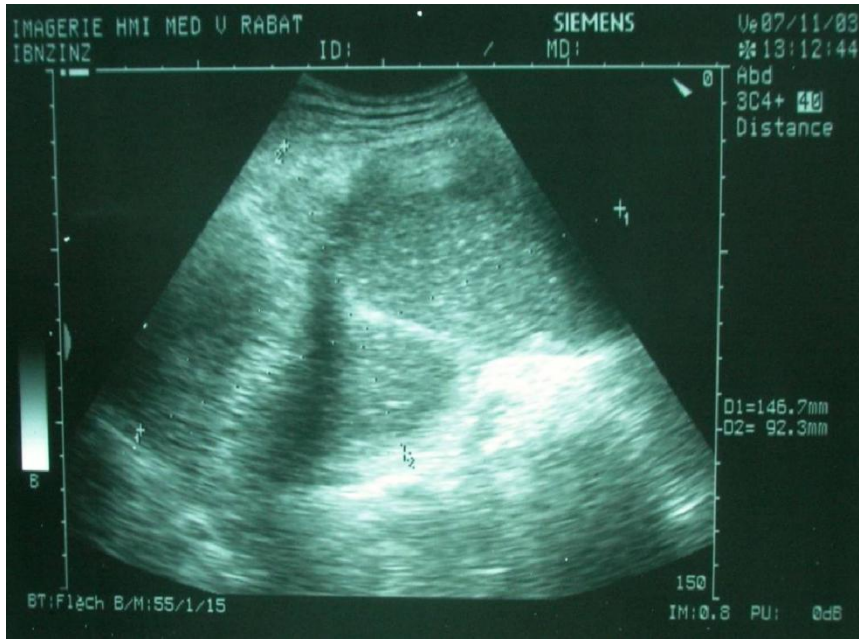

Figure 1: An Ultrasound Image shows a cystic mass of 15 cm corresponding to the type III hydatid cyst.

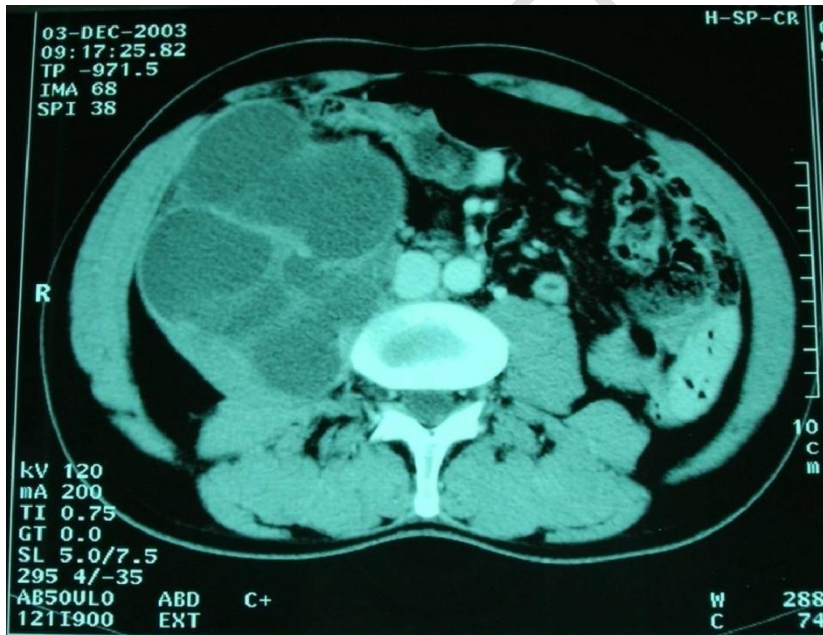

Figure 2: A CT scan image specifies the retroperitoneal location of the cyst in the right psoas.

CASE 2:

A 34-year-old male with no pathological history. In 2006, He was admitted to the neurosurgery department to manage a right paravertebral collection evolving in a febrile context with low back pain and weight loss estimated at 6 kg in two months.

The clinical examination showed a swelling of the right iliac fossa and the fold of the right groin (Figure 3). The diagnosis of probably tuberculous spondylodiscitis was mentioned.

The abdominal ultrasound showed a suitable paravertebral collection that extended to the iliac crest. The abdominopelvic CT scan had objectified a septate collection of the right iliopsoas muscle (Figure 4). The biological assessment had shown a leukocytosis at 12000 elements per mm³. BK testing in sputum and urine was negative, as was IDR for tuberculin. The chest X-ray was normal. The patient was diagnosed with a psoas abscess and referred to the visceral surgery department for therapy.

An exploratory laparotomy was performed on the patient, which revealed a hydatid cyst of the psoas adherent to the iliac psoas muscle and the groin crease. After a section of the cyst's contents, using fields soaked in hydrogen peroxide to protect the area. A pericystectomy was performed with satisfactory clinical and radiological results.

The postoperative follow-ups were simple, and a repeat examination performed two years later showed no recurrence of hydatid disease.

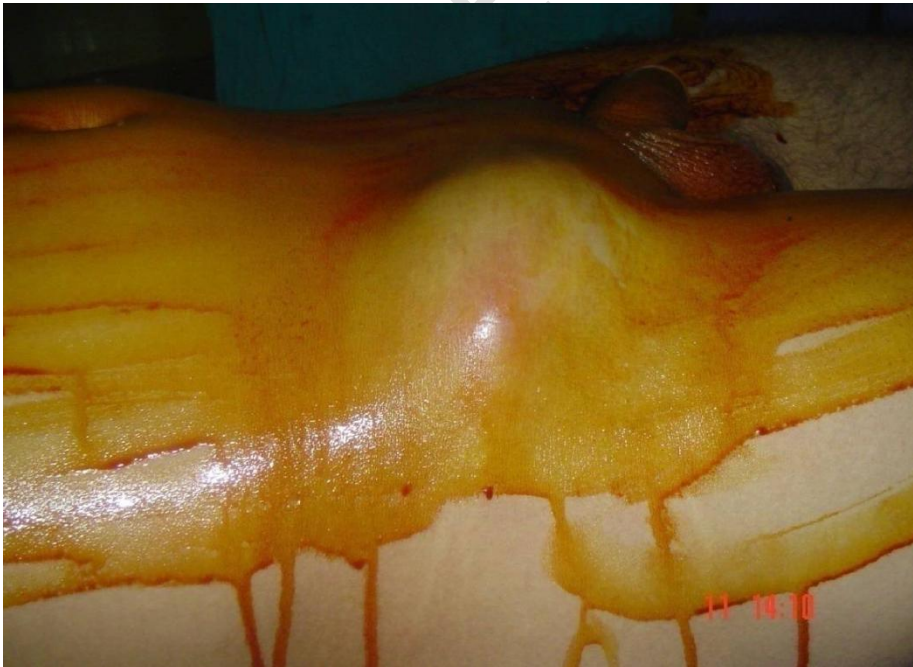

Figure 3: A swelling of the right iliac fossa and the fold of the right groin.

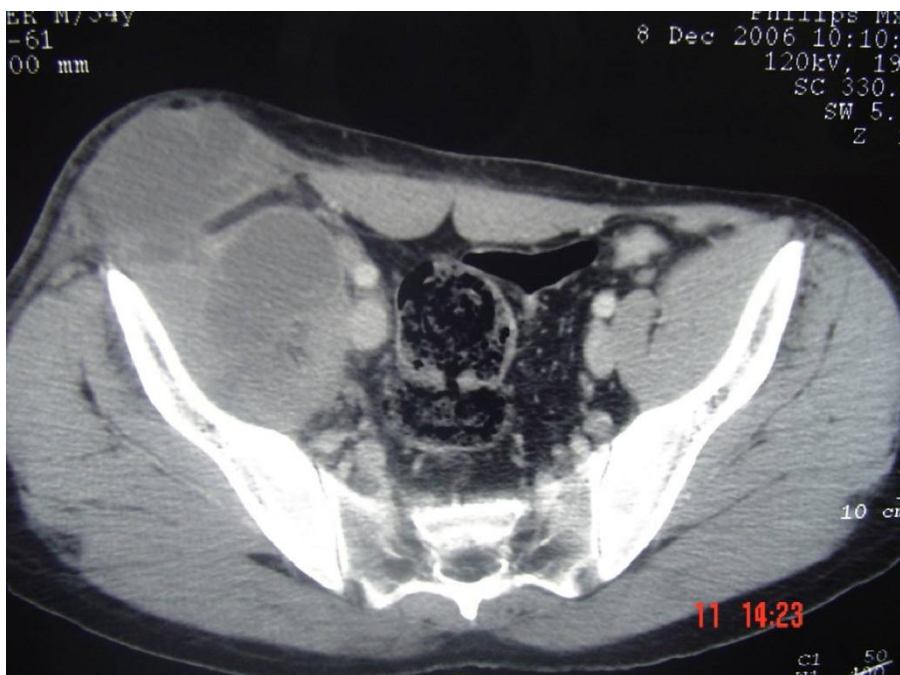

Figure 4: The abdominopelvic CT scan image shows a collection of the right iliopsoas muscle.

CASE 3:

A 30-year-old male JA with no specific medical or surgical history. He was admitted to service in 2009 after taking charge of a mass on the right flank.

Clinical examination showed a painful mass of the right iliac fossa evolving in a febrile context.

The abdominopelvic CT scan demonstrated a heterogeneous process of the right iliac psoas muscle (Figure 5).

A right lumpectomy with retroperitoneal access was performed on the patient; the cyst was located, and a total pericystectomy was performed.

The postoperative follow-ups were simple, and the patient left the department on the sixth day with good clinical and radiological progress.

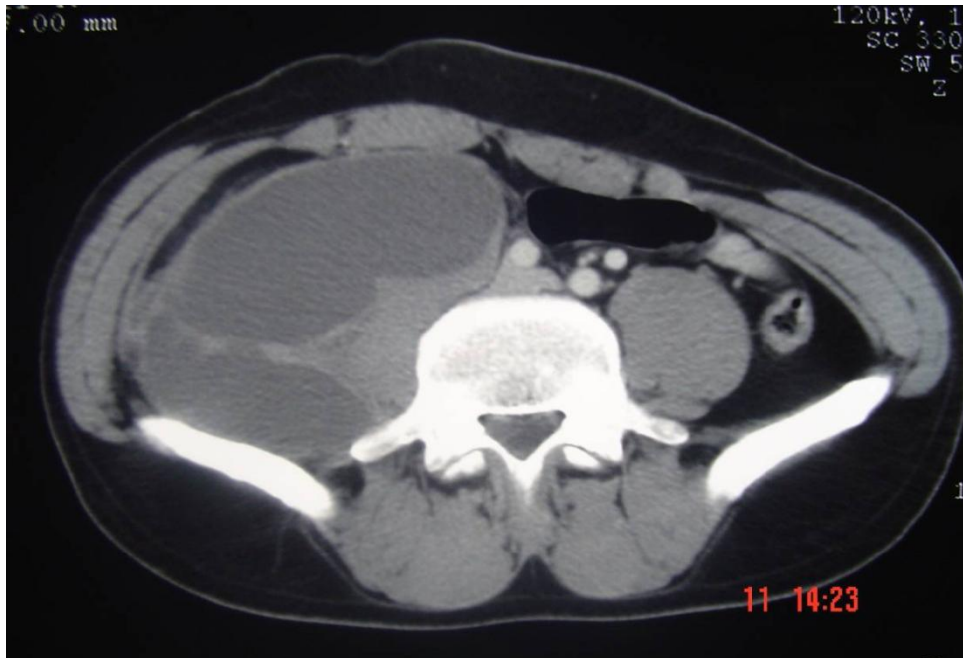


Figure 5: CT scan image shows a large hydatid cyst developing on the right iliac psoas muscle.

3-RESULT

The frequency of muscular hydatidosis varies from 1 to 3% [9]. The muscle location reported in our series of cases is that of the psoas muscle among 865 cases of hydatid cyst treated in the visceral surgery department at the Avicenne Military Hospital and at the 5th Military Hospital in Guelmim over 12 years (between 1998 and 2010). The rarity of this location is that the muscle is generally very resistant to echinococcosis because it tends to partition and encapsulate the larva as well as the contractile activity and the production of lactic acid [10, 5, 11].

The hydatid cyst is more common in females; our series did not confirm this; the three patients were male. The patients were, respectively, 43, 34, and 30 years old, with an average age of 35. These data join those in the literature considering hydatid disease as a pathology of young adults.

As far as history is concerned, contact with dogs represents one of the most frequent modes of contamination [12, 13], which is missing in our three patients, which suggests an indirect mode of transmission of the parasite.

Clinically, the hydatid cyst of the psoas is revealed by a painful swelling, which is most often the reason for consultation, sometimes evolving in a febrile context, as is the case in the second and third patients in our series. The evolution in a febrile

context was confusing with an abscess of the psoas; this was the case in the second patient. The hydatid cyst can remain asymptomatic for a long time or cause symptoms related to compression of the adjacent nerve structures, as it can reach a large volume and have a mass effect on the adjacent organs.

Biologically, hypereosinophilia is present in one patient. The unprepared abdominal X-ray on the first patient showed obliteration of the right psoas shadow. Ultrasound in the two patients was used to specify the fluid nature of the mass, its location, and its size.

The CT scan of the three patients confirmed the diagnosis. It made it possible to specify the location of the cyst and its anatomic relationship, eliminating the differential diagnosis.

Surgery is the mainstay of treating hydatid cysts by total or partial pericystectomy; it is the only radical treatment that confirms the diagnosis and ensures a complete cure. The surgical field is protected by using surgical drapes soaked in hypertonic saline or oxygenated water to avoid the dissemination of the parasite during surgery.

The postoperative follow-ups were simple except in the first patient, where a crural paralysis was reported but regressed spontaneously in six months.

4-Discussion:

Echinococcosis, often known as hydatidosis, is a global anthroponosis caused by tapeworms of the genus *Echinococcus* [14]. The human infestation is induced by eating tapeworm eggs, which dogs ingest. [15]. All the localizations of hydatidosis have been described [4]. In 90% of cases, it affects the liver and lungs [5]. The blood circulation of the parasite explains this distribution, and the blood flows in the portal circulation. Human-ingested tapeworm eggs enter the portal circulation, where they are carried and immobilized at the level of the sinusoids, which serve as a natural filter. 10 to 20% of the larvae escape this hepatic barrier and join the large circulation to go and lodge in one of the organism's tissues [4, 5]. The frequency of muscular hydatidosis varies from 1 to 3%. The muscle location reported in our case series is that of the psoas muscle among 865 cases of hydatid cyst treated in the visceral surgery department at the Avicenne Military Hospital and at the 5th Military Hospital in Guelmim for 12 years (1998–2010).

Soft tissue involvement is unusual (0.5 to 4.7% of cases) and primarily involves the skeletal muscles of the neck and lower limbs [5]. This is attributable, on the one hand, to the degree of vascularization of the tissues and to the muscular

contractions, which would prevent the development of the larva, and, on the other hand, to the richness in lactic acid of the muscle, which would prevent the growth of the hydatid [5, 9].

In our context, our three patients' dog contact history must be included. The preoperative diagnosis of the hydatid cyst of the psoas is challenging to establish. Clinically, it manifests as a painful swelling, which is frequently the reason for consultation, and it can also manifest in a febrile environment, as in the case of two patients in our series. The evolution in a febrile context lends confusion to an abscess of the psoas; this is the case in the second patient. The growth of the cyst may manifest, in addition to the presence of a mass, local symptoms related to nerve compression, which has been reported in the first patient as crural paralysis but which has spontaneously regressed in six months, or infection. The latter was suspected in the second patient because of fever and pain. These cysts are usually superinfected by hematogenous dissemination. [16]. In these cases, the diagnosis can be an abscess [16].

The allergic reaction can range from a skin rash or simple urticaria to anaphylactic shock due to spontaneous or provoked rupture or cyst puncture; this is why some authors do not recommend this procedure [5].

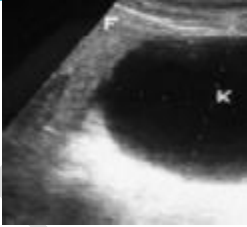

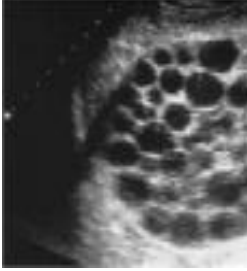
In biology, hypereosinophilia is inconstant and has only an interest in the orientation of the diagnosis. It is present in one patient. The qualitative and quantitative methods are difficult to interpret; however, Western Blot is more sensitive and specific [17].

Imaging is essential for diagnosis and pre-therapeutic assessment [18]. Ultrasonography is an innocuous first-line examination with diagnostic reliability estimated at 96% [19]. The ultrasound appearance reproduces the stages of Gharbi's classification and reflects the evolutionary stage of the disease (table I): **Type I: simple cyst with no internal architecture; Type II: anechoic image with membrane detachment; Type III: multivesicular fluid collection; Type IV: mass of heterogeneous echostructure, pseudotumoral; Type V: calcified cyst** [20]. Even if high-frequency probes make it possible to refine the ultrasound study of the cyst wall [21] in deep locations like the psoas, the interest of a CT scan remains necessary. CT scan allows an easy diagnosis with a more accurate topographic assessment [22]. The morphological aspects are identical to those described in ultrasound [18, 23]. Magnetic resonance imaging is an expensive examination for benign pathology. It has a diagnostic contribution in cases where the cysts are not characteristic on ultrasound or scanning, especially in pseudo-tumor forms. It allows an axial, frontal, sagittal, and oblique multiplanar study and a detailed study of the wall and cystic contents [24].

Surgery with a whole or partial pericystectomy and irrigation of the surrounding tissues with a solid hypertonic solution is the only curative therapy for a psoas hydatid cyst. Albendazole Medical treatment for cystic echinococcosis is limited; albendazole is used mainly for inoperable cases and combined with surgery to

prevent postoperative recurrence [15, 25]. Laparoscopic surgery of the hydatid cyst of the psoas remains to be validated [26].

The extraperitoneal approach is the safest way to avoid peritoneal dissemination. Surgical excision must be careful, thus preventing the opening of the cyst, because the greatest danger for the patient is dissemination, with the possibility of a second implant and an anaphylactic reaction [5, 15, 27].

Type	Description	Image
Type I	pure anechoic image well limited: unilocular cystic lesion	
Type II	anechoic image with membrane detachment	
Type III	multivesicular fluid collection.	



Type IV	mass of heterogeneous echostructure, pseudotumoral	
Type V	calcified cyst	

Table I: The Gharbi ultrasound classification

4. CONCLUSION

The hydatid cyst of the psoas is rare and must be evoked before any lumbar or iliac cystic mass, especially in hydatid-endemic countries. Most cases are secondary to rupture or spillage of liver hydatid cysts, although they can sometimes be primary.

The diagnosis is based on ultrasound and CT scans; biology provides additional elements.

Pericystectomy remains the treatment of choice in combination with medical treatment, which is helpful in the event of a rupture or multiple locations. The prognosis remains favorable in the absence of other locations or morbid complications. However, the best treatment is based on the prevention of hydatidosis.

CONSENT

Written informed consent was obtained from the patient for publication of this case report and any accompanying images.

REFERENCES

1. K. Abbassioun & A. Amirjamshidi, "Diagnosis And Management Of Hydatid Cyst Of The Central Nervous System: Part 1: General Considerations And Hydatid

Disease Of The Brain":, Neurosurgery Quarterly, Vol. 11, No 1, P. 1–9, March 2001,.

2. M. Soufi et al., "Hydatid Cyst of the Psoas Muscle Revealed by a Febrile Abdominal Mass: About a Case", Afr J Urol, Vol. 15, No 1, P. 72, March 2011.

3. O. Derfoufi Et Al., "Epidemiological Profile Of Cystic Echinococcosis In Morocco From 1980 To 2008", Annales De Biologie Clinique, Vol. 70, No 4, P. 457-461, July. 2012.

4. Ben Ayed M, Kamoun N, Makni K, Ben Romdhane K. Hydatid cyst: 281 cases, of which 86 cases had an unusual localization, seen during a 10-year period (1972-1981). Tunis Med 1986;64:389-95.

5. Mseddi M, Mtaoumi M, Dahmene J, et al. Muscular hydatid cyst Apropos of 11 cases. Rev Chir Orthop 2005;91:267-71.

6. Joseph F. Baker, Darren F. Lui, Margaret Cavanagh, and Brain J . Hurson, "Compressive Femoral Neuropathy Secondary To A Hydatid Cyst Of The Iliopsoas Muscle", Revue Du Rhumatisme, Vol. 77, 2010.

7. Benazzouz And E. A. Essaid, "Percutaneous Treatment Of The Hydatid Cyst Of The Liver", Emc - Hépatologie, Vol. 1, No 4, P. 131-137, Oct. 2004.

8. A. Agoumi, Summary of Medical Parasitology. Rabat (Morocco), Morocco: Editions Horizons Internationales, 2003.

9. H. Bedioui Et Al., "[Primary Hydatid Cyst Of The Psoas Muscle: Description Of 9 Cases In Tunisia And Review Of The Literature]", Med Trop (Mars), Vol. 68, No 3, P. 261-266, June 2008.

10. Ouzaa M.R Et Al., "Voluminous Muscular Hydatid Cysts About Three Cases", Moroccan Journal of Orthopedic and Traumatological Surgery, No 71, 2017.

11. Bedioui H, Noura K, Daghfous A, et al. Primary hydatid cyst of the psoas: 9 Tunisian cases and review of the literature. Med Trop 2008;68:261-6.

12. K. Rafiqi et al., "Primary hydatid cyst of the thigh in a bodybuilder. Apropos of a Case and Review of the Literature", Journal de Traumatologie du Sport, Vol. 33, No 2, P. 107-109, June 2016.

13. Kafih M, Ajbai M, Ridai M, Idrissi H, Zerouali O. Hydatid cysts of the psoas muscle. Ann Gastroenterol Hepatol 1993;29:110-2.

14. M. Soufi Et Al., "Osteoarticular - Hydatid Cyst Of The Psoas: About Two Cas", Dec. 2010.

15. Melis M, Marongiu L, Scintu F, et al. Primary hydatid cysts of psoas muscle. ANZ

J Surg 2002;72:443-5.

16. Amar I, Gamier J, Faraj A, et al. Isolated retroperitoneal hydatid cyst (apropos of two new cases). J Urol 1983;89:147-52.

17. Benchekroun A, Jira H, Cheikhani OJ, et al. Hydatid cyst of the psoas apropos of a case. Ann Urol 2001;35:108-10.

18. Kehila M, Allegue M, Abdelassem M, et al. Hydatid cyst of the psoas muscle. About a case. J Radiol 1987;68:265-8.

19. Hammami T, Noomane F, Ketata M, et al: Muscular hydatid cyst of the thigh. About 3 sightings. Rev Chir Orthop 2002;88:193-6.

20. Gharbi HA, Hassine W, Branner MW. Ultrasound examination of hydatid liver. Radiology 1981;139:459-63.

21. Saez J, Pinto P, Apt W, Zulantay I. Cystic echinococcosis of the tongue leading to diagnosis of multiple localizations. Am J Trop Med Hyg 2001;65:338-40.

22. Von Sinner WN, Stridbeck H, Hydatid disease of the spleen. Ultrasonography, CT and MR imaging. Acta Radiol 1992; 33:459-61.

23. Gossios KJ, Kontoyiannis DS, Dasclogiannaki M, Gourtsoyiannis NC. Uncommon locations of hydatid disease: CT appearances. Eur Radiol 1997;7:1303-8.

24. Ben M'Rad S, Mathlouthi A, Merai S, et al. Multiple hydatidosis of the thigh: role of magnetic resonance imaging. J Radiol 1998;79:877-9.

25. El Malki HO, El Mejdoubi Y, Bouslami B, et al. Hydatid cyst of the psoas muscle. Notebooks for French-speaking studies and research. Health 2007;17:177-9.

26. Oubejja H, Khalloufi N, Kisra M, Ettayeb F. Laparoscopic treatment of a hydatid cyst of the psoas apropos of a case. J Coelio Chir 2008;68:14-16.

27. Vissot E, Putot Jp, Decos V, et al: Hydatid cyst of the psoas, diagnosis using CT scanner. J Chir 1984, 121, 7-9.

UNDER PEER REVIEW