

Original Research Article

HISTOLOGICAL EFFECT OF AQUEOUS EXTRACT OF TAMARIND PULP ON THE CEREBRAL CORTEX OF ADULT WISTAR RAT

ABSTRACT

Investigation on the effect of aqueous extract of tamarind pulp on the histoarchitecture of cerebral cortex in 25 adult Wistar rat under five treatment groups including control, conducted at the Department of Anatomy, Nnamdi Azikiwe University Nnewi Campus. The rats were grouped into 5 groups. Groups A, B, C & D were the experimental groups exposed to 200,400, 600 and 800mg/kg while group E was the control group and received food and water only. Extract was administered orally for 21 days after which the animals were weighed and sacrificed by cervical dislocation. The results showed there was significant increase in the mean body weight of the rats in all groups at the final stage compared to the initial. This shows that the extract administered did not adversely affect the body weight of rats in the experimental groups. The sections of cerebral cortex of the rats in all the groups (A, B, C, D and E) showed normal layers of cells. In conclusion tamarind has no adverse effect on the histology of the cerebral cortex of adult Wistar rats.

Keywords: tamarind pulp, histoarchitecture, histology, cerebral cortex

INTRODUCTION

Tamarind(*Tamarindus indica*), belongs to the Fabaceae family. It is indigenous to tropical Africa, cultivated in Cameroon, Nigeria and Tanzania. It is widely distributed throughout the Tropical belt, from Africa to South Asia, and throughout South East Asia, Taiwan and as far as China. In the 16th century, it was heavily introduced to Mexico as well as South America by Spanish and Portuguese colonists, to the degree that it became a common ingredient in those places (Mortal et al, 1987). There are several varieties of tamarind. Some yield fruits that are very sweet, without the slightest trace of sourness. The fruit is an indehiscent legume, sometimes called a pod, 12 to 15 cm in length with a hard, brown shell (Tamale et al, 1995). It is mature when the flesh is coloured brown or reddish-brown. The tamarinds of Asia have longer pods containing 6-12 seeds, whereas African and West Indian varieties have short pods containing 1-6 seeds. The seeds are somewhat flattened, and glossy brown. The tamarind is best described as sweet and sour in taste, and high in acid, sugar, vitamin B and, calcium (Popenoe, 1974).

The fruit pulp is edible and popular in Indian cuisine. The immature pods and flowers are also pickled and used as a side dish. In Egypt, a sour, chilled drink made from tamarind is popular during the summer. In southern Kenya, the Swahili people use it to garnish legumes and also make juices. In Madagascar, its fruits and leaves are a well-known favorite of the Ring-tailed Lemurs, providing as much as 50% of their food resources during the year. In Northern Nigeria, it is used with millet powder to prepare Kunun Tsamiya, a traditional Pap mostly used as breakfast, and usually eaten with bean cake. In Lebanon, the Kazouza company sells a tamarind-flavoured carbonated beverage. In the Philippines, tamarind is used in foods like sinigang soup,

and also made into candies. The leaves are also used in sinampalukan soup. In Thailand a specific cultivar has been bred specifically to be eaten as a fresh fruit, famous for being particularly sweet and minimally sour. It is also sometimes eaten preserved in sugar with chili as a sweet-and-spicy candy (Burkill, 1997).

Tamarind is used in Indian Ayurvedic Medicine for gastric problems, and in cardioprotective activity. Other medicinal uses include anthelmintic (worm expellant), antimicrobial and antiseptic effects. Other reported benefits in folklore include antiviral, astringent, antibacterial (erysipelas), boils, chest pain, cholesterol metabolism disorders, colds, colic, conjunctivitis, constipation (chronic or acute), diabetes, diarrhea (chronic), dry eyes, dysentery, eye inflammation, fever, gallbladder disorders, gastrointestinal disorders, gingivitis, hemorrhoids, indigestion, jaundice, keratitis (inflammation of the cornea), leprosy, liver disorders, nausea and vomiting (pregnancy-related), paralysis, poisoning (Datura plant), rash, rheumatism, saliva production, skin disinfectant, sore throat, sores, sprains, sunscreen, sunstroke, swelling (joints), urinary stones and wound healing. It is also anti-bilious and anti-scorbutic. The pulp of the fruit is useful in constipation (Doughari, 2006). The seeds are sometimes used by children in traditional board games such as Chinese checkers (China), Dhakon (Java), and others. The tamarind tree is the official plant of Santa Clara, Cuba. Consequently it appears in the coat of arms of the city (Burkill, 1997).

Tamarind has a variety of uses. The leaves and seeds are astringent. Tender leaves and flowers have a cooling effect. The bark is astringent and serves as a tonic. Its use in cooking is well known and is much in vogue particularly in South India. Added in proper measure. Tamarind is beneficial to health, excessive use may prove harmful to the body (Tona, 1998). The pulp of the ripe fruit along with the skin of dates or gur mixed freely in water, stirred and filtered, along with pepper, cardamom, clove and a little salt makes a very tasty and delicious ream, which is often taken along with food. The pulp is also used for seasoning, in prepared foods, to flavour confections, curries and sauces, and as a major ingredient in juices and other beverages (Abubakar et al, 2008). Tamarind is efficacious in preventing or curing scurvy. In short, tamarind which is widely used in cooking, has numerous medicinal applications (Doughari, 2006). The aim of this study therefore is to determine the effect of oral administration of tamarind pulp extract on the histoarchitecture of the cerebral cortex of adult Wistar rat.

The recorded use of tamarind in the treatment of ailments dates back to antiquity (Sofowora, 1993). It is applied on inflammations, used to gargle sour throat, mixed with salt as a liniment for rheumatism, relieve pains, reduce secondary bacterial infection and promote healing (Fabiya, 1993). Plants are recognized for their ability to produce a wealth of secondary metabolites and mankind has used many species for centuries to treat a variety of diseases (Cragg et al. 1999). It has been stated that the pulp and especially the leaves of tamarind could be a promising antifungal agent and the result confirms the use of this plant in traditional medicine for the

treatment of fungal infections (Verpoorte, 2000). The antibacterial and antifungal activities varied with the species of the plant and plant material used (Bai, 1990). Tamarind is beneficial to health, excessive use may prove harmful to the body, Sometimes it is given to patients suffering from fever, sunstroke and inflammatory conditions (Tona, 1998). (Mahesh and Satish, 2008). (Bryce, 1992) (Ajaiyeoba *et al.*, 1998) and *Khaya ivorensis* and *Tetracera potatoria* (Adekunle *et al.*, 2003).

Phytochemical studies revealed the presence of tannins, saponins, sesquiterpenes, alkaloids and phlobatamins and other extracts active against both gram positive and gram negative bacteria, at temperatures of 4–30 °C (39–86 °F) (Ahmad, 2001). Studies on the minimum inhibitory concentration (MIC) and minimum bactericidal concentration (MBC) of the extracts on the test organisms showed that the lowest MIC and the MBC were demonstrated against *Salmonella paratyphi*, *Bacillus subtilis* and *Salmonella typhi* and the highest MIC and MBC was exhibited against *Staphylococcus aureus* (Doughari, 2006). In animal studies, tamarind has been found to lower serum cholesterol and blood sugar levels. Due to a lack of available human clinical trials, there is insufficient evidence to recommend tamarind for the treatment of hypercholesterolemia or diabetes. Based on human study, tamarind intake may delay the progression of fluorosis by enhancing excretion of fluoride (Oliver, 1960). Study of the aqueous extract of tamarind seed showed potent antidiabetogenic activity that reduced blood sugar in streptozotocin-induced diabetic male rats lowered blood glucose level (Maiti, 2004).

The optimal effectiveness of a medicinal plant may not be due to one main active constituent, but may be due to the combine action of different compounds originally in the plant (Bai, 1990). Leaves and seeds are astringent while tender leaves and flowers possess antibilious properties. Bark is reported to be prescribed in asthma, amenorrhoea and afebrifuge (Yusuf *et al.*, 1994). Tamarind fruits have been investigated for its cholesterol-lowering effect on rat, the effect of dried and pulverized pulp of Tamarind fruit (oral administration) on serum cholesterol, HDL- and LDL-cholesterol and triglycerides have been studied in human models to look for their possible cholesterol lowering activity (Ukwuani, 2008) (Abubakar, 2008).

The cerebral cortex includes the cerebral hemispheres and basal ganglia. The cerebral hemispheres, separated by the cerebral falx, are visible within the longitudinal cerebral fissure. Each cerebral hemisphere is divided into four lobes, each of which is related to the overlying bones of the same name. From a superior view, the cerebrum is essentially divided into quarters by the median longitudinal cerebral fissure and the coronal central sulcus. The hemispheres occupy the entire supratentorial cranial cavity. The frontal lobes occupy the anterior cranial fossae, the temporal lobes occupy the anterior cranial fossae, and the occipital lobes extend posteriorly over the cerebellar tentorium (Moore and Darley, 2006). The cerebral hemispheres consist of a convoluted cortex of grey matter overlying the cerebral medullary mass of white matter which conveys fibers between different parts of the cortex and to and from other parts of the CNS. Histologically, the neurons of the cerebral cortex are divided into five different morphological types which are arranged in several layers. In sub-mammalian species, the major function of the cortex concerns the sense of olfaction and the neurons are arranged into three layers. In mammals the neocortex consists of six layers of neurons. The neocortex includes the

sensory and motor areas of the cortex as well as the association cortex and constitutes about 90% of the cerebral cortex (Young et al, 2006).

The pyramidal and satellite neurons are by far the most common types of neurons in the cerebral cortex (Young, 2000). Pyramidal cells, as their name implies have pyramid shaped cell bodies the apex being directed toward the cortical surface. The huge upper motor neurons of the motor cortex known as bertz cells are the largest of the pyramidal cells in the cortex. Satellite (granule cells) are small neurons with a short vertical axon and several short branching dendrites giving the cell body the shape of a star ; basket and neuroglia form subtypes the cells look like small granules giving rise to their alternative name. Cells of Martinotti are small polygonal cells with a few short dendrites; the axon extends towards the surface and bifurcates to run horizontally usually in the most superficial layer. Horizontal cells of Cajal are small and spindle shaped but oriented parallel to the surface. They are the least common cell type and are only found in the most superficial layer where their axon pass laterally to synapse with the dendrites of the pyramidal cells. Layers of the neocortex, in the neocortex are arranged into six layers with neurons differing in morphology, size and population density. The layers merge with one another rather than being highly demarcated and vary somewhat from one region of the cortex to another depending on cortical thickness and function (Young, 2000).

Plexiform or molecular layer is the most superficial layer mainly contain dendrites axons of cortical neurons making synapse with one another the sparse nuclei are those of neuroglia are occasional horizontal cells of cajal. Outer granular layer is this dense population of small pyramidal cells and satellite cells make up this thin layer which also contains various axon and dendrite connections from deeper layers. Pyramidal cells layer are moderate size predominant in this broad layer, the cells increasing in size deeper in the layer. Inner granular layer consist of mainly of densely packaged satellite cells. Gang ionic layer is a large pyramidal cell and smaller numbers of satellite cells and cells of martinotti make up this layer, the name of the layer originating from the huge pyramidal (ganglion) bertz cells of the motor cortex. Multiform cells layer is so named for a wide variety of differing morphological form found in this layer. It contain numerous small pyramidal cells and cells of martiontti, as well as satellite cells, especially superficially and fusiform cells in the deeper part (Young, 2000).

MATERIALS AND METHOD

MATERIALS

Some materials used for this research include digital weighing balance (New Jersey, USA), Analytical beam balance, Measuring cylinder (Maramber, Britain), Hot air oven, Rubber feeders, Distilled Water, 50mls beaker, string, orogastric tube, distilled water, light microscope, Digital camera, Scalpel, Thread, Cages, Razor blades, Bouin' s fluid, Heamatoxylin and Eosin Stain.

PLANT MATERIALS

The tamarind fruits were obtained from nkwo nnewi market. The tamarind fruit was authenticated at the department of pharmacology, Nnamdi Azikiwe University Nnewi. 600gram of the dried tamarind fruit was weighed on analytical beam balance and then soaked in 5 liter round-bottom flask and distilled water was added above the level of the tamarind fruit for 4

hours, after which it was vigorously shaken and then decanted and filtered to remove the debris. The filtrate is poured on a tray and concentrated on a hot air oven at 40-50°C. Phytochemical analysis was carried out the result showed the presences of carbohydrates, cordiac glycosides, saponin glycosides and flavonoids.

EXPERIMENTAL PROTOCOL

Twenty five male Wistar rats, weighing between 126.5g-162.2g were obtained from the Departmental Animal House. They were kept and acclimatized for 14 days period, and fed with pelletized rat chow and water ad libitum throughout the period of the research. The rats were weighed using a digital weighing balance available at the Histology lab of the Department of Anatomy after the 2-weeks acclimatization period for INITIAL weight. The rats were housed in plastic cages in the animal house of the department and grouped into 5; A, B, C, D and E of 5 rats in each group. Group A received feed and water, and 200mg of aqueous extract of tamarind pulp, Group B received water, feed and 400mg of aqueous extract of tamarind pulp, Group C received water, feed and 600mg of aqueous extract of tamarind pulp, Group D received 800mg of aqueous extract of tamarind pulp, and Group E served as control receiving only water and feed. The increasing volume of aqueous extract of tamarind pulp administered was based on arithmetic progression. The administration was done via oral intubation which lasted for 21 days, after which the rats were weighed for FINAL weight, and sacrificed by cervical dislocation.

HISTOLOGICAL PROCEDURE

The whole brain was removed and fixed in bouin's solution containing saturated aqueous picric acid (75ml), 40% formaldehyde (25ml), and glacial acetic acid (5ml). The tissue were dehydrated in ascending grade concentration of alcohol, cleared in xylene and embedded in paraffin wax. Serial sections of 5micron were obtained using rotatory microtome. The deparaffinized sections were stained routinely with heamatoxylin and eosin stain. Photomicrographs of the results were obtained using research photographic microscope in the histopathology section of the department.

STATISTICAL ANALYSIS

Statistical analysis was performed using the numerical data obtained from the study and were expressed as the Mean \pm Standard error of mean (S.E.M). Differences among means of control and treated groups were determined using statistical package for social sciences (SPSS) version 23.0. A probability level of greater than 5% ($P > 0.05$) was considered not significant.

RESULTS

TABLE 1: EFFECT OF AQUEOUS EXTRACT TAMARIND PULP ON THE MEAN BODY WEIGHT OF WISTER RAT

GROUPS	DOSAGE mg/kg	INITIAL WEIGHT(g)	FINAL WEIGHT(g)	DIFFERENCE IN WEIGHT(g)
A	200	144.9±5.6	168.9±7.5	24.0±1.5
B	400	153.1±4.3	186.6±8.3	33.5±5.0
C	600	137.9±5.3	155.6±8.4	17.7±3.1
D	1000	139.6±7.2	159.3±10.9	19.7±3.7
E	Control	151.9±5.5	181.1±10.04	29.2±4.9

P value is < 0.05

The table 1 with ($P < 0.05$) is said to be very significant. There was steady increase in the mean body weight of the rats.

HISTOLOGICAL OBSERVATIONS

After the histological preparation with H&E, microscopic observation were carried out with binuclear light microscope and auto micrograph of each slide was taken using photographic set. The following observations were made, the sections of cerebral cortex of the rat in control appeared normal (Plate 1).The sections receiving 200mg/kg also shows normal layer and structure of the cerebral cortex as in the control (Plate: 2).The sections of cerebral cortex of rat receiving 400mg/kg, 600mg/kg and 800mg/kg show no significant difference in observation in the section of rats in the control group as shown in (Plate: 3, Plate:4, and Plate:5 respectively).

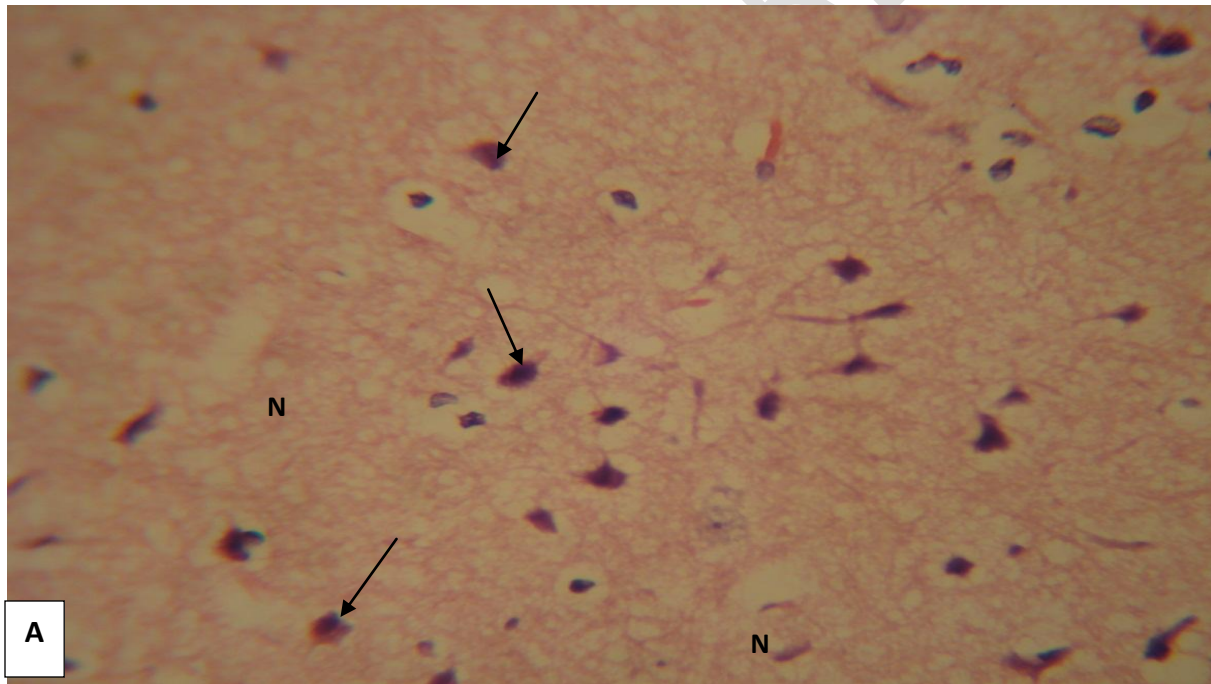
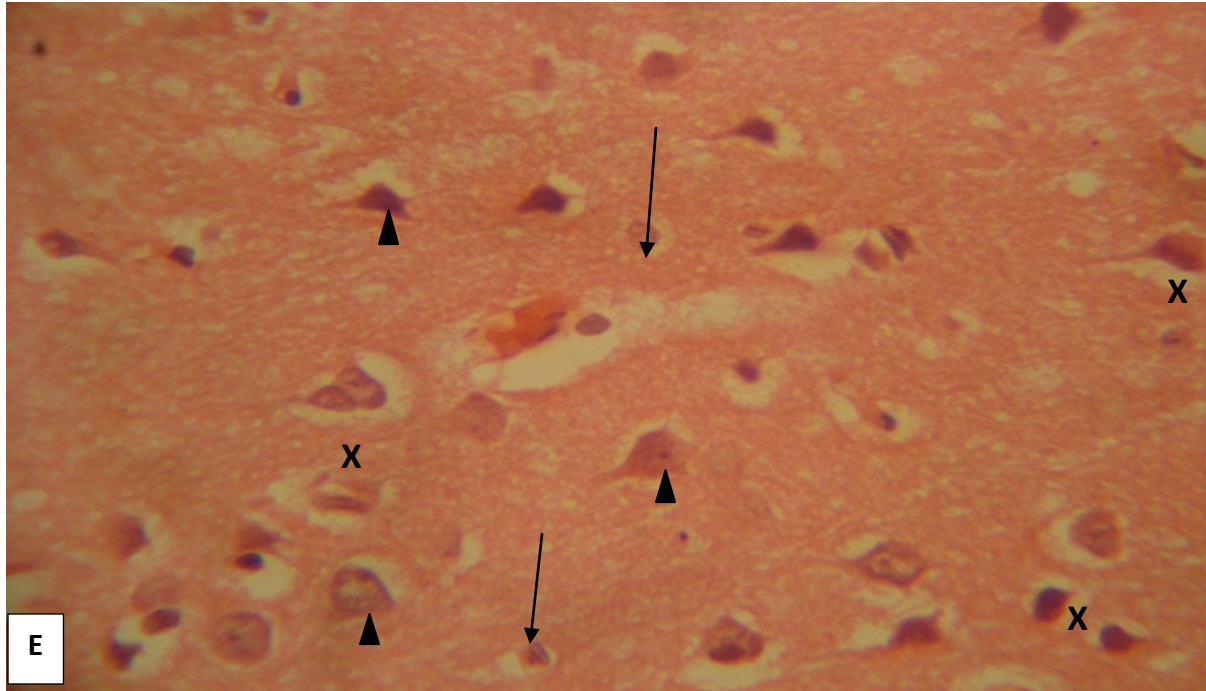


Plate 1: Photomicrograph of Wistar rat cerebral cortex from control group (E) showing normal cerebral cortex with moderate pyramidal cell (arrow heads), neuroglia cell nucleus (arrows) and polymorphic cell body (X) H&E. x400.

Plate.2 - Photomicrograph of rat cerebral cortex from group B that received 200mgkg^{-1} of tamarind pulp extract showing normal pyramidal cells (arrows) and neurophil spaces (N) H&E x400

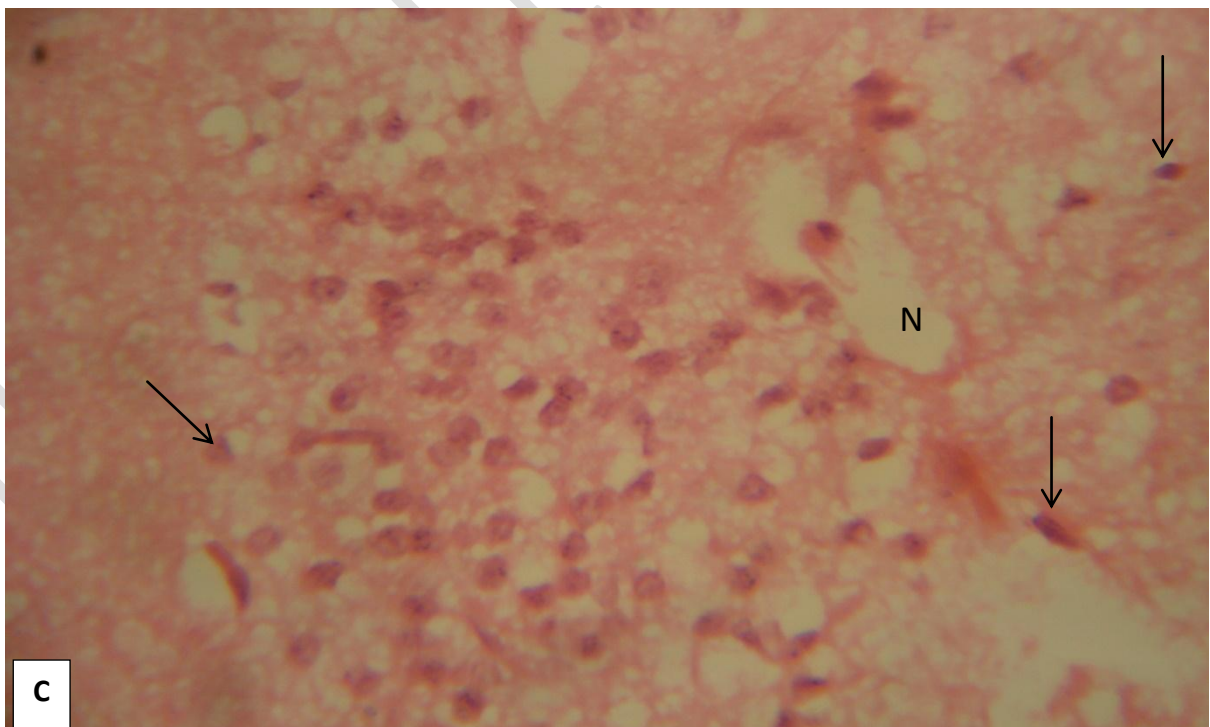
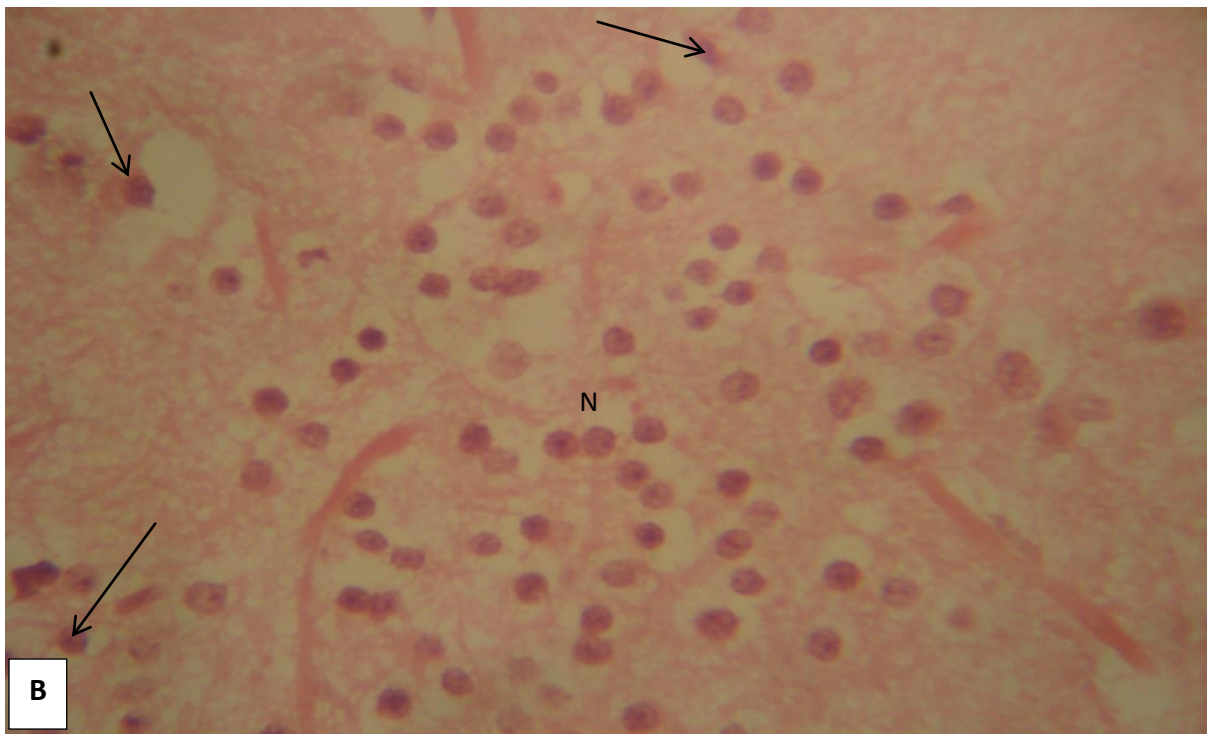


Plate 3: Photomicrograph of rat cerebral cortex from group B that received 400mgkg^{-1} of tamarind pulp extract showing normal pyramidal cells (arrows) and neurophil spaces (N).

Plate 4: Photomicrograph of rat cerebral cortex from group C that received 600mgkg^{-1} of tamarind pulp extract showing normal pyramidal cells and neurophil spaces (N) H&E x400.

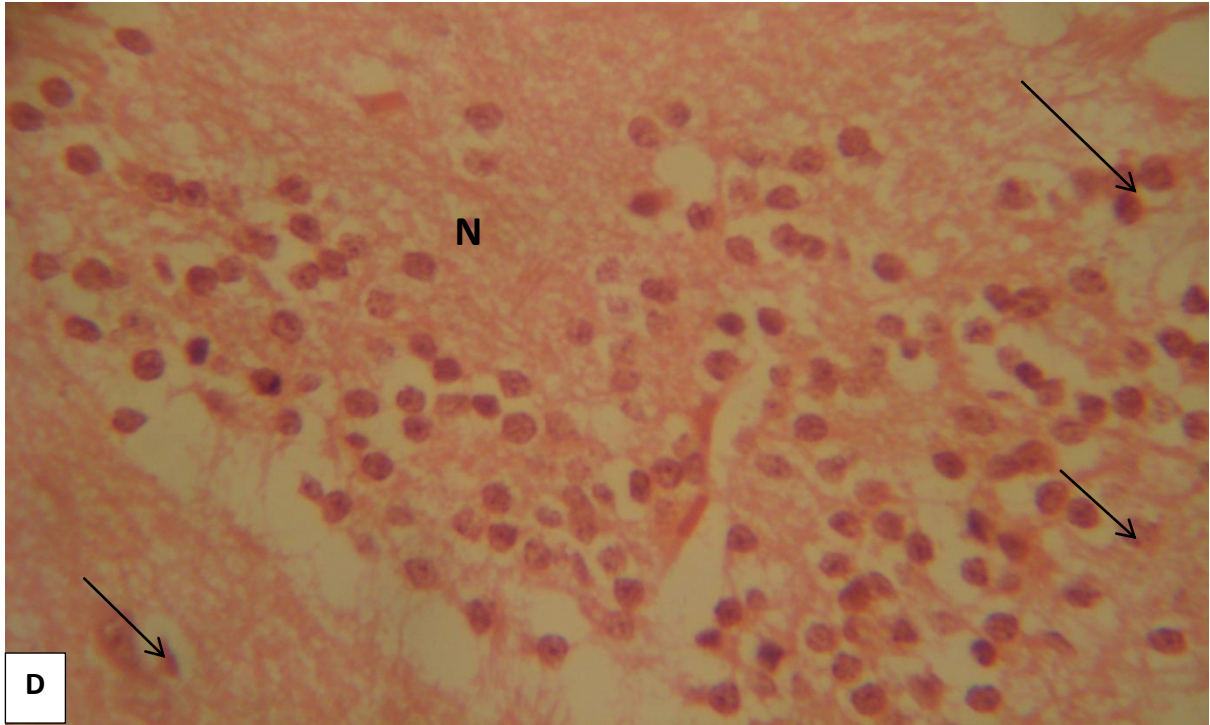


Plate 5: Photomicrograph of rat cerebral cortex from group D rats that received 800mgkg^{-1} of tamarind pulp extract showing normal pyramidal cells (arrows) and neurophil spaces (N) H&E x400

DISCUSSION AND CONCLUSION

DISCUSSION

Effect of acute oral administration of tamarind pulp extract showed significant increase on the mean body weight of the rats that were in the experimental groups (A-D), there was a steady increase in weight of the rat when compared with the control group (E). Mean, Standard error of mean (S.E.M) and P-values also for independent sample t-test at 95% significance level are included in table 1. The average body weight of 5 rats in control was 166.5 kg and 155.7 kg for experimental group after taking tamarind. P-value for independent sample t-test was <0.05 , this indicates that there is significant increase on body weight. After administration of tamarind to the rats however, it was observed that, oral administration of tamarind had no significant impact on mean body weight.

From histological observations, group (A) that received 200mg/kg and group (E) the control showed normal histological features with normal molecular and granular layers. Group (B-D)

that received 400mg/kg, 600mg/kg and 800mg/kg of the aqueous tamarind pulp extract showed normal molecular layer and granular layer as well, with moderate pyramidal cells and neutrophil space as seen on the control and the experimental groups. Ukwuani (2008) investigated, the effect of dried and pulverized pulp of Tamarind fruit (oral administration) for cholesterol and Low density lipoprotein (LDL) and was proven to be reducing agent and above all relatively safe for human consumption (Abubakar *et al*, 2008).

CONCLUSION

This study demonstrated that consumption of aqueous tamarind pulp extract for 21 consecutive days had no adverse significant effect on the histology of the cerebral cortex of Wistar rats. The aqueous extract of the tamarind pulp has no significant effect on the mean body weight of rats and it was observed that there was uniform increase in weight between the experimental animals and the control. It is therefore recommended that further study be carried out on other organs of the body with the extract and for more than 21 days.

REFERENCES

- Abubakar, M.G., Ukwuani A. N. and Shehu R. A. (2008). An evaluation of the toxic effect of *Tamarindus indica* pulp in rats. *Journal of pharmacology and toxicology*. 3(2): 111-118.
- Adekunle A. A. (2001). Ethnobotanical studies of some medicinal plants from Lagos State of Nigeria. *Nigerian Journal of Botany*. 14: 71 – 79.
- Adekunle, A. A., Duru, C. and Odufuwa, O. M. (2003). Antifungal activity and phytochemical screening of the crude extracts of *Khaya ivorensis* JUSS (Meliaceae) and *Tetracera potatoria* L (Dilleniaceae). *South African Journal of Botany*. 69: 568– 571.
- Ahmad, I. and Beg, A. Z. (2001). Antimicrobial and phytochemical studies on 45 Indian medicinal plants against multi-drug resistant human pathogens *Journal of Ethnopharmacology*, 74, 113-123.
- Ajaiyeoba, E. O., Rahman, A. W. and Chondhary, I. M. (1998). Preliminary antifungal and cytotoxicity studies of extracts of *Ritchiea capparoides* var. *longipedicallata*. *J Ethnopharmacol*. 62: 243– 246.
- Brust JCM (2000). Coma. In Rowland LP Merritt's Textbook of neurology, 10th edition. Baltimore, Lippincott Williams and Wilkins, Pp. 78
- Bryce, K. (1992). The Fifth kingdom. Mycologue Publications, Ontario; Pp: 451

- Burkill, H. M. (1997). The useful plants of the west tropical Africa. Vol 2. Royal Botanic Garden, Kew. Pp: 969.
- Chiariandy, C. M., Seaforth, C. E., Phelps, R. H., Pollard, G. V. and Khambay, B. P. (1999). Screening of medicinal plants from Trinidad and Tobago for antimicrobial and insecticidal properties. *Journal of Ethnopharmacology*, 64, 265-270.
- Cragg, G. M., Boyd, M. R., Khanna, R., Kneller, R., Mays, T. D., Mazan, K. D., Newman, D. J. and Sausville, E. A. (1999). International collaboration in drug discovery and development: the NCI experience. *Pure Appl Chem* 71: 1619-1633.
- Cragg, G.M. and Newman, D. J. (2005). Biodiversity: A continuing source of novel drug leads. *Pure Appl. Chem.*, 77(1): 7– 24.
- Doughari, J. H. (December 2006). "Antimicrobial Activity of *Tamarindus indica*". *Tropical Journal of Pharmaceutical Research* 5 (2): 597– 603.
- Fabiyi, J. P., Kela, S. L., Tal, K. M., and Istifamus, W. A. (1993). Traditional therapy of dracunculiasis in the state of bauchi, Nigeria. *Dakar Med.*, 38: 193 – 195.
- Irobi, O. N. and Daramola, S. O. (1993). Antifungal activities of crude extracts of *Mitracarpus villosus* (Rubiaceae). *J Ethnopharmacol.* 40: 137– 140
- Iwu, M. W., Duncan, A. R. and Okunji, C. O. (1999). New Antimicrobials of Plant origin In: J.Janick (ed.), *Perspectives on New Crops and New Uses*. ASHS Press, Alexandria, VA. Pp. 457-462.
- Keay, R. W. J., Onochie, C. F. A. and Stanfield, D. F. (1964). *Nigerian Trees*. Nigeria National Press Ltd, Lagos; Pp: 495.
- Keith L. Moore and Dalley F. A. (2006): *Brain, Clinical Oriented Anatomy*.
- Khambay, B.P (1999). Screening of medicinal plants from Trinidad and Tobago for antimicrobial and insecticidal properties. *Journal of Ethnopharmacology*, 64, 265-270.
- Kudi, A. C., Uhoh, J. U., Eduvie, L. O. and Gefu, J. (1999). Screening of some Nigerian medicinal plants for antibacterial activity. *Journal of Ethnopharmacology*, 67, 225-228.
- Mahesh, B. and Satish, S. (2008). Antimicrobial activity of some important medicinal plant against plant and human pathogens. *World Journal of Agricultural Sciences* 4 (S): 839-843.
- Moore KL, Persuade, (2003). *TVN: The developing Human: clinically oriented embryology* 7th edition Philadelphia, Saunders. Pp.234
- Morton, J., (1987). *Tamarinds*. In: *fruits of the cimates*. Pp 115 – 121. Maimi, FL
- Morton, Julia F. (1987). *Fruits of Warm Climates*, Wipf and Stock Publishers. Pp. 115– 121.
- ofnoveldrug leads. *Pure Appl. Chem.*, 77(1): 7– 24.
- Okeke, M. I., Iroegbu, C. U., Eze, E. N., Okoli, A. S. and Esimone, C. O. (2001). Evaluation of extracts of the root of *Landolphia owerrience* for antibacterial activity. *Journal of Ethnopharmacology*, 78, 119-127.
- Oliver, B. E. P.(1960). *Medicinal Plants in Nigeria*. Nigerian College of Arts, Scienceand Technology, Lagos; Pp: 70.
- Popenoe, W. (1974). *Manual of Tropical and Subtropical Fruits*. Hafner Press.Pp. 432– 436.

- Sacco RL,(2000).Pathogenesis classification and epidemiology of cerebrovascular disease. In Rowland LP (ed): Merritt' s Textbook of Neurology 10th edition Baltimore Lippincott William' s ' and Wilkins.
- Sofowora, A. E. (1982). Medicinal plants and traditional medicine in Africa Vol 1. John Wiley and Sons, New York; Pp: 251.
- Sofowora, A. E. (1993). Medicinal Plants and traditional medicine in Africa. Vol 2.Spectrum Books Ltd, Ibadan; Pp 288.
- Tamale, E.; Jones, N.; Pswarayi-Riddihough, I. (August 1995).Technologies Related to Participatory Forestry in Tropical and Subtropical Countries. World Bank Publications.
- Tona, L., Kambu, K., Ngimbi, N., Cimanga, K. and Vlietinck, Z. A. (1998). Antiamoebic and phytochemical screening of some Congolese medicinal plants. J. Ethnopharmacol., 61: 57-65.
- Ukwuani, A. N., Abubakar, M. G., Shehu, R. A. and Hassan, L. G. (2008). Antiobesity effects of pulp extract of Tamarindus indica pulp in rats. Journal of pharmacology and toxicology. 3(4): 221-227.
- Verpoorte, R. (1998). Exploration of nature' s chemodiversity: the role of secondary metabolites as leads in drug development. Drug Develop Trends 3: 232-238.
- Verpoorte, R. (2000). Pharmacognosy in the new millennium: lead finding and biotechnology. J Pharm Pharmacol 52: 253-262.