

Advanced Platelet-Rich Fibrin (A-PRF) Associated with the Tunneling Technique in the Treatment of Cairo Type 1 Gingival Recessions: Randomized and Blinded Clinical Study

ABSTRACT

The use of advanced platelet-rich fibrin (A-PRF) has presented good results in periodontal plastic surgery for treatment of gingival recessions. The present study aims at assessing the effectiveness of the use of A-PRF in root coverage and periodontal clinical parameters of patients with Cairo Type 1 gingival recession. Forty four (44) bilateral Cairo Type 1 gingival recessions were selected. The recessions were split in two groups according to the surgical procedure made (n=44): SCTG: Subepithelial Connective Tissue Graft and A-PRF, using tunnel surgical technique in both sides. The patients were monitored on 0, 90, and 180 days for assessment of the recession height and width; probing depth and bleeding on probing; clinical attachment level; keratinized tissue band width; thickness of keratinized gingival tissue and sensitivity level. The data obtained were initially analyzed and assessed with SHAPIRO-WILK test for normality and later ANOVA and TUKEY tests were used for normal data, or KRUSKALL-WALLIS and DUNN test for non-normal data. For analysis of sensitivity parameter, the test chosen was KRUSKALL-WALLIS and DUNN, with 5% significance level. In the analysis across groups the Student's *t*-test was conducted. Both groups presented improvement in periodontal parameters, however without significant statistical difference between them, which suggests that A-PRF can be an alternative to SCTG in root coverage surgeries of Cairo type 1 recession.

Keywords: platelet-rich fibrin; gingival recession; dentin hypersensitivity.

1. Introduction

Gingival recessions can cause esthetic damages to smile, in addition to bringing complications, like dentin hypersensitivity and cervical caries. Gingival recession is defined as the apical displacement of the gingival margin in relation to the cementoenamel junction (CEJ) and is associated to the loss of attachment and exposure of the root surface to the oral environment. The gingival inflammation in response to the accumulation of dental biofilm, or mechanical trauma caused by tooth brushing, has been indicated as main etiological factor of these injuries (Bedoya and Park, 2014; Öncü, 2017). Biofilm accumulation, local trauma and absence of gingival attachment are etiological factors associated to this pathology (Cortellini et al., 2018).

Its etiological factors can be divided into: triggering factors and predisposing factors (Fu J et al., 2012). The triggering factors include tooth-brushing trauma, occlusal trauma, gingival inflammation, iatrogenic treatments and tabagism (Borghetti A., 2002). The predisposing factors, on the other hand, are essentially the anatomic characteristics of the patient that can influence the occurrence of gingival recessions, such as: gingiva biotype, variations in the underlying bone morphology, incorrect dental position and the presence of high attachment and short vestibule frena (Fu J et al., 2012).

Currently, the most used classification is that of Cairo, whose parameter is the loss of interproximal attachment tissue: RT1) soft tissue recessions that do not present loss of interproximal attachment; RT2) when there is loss of interproximal attachment, with distance from the cementoenamel junction – CEJ in the bottom of sulcus shorter or equal to the vestibular attachment loss (measured from the CEJ to the bottom of vestibular sulcus); and RT3) Loss of interproximal attachment, with distance from CEJ to the sulcus bottom longer than the loss of vestibular attachment (Cairo et al., 2011; Steffens e Marcantonio, 2018).

Several surgical procedures were used for the treatment of gingival recessions in the last years, including the lateral repositioning of the flap, free gingival graft, tunneling surgery with and without subepithelial connective tissue (SCTG) graft, coronally positioned flap with or without SCTG, residual regeneration with membranes, acellular dermal matrix, platelet-rich plasma (PRP) and platelet-rich fibrin (PRF) (Aroca et al., 2009; Padma et al., 2013; Gupta et al., 2015; Tunali et al., 2015 Oncu et al., 2017).

The application of SCTG has been widely used in the treatment of gingival recessions, event presenting as its worse disadvantage the need of tissue from a donor area, which normally results in greater post-operative discomfort, and, in cases where several areas must be treated, a large amount of donor tissue is necessary. It is in this ambit that the L-PRF arises

as alternative, in terms of replacing the use of SCTG, because it demonstrates large amounts of growth factors, easiness to obtain, in addition to presenting a very favorable post-operative (Moraschini e Barboza, 2016).

The leukocyte- and platelet-rich fibrin (L – PRF) is a platelet aggregator obtained by blood centrifugation that started to be used in several tissue regeneration procedures in medicine and odontology after Choukroun studies in 2001. It is a framework of tridimensional fibrin with cells (leukocytes), growth factors, cytokines, and angiogenesis factors inside it, potentiating tissue repair and regeneration. In dentistry, it has been widely used in implants, bone reconstructions, and periodontal surgeries, as in the treatment of gingival recessions (Choukroun et al., 2016; Dohan et al., 2009; Aroca et al., 2009).

The A-PRF (*Advanced PRF*) effects have been reported for presenting a larger amount of cells (macrophages and monocytes) and larger amount of growth factors, due to its slower centrifugation, when compared to L-PRF (Kobayashi et al., 2016). The standard L-PRF was improved to A-PRF (*Advanced – PRF*) for having larger amounts of cells (macrophages and monocytes) and for supporting more release of growth factor in A-PRF (Ghanaati et al., 2014).

Normally, a shorter time of centrifugation increases the total number of cells contained in the PRF upper layer, producing a higher number of leukocytes “trapped” inside the fibrin matrix (Choukroun et al., 2006; Ghanaati et al., 2014; Kobayashi et al., 2016).

Thus, the objective of the present study was to assess the effectiveness of Advance platelet-rich fibrin (A-PRF) membranes associated to the tunnel technique for root coverage in patients with Cairo type 1 gingival recession for a period of 180 days.

2. Materials and Methods

The study conducted is of applied clinic nature, randomized, prospective with split-mouth and, parallel groups. It was conducted at the Clinics of Unioeste Cascavel Campus Odontology Course.

Forty four recessions were selected, of patients from 23 to 47 years old, of both sexes, that presented bilateral Cairo type 1 gingival recessions, with probing depth inferior to 3mm in all teeth, without gingiva inflammation and free of caries (Figure 1 and 2). Patients with history of systemic disease, smokers, pregnant women or breastfeeding women and those with previous surgeries in the recession location were excluded. The calculation of the sample size

to the number of gingival recessions was made with t-test for independent samples with test power of 80% and alpha level of 0.05. These data were based on previous studies of the researchers group (Tonet et al., 2010; Nassar et al., 2014; Spada et al., 2017).

The initial clinical/periodontal examination was conducted by a single operator, previously calibrated that, with **by Willians** n° 23 type periodontal probe, determined: 1. Recession height: measured as the distance from the cementoenamel junction to the gingival margin, in mm; 2. Recession width: mesio-distal distance of the gingival margin, measured in mm; 3. **Pocket Depth:** distance from the gingival margin (GM) to the bottom of the sulcus with presence or absence and measured in mm; 4. Bleeding on probing: at each three teeth with interval of approximately 30 seconds for record of the parameter, which corresponds to the probing time with record of presence or absence. 5. Clinical attachment level: distance from the cementoenamel junction (CEJ) to the bottom of the sulcus, with record of presence or absence, and measured in mm. Obtained from the sum of the gingival recession and the probing clinical depth; 6. Height of the keratinized tissue strip: the distance from the mucogingival junction to the gingival margin; 7. Thickness of the keratinized gingival tissue at three points (Mesial, central and distal); 8. Degree of sensitivity (U.S. Public Health Service modified index comprising three scores: 0 (Alpha) – no sensitivity; 2 (Bravo) – slight sensitivity; 3 (Charlie) – high sensitivity (Camilotti et al., 2012).

After the initial periodontal clinical examination, the recessions were randomly divided into two groups (Random Group Generator – Web Site - <https://pt.rakko.tools/tools/59/>), according to the treatments proposed in Figure 3. Each patient received both surgical techniques, in **hemiarch**, tunneling associated to subepithelial connective tissue (Tunneling + SCTG) and in the other hemiarch, tunneling associated to A-PRF membranes (Tunneling + A-PRF), and the distribution to hemiarchs was randomly made.

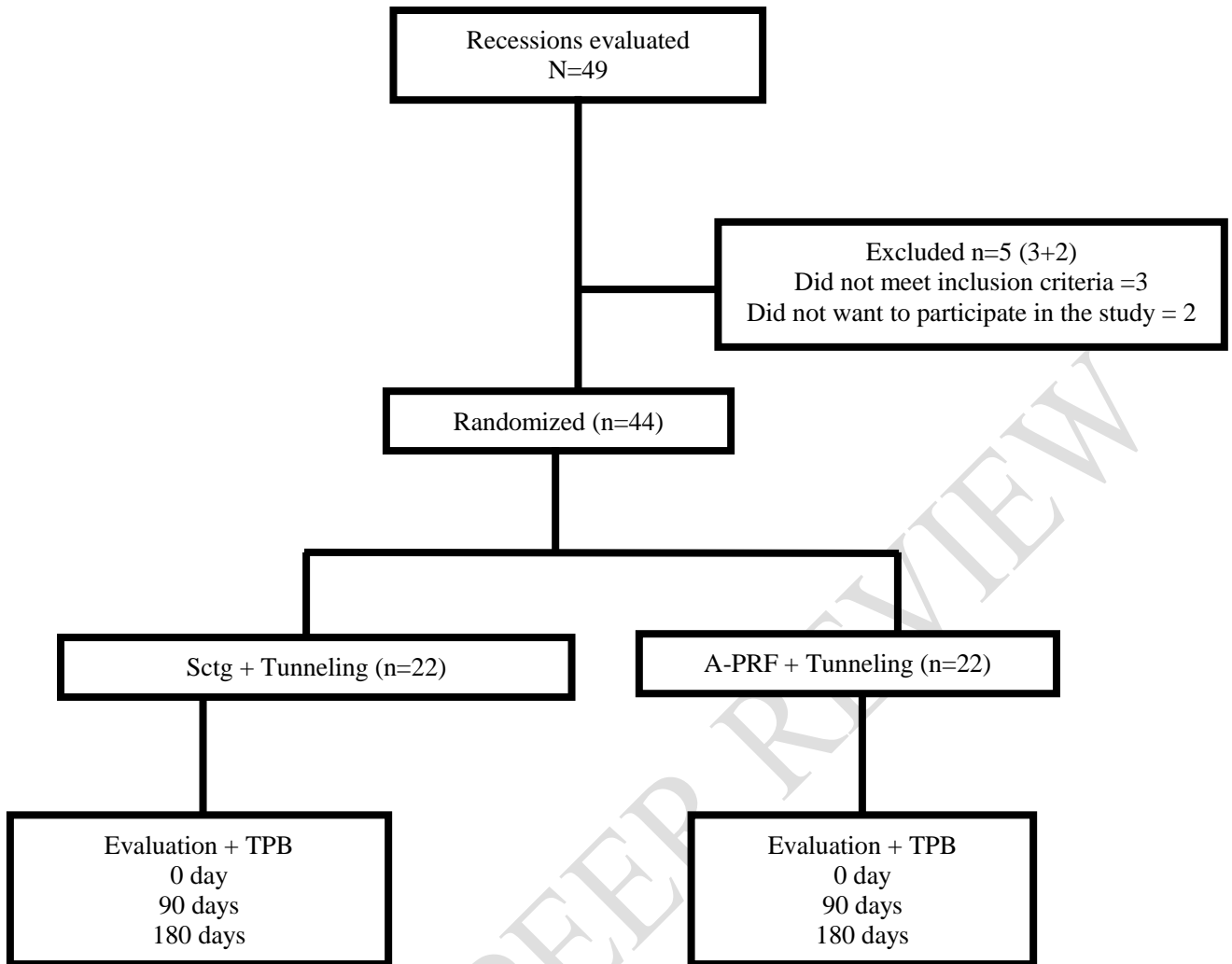


Figure 3. Distribution of the 44 recessions according to the treatments proposed.

2.1 Surgical techniques

2.1.1 Recipient bed preparation:

The two surgical techniques were performed in one single surgical act, and so, the bilateral receptor areas were simultaneously prepared. The receptor area was anesthetized with infiltrative terminal anesthesia, with anesthetic articaine 4% and epinephrine 1:100.000 (*DFL, Rio de Janeiro, RJ, Brazil*). Intra-sulcus incision was performed in the cervical region, at CEJ level, for mesial and distal with 15c blade (*Swann Morton, England*), creation of tunnel with tunnelers (*Supremo Instrumentais Cirúrgicos, São Paulo, Brazil*), by means of a flap with total thickness close to the gingival margin, until going beyond the mucogingival junction, so as to obtain a tissue without tensions. The tooth root was scraped and smoothed with periodontal curette, Gracey type, specific to the region, followed by abundant irrigation with saline solution 0.9%.

2.1.2 Obtention of the connective tissue graft and adaptation to the recipient bed (Tunneling + SCTG Group)

The subepithelial connective tissue graft was obtained from the palate, through single incision technique (linear incision) (Xavier e Alves, 2015). The donor region was sutured with simple sutures using Nylon 5.0 prolene (*SHALON[®] São Luis M. Belos, Goiás, Brazil*), then it was positioned on the gingival recession and stabilized in proximals with propylene thread 5.0 (*TECHSUTURE[®], Bauru, São Paulo, Brazil*) at CEJ level. It was later coronally tractioned with vertical sutures fixed in the incision/vestibular region of the dental elements involved, using polypropylene thread 5.0 (*TECHSUTURE[®], Bauru, São Paulo, Brazil*).

2.1.3 Preparation of Advanced Platelet-rich Fibrin and adaptation in the recipient bed (Tunneling + A-PRF Group)

Protocol for obtention and use of A-PRF (Choukroun and Ghanaati et al., 2018): 1st Stage: Venipuncture and blood collection; 2nd Stage: Cell separation (centrifugation); 3rd Stage: Preparation of A-PRF membranes. 1st Stage: Venipuncture and blood collection: Before starting the surgical procedure for root coverage, venipuncture of around 60 ml of blood was performed (according to the extension of the recipient bed). 2nd Stage: Cell separation (centrifugation): The blood collected was immediately placed in the centrifuge (*Centrifuga Spinlab, São Paulo, Brazil*), not exceeding 3 minutes, in 10 ml portions. The fibrin membranes were obtained by 1,500 rpm centrifugation for 14 minutes. When the centrifugation was finished, the tubes were collected, and the fibrin was not immediately removed. At least 30 minutes passed before its use in the surgical bed. 3rd Stage: Preparation of A-PRF membranes: With the appropriate stainless-steel kit for making PRF membranes (*Supremo Instrumentais Cirúrgicos, São Paulo, Brazil*) the intermediary portion centrifuged, the fibrin clot, was separated from the portion of red cells and platelet-poor plasma and deposited in the stainless steel box. The compressive lid was applied, without tightening it, for 15 minutes. The weight itself (130g) is enough to compress the clot to obtain the membranes, without posing damages to the cell structures present in the fibrin mesh. Four A-PRF membranes were used, and they were positioned and sutured inside the mucoperiosteal tunnel created (Figure 4). The tissue was later coronally tractioned with vertical sutures fixed in the incision/vestibular region of the dental elements involved, using polypropylene thread 5.0 (*TECHSUTURE, Bauru, São Paulo, Brazil*). (Figure 5 and 6)

2.2 Post-operative control and evaluations

The patients received pain relief medications, antibiotic therapy, non steroidal anti-inflammatory, analgesic and mouthwash (Amoxicillin 500mg at each 8 hours, for seven days, nimesulide 100mg at each 12 hours for 3 days, dipyron 500mg/5ml for 3 days and chlorhexidine digluconate 0.12% at each 12 hours for 15 days). The donor region sutures were removed after 7 days, and the recipient bed sutures were removed after 15 days.

The patients were assessed for a period of 180 days, and the clinical examinations were made in periods of 0, 90 and 180 days, and in all periods the patients received maintenance therapy, with all criteria of the initial periodontal examination reassessed. After the 180 days of experimental period, all patients were included in a periodontal maintenance program (Figure 7 and 8).

2.3 Statistical analysis

The program used for statistical analysis was GraphPad Prism 8.0®. The clinical data were initially analyzed and assessed with SHAPIRO-WILK test for normality verification, ANOVA and TUKEY tests for normal data and KRUSKALL-WALLIS and DUNN tests for non-normal data. For analysis of sensitivity parameter and bleeding KRUSKALL-WALLIS and DUNN tests were used. In the analysis between groups the STUDENT t-test was used, with significance level of 5%.

3. Results

Forty four gingival recessions were analyzed, 22 from the tunneling + SCTG group and 22 from the tunneling +A-PRF group.

Table 1 displays the values of periodontal clinical parameters for the tunneling + A-PRF group analyzed after 180 days, with all parameters presenting statistically significant improvements after the 180 days of follow-up ($p<0.05$).

Table 1 – Comparative analysis of periodontal parameters of the Tunneling + A-PRF group in the initial and final periods. The values represent mean \pm standard deviation.

Parameters (mm)	Tunneling + A-PRF (initial)	Tunneling + A-PRF (90 days)	Tunneling + A-PRF (180 days)
Recession width	2.68 \pm 0.64A	1.63 \pm 0.95B	1.53 \pm 0.63B
Recession height	2.13 \pm 0.83A	1.05 \pm 0.62B	1.13 \pm 0.51B
Probing depth	1.71 \pm 0.38A	1.35 \pm 0.37B	1.08 \pm 0.26B
Clinical attachment level	3.18 \pm 0.85A	2.21 \pm 0.71B	2.13 \pm 0.51B
Height of attached gingiva	1.37 \pm 0.47A	2.21 \pm 0.53B	2.33 \pm 0.81B
Degree of sensitivity	1.68 \pm 0.99A	0.68 \pm 0.94B	0.4 \pm 0.63B
Bleeding rate	0.31 \pm 0.64A	0 \pm 0A	0.6 \pm 0.50B
Tissue thickness	1.40 \pm 0.50A	2.42 \pm 0.76B	2.26 \pm 0.70B

NOTE: Different letters mean that they are statistically different in each treatment group ($p<0.05$).

Table 2 presents the values of periodontal clinical parameters for the tunneling + SCTG group analyzed after 180 days, where all periodontal parameters presented statistically significant improvement, except for bleeding rate.

Table 2 - Comparative analysis of periodontal parameters of the Tunneling + SCTG group in the initial and final periods. The values represent mean \pm standard deviation.

Parameters (mm)	Tunneling + SCTG (initial)	Tunneling + SCTG (90 days)	Tunneling + SCTG (180 days)
Recession width	2.5 \pm 0.51A	1.73 \pm 0.73B	1.26 \pm 0.59B
Recession height	2.04 \pm 0.57A	0.89 \pm 0.56B	0.93 \pm 0.45B
Probing depth	0.71 \pm 0.52A	1.24 \pm 0.39B	1.06 \pm 0.13B
Clinical attachment level	3.18 \pm 0.73A	2 \pm 1B	2.13 \pm 0.74B
Height of attached gingiva	1.36 \pm 0.49A	2.15 \pm 0.50B	2.2 \pm 0.67B
Degree of sensitivity	1.68 \pm 1.08A	0.42 \pm 0.50B	0.13 \pm 0.35B
Clinical attachment level	0.27 \pm 0.45A	0.05 \pm 0.22A	0.4 \pm 0.63A
Tissue thickness	1.27 \pm 0.55A	2.36 \pm 0.49B	2.53 \pm 0.74B

NOTE: Different letters mean that they are statistically different in each treatment group ($p < 0.05$).

Table 3 presents the comparison of the means variation (initial and after 180 days) of each periodontal parameters among SCTG and A-PRF groups. No statistically significant differences were observed, and there was gain of 1.40 ± 0.66 mm in gingival height in tunneling + SCTG group and 1.36 ± 0.72 mm in tunneling + A-PRF group. Besides, gain in the tissue thickness was obtained for both groups: 0.45 ± 1.40 mm for the tunneling + SCTG group, and 0.13 ± 1.45 mm for the tunneling + A-PRF group. Dentin sensitivity also presented significant improvement ($p < 0.05$) from 1.68 ± 1.08 to 0.13 ± 0.35 in the SCTG group, and from 1.68 ± 0.99 to 0.4 ± 0.63 for the A-PRF group.

Table 3 - Comparative analysis of the variation (0 – 180 days) of periodontal parameters in SCTG and A-PRF groups. The values represent mean \pm standard deviation.

Parameters (mm)	Tunneling + SCTG	Tunneling + A-PRF
Recession width	1.73 ± 0.78	1.63 ± 1.04
Recession height	1.40 ± 0.66	1.36 ± 0.72
Probing depth	0.98 ± 0.96	0.96 ± 0.80
Clinical Attachment Level	1.72 ± 1.12	1.72 ± 0.93
Height of attached gingiva	-0.13 ± 1.20	-0.27 ± 1.27
Tissue thickness	-0.45 ± 1.40	-0.13 ± 1.45

NOTE: Data not statistically significant ($p > 0.05$).

Some patients reported more intense pain in the donor region. Swelling and discomfort were the complications reported by the patients in this study in the first post-operative days, while after the first week no type of discomfort was reported.

All patients stated that they would undergo the procedure again, if necessary, chiefly due to the improvement in esthetic and in the initially presented dentin sensitivity.

4. Discussion

For gingival recession coverage, the gingival plastic surgery is a daily challenge in the clinical practice, because many anatomic variations must be considered in their treatment, which can influence their prognosis. The presence of interproximal bone, the thickness of the keratinized tissue, the size of adjacent papillae, the teeth positioning, as well as the dexterity, skills and experience of the professional were reported by Corteleni et al., 2018; Corteleni et al., 2009; and Tonetti e Jepsen, 2014.

The tunneling technique associated to the coronal positioning provides high safety with minimum handling and tension in the graft, thus ensuring less post-operative discomfort. This technique is indicated for multiple gingival recessions in the literature (Zabalegui et al., 1999).

Patients that present gingival recessions with complaints associated to dentin hypersensitivity and esthetics are eligible to receive periodontal plastic surgery for root coverage. Root coverage in locations with loss of gingival tissue, whether localized or generalized, is one of the objectives of periodontal plastic surgeries (Nassar et al., 2014).

The present study showed significant improvement in periodontal parameters in both groups after 6 months of post-operative, and such results are aligned with those of studies conducted by Sato et al., 1993 and Cugini et al., 2000.

Though SCTG presents better results in most periodontal parameters, they were not statistically significant, which demonstrates that A-PRF membranes can be indicated for patients that don't want to undergo the procedure for removal of the graft; and in cases where the patient does not have enough gingival tissue at the donor location. Moreover, the absence of risk of post-operative complications like pain, palate necrosis, and vascular accident of the palatine artery, is an advantage assigned to the use of A-PRF.

Several treatment modalities are being added, like different flap designs, autogenous grafts associated or not to other materials, synthetic materials, and even orthodontic treatment (Kassab et al.; 2010). The advanced platelet-rich fibrin (A-PRF) matrix can protect open injuries (Martins et al., 2017), and, mainly, it can increase tissues cicatrization (Lebarbenchon et al., 2019), because it can control the inflammatory process by gradual release of cytokines and growth factors, thus stimulating the synthesis of fibroblasts and collagen, also promoting angiogenesis and epithelial migration (Martins, 2017; Macedo, 2019; Culhaoglu, 2018).

Previous studies on Miller class I and II bilateral recessions, split mouth, that assessed the use of PRF for root coverage compared to connective tissue graft reported results without statistical differences in the level of root coverage across groups (Jandovic 2012; Tunali 2015; Oncu 2017). However, according to Miron et al. systematic review, 2017, the results of root

coverage performed with Coronary Repositioning + connective tissue graft are better than those found with the use of PRF. The amount of gingiva attached was statistically higher in both groups of the present study when compared to the initial value, with statistical differences between the two groups, and with values favorable to the group that used connective graft. Such result corroborates previous systematic reviews (Moraschini 2016; Miron et al., 2017; Castro 2017).

Tunali 2015, in his study, did not observe statistically significant differences in the amount of gingiva attached after 12 months. The increase of gingiva attached in the connective graft group is explained by the fact that the connective tissue graft transfers its genetic expression from the donor location, increasing the strip of keratinized tissue and the thickness of the gingiva attached to the recipient area.

The shorter strip of keratinized tissue in the PRF group can be explained by the fact that the autologous fibrin works with angiogenesis increase, promoting and inducing the formation of neovascularization and new tissues in the recipient bed. For the root coverage procedure to be successful, the quality of the recipient bed is fundamental, therefore, when a strip of keratinized tissue is available, it will promote the formation of more keratinized tissues. However, in case there is only a loose mucous tissue, not adhered, a similar formation of this tissue, with poor quality, will be found (Dohan et al., 2006).

The positive PRF results are granted to the different growth factors (PDGF, VEGF E TFG), cytokines, glycoproteins, and chiefly the dense network of fibrin matrix (100x greater than normal) that increases and promotes angiogenesis and matrix synthesis (Keceli et al., 2008, 2015). In this study there was efficacy in recession coverage for both groups (tables 1 and 2), which is aligned to other studies that found similar results, like those by Oncu 2017 and Keceli et al., 2008.

Recent studies have emphasized the tissue biotype importance for the gingival margin stability over time (Pini Prato et al., 2017). Techniques that utilize connective tissue graft are reported with more gain in gingival thickness (Baldi et al., 1999). In the present study, it was observed that in situations where A-PRF was used there was no statistically significant difference in gingival thickness.

Improvement in the height of the attached gingiva was observed in both groups, however, the A-PRF group obtained greater gain, though without statistical differences between them (increase of 0.13 ± 1.20 against 0.27 ± 1.27), result that is similar to that found in the study by Oncu et al., 2017.

The quality and amount of soft tissue reached after the root coverage with PRF membrane graft is directly associated to the amount of fibrin matrix grafted. Ghanaati et al 2014 found out that while using 3 to 4 PRF membranes, fibropromotion could be clinically predictable.

The advantages of using L-PRF or A-PRF are based on the platelet cytokines that play a fundamental role in the initial mechanisms of the cicatrization process, due to their capacity to stimulate cell migration and proliferation, induce remodeling of the fibrin matrix and the secretion of a collagen matrix. These cytokines stay trapped in the fibrin mesh. The increase in the number of leukocytes plays a central role in the phagocytosis of microorganisms and necrotic tissues, and also directs the future regeneration of these tissues through the release of cytokines and growth factors, in addition to stimulating angiogenesis and the formation of tissues (Ghanaati et al., 2014; Isobe et al., 2017; Kobayashi et al., 2016).

5. Conclusion

Based on the clinical significance of results, it was possible to conclude that both SCTG and A-PRF, associated to the tunneling technique, presented significant improvement in the periodontal parameters assessed, without presenting significant statistical difference between them, suggesting that A-PRF associated to the tunneling technique, can be used as alternative to SCTG in the treatment of Cairo type I gingival recessions.

Ethical Approval

The study was submitted and approved by Unioeste Committee of Ethics and Research on Human Beings (opinion number 3.359.508, CAAE 13806519.0.0000.0107, May 31, 2019 – ANNEX A).

Consent

As per international standard or university standard, patient(s) written consent has been collected and preserved by the author(s).

UNDER PEER REVIEW

References

Aroca, S., Keglevich, T., Barbieri, B., Gera, I., Etienne, D. Clinical evaluation of a modified coronally advanced flap alone or in combination with a platelet- rich fibrin membrane for the treatment of adjacent multiple gingival recessions: a 6- month study. *Journal of periodontology*, v. 80, n. 2, p. 244-252, 2009.

Bedoya, M. M., Park, J. H. The etiology and prevalence of gingival recession. *Jada*, 140(12), 1485–1493, 2014

Baldi, C., Pini-Prato, G., Pagliaro, U. Coronally advanced flap procedure for root coverage. Is flap thickness a relevant predictor to achieve root coverage? A 19- case series. *J Periodontol* 1999; 70:1077–1084.

Borghetti A. Anatomia e histologia do complexo mucogengival. 1st edition ed. Porto Alegre 2002. 1st edition ed. Porto Alegre, 2002. 3-34.

Cairo, F., Nieri, M., Cincinelli, S., Mervelt, J., Pagliaro, U. The Interproximal clinical attachment level to classify gingival recessions and predict root coverage outcomes: an 10 explorative and reliability study. *J Clin Periodontol*. v. 38, p. 661–666, 2011.

Castro, A.B., Meschi, N., Temmerman, A., Pinto, N., Lambrechts, P., Teughels, W., Quirynen, M. Regenerative potential of leucocyte- and platelet-rich fibrin. Part A: intra-bony defects, furcation defects and periodontal plastic surgery. A systematic review and meta-analysis. *J Clin Periodontol* 2017; 44: 67–82. doi: 10.1111/jcpe.12643

Camilotti, V., Zilly, J., Busato, P.M.R., Nassar, C.A., Nassar, P.O. Desensitizing treatments for dentin hypersensitivity: a randomized, split-mouth clinical trial. *Braz. Oral Res.* v. 26, n.3, 2012.

Cortellini, P., Bissada, N.F. Mucogingival conditions in the natural dentition: Narrative review, case definitions, and diagnostic considerations. *J Clin Periodontol*. v. 45(Suppl 20), p. S190–S198, 2018.

Cortellini, P., Tonetti, M., Baldi, C., Francetti, L., Rasperini, G., Rotundo, R., Nieri, M., Franceschi, D., Labriola, A., Prato, G.P. Does placement of a connectivetissue graft improve the outcomes of coronally advanced flap for coverage ofsingle gingival recessions in upper anterior teeth? A multi-centre, randomized, double-blind, clinical trial. *J Clin Periodontol.* 2009; 36(1):68-79.

Culhaoglu, R., Taner, L., Guler, B. Evaluation of the effect of dose-dependent platelet-rich fibrin membrane on treatment of gingival recession: a randomized, controlled clinical trial. *Journal of Applied Oral Science*, v. 26, n. 0, 14 maio 2018.

Choukroun, J., Ghanaati, S. Reduction of relative centrifugation force within injectable platelet-rich-fibrin (PRF) concentrates advances patients' own inflammatory cells, platelets and growth factors: the first introduction to the low speed centrifugation concept. *European Journal of Trauma and Emergency Surgery*, v. 44, n. 1, p. 87-95, 2018.

Choukroun, J., Diss, A., Simonpieri, A., Girard, M. O., Schoeffler, C., Dohan, S. L., Dohan, A. J. J., Mouhyi, J., & Dohan, D. M. Platelet-rich fibrin (PRF): A second-generation platelet concentrate. Part IV: Clinical effects on tissue healing. *Oral Surgery, Oral Medicine, Oral Pathology, Oral Radiology and Endodontology*, 101(3), 56–60, 2006. <https://doi.org/10.1016/j.tripleo.2005.07.011>.

Dohan, D. M., Lars, R., Albrektsson, T. Classification of platelet concentrates: from pure platelet-rich plasma (P-PRP) to leucocyte-and platelet-rich fibrin (L-PRF). *Trends in biotechnology*, v. 27, n. 3, p. 158-167, 2009.

Dohan, D. M., Choukroun, J., Diss, A., Dohan, S. L., Dohan, A. J. J., Mouhyi, J., & Gogly, B. Platelet-rich fibrin (PRF): A second-generation platelet concentrate. Part II: Platelet-related biologic features. *Oral Surgery, Oral Medicine, Oral Pathology, Oral Radiology and Endodontology*, 101(3), 2006. <https://doi.org/10.1016/j.tripleo.2005.07.0>.

Fu, J.H., Su, C.Y., Wang, H.L. Esthetic soft tissue management for teeth and implants. *J. Evid. Basead Dent Pract.* 12, 129-142, 2012.

Ghanaati, S., Booms, P., Orłowska, A., Kubesch, A., Lorenz, J., Rutkowski, J., Les, C., Sader, R., Kirkpatrick, C. J., & Choukroun, J. Advanced platelet-rich fibrin: A new concept for cell-based tissue engineering by means of inflammatory cells. *Journal of Oral Implantology*, 40(6), 679–689, 2014. <https://doi.org/10.1563/aaid-joi-D-14-00138>.

Gupta, S., Banthia, R., Singh, P., Banthia, P., Raje, S., Aggarwal, N. Clinical evaluation and comparison of the efficacy of coronally advanced flap alone and in combination with platelet rich fibrin membrane in the treatment of Miller Class I and II gingival recessions. *Contemp Clin Dent*. 2015 Apr-Jun;6(2):153-60. doi: 10.4103/0976-237X.156034. PMID: 26097347; PMCID: PMC4456734.

Isobe, K., Watanebe, T., Kawabata, H., Kitamura, Y., Okudera, T., Okudera, H., Uematsu, K., Okuda, K., Nakata, K., Tanaka, T., Kawase, T. Mechanical and degradation properties of advanced platelet-rich fibrin (A-PRF), concentrated growth factors (CGF), and platelet-poor plasma-derived fibrin (PPTF). *International Journal of Implant Dentistry*, 3(1), 4–9, 2017. <https://doi.org/10.1186/s40729-017-0081-7>

Kassab, M.M., Badawi, H., Dentino, A.R. Treatment of Gingival Recession. *Dental Clinics of North America*, 54(1), 129–140, 2010. <https://doi.org/10.1016/j.cden.2009.08.009>

Keceli, H. G., Kamak, G., Erdemir, E. O., Evginer, M. S., Dolgun, A. The Adjunctive Effect of Platelet-Rich Fibrin to Connective Tissue Graft in the Treatment of Buccal Recession Defects: Results of a Randomized, Parallel-Group Controlled Trial. *Journal of Periodontology*, 86(11), 1221–1230, 2015. <https://doi.org/10.1902/jop.2015.150015>

Keceli, H. G., Sengun, D., Berberoğlu, A., Karabulut, E. Use of platelet gel with connective tissue grafts for root coverage: A randomized-controlled trial. *Journal of Clinical Periodontology*, 35(3), 255–262, 2008. <https://doi.org/10.1111/j.1600-051X.2007.01181.x>

Kobayashi, E., Flückiger, L., Fujioka-Kobayashi, M., Sawada, K., Sculean, A., Schaller, B., Miron, R.J. Comparative release of growth factors from PRP, PRF, and advanced-PRF. *Clinical Oral Investigations*, 20(9), 2353–2360, 2016. <https://doi.org/10.1007/s00784-016-1719-1>

Lebarbenchon, M.B. Avaliação do plasma rico em fibrina e enxerto de tecido conjuntivo subepitelial em recobrimentos radiculares. Dissertação (Mestrado em Medicina Dentária) — Faculdade de Ciências da Saúde, Universidade Fernando Pessoa, Porto, 2019.

Macedo, B.F. O uso da fibrina rica em plaquetas na odontologia: Revisão de literatura e relato de caso clínico. 2019. n. 25. Monografia (Bacharelado em Odontologia) — Faculdade Sete Lagos, Sete Lagos, 2019.

Martins, G. A. Emprego estético e terapêutico de fibrina rica em plaquetas em procedimentos orofaciais: Revisão de literatura. 2017. n. 44. (Bacharelado em Odontologia) — Universidade Federal de Santa Catarina, Florianópolis, 2017.

Miron, R.J., Zucchelli, G., Pikos, M.A., Salama, M., Lee, S., Guillemette, V., Kobayashi, M., Bishara, M., Zhang, Y., Wang, H.L., Chandad, F., Nacopoulos, C., Simonpieri, A., Aalam, A.A., Felice, P., Sammartino, G., Ghanaati, S., Hernandez, M.A., Choukroun, J. Use of platelet-rich fibrin in regenerative dentistry: a systematic review. *Clin Oral Investig.* 2017 Jul;21(6):1913-1927. doi: 10.1007/s00784-017-2133-z. Epub 2017 May 27. PMID: 28551729.

Moraschini, V., Barboza, E. dos S. P. Use of Platelet-Rich Fibrin Membrane in the Treatment of Gingival Recession: A Systematic Review and Meta-Analysis. *Journal of Periodontology*, 87(3), 281–290, 2016. <https://doi.org/10.1902/jop.2015.150420>.

Nassar, C.A., Da Silva, W.A., Tonet, K., Secundes, M.B., Nassar, P.O. Comparing semilunar coronally positioned flap to standard coronally positioned flap using periodontal clinical parameters. *Gen Dent.* 2014; 62(2):47-49.

Öncü, E. The Use of Platelet-Rich Fibrin Versus Subepithelial Connective Tissue Graft in Treatment of Multiple Gingival Recessions: A Randomized Clinical Trial. *International Journal of Periodontics & Restorative Dentistry*, v. 37, n. 2, 2017.

Padma, R., Shilpa, A., Kumar, P.A., Nagasri, M., Kumar, C., Sreedhar, A. A split mouth randomized controlled study to evaluate the adjunctive effect of platelet-rich fibrin to

coronally advanced flap in Miller's class-I and II recession defects. *Journal of Indian Society of Periodontology*, 17(5), 631–636, 2013. <https://doi.org/10.4103/0972-124X.119281>

Pinto, N.R., Temmerman, A., Castro, A.B., Cortellini, S., Teughels, W., Quirynen, M. Guide for using L-PRF. *Departments of Periodontology, Universidade de los Andes*. 2017

Pini Prato, G. P., Magnani, C., Chambrone, L. Long-term evaluation (20 years) of the outcomes of coronally advanced flap in the treatment of single recession-type defects. *Journal of Periodontology*, 89(3), 265–274. <https://doi.org/10.1002/JPER.17-0379>, (2018).

Spada, V.J., Nassar, P.O., Cardoso, N., Caldato, K.M.B., Pandini, J.H., Randon, D.M., Nassar, C.A. Root coverage in Miller classes I and II associated with subepithelial connective tissue graft: A comparative clinical trial of two techniques. *World Journal of Dentistry*, 8(4), 248–254, 2017. <https://doi.org/10.5005/jp-journals-10015-1446>

Steffens, J. P., Marcantonio, R.A.C. Classificação das doenças e condições periodontais e peri-implantares 2018: guia prático e pontos-chave. *Revista de Odontologia da UNESP*, v. 47, n. 4, p. 189-197, 2018.

Tonet, K., Bombardelli, C.G., Bussman, L.F., Secundes, M.B., Nassar, C.A., Nassar, P.O. Avaliação de diferentes técnicas de recobrimento radicular para a saúde dos tecidos periodontais. *Perionews*, v. 4, p. 473-477 (in portuguese), 2010.

Tonetti, M.S., Jepsen, S. Clinical efficacy of periodontal plastic surgery procedures: Consensus Report of Group 2 of the 10th European Workshop on Periodontology. *J Clin Periodontol*. 2014; 41 Suppl. 15: 36-43.

Tunali, M., Ozdemir, H., Pikdoken, M. Clinical Evaluation of Autologous Platelet-Rich Fibrin in the Treatment of Multiple Adjacent Gingival Recession Defects: A 12-Month Study. *Int J Periodontics Restorative Dent* 2015; 35:105–114.

Zabalegui, A., Sicilia, J., Cambra, J.M. Treatment of multiple adjacent gingival recessions with the tunnel subepithelial connective tissue graft: a clinical report,” *The International Journal of Periodontics and Restorative Dentistry*, vol. 19, no. 2, pp. 199–206, 1999.

Xavier, I., Alves, R. Enxerto de tecido conjuntivo tunelizado – a proposito de um caso clínico. *Revista Portuguesa de Estomatologia, Medicina Dentária e Cirurgia Maxilofacial*, 56(4), 256–261. <https://doi.org/10.1016/j.rpemd.2015.11.003>, 2015.

UNDER PEER REVIEW

ANNEX A

CONSUBSTANTIATED OPINION OF THE CEP

UNDER PEER REVIEW

UNIOESTE - CENTRO DE
CIÊNCIAS BIOLÓGICAS E DA
SAÚDE DA UNIVERSIDADE



PARECER CONSUBSTANCIADO DO CEP

DADOS DO PROJETO DE PESQUISA

Título da Pesquisa: FIBRINA RICA EM PLAQUETAS (PRF) NO RECOBRIMENTO DE RAÍZES COM RECESSÃO TIPO 1 DE CAIRO E RESTAURADAS COM CIMENTO DE IONÔMERO DE VIDRO MODIFICADO POR RESINA.

Pesquisador: Carlos Augusto Nassar

Área Temática:

Versão: 1

CAAE: 13806519.0.0000.0107

Instituição Proponente: Centro de Ciências Biológicas e da Saúde CCBS - UNIOESTE

Patrocinador Principal: Financiamento Próprio

DADOS DO PARECER

Número do Parecer: 3.359.508

Apresentação do Projeto:

Estudo clínico randomizado do tipo boca dividida em que deverão ser incluídos 40 pacientes com recessão gengival Tipo 1 de Cairo bilaterais que buscam tratamento da Clínica de Odontologia da Unioeste, com idade entre 20 e 60 anos, sem comorbidades sistêmicas que impossibilitem a realização de procedimentos cirúrgicos. Os pacientes serão submetidos a cirurgia periodontal de recobrimentos radicular associada a enxerto de tecido conjuntivo subepitelial - ETCS de um lado da arcada dentária e do outro membranas de fibrina rica em plaquetas - PRF, sendo realizadas as técnicas de Túnel e Retalho Reposicionado Coronariamente. Os pacientes serão acompanhados por 90 e 180 dias, para verificação da altura e largura da recessão; Profundidade de sondagem e Sangramento à Sondagem; Nível de inserção clínica; Nível Gengival (Recessão); Largura da faixa de tecido queratinizado; Espessura do tecido gengival queratinizado em 3 pontos (Mesial, central e distal); Grau de sensibilidade (Índice modificado da U.S. Public Health Service composto de três escores: 0 (Alpha) - sem sensibilidade; 2 (Bravo) - pequena sensibilidade; 3 (Charlie) - alta sensibilidade. Para análise será utilizado o teste de SHAPIRO-WILK para verificação da distribuição da normalidade; depois, serão utilizados o teste de ANOVA e TUKEY para verificar diferença entre os grupos. Para análise do parâmetro de sensibilidade, serão utilizados os testes de KRUSKAL-WALLIS e DUNN, com nível de significância de 5%. O programa Bioestat 5.4 (Instituto Mamirauá, Amazonas, Brasil) será utilizado para a realização de toda a análise estatística do estudo.

Endereço: RUA UNIVERSITÁRIA 2089

Bairro: UNIVERSITÁRIO

CEP: 85.819-110

UF: PR

Município: CASCAVEL

Telefone: (45)3220-3002

E-mail: cep.cepg@unioeste.br

UNIOESTE - CENTRO DE
CIÊNCIAS BIOLÓGICAS E DA
SAÚDE DA UNIVERSIDADE



Continuação do Parecer: 3.359/200

Objetivo da Pesquisa:

Comparar os resultados do recobrimento radicular utilizando-se o ETCS ou PRF, associados com Retalho Posicionado Coronalmente (RPC) ou a Técnica do Tunelamento (Tunel) em raízes restauradas com CIV-R.

Objetivo Secundário: * Conhecer os efeitos do PRF em recobrimento radicular utilizando duas técnicas cirúrgicas distintas, RPC e Tunel; * Analisar a morbidade pós-operatória em ambas as técnicas cirúrgicas; * Verificar se há melhora da sensibilidade após a realização do recobrimento radicular; * Averiguar clinicamente sobre a estabilidade dos resultados em ambas as técnicas e ambos os materiais de enxerto, em 0, 90 dias e 180 dias.

Avaliação dos Riscos e Benefícios:

Riscos: Estão relacionados à utilização de anestésicos locais, de rotina no atendimento odontológico, dor, desconforto, necroses gengivais (tanto do enxerto como do leito receptor) e sangramento pós-operatório. Em relação aos riscos dos anestésicos, estes podem ser diminuídos pela avaliação de episódios anteriores de reações alérgicas ou alterações na pressão arterial e, caso sejam relatadas alterações de qualquer natureza, o paciente será encaminhado para avaliação médica e somente poderá participar do estudo quando houver autorização do profissional. Com relação aos demais riscos, para que os mesmos sejam minimizados, os pacientes deverão seguir as recomendações pós-operatórias, como por exemplo a realização de compressas de gelo no local, repouso e alimentação leve.

Benefícios: Os benefícios esperados são de que se estabeleça uma melhora dos parâmetros clínicos periodontais das áreas com recessões gengivais de todos os pacientes, bem como, o recobrimento radicular, formação de um bom volume de tecido queratinizado, melhora da sensibilidade e do contorno estético da margem gengival, além da não necessidade de remoção de enxertos autógenos no grupo teste.

Comentários e Considerações sobre a Pesquisa:

Pesquisa apresenta relevância científica e uma revisão breve do tema.

Considerações sobre os Termos de apresentação obrigatória:

Apresentou todos os termos obrigatórios.

Endereço: RUA UNIVERSITÁRIA 2000
Bairro: UNIVERSITÁRIO CEP: 85.819-110
UF: PR Município: CASCAVEL
Telefone: (48)3220-3002 E-mail: cep.propq@unioeste.br

**UNIOESTE - CENTRO DE
CIÊNCIAS BIOLÓGICAS E DA
SAÚDE DA UNIVERSIDADE**



Continuação do Parecer: 3.359.509

Conclusões ou Pendências e Lista de Inadequações:

A pesquisa atende os preceitos éticos da pesquisa que envolve seres humanos.

Este parecer foi elaborado baseado nos documentos abaixo relacionados:

Tipo Documento	Arquivo	Postagem	Autor	Situação
Informações Básicas do Projeto	PB_INFORMAÇÕES_BÁSICAS_DO_PROJETO_1333453.pdf	24/04/2019 10:59:43		Aceito
TCLE / Termos de Assentimento / Justificativa de Ausência	termodeconsentimentolivreescarecido.pdf	20/04/2019 10:54:37	Carlos Augusto Nassar	Aceito
Outros	termodecompromissosusedados.pdf	11/04/2019 20:23:23	Carlos Augusto Nassar	Aceito
Declaração de Pesquisadores	declaracao.pdf	11/04/2019 20:22:57	Carlos Augusto Nassar	Aceito
Projeto Detalhado / Brochura Investigador	Projetoomite.pdf	11/04/2019 16:28:35	Carlos Augusto Nassar	Aceito
Outros	termocienciadoresponsavel.pdf	11/04/2019 16:28:25	Carlos Augusto Nassar	Aceito
Outros	instrumentocoletadados.pdf	11/04/2019 16:27:51	Carlos Augusto Nassar	Aceito
Parecer Anterior	parecerambulatorioodonto.pdf	11/04/2019 16:27:34	Carlos Augusto Nassar	Aceito
Folha de Rosto	folhaderosto.pdf	11/04/2019 16:27:22	Carlos Augusto Nassar	Aceito

Situação do Parecer:

Aprovado

Necessita Apreciação da CONEP:

Não

CASCAVEL, 31 de Maio de 2019

Assinado por:
Darlei Ferrari de Lima
(Coordenador(a))

Endereço: RUA UNIVERSITÁRIA 2009
Bairro: UNIVERSITÁRIO
UF: PR Município: CASCAVEL
Telefone: (46)3201-3002 CEP: 85.819-110
E-mail: cep.propq@unioeste.br

FIGURES

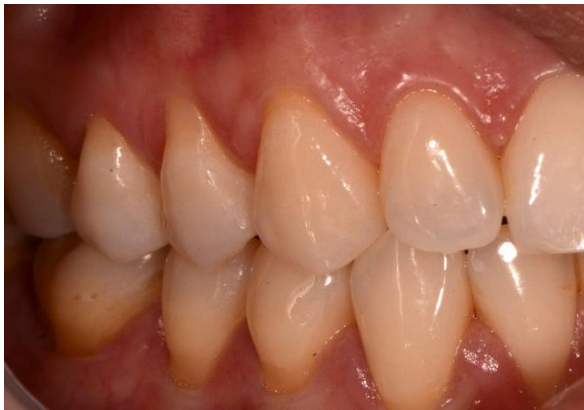

Figure 1

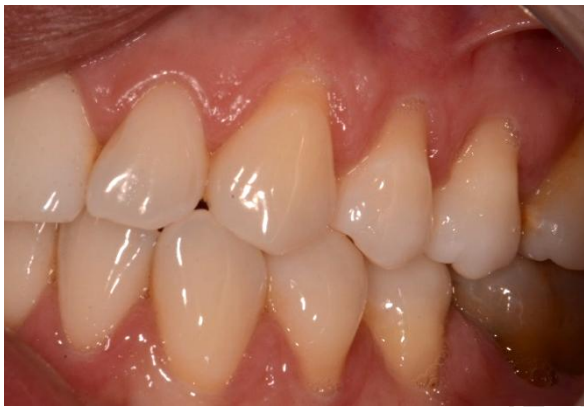

Figure 2

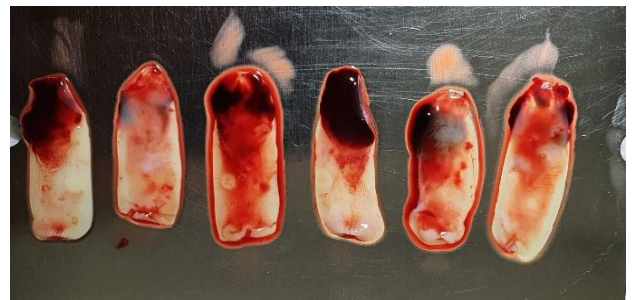


Figure 4

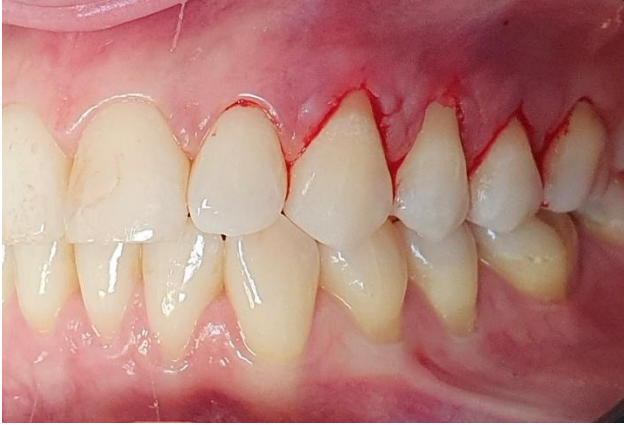

Figure 5

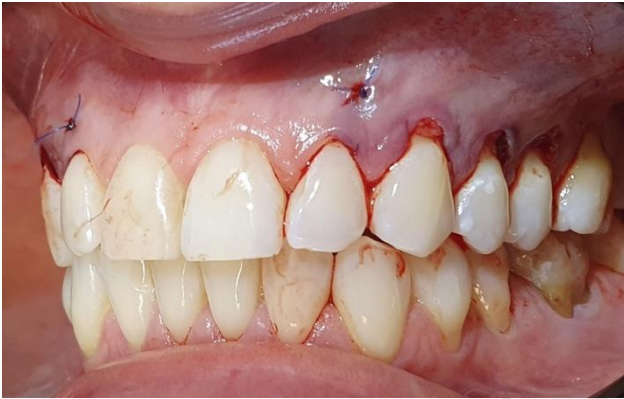

Figure 6

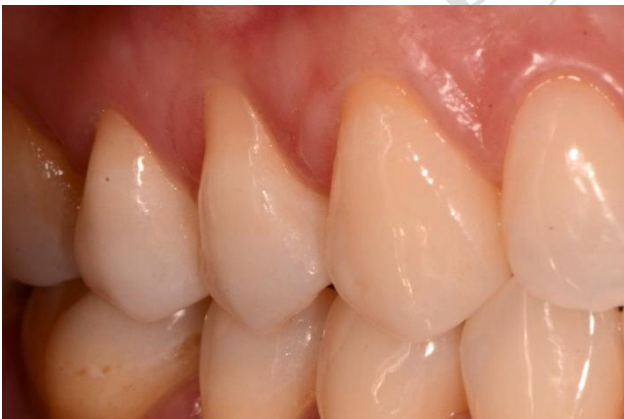

Figure 7

PEER REVIEW

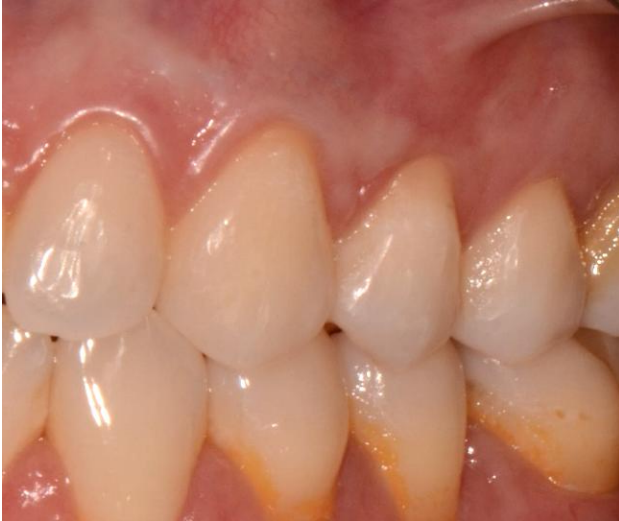

Figure 8

UNDER PEER REVIEW

Figure legends:

Figure 1: RTI Cairo recession, initial appearance.

Figure 2: RTI Cairo recession, initial appearance.

Figure 3: Distribution of the 44 recessions according to the treatments proposed.

Figure 4: Appearance of the fibre membrane after centrifugation.

Figure 5: Receiving bed prepared using the tunnelling technique.

Figure 6: ECTS and A-PRF membranes sutured to the recipient bed.

Figure 7: Postoperative appearance at 180 days

Figure 8: Postoperative appearance at 180 days

UNDER PEER REVIEW