

Case study

Idiopathic pulmonary hemosiderosis in pediatric patients: A report of four cases in Rabat, Morocco.

Comment [h1]: Modify as Idiopathic pulmonary hemosiderosis in pediatric patients in Rabat, Morocco: Report

Abstract :

Idiopathic pulmonary hemosiderosis (IPH) is a rare cause of diffuse alveolar hemorrhage. Patients with IPH usually present with the classical triad: hemoptysis, and iron deficiency anemia, and pulmonary infiltrates on chest imaging, the diagnosis is often delayed by years.

Comment [h2]: Suffix s

We report four IPH pediatric cases of children diagnosed at the children's hospital of Rabat, Morocco. The aim of this study is to review the clinical manifestations, diagnostic tools and treatment of this affection.

All the four patients were presented with the classical triad, the diagnosis was based on the Clinical, radiologic and biologic findings. A bronchoalveolar lavage was performed to all the patients and confirm the diagnosis by the identification of siderophages.

Comment [h3]: delete

Comment [h4]: B

Comment [h5]: confirmed

High doses of Corticosteroids, by an induction therapy with an intravenous methylprednisolone (20 mg/kg/day for 3 days) followed by oral prednisone (1 mg/kg/day) had shown a good therapeutic response. One patient was treated first with oral corticosteroid which was switched to synthetic antimalarial drugs, because he had side effects from long-term cortico therapy. Then the clinical condition has been improved. The evaluation of response to the therapy included the clinical symptoms and signs, laboratory data and chest x ray.

Comment [h6]: replace with and switched over to

The prognosis of IPH is influenced by several factors, including the time of diagnosis, early initiation of treatment, and the presence of comorbidities.

Key words : hemosiderosis- idiopathic pulmonary hemosiderosis – hemoptysis – siderophage – pulmonary infiltrates- golde score

Comment [h7]: arrange alphabetically with punctuation , but not - inbetween

Introduction

Idiopathic pulmonary hemosiderosis (IPH) is a rare disease marked by recurrent episodes of diffuse alveolar hemorrhage that are accompanied by abnormal haemosiderin accumulation in pulmonary macrophages, which causes the alveolar basement membrane to thicken and ultimately results in interstitial fibrosis [1]. Hemoptysis, iron deficiency anemia, and pulmonary infiltrates on chest imaging are the Triad that define IPH.

Comment [h8]: replace with condition

The aim of this study is to share our clinical and therapeutic experience in the management of four children diagnosed with idiopathic pulmonary hemosiderosis in the children's hospital in Rabat Morocco.

Material and methods

We conducted a retrospective study of four cases of idiopathic pulmonary hemosiderosis, collected at the division of Pediatric Immuno Allergology and Infectious Diseases at the Children's Hospital C.H.U Rabat during a 9 years period, from August 2014 to August 2023. The parameters studied were: age, sex,

symptoms, para-clinical examinations performed to make the diagnosis, treatment performed and evolution. The diagnosis was retained on clinical, biological and radiological arguments.

Results

The results of this study is summarized on table 1. The age of diagnosis of our patients was between three and seven years old; the Sex/ratior: 1. All of the patients had a history of chronic iron deficiency anemia, and were admitted to the hospital for hemoptysis,

Clinical history (severe persistent anemia that worsened during lower respiratory tract infections and that occurred multiple blood transfusions) and radiologic findings resulted in the suspicion of pulmonary hemosiderosis.

A bronchoalveolar lavage was requested and confirm the diagnosis of IPH: showed the presence of hemosiderin-laden macrophages (siderophages).

Serologic tests for autoimmune diseases (anti-nuclear antibodies, anti-DNA antibodies, anti-smooth muscle antibodies, anti reticuline antibodies, rheumatoid factor) were performed for all the patients, and the results were negative. Celiac screening and specific cow's milk IgE test results were also negative. Idiopathic pulmonary hemosiderosis was diagnosed, after discarding all causes of a secondary pulmonary hemosiderosis.

Three patients responded very well to intravenous methylprednisolone (20 mg/kg/day for 3 days) which was immediately administered, relayed by oral corticosteroid therapy (prednisone 1 mg/kg/day).

The fourth patient had corticosteroid at first for a year then, the infant developed a Cushing syndrome, gastritis and joint pain, the gradual reduction in prednisone dosage was started and the patient started taking Immunosuppressive agents (nivaquine). Clinical improvement was observed by a decrease in the frequency of hemorrhagic episodes.

Table 1: Description of the four cases reported

Patients	Case 1	Case 2	Case 3	Case 4
Age (years)	5	3	7	3
Sex	Male	Male	Female	Female
Medical history	iron-deficiency anemia	Hospitalized three times for severe anemia (hemoglobin level: 3 g/dL), which required a blood transfusion.	hospitalized six month before for a severe anemia (hemoglobin level: 4 g/dL) that required a blood transfusion.	hospitalized two times for a severe anemia that required a blood transfusion.
Clinical signs	dyspnea, polypnea, hemoptysis	hemoptysis chronic cough	dyspnea, polypnea, hemoptysis	recurrent episodes of hemoptysis associated to severe anemia
physical finding	pallor, dyspnea Sa O2 : 92%	pallor and dyspnea Sa O2 : 90%	pallor, tachycardia, dyspnea and bilateral crackles rales	pallor, tachycardia and dyspnea
Chest x- Ray	diffuse alveolar opacity (figure1)	diffuse alveolar opacity	diffuse alveolar opacity (figure 2)	diffuse alveolar opacity
CT scan	diffuse ground-glass opacity in both lung fields suggestive of pulmonary hemorrhage (Figure 3).	mosaic pattern lung parenchymal perfusion anomalies.	mosaic pattern lung parenchymal perfusion anomalies.	ground-glass appearance in both lung fields with subpleural nodules
Broncho	presence of	Presence of	the presence of	presence of siderophages.

Comment [h9]: mention the details and references

Comment [h10]: mention the no s of figures in the text

Comment [h11]: are

Comment [h12]: replace with with

Comment [h13]: delete

Comment [h14]: B

Comment [h15]: Suffix ed

Comment [h16]: Replace with with

alveolar lavage	hemosiderin-laden macrophages (siderophages) with a score of GOLD estimated 300. (figure 4)	hemosiderin-laden macrophages (siderophages)	haemosiderin-laden macrophages (siderophages)	
Treatment	oxygen with high-flow nasal cannulae amoxicillin treatment (80 mg/kg/day in three doses for 8 days) Intravenous methylprednisolone (20 mg/kg/day for 3 days) was immediately administered. Then, oral prednisone (1 mg/kg/day)	prompt blood transfusion oxygen with high-flow nasal cannulae intravenous methylprednisolone (20 mg/kg/day for 3 days) was immediately administered, then, oral prednisone (1 mg/kg/day)	oxygen with high-flow nasal cannulae was immediately administered. Intravenous methylprednisolone (20 mg/kg/day for 3 days) was immediately administered, Then, oral prednisone (1 mg/kg/day).	A prompt blood transfusion was performed Oral prednisone (2 mg/kg/day) was started and pursued for one year. however the infant developed a Cushing syndrome, gastritis and joint pain, the gradual reduction in prednisone dosage was started and the patient started taking Immunosuppressive agents (Nivaquine),
Evolution / follow-up duration	improvement in respiratory symptoms 3 days after the intravenous methylprednisolone and stabilization of hematological data in four weeks.	improvement in respiratory symptoms and stabilization of hematological data	improvement in respiratory symptoms and stabilization of hematological data	Decrease in the frequency of hemorrhagic episodes and stabilization of hematological data 4 weeks after the introduction of Nivaquine.

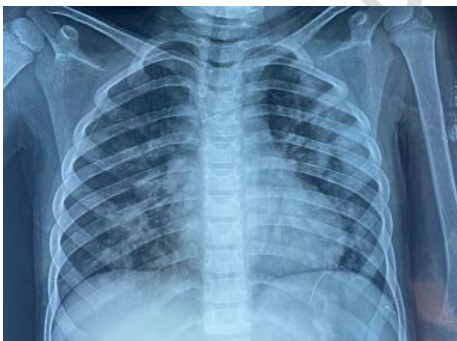

Figure 1: Chest x ray of case number 1 : diffuse alveolar opacity

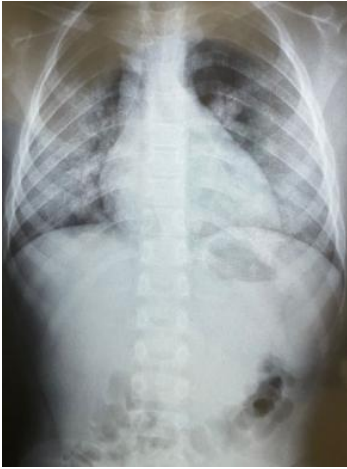

Figure 2: chest x ray of case number 3 showing diffuse alveolar

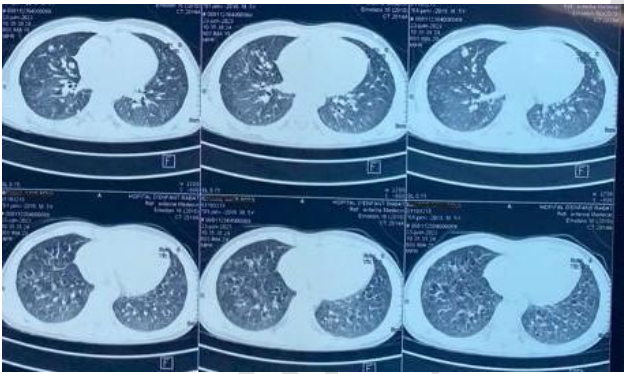


Figure 3 CT scan of case number 1 of the thorax : Diffuse ground-glass opacity in both lung fields suggestive of pulmonary hemorrhage

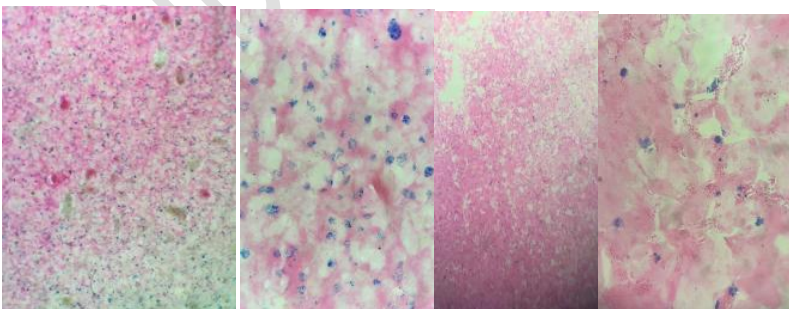


Figure 4- : Cytological study of broncho alveolar lavage fluid (case 1): Presence of siderophages (the blue pigments) .

Comment [h17]: mention stain and magnification

Discussion :

IPH is a rare clinical illness that typically affects children under the age of 10 years [2], especially between the ages of 1 and 7 years [3]. In this study, the patients age at disease onset was between three and seven years of age.

This condition was first described by Rudolf Virchow in 1864 in patients after their death [4]. In selected populations, the incidence is thought to range from 0.24 to 1.23 cases per million, with a fatality rate of up to 50% [3,5]. Although more common in the pediatric population, IPH can present at any age. Given the rarity of the condition, a definitive diagnosis is often delayed. Children with IPH seem to have a worse prognosis than adults and seem to more typically have an accelerated course. Death may quickly occur with acute massive pulmonary hemorrhage or may occur over longer periods as the result of continued respiratory insufficiency and heart failure [3,6]. Historically, patients with IPH had an average survival of 2.5 years after diagnosis. Currently, 86% of patients with IPH may survive beyond 5 years [4].

Several hypotheses regarding the pathogenesis of IPH have been proposed. These risk factors include an autoimmune, allergic or genetic predisposition, and possible environmental exposure [7].

Classically, IPH manifests with the triad hemoptysis, radiologic chest infiltrates, and iron deficiency anemia [8].

The diagnosis of IPH is based on searching for hemosiderin-laden macrophages. Kabra et al. had reported that the sensitivity of finding hemosiderin-laden macrophages is 30% in gastric juice and 92% in bronchoalveolar lavage fluid [9]. After centrifugation, the samples are smeared with Perls staining and the Golde score is established. The Golde score is a subjective assessment of the hemosiderin content of alveolar macrophages (appearing as blue pigments), estimated on at least 200 macrophages and graded from 0 to 4. (0: no colour; 1: faint blue in one portion of the cytoplasm; 2: deep blue in a minor portion of the cell; 3: deep blue in most areas of the cytoplasm; 4: deep blue throughout the cell). To determine the hemosiderin score for a mean of 100 alveolar macrophages, the total score is divided by 2 [10]. A Golde score >100 indicates severe alveolar hemorrhage, while a score of 20-100 corresponds to mild to moderate alveolar hemorrhage, normal is less than 20 [10].

In order to make the diagnosis of IPH, other causes of diffuse alveolar hemorrhage must be ruled out, including infection, medication, toxic inhalation, vasculitis, and anti-glomerular basement membrane disease, among others [7].

In this study, all our patients presented the classical triad : hemoptysis, radiologic chest infiltrates, and iron deficiency anemia, and all of them had a bronchoalveolar lavage which confirm the diagnosis by finding siderophages in it. IPH diagnosis was retain after discarding all causes of a secondary pulmonary hemosiderosis.

Patients with hemodynamic instability or respiratory distress in the acute stage of pulmonary hemorrhage will benefit from appropriate transfusion of packed red blood cells, respiratory assistance with oxygen supplement, or mechanical ventilation [12,13]. In this study, three of our patients needed a multiple blood transfusion.

Currently, there exist no international therapeutic guidelines on IPH, regarding the choice of medications, dose, and duration of therapy. Glucocorticoids and immunosuppressive agents (e.g., hydroxychloroquine, azathioprine, and cyclophosphamide) are the first choice for treating IPH. [11,14,15].

Three of our patients we relied on systemic corticosteroids to induce remission, followed by maintenance therapy, which implied adjuvant therapy (calcium, vitamin D and potassium), those patients had a good response to corticotherapy by a decrease in the frequency of hemorrhagic episodes. For the fourth patient we treated her right away with oral corticosteroid, a year later she presented side effect: Cushing syndrome

Comment [h18]: modify as IPH ; though more common in the pediatric population and can at any age.

Comment [h19]: delete

Comment [h20]: A

Comment [h21]: delete

Comment [h22]: replace with in this study revealed

Comment [h23]: delete

Comment [h24]: suffix are existing with respect to

Comment [h25]: delete

and gastritis, which lead to change the treatment to a synthetic antimalarial drugs (Nivaquine) and since then (three years ago) the child is doing well.

In this study we show that a systemic corticosteroid followed by maintenance therapy with oral corticosteroids had a good therapeutic response. Yang C-T et al. showed that aggressive high dose CS therapy might prevent intensive care unit admission, improve disease activity, and promote Hb recovery. [16].

Comment [h26]: suffix ed

Comment [h27]: replace with Reports of [16]

Comment [h28]: delete

The evaluation of response to the therapy included the clinical symptoms and signs, laboratory data and chest x ray. [4,17] Patient's Hb level could be the key markers to adjust medication [16].

The prognosis of IPH is influenced by several factors, including the time of diagnosis, early initiation of treatment, and the presence of comorbidities [18]. The overall survival has improved over the past decades, possibly due to the overall improvement of supportive care as well as the early institution of corticosteroid and other immunosuppressive medications [14].

Conclusion

The IPH is a very rare disease, often under-diagnosed. It should be suspected in children with pallor and dyspnea. The iron deficiency anemia who show no signs of improvement with iron supplementation accompanied with bilateral lung infiltration should lead to the diagnosis of IPH. Early diagnosis plays a crucial role in prolonging survival and improving prognosis. Future efforts must be made to reduce underdiagnosis and incorrect diagnoses of IPH.

Comment [h29]: suffix ed

Comment [h30]: delete

REFERENCES :

1. Poggi V, Lo Vecchio A, Menna F, Menna G. Idiopathic pulmonary hemosiderosis: a rare cause of iron-deficiency anemia in childhood. *J Pediatr Hematol Oncol.* 2011;33:e160–2.
2. Morgan PG and Turner-Warwick M. Pulmonary haemosiderosis and pulmonary haemorrhage. *Br J Dis Chest* 1981; 75: 225–242.
3. Ohga S, Takahashi K, Miyazaki S, et al. Idiopathic pulmonary haemosiderosis in Japan: 39 possible cases from a survey questionnaire. *Eur J Pediatr* 1995; 154: 994–995.
4. Saeed MM, Woo MS, MacLaughlin EF, et al. Prognosis in pediatric idiopathic pulmonary hemosiderosis. *Chest* 1999; 116: 721–725.
5. Kjellman B, Elinder G, Garwicz S, Svan H. Idiopathic pulmonary hemosiderosis in Swedish Children. *Acta Pediatr Scand* 1984; 73: 584-588.
6. Corrin B, Jagusch M, Dewar A, et al. Fine structural changes in idiopathic pulmonary haemosiderosis. *J Pathol* 1987; 153: 249–256.
7. Saha, Biplab K. Idiopathic pulmonary hemosiderosis: A state of the art review <https://doi.org/10.1016/j.rmed.2020.106234>
8. Milman, N. Idiopathic pulmonary hemosiderosis. Post TW, ed. UpToDate. Waltham, MA: UpToDate Inc. <http://www.uptodate.com>. Accessed Oct 21, 2020.)
9. Le Clainche L, Le Bourgeois M, Fauroux B, Forenza N, Dommergues JP, Desbois JC et al (2000) Long-term outcome of idiopathic pulmonary hemosiderosis in children. *Medicine (Baltimore)* 79(5):318–326

10. Maldonado, F., Parambil, J. G., Yi, E. S., Decker, P. A., & Ryu, J. H. (2009). Haemosiderin-laden macrophages in the bronchoalveolar lavage fluid of patients with diffuse alveolar damage. *European Respiratory Journal*, 33(6), 1361-1366
11. Kabra SK, Bhargava S, Lodha R, Satyavani A, Walia M. Idiopathic pulmonary hemosiderosis: clinical profile and follow up of 26 children. *Indian Pediatr* 2007;44(5):333e8..
12. Yao TC, Hung IJ, Wong KS, Huang JL, Niu CK. Idiopathic pulmonary haemosiderosis: an Oriental experience. *J Paediatr Child Health* 2003;39(1):27e30.
13. Susarla SC, Fan LL. Diffuse alveolar hemorrhage syndromes in children. *Curr Opin Pediatr* 2007;19(3):314e20.
14. N. Kiper, A. Goçmen, " U. Ozçelik, " E. Dilber, D. Anadol, Long-term clinical course of patients with idiopathic pulmonary hemosiderosis (1979–1994): prolonged survival with low-dose corticosteroid therapy, *Pediatr. Pulmonol.* 27 (3) (1999) 180–184.
15. Chin CI, Kohn SL, Keens TG, et al. A physician survey reveals differences in management of idiopathic pulmonary hemosiderosis. *Orphanet J Rare Dis* 2015. DOI: 10.1186/s13023-015-0319-5.
16. Yang C-T et al., Aggressive corticosteroid treatment in childhood idiopathic pulmonary hemosiderosis with better outcome, *Journal of the Formosan Medical Association*, <https://doi.org/10.1016/j.jfma.2020.05.022>
17. Ioachimescu OC, Sieber S, Kotch A. Idiopathic pulmonary haemosiderosis revisited. *Eur Respir J* 2004;24(1):162e70.
18. Afzal N, Mushtaq A, Rahman A, et al. Idiopathic pulmonary haemosiderosis presenting as severe iron deficiency anaemia—a case from Pakistan. *J Pak Med Assoc* 2012; 62: 845–847.

Comment [h31]: provide all authors names