

G6PD DEFICIENCY REVEALED BY SARS-COV-2 INFECTION: A CASE REPORT FROM SENEGAL

ABSTRACT

We report the case of a young girl in whom the diagnosis of G6PD deficiency was revealed by an infection with COVID 19. The patient was 17 years old, with no particular personal pathological history. Clinical examination revealed sepsis, with right basal pulmonary condensation syndrome, anemia, hemolytic icterus with non-discolored stools and dark urine, but no splenomegaly. The frontal chest X-ray showed blurred opacities in the lower right lung and the middle left lung. Thoracic angioscanner ruled out pulmonary embolism, but showed a typical appearance of SARS-COV pneumonitis of minimal severity. The COVID-19 direct antigen test was positive, and the sputum cytobacteriological examination did not isolate any germs. The blood smear showed anisopoikilocytosis with the presence of numerous phantom red blood cells or hemighost, bitten red blood cells or "bite cells", with the absence of spherocytes and elliptocytes. Hemoglobin electrophoresis was performed, as well as G6PD assay, which had collapsed to 2.6 IU/g Hb (7 - 10 IU/d hemoglobin). After two weeks of hospitalization, the evolution was favorable, the Covid PCR test was negative and the control blood count showed a hemoglobin level of 12.1 g/dl.

Keywords : G6PD deficiency, COVID 19, INFECTION

INTRODUCTION

Glucose-6-phosphate dehydrogenase (G6PD) deficiency is the most widespread enzyme anomaly in the world [1]. It affects around 420 million people, mainly in the Mediterranean basin [20].

According to the WHO, 7.5% of the world's population has one of the variants of G6PD deficiency, but often without clinical manifestations, and around 3.4% of this population is at risk of potential pathology [21]. These individuals suffer a hemolytic crisis after exposure to oxidants such as foods (fava beans), drugs (quinines), or microbes, notably coronaviruses [17]. Although many circumstances of discovery have been described in the literature, the case of a revelation following a SARS-COV-2 infection remains rare. We report the case of a

young girl in whom the diagnosis of G6PD deficiency was revealed by an infection with COVID-19.

Case Presentation

The patient was 17 years old, with no particular personal pathological history. She was admitted with symptomatology that began 2 days before her admission, consisting of a productive cough producing yellowish sputum, associated with diffuse pain and fatigue on exertion, with no notion of phytotherapy or medication. On initial examination, she was classified as Performance Status 3 according to WHO, with pale icteric conjunctival mucosa. Her temperature was 38°C, associated with tachycardia at 116 beats per minute. Respiratory rate, oxygen saturation, and other vital signs were unremarkable. Clinical examination of the systems revealed sepsis, with right basal pulmonary condensation syndrome, anemia, hemolytic icterus with non-discolored stools and dark urine, but no splenomegaly. The frontal chest X-ray showed blurred opacities in the lower right lung and the middle left lung. Thoracic angioscanner ruled out pulmonary embolism, but showed a typical appearance of SARS-COV pneumonitis of minimal severity (Fig. 1). The COVID-19 direct antigen test was positive, and the sputum cytobacteriological examination did not isolate any germs. The blood count showed a predominantly neutrophilic hyperleukocytosis associated with a highly regenerative normocytic normochromic anemia; the platelet count was normal (Table 1). The blood smear showed anisopoikilocytosis with the presence of numerous phantom red blood cells or hemighost, bitten red blood cells or "bite cells", with the absence of spherocytes and elliptocytes (figure 2). On the basis of these findings and the clinical context, the hemolysis assessment and some inflammatory parameters were requested (Table 1). Unconjugated serum bilirubin was increased (conjugated bilirubin normal), serum haptoglobin collapsed, and serum LDH increased (3 times normal). C-reactive protein was 98 mg/l and fibrinogen 3g/l. The patient's age led us to search for a congenital cause of hemolytic anemia, notably hemoglobinopathy, enzymopathy, or membrane abnormality. With this in mind, hemoglobin electrophoresis was performed, as well as G6PD assay, which had collapsed to 2.6 IU/g Hb (7 - 10 IU/d hemoglobin). Therapeutic measures included transfusion of two packed red blood cells, pulmonary bi-antibiotic therapy, level 2 analgesics according to the visual analog scale, and avoidance of drugs that could cause hemolysis in this setting (Table 2). After two

weeks of hospitalization, the evolution was favorable, the Covid PCR test was negative and the control blood count showed a hemoglobin level of 12.1 g/dl.

DISCUSSION

There are around 350 million people worldwide with glucose-6-phosphate dehydrogenase (G6PD) deficiency, with higher frequency levels in sub-Saharan Africa [6]. G6PD deficiency is an X-linked disease resulting from an alteration or mutation of the G6PD gene located at the distal end of the long arm of the X chromosome [22][19]. Because the condition is X-linked, it is often considered and reported to be more common in males; however, heterozygous females are in fact the most common genotype [22][9]. Expression of the genetic mutation is more common in males, as heterozygous females are unlikely to develop full-blown deficiency due to favorable inactivation of the X chromosome [22][4]. Homozygous female genotypes are extremely rare [22][4][5]; complete inactivation of G6PD is incompatible with life and may result in spontaneous abortion [13][2][15]. This statement suggests that our 17-year-old patient has the heterozygous genotype.

Due to variability in gene mutation expression and enzyme deficiency, patients may present with different clinical manifestations depending on their WHO classification, type or extent of trigger, and lifestyle choices [9][12]. The three main types of triggers are infections, certain drugs, and certain foods [22][5][3]. Infection is the most frequently cited cause of acute hemolytic anemia in patients with G6PD deficiency [4]. Infection, whether bacterial, viral, or fungal, produces reactive oxygen species through the inflammatory response, to which deficient cells are particularly sensitive [3]. An *ex vivo* study showed that G6PD-deficient cells are more vulnerable to human coronavirus infection than normal G6PD cells [16]. G6PD deficiency is an asymptomatic condition whose clinical consequences include hematological disorders, such as neonatal jaundice and hemolytic anemia. It usually goes undetected until triggered by hemolytic agents. This may explain the discovery of G6PD deficiency in our previously asymptomatic patient. Clinical presentation in heterozygous females can vary individually and over time, due to X chromosome inactivation and variability in the ratio of deficient to normal erythrocytes [12]. G6PD variants are classified into five classes according to enzyme activity and clinical presentation [10]. Our patient had an enzyme activity of less than 10% and had been asymptomatic since birth; this classifies her as variant type II. G6PD deficiency reduces the quantity of NADPH, and the activity of

antioxidant systems, which depend on the reducing equivalents produced by this enzyme. Deficiency, although most evident in erythrocytes, can impact the biological functions of other cells in the body. In macrophages, for example, G6PD deficiency alters polarization, contributing to the overexpression of inflammatory cytokines [11]. In human granulocytes, G6PD deficiency abolished lipopolysaccharide-induced NO production [18]. This is important because unrecognized G6PD deficiency in patients infected with SARS-CoV-2 could be associated with severe infection with worse outcomes by inducing hemolytic crisis [7]. However, our patient did not present with a severe infection; she consulted 2 days after the onset of symptoms. Early management could be a limiting factor in this potentially serious infection. Hydroxychloroquine is no longer an acceptable mode of treatment in COVID-19 but it is conceivable that during the time when it was in use coexistence of G6PD deficiency could have led to severe hemolysis [8][14].

CONCLUSION

This case study illustrates the relative vulnerability of G6PD-deficient patients to SARS-COV-2 infection and suggests that systematic screening for G6PD deficiency should be considered in order to anticipate management and avoid potentially deleterious drugs in G6PD-deficient patients.

Table 1: Biological characteristics of the patient

Biological parameters		
• Full blood count		Norms
White Blood Cells (G/L)	17	4 – 10
Neutrophils (G/L)	11	1,8 – 7
Lymphocytes (G/L)	3	1,5 – 4
Monocytes (G/L)	1,5	0,1 – 0,9
Hemoglobin (g/dl)	9	12 – 14
MCV (fl)	88	80 – 90
MCHC (pg)	26	27 – 32
MCCH (g/dl)	29	32 – 36
Platelets (G/L)	238	200 – 400
Reticulocyte levels (G/L)	253	80 – 120
• Hemolysis assessment		Normes
LDH (UI/l)	654	120 – 246
Haptoglobin (g/l)	0,2	0,30 – 2
Unconjugated bilirubin (mg/l)	24	< 10
• Hemostasis assessment		Normes
Prothrombin levels (%)	100	70 – 100
Ratio TCA	1	0,8 – 1,2
Fibrinogen (g/l)	3	2 – 4
D - Dimers (microgrammes/litre)	600	< 500
• Inflammatory assessment		Norms
Sedimentation rate (mm) at 1st hour	100	< 15 mm at 1st hour
C reactive Protein (mg)	98	< 12 mg/l

*Abbreviations: LDH: lactate dehydrogenase; APTT: activated partial thromboplastin time

UNDER PEER REVIEW

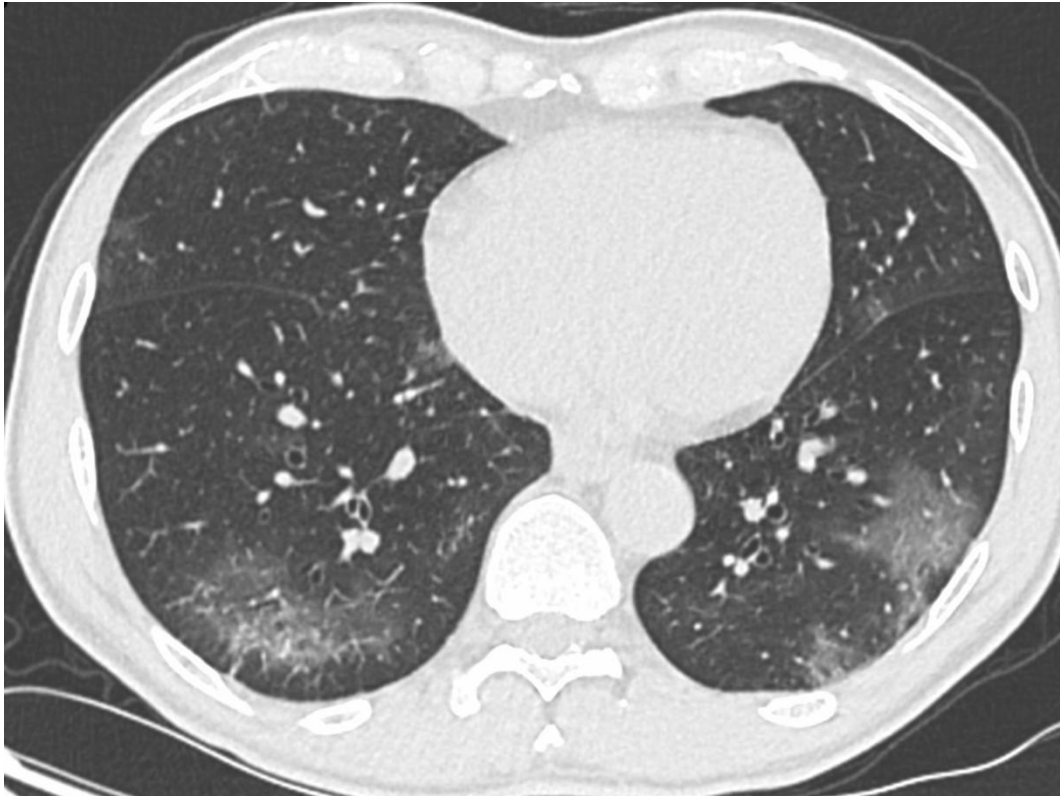

Figure 1: Chest CT scan without injection in axial sections: bilateral ground-glass areas (arrows)

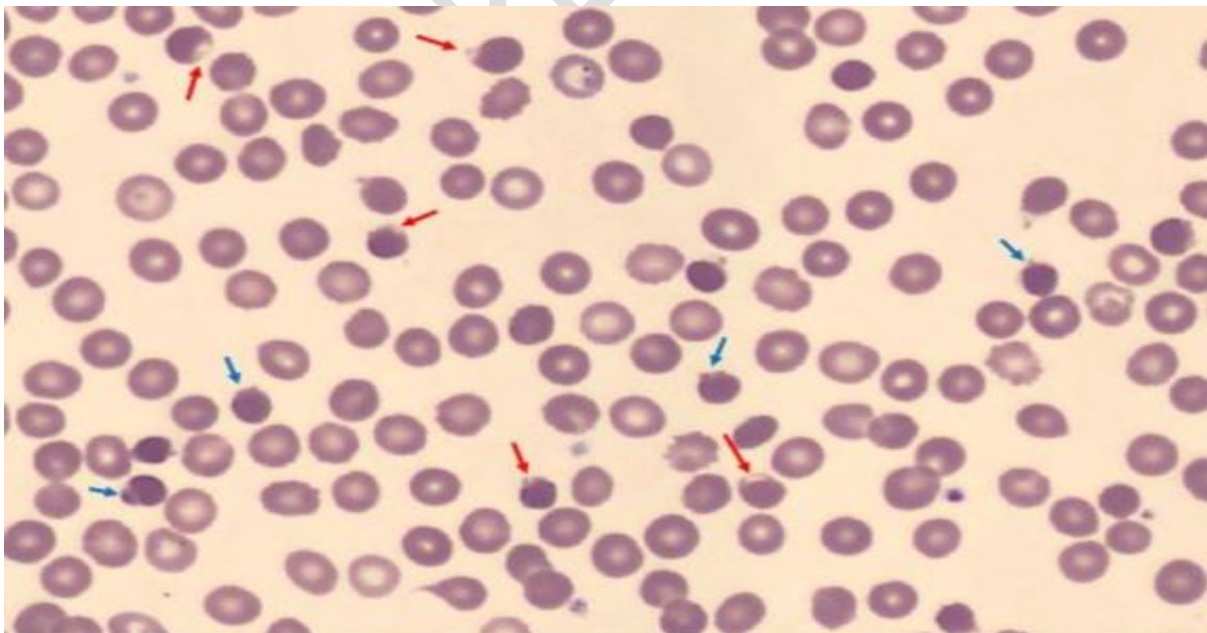


Figure 2: May Grunwald Giemsa-stained blood smear: ghost red blood cells (blue arrow) bite cells (red arrow)

UNDER PEER REVIEW

Table 2: Common medications that patients with G6PD deficiency should avoid or use with caution.

Generic name	Risk level	Variant
Acetaminophen	Low	All
Acetylsalicylic acid	Variable*	All
Ascorbic acid (vitamin C)	High, with high-dose therapy	All
Chloramphenicol	High	Mediterranean, Asian
Ciprofloxacin	High	All
Colchicine	Low	All
Diphenhydramine	Low	All
Glimepiride	High	All
Glipizide	High	All
Glyburide	Use with caution	All
Isoniazid	Low	All
Levofloxacin	High	Mediterranean, Asian
Methylene blue	High	All
Moxifloxacin	High	Mediterranean, Asian
Nitric oxide	High	All
Nitrofurantoin	High	All
Nitroglycerin	High	All
Phenazopyridine (pyridium)	High	Mediterranean, Asian
Primaquine	High**	All
Probenecid	High	All
Rasburicase	High***	All
Sodium nitroprusside	High	All
Streptomycin	Low	All
Sulfacetamide	High	All
Sulfamethoxazole	High****	All
Trimethoprim	Low****	All
Vitamin K	Low to high†	All

Ethical Approval:

As per international standard or university standards written ethical approval has been collected and preserved by the author(s).

Consent

As per international standards, parental written consent has been collected and preserved by the author(s).

REFERENCES

1. Albagshi MH, Alomran S, Sloma S, et al.. Prevalence of Glucose-6-Phosphate Dehydrogenase Deficiency Among Children in Eastern Saudi Arabia. *Cureus*. 2020.
2. Boonyuen U, Chamchoy K, Swangsri T, et al. A trade-off between catalytic activity and protein stability determines the clinical manifestations of glucose-6-phosphate dehydrogenase (G6PD) deficiency. 2017.
3. Bulp J, Jen M, Matuszewski K. Managing patients with glucose-6-phosphate dehydrogenase (G6PD) deficiency: implications for pharmacy. 2015.
4. Gómez-Manzo S, Marcial-Quino J, Vanoye-Carlo A, et al. Glucose-6-phosphate dehydrogenase: update and analysis of new mutations worldwide. 2016.
5. Heuvel E., Baauw A, Mensink-Dillingh SJ, et al. A rare disease or not? How a child with jaundice changed a national diet in the Netherlands. 2017.

6. Howes RE, Piel FB, Patil AP, et al. G6PD Deficiency Prevalence and Estimates of Affected Populations in Malaria Endemic Countries: A Geostatistical Model-Based Map. von Seidlein L, ed. PLoS Med. 2012.
7. Jamerson BD, Haryadi TH, Bohannon A. Glucose-6-Phosphate Dehydrogenase Deficiency: An Actionable Risk Factor for Patients with COVID-19? Arch Med Res. 2020;51(7):743-744.
8. Laslett N, Hibbs J, Hallett M, et al. Glucose-6-Phosphate Dehydrogenase Deficiency-Associated Hemolytic Anemia and Methemoglobinemia in a Patient Treated With Hydroxychloroquine in the Era of COVID-19. Cureus. 2021.
9. Sparrow RL. Red blood cell components: it is time to revisit the sources of variability. Blood transfusion; 2017.
10. Onori ME, Ricciardi Tenore C, Urbani A, et al. Glucose-6-phosphate dehydrogenase deficiency and hydroxychloroquine in the COVID-19 era: a mini review. Mol Biol Rep. 2021;48(3):2973- 2978.
11. Parsanathan R, Jain SK. Glucose-6-phosphate dehydrogenase (G6PD) deficiency is linked with cardiovascular disease. Hypertens Res. 2020;43(6):582-584.
12. Relling MV, McDonagh EM, Chang T, et al. Clinical Pharmacogenetics Implementation Consortium (CPIC) guidelines for rasburicase treatment in the context of G6PD deficiency genotype. 2014.
13. Richardson SR, O'Malley GF. Glucose 6 Phosphate Dehydrogenase (G6PD) deficiency. 2018.

14. Scholkmann F, Restin T, Ferrari M, Quaresima V. The Role of Methemoglobin and Carboxyhemoglobin in COVID-19: A Review. *J Clin Med*. 2020;10(1):50.
15. Suhartati Soemarno TM, Notopuro H, Santoso H. Glucose 6 phosphate dehydrogenase (G6PD) deficiency in history of poor pregnancy at St. Vincentius A Paulo Catholic Hospital, Surabaya. 2007.
16. Wu Y-H, Tseng C-P, Cheng M-L, Ho H-Y, Shih S-R, Chiu DT-Y. Glucose-6-Phosphate Dehydrogenase Deficiency Enhances Human Coronavirus 229E Infection. *J Infect Dis*. 2008;197(6):812-816.
17. Yang H-C, Ma T-H, Tjong W-Y, et al. G6PD deficiency, redox homeostasis, and viral infections: implications for SARS-CoV-2 (COVID-19). *Free Radic Res*. 2021;55(4):364-374.
18. Youssef JG, Zahiruddin F, Youssef G, et al. G6PD deficiency and severity of COVID19 pneumonia and acute respiratory distress syndrome: tip of the iceberg? *Ann Hematol* . 2021;100(3):667-673.
19. Erythrocyte glucose-6-phosphate dehydrogenase (G6PD) deficiency and screening programs for sickle cell traits. 2019.
20. <https://www.scidev.net/afrique-sub-saharienne/news/maludisme-outil-g6pd-06102019/> . .
21. <http://www.favisme.ch/fr/articles/repartition-geographique-du-deficit-en-g6pd-a-travers-le-monde/>.
22. National Organization for Rare Diseases. . Available at: <https://rarediseases.org/rare-diseases/glucose-6-phosphate-dehydrogenase-deficiency>.

UNDER PEER REVIEW