TUBERCULOSIS: MASQUERADE IN OTORHINOLARYNGOLOGY

Abstract:

Tuberculosis is a completely curable disease which can affect any part of the body. But rare site TB can lead to diagnostic dilemma as it mimics other conditions. This study aims at identifying cases at an early stage preventing morbidity and mortality associated with the same.

KEYWORDS: cholesteatoma, diagnostic error, parotid, radiology of the paranasal sinuses

INTRODUCTION

Tuberculosis (TB) is a bacterial infection caused by Mycobacterium tuberculosis. Commonest site of involvement is lung, but it can also affect other parts of the body known as extrapulmonary tuberculosis. However, extrapulmonary tuberculosis poses a diagnostic challenge. Since COVID pandemic there was significant reduction of around 18% in TB cases according to 2021 WHO report.[1] But still it accounts for significant morbidity worldwide. Even though the mortality rate is high, it's a completely curable condition with prompt treatment.

Most common site of extrapulmonary TB is lymph node. Our study covers one of its rare forms, the otorhinolaryngeal TB. Our study aims at understanding this diagnostic puzzle and its timely management.

CASE REPORT

We had four cases of rare site TB in the head and neck region.

A 45-year-old female presented with a non-healing ulceroinflammatory lesion over the right medial canthus which was not improving with antibiotics. On anterior rhinoscopy, a fleshy pink bleeding nasal mass was visualised below the right inferior turbinate. Imaging studies revealed a heterogeneously enhancing mass lesion with erosion of adjacent walls. All these investigations narrowed down the differential diagnosis to the possibility of either a lacrimal sac neoplasm or a granulomatous lesion involving the lacrimal sac. Hence to obtain a confirmatory diagnosis, biopsy from representative area was taken. To our surprise, the

histopathological assessment was reported as caseating granuloma suggestive of TB. Anti- tubercular therapy (ATT) was then started and resulted in a healed lacrimal tract fistula (Figure 1) which was later taken for secondary suturing.

Next was a 38-year-old male patient who had slow growing painless swelling in the left infraauricular region. An ultrasonography (USG) was advised initially which reported as suspected ruptured dental abscess. Fine needle aspiration cytology (FNAC) showed inflammatory pathology, acid fast bacilli stain was negative. To assess the spread a CT scan was done which had features suggestive of parapharyngeal neoplasm with submandibular, parotid glands, mandible and left petrous temporal bone involvement with necrotic lymph node (Figure 2). Here our differentials were parapharyngeal neoplasm and osteomyelitis of mandible. In view of those necrotic lymph nodes, a biopsy was advised. USG guided biopsy was performed and sent for HPR which came as necrotising granulomatous lymphadenitis possibly of tubercular aetiology, but special stains for TB were negative. Still, we went on with TB management and the patient started showing recovery in 3 weeks of commencement of ATT.

Third case was that of a 14-year-old female who presented with gradual onset diplopia on right lateral gaze. Clinical examination showed right lateral rectus palsy, rest everything was normal. Radiological imaging of paranasal sinus revealed isolated sphenoid sinus disease eroding the roof of sphenoid (Figure 3) with contrast enhancement in parasellar cavernous sinus. Differential diagnosis of sellar neoplasm, osteomyelitis of sphenoid or allergic fungal rhinosinusitis were taken into consideration. She was posted for surgical clearance of the sinus. Intraoperatively we found granulation tissue (Figure 4) over the sinus mucosa and sample was taken for histopathology reporting. The report was conclusive of multidrug resistant TB on gene xpert. Visual complaints reversed within 1 month of starting ATT.

Another such case was of a 50-year-old female presented with left sided lower motor neuron (LMN) facial palsy and left sided gradual hearing loss associated with vertigo for 8 months. High resolution CT of temporal bone and MRI revealed contrast enhanced erosive lesion involving the left petrous apex (Figure 5). So, we made a differential list of temporal bone neoplasm, osteomyelitis involving the petrous apex and petrous apex cholesteatoma. Since her hearing in left side was non salvageable, we went on with trans cochlear approach and tissue sample were sent for HPR and the result came as TB.

DISCUSSION

Tuberculosis is an endemic disease in developing countries and now there is resurgence of TB in developed countries due to the increased global incidence of AIDS.[2] Despite lungs being the primary site of involvement, extrapulmonary TB is the major clinical problem as it poses a diagnostic challenge. Extrapulmonary TB accounts for 16% of all incident cases worldwide.[3] The presentations are often misleading camouflaging other conditions because of clinical plagiarism.[3,4] Most common site of extrapulmonary TB is cervical lymphnodes.[1] Rare forms of extrapulmonary TB include cutaneous, breast, otorhinolaryngeal and disseminated TB.

In our study, first case was an ulceroproliferative lesion of the lacrimal tract failed with conventional treatment modalities, second such case was a parapharyngeal swelling involving mandibular bone, then we had isolated sphenoid sinusitis with cranial neuropathy not recovering with antibiotics and the last patient had petrous apex inflammation with cranial neuropathies. In all these cases, the initial differential diagnosis was neoplastic lesion considering its spread and erosive bony margins. To confirm the diagnosis, biopsy sample was taken in all cases. Keeping in mind, the rise in incidence of extrapulmonary TB with its multidrug resistant form in hike, the tissue samples were also sent for testing TB and reported positive for the same. Still, there was a significant delay in our diagnosis due to its features on imaging favouring neoplasm with subsequent negative stain (acid fast bacilli, AFB) of the FNAC sample.

TB in these rare sites is less mentioned in literature. Failure of initial management protocol should always be an alerting sign to consider TB as a probable diagnosis, especially in a developing country. Routine testing often shows false negative results, so it is necessary to do a cytological/ biopsy evaluation and GeneXpert study to confirm especially in case of rare site extrapulmonary TBs.[5] Specific and accurate diagnostic tests are required for promptly identify these rare cases which can be easily misdiagnosed.[6] With a clinical suspicion of tuberculosis and a positive histopathological report, anti-tubercular therapy should be commenced even on negative AFB staining.[1] Early initiation of treatment will prevent hematogenous spread and thereby mortality.

CONCLUSION

Although the incidence of tuberculosis is high, unusual site tuberculous infections are rare. Rare site tuberculosis mimics malignancy resulting in a diagnostic dilemma. A high index of suspicion of TB should be there when the conventional treatment fails, especially in a developing country where it is endemic. Biopsy sample should always be sent for gene Xpert in doubt. Caseating necrosis with epithelioid granuloma even in the absence of AFB should be treated as TB. If diagnosed early and is still sensitive to first line drugs, then tuberculosis is a completely curable disease.

Ethical Approval:

As per international standard or university standards written ethical approval has been collected and preserved by the author(s).

Consent

As per international standard or university standards, patient(s) written consent has been collected and preserved by the author(s).

COMPETING INTERESTS

Authors have declared that they have no known competing financial interests OR non-financial interests OR personal relationships that could have appeared to influence the work reported in this paper.

REFERENCES

1. Mocanu AI, Mocanu H, Moldovan C, Soare I, Niculet E, Tatu AL, Vasile CI, Diculencu D, Postolache PA, Nechifor A. Some Manifestations of Tuberculosis in Otorhinolaryngology – Case Series and a Short Review of Related Data from South-Eastern Europe. *Infect Drug Resist*. 2022;15:2753-2762 https://doi.org/10.2147/IDR.S367885

2. SCASSO F, FERRARI G, DE VINCENTIIS GC, et al. Emerging and re-emerging infectious disease in otorhinolaryngology. *Acta Otorhinolaryngologica Italica*. 2018;38(2, SUPPLEMENT 1):S1-S106. doi:10.14639/0392-100x-suppl.1-38-2018

3. WHO. Global Tuberculosis Report 2020. Available online: https://www.who.int/publications/i/item/9789240013131 (accessed on 16 April 2021).

4. Tuang GJ, Muhammad A, Zahedi FD. 'Master of many faces: extrapulmonary tuberculosis in the eyes of otolaryngologists'. Postgrad Med J. 2022;98(1158):311-312. doi:10.1136/postgradmedj-2020-139414

5. Qian X, Albers AE, Nguyen DTM, et al. Head and neck tuberculosis: Literature review and meta-analysis. *Tuberculosis*. 2019;116:S78-S88. doi:10.1016/j.tube.2019.04.014

6. Ahmed S, Mustahsan SM, Jamil B, Ilyas F. Nasopharyngeal Tuberculosis. J Coll Physicians Surg Pak 2022;32(Supp1):S39-S40

FIGURE LEGENDS

Figure 1: Right medial canthus ulceroinflammatory lesion before and after anti-tubercular therapy.

Figure 2: Left parapharyngeal soft tissue enhancement with erosion of mandible.

Figure 3: Soft tissue enhancement in sphenoid sinus with erosion of its walls.

Figure 4: Pale granulation tissue obtained during surgery.

Figure 5: CT showing soft tissue lesion involving left petrous apex with bony wall erosion.

Figure 1: Right medial canthus ulceroinflammatory lesion before and after anti-tubercular therapy

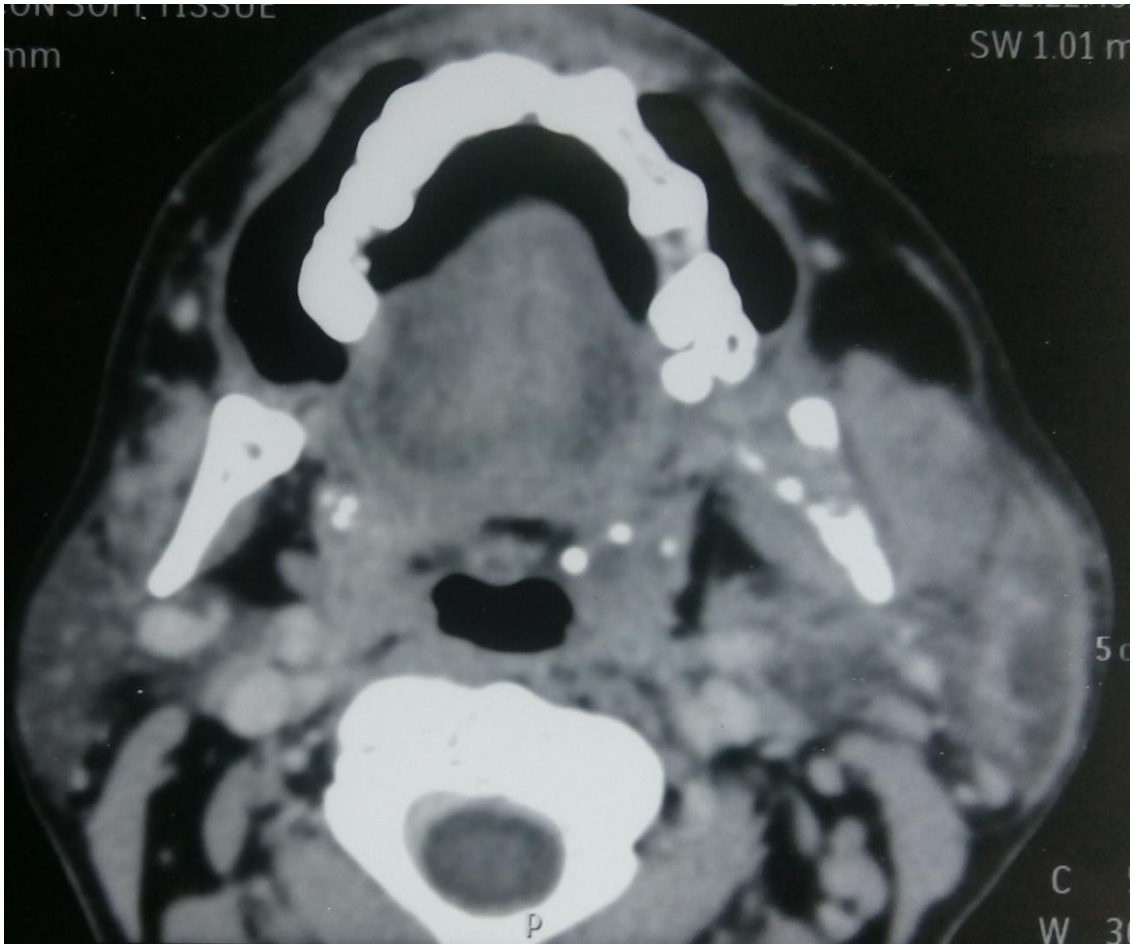

Figure 2: Left parapharyngeal soft tissue enhancement with erosion of mandible.

Figure 3: Soft tissue enhancement in sphenoid sinus with erosion of its walls

Figure 4: Pale granulation tissue obtained during surgery.

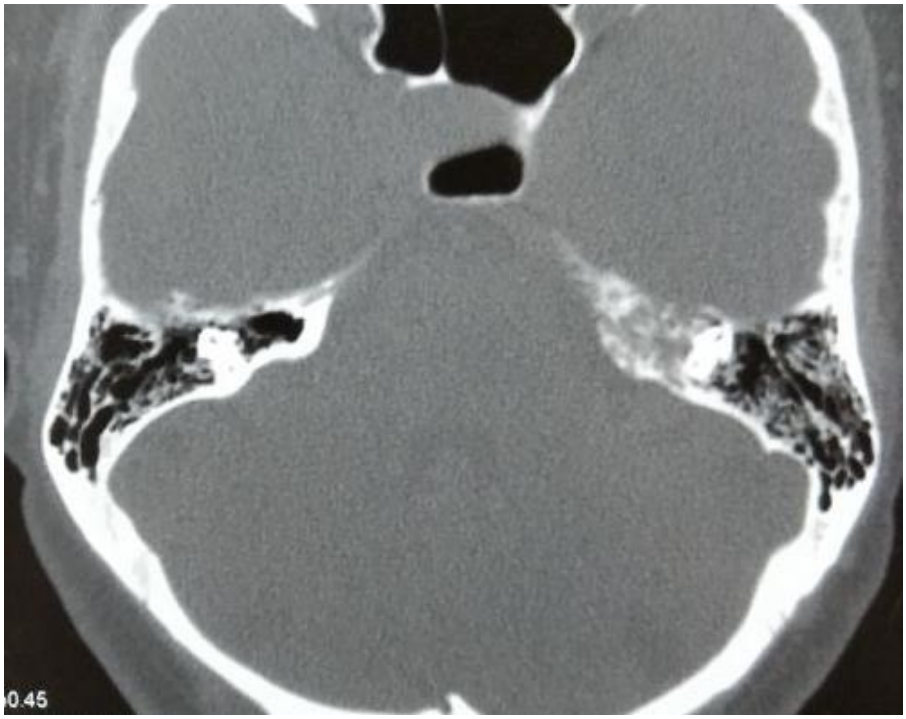

Figure 5: CT showing soft tissue lesion involving left petrous apex with bony wall erosion.