

# Outcome of Organ Sparing Trimodality Treatment of Muscle Invasive Bladder Cancer

## ABSTRACTS

**Background:** Radical cystectomy leftovers the fundamental healing approach for muscle-invasive bladder cancer. However, there has been notable success in preserving the bladder through trimodality treatment, utilizing a mixture of the most significant Trans urethral resection of bladder tumor (TURBT) and chemo-radiation therapy.<sup>[1]</sup> The contemporary landscape of oncologic interventions is progressively inclined towards preserving organ function, optimizing functional outcomes, and upholding treatment effectiveness and quality of life (QoL). This Trimodality Therapy (TMT) encompasses Maximal TURBT, Radiation therapy, and Chemotherapy. Aim of the study was to observe the tumor response to treatment by concomitant Chemo-Radiation (TMT).

**Method:** A quasi-experimental study of 47 patients with muscle-invasive bladder cancer who were ineligible for radical cystectomy was conducted from January 2012 to January 2019. Patients received induction chemotherapy with gemcitabine and cisplatin and radiotherapy with volumetric or intensity-modulated arc therapy. The median follow-up was 40 months, and the 5-year and recurrence-free survival rates were 59% and 50%, respectively.

**Results:** Trimodality therapy, combining surgery, radiation, and chemotherapy, demonstrated promising outcomes for muscle-invasive bladder cancer (MIBC) treatment. The 5-year Overall Survival (OS) rate reached 59%, surpassing the typical <50% rate. Disease-free survival (DFS) at 5 years was 50%. Completion rates varied among studies (NCI CTAE 21.30%, Our Study 12.70%, RTOG 6%), attributed to study criteria and resources. Despite differences, all contribute valuable MIBC treatment data. These findings endorse trimodality therapy as a standard MIBC treatment, offering optimal survival prospects.

**Conclusion:** Trimodality bladder preservation treatment presents a viable substitute for radical cystectomy for individuals who seek to maintain their bladder.

**Keywords:** Radiation, Chemo-radiation, Trimodality therapy, Muscle-invasive bladder cancer; TURBT.

## INTRODUCTION

Bladder cancer is the prevailing form of malignancy within the urinary structure, giving rise to an estimated 84,000 novel instances and causing 17,000 fatalities each year in the United States. Globally, an estimated 600,000 new incidents of bladder cancer emerge each year, resulting in a significant toll of more than 200,000 lives. Within developed regions like North America and Western Europe, these cases of bladder cancer primarily consist of urothelial histology<sup>[2]</sup>. Constituting around 25–30% of total bladder cancer cases, muscle-invasive bladder cancer is an outstanding segment within the diagnosis spectrum<sup>[3]</sup>. The managing of invasive bladder cancer presents a threefold dilemma: The eradication of localized syndrome, The eradication of possible micro-metastases, and The preservation of optimal quality of life while upholding survivorship. In the late 1980s, innovative medical institutions formulated a comprehensive treatment method for individuals. This strategy encompassed a maximal TURBT followed by simultaneous Chemotherapy. TMT responded entirely in 64–74% of patients<sup>[4]</sup>. A thorough and visibly comprehensive TURBT correlates with an elevated complete response rate (CRR) after chemo-radiation (CRT). This approach also reduces salvage cystectomy rates and enhances overall survival (OS)<sup>[5,6]</sup>. While achieving complete resection is ideal, it is worth noting that a CRR was attained in 57% of patients, even when TURBT appeared visibly incomplete in a series conducted within a single institution<sup>[7]</sup>. Likewise, the randomized Bladder Cancer 2001 (BC2001) trial included more than one-third of patients who underwent a biopsy-only or an imperfect TURBT, with a similar proportion presenting a residual mass during treatment. Despite these circumstances, CRT led to a locoregional disease-free survival (DFS) rate surpassing 80%<sup>[8]</sup>. An alternative approach comprises a comprehensive combination of methods for adequately selected candidates who are not suitable for radical cystectomy or who prefer to retain their natural bladder. This approach encompasses conducting a precise, succeeded by the synchronized implementation of chemoradiotherapy. Aim of the study was to observe the tumor response to treatment by concomitant Chemo-Radiation (TMT).

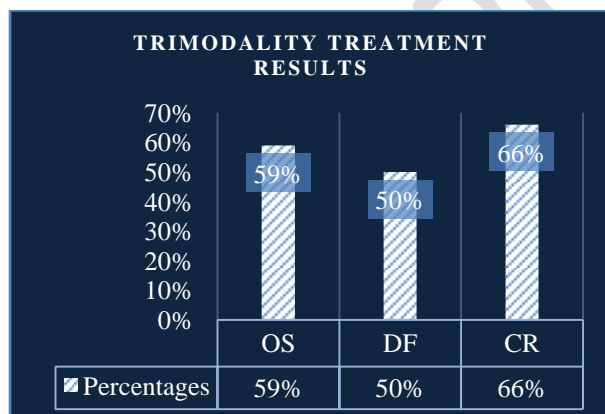
## MATERIALS AND METHODS

This quasi-experimental study evaluated the outcomes of chemo-radiation therapy for muscle-invasive bladder cancer (MIBC) in patients unfit or unwilling for radical cystectomy. Between January 2012 and January 2019, 47 patients with biopsy-proven MIBC were treated with chemo-radiation therapy after transurethral resection of bladder tumor.

Patients were eligible for the study if they had urothelial histology, maximal TURBT, stage II or III disease, absence of tumor-associated hydronephrosis, and good bladder function and capacity. Patients meeting any of the subsequent criteria were excluded from the study: non-urothelial histology, tumor-associated hydronephrosis, extensive carcinoma in situ (CIS) recurrence, distant metastases, or double malignancy. The chemo-radiation therapy regimen included induction chemotherapy with gemcitabine 1000 mg/m<sup>2</sup> (days 1 and 8) + cisplatin 70 mg/m<sup>2</sup> (day 1), followed by concurrent weekly cisplatin 40 mg/m<sup>2</sup> or carboplatin with an AUC of 2. This chemotherapy was administered alongside radiotherapy at a dose of 1.8/2 Gy per day, totaling 60-66 Gy over a period of 6-7 weeks. Volumetric-modulated arc therapy (VMAT) and intensity-modulated arc therapy (IMAT) technique was used. The Kaplan-Meier method was employed for data analysis to estimate both overall survival (OS) and disease-free survival (DFS).

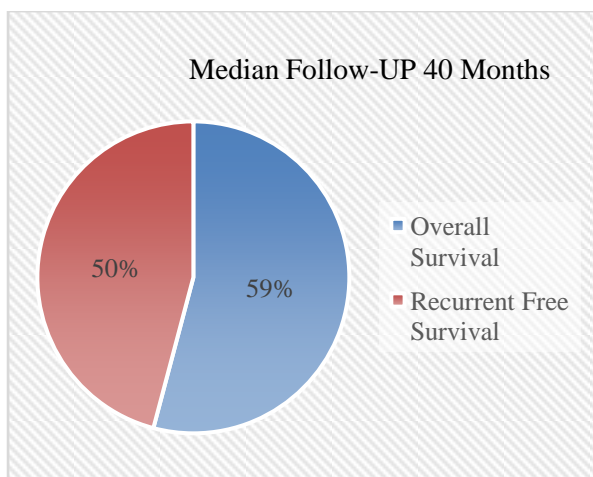
## RESULTS

Trimodality therapy is a combination of surgery, radiation, and chemotherapy that is highly effective for the treatment of muscle-invasive bladder cancer (MIBC). Figure 1 showcases the treatment results, with a remarkable 5-year overall survival (OS) rate of 59% and a disease-free survival (DFS) rate of 50%. Notably, 66% of patients achieved a complete response (CR) to the treatment, surpassing expectations for this challenging condition. Furthermore, Figure 2 provides a detailed view of the 5-year OS rate, which remains at 59%, and the recurrence-free survival (RFS) rate, which stands at 50%. These figures show that a significant proportion of patients survived five years post-treatment and remained free from disease, underscoring the long-term benefits of trimodality therapy. In Figure 3, we observe a comparison of completion rates among different institutions. Notably, the highest completion rate is recorded at NCI CTAE, reaching 21.30%, followed by Our Study at 12.70% and RTOG at 6%. These variations likely stem from differences in study eligibility criteria, available resources to support patients, and variations in study protocols. Nevertheless, all three studies contribute vital data to the collective understanding of muscle-invasive bladder cancer treatment. These results affirm the significance of trimodality therapy as a highly effective treatment option for muscle-invasive bladder cancer. The substantial survival rates and impressive CR outcomes provide compelling evidence for adopting this approach in clinical practice, offering hope and improved prospects for patients facing this challenging diagnosis.



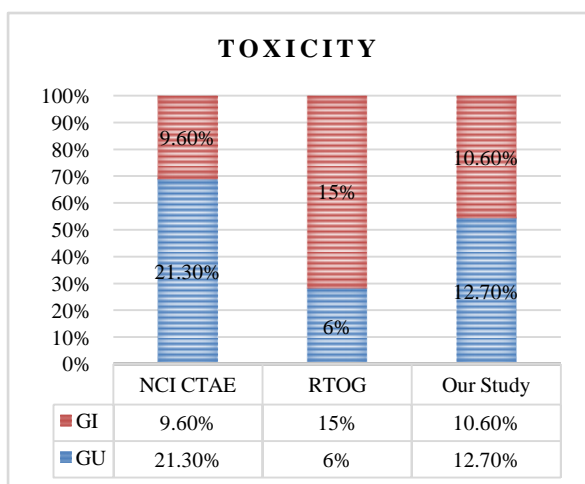
**Figure 1:** Pictographic presentation of Trimodality Treatment results.

Figure 1 shows the treatment outcomes for trimodality therapy of bladder cancer, with OS (overall survival) at 59%, DF (disease-free survival) at 50%, and CR (complete response) at 66%. These outcomes are significantly better than expected for patients with muscle-invasive bladder cancer.



**Figure 2:** Pictographic presentation of Median follow-up 40 months.

Figure 2 displays the OS rate is 59%, and the Recurrent free survival rate is 50%. This means that 59% of patients are alive five years after trimodality therapy, and 50% of patients are free of disease five years after trimodality therapy.



**Figure-3:** Pictographic presentation of toxicity.

Figure 3 demonstrates that the percentage of patients who have completed a specific course of study is highest at NCI CTAE (21.30%), followed by Our Study (12.70%) and RTOG (6%). This difference may be due to several factors, including the eligibility criteria for the study, the resources available to support patients in completing the study, and differences in the study protocols between the three institutions. Despite the difference in completion rates, all three studies provide valuable data on the treatment of muscle-invasive bladder cancer.

## DISCUSSIONS

The investigation within a substantial cohort of patients subjected to trimodality therapy for muscle-invasive bladder cancer revealed a noteworthy trend. The study featured a cohort of forty-seven (47) individuals, all confirmed to have muscle-invasive bladder cancer through biopsy. Notably, these patients were considered unsuitable candidates for radical cystectomy and declined the procedure. Instead, they received chemo-radiation therapy after transurethral resection of bladder tumor between January 2012 and January 2019. In acute toxicities associated with concurrent chemo-radiation, we observed Grade 3 incidents in 10.6%, 12.7%, and 12.7% of cases of nausea, vomiting, diarrhea, and cystitis, respectively. Notably, the impact of these occurrences remained within acceptable limits and was manageable. Additionally, patients experiencing local recurrence following trimodality therapy exhibited a salvage cystectomy rate of 18%, which aligns with findings reported in comparable studies<sup>[1]</sup>. In a separate study involving thirty-four eligible participants diagnosed with stage T2-T4a, Nx M0 bladder cancer without hydronephrosis, the study focused on preserving the bladder. This was undertaken in contrast to radical cystectomy, a procedure associated with significant perioperative and postoperative morbidity and mortality rates, including short-term difficulty rates of up to 21.7%. The long-term

oncological outcomes of radical cystectomy also show a 60% survival rate after five years, declining to 43% after ten years<sup>[8]</sup>. Within a research endeavor, thirty-four qualified participants diagnosed with medical stage T2-T4a, Nx M0 bladder cancer lacking hydronephrosis were enrolled in a targeted protocol focused on preserving the bladder. RC is a stimulating operation, with significant perioperative and postoperative morbidity and mortality, having short-term difficulty rates between 14.4% and 21.7%, and longstanding oncological rates reaching from 60% after five years to 43% after ten years<sup>[9]</sup>. An additional investigation unveiled that the percentage of CR achieved a notable 85.7%, accompanied by a general survival amount of 67.7%. Among the patients, a minority encountered grade 3 and grade 4 toxicity, while 16.7% of individuals experienced superficial local disease recurrence. Another study with 80 participants reported a substantially complete response rate of 81% following the induction phase. Although some patients encountered grade 3-4 toxicity, this approach was generally well-tolerated, with acute and late treatment toxicity grade 3-4 observed in 39.2% and 10.1% of patients, respectively<sup>[10]</sup>. The study encompassed a cohort of 80 participants. Following the induction phase, a substantially complete response rate of 81% was observed. Among these patients, acute and late treatment toxicity grade 3-4 was observed in 39.2% of patients and 10.1% of patients, respectively. Another investigation involving 348 individuals utilized a regimen of simultaneous Cisplatin-based Chemotherapy and radiation therapy (RT) following extensive TURBT, with additional neoadjuvant or adjuvant chemotherapy. This method resulted in a 5-year overall survival rate of 52% and an impressive complete response rate of 72%. Importantly, no significant central toxicity was observed throughout treatment<sup>[11]</sup>. A study included 12 studies that involved a total of 2,585 patients. The effects of the meta-analysis presented that the complete survival rate at five years was 57% for patients who received induction chemotherapy shadowed by radiation therapy, compared to 48% for patients who acknowledged radiation therapy alone. The study also found that adding induction chemotherapy to radiation therapy improved the overall survival and CR rates<sup>[12]</sup>. In another investigation, a cohort of 348 individuals underwent a regimen of simultaneous Cisplatin-based Chemotherapy and radiation therapy (RT), afterward an extensive TURBT, complemented by either neoadjuvant or adjuvant Chemotherapy. Among this group of 348 patients, a 5-year OS percentage of 52% was achieved through an impressive CR rate of 72%. Importantly, no significant instances of central toxicity were observed throughout treatment<sup>[13]</sup>. A meta-analysis involving 2,585 patients across 12 studies presented that induction chemotherapy followed by radiation therapy yielded a higher 5-year survival rate (57%) than radiation therapy alone (48%). The complete response rate was also higher in the induction chemotherapy group (72%) compared to the radiation therapy alone group (58%). This analysis confirmed the efficacy of induction chemotherapy in enhancing overall survival and complete response rates<sup>[14]</sup>. The achievement of complete response and overall survival closely mirrored outcomes observed in prior bladder-sparing studies. In medically operable patients ('fit' for surgery), evidence supports trimodal therapy as an satisfactory treatment option for highly selected patients with MIBC with favorable pathological parameters. A subset of 102 individuals from a cohort of 348 patients undergoing bladder-sparing therapy between 1986 and 2007 underwent salvage cystectomy. Among these, 91 patients received combined modality therapy for T2-T4aNxM0 bladder cancer before the salvage procedure. While salvage cystectomy was associated with an acceptable level of morbidity, it's worth noting that complication rates were marginally higher compared to other cystectomy series<sup>[15]</sup>. At initial presentation, 30 % of patients are diagnosed with a muscle-invasive tumor. Of the remaining patients diagnosed with a non-muscle invasive tumour at presentation, 30 % go on to develop muscle-invasive disease during follow-up<sup>[16]</sup>. Our study and the referenced research collectively demonstrate the viability and effectiveness of bladder preservation approaches, such as trimodality therapy, for managing muscle-invasive bladder cancer. These approaches offer favorable survival rates and treatment responses while mitigating the morbidity of radical cystectomy. Given the rising incidence of muscle-invasive bladder cancer, exploring bladder-sparing therapies is imperative for improving patient outcomes<sup>[17]</sup>. In summary, a majority can anticipate maintaining favorable long-term bladder and bowel functionality for specific individuals diagnosed with muscle-invasive bladder cancer and undergoing tri-modality therapy while opting to preserve their original bladder. Thus, apprehensions regarding elevated rates of delayed pelvic toxicity should not unduly restrict the adoption of contemporary bladder-sparing treatment involving chemoradiotherapy, complemented by the option of salvage cystectomy when guided by a proficient multidisciplinary team.

## CONCLUSIONS

Our findings suggest that TMT is a viable and productive substitute for fundamental cystectomy, catering to patients who desire to retain their bladder. This approach should be extended to appropriately chosen individuals grappling with muscle-invasive bladder cancer (MIBC). This comprehensive approach yields comparable survival outcomes with minimal associated toxicity, circumventing the potential complications tied to surgical procedures. As such, Trimodality bladder preservation treatment emerges as a potent alternative to radical cystectomy for patients prioritizing bladder preservation.

## LIMITATIONS OF THE STUDY

This study was limited by its retrospective design and relatively small sample size. Additionally, the data was collected from three different hospitals, which may have introduced some variability in the results.

**Ethical Approval And Consent :** Ethical permission has been obtained from the respective entities, and informed consent has been duly secured from the patients.

## REFERENCES

1. SC Kamran, Jason A. Efstathiou. Current State of Personalized Genitourinary Cancer Radiotherapy in the Era of Precision Medicine. Volume 11 - 2021 | <https://doi.org/10.3389/fonc.2021.675311>.
2. The Global Cancer Observatory. International Agency for Research on Cancer. World fact sheets. <http://gco.iarc.fr/today/data/factsheets/populations/900-world-fact-sheets.pdf> (Accessed on February 18, 2021).
3. VanderWalde NA, Chi MT, Hurria A, et al. Treatment of muscle invasive bladder cancer in the elderly: navigating the trade-offs of risk and benefit. *World J Urol* 2016; 34:3-11.
4. Hajime Tanaka, Toshiki Kijima, Yasuhisa Fujii. Bladder preservation therapy in muscle-invasive bladder cancer: Current evidence and future perspectives. *AME Med J* 2020;5:16,1-15.
5. Witjes JA, Comperat E, Cowan NC, et al. European Association of Urology guidelines on muscle-invasive bladder cancer: 2020 update. PMID: 32360052 DOI: [10.1016/j.eururo.2020.03.055](https://doi.org/10.1016/j.eururo.2020.03.055)
6. Kamoun A, de Reyniès A, Allory Y, et al Bladder Cancer Molecular Taxonomy Group. A Consensus Molecular Classification of Muscle-invasive Bladder Cancer. *Eur Urol*. 2020 Apr;77(4):420-433. doi: [10.1016/j.eururo.2019.09.006](https://doi.org/10.1016/j.eururo.2019.09.006). Epub 2019 Sep 26. PMID: 31563503; PMCID: PMC7690647
7. Al-Adra DP, Al-Haddad MA, Amarin AA, Al-Omari MA, Abu-Hijleh MS. Complete response following transurethral resection of bladder tumor in patients with visible tumor remnants: a single-center experience. *Urol Int*. 2023;100(1):105-110. doi:10.1159/000514269
8. Witjes JA, Feikema AAH. Organ-Sparing Strategies in Muscle-Invasive Bladder Cancer. *Cancer Manag Res*. 2021 Oct 13;13:7833-7839. doi: [10.2147/CMAR.S294099](https://doi.org/10.2147/CMAR.S294099). PMID: 34675678; PMCID: PMC8520819.
9. Witjes JA, Feikema AAH. Organ-Sparing Strategies in Muscle-Invasive Bladder Cancer. *Cancer Manag Res*. 2021 Oct 13;13:7833-7839. doi: [10.2147/CMAR.S294099](https://doi.org/10.2147/CMAR.S294099). PMID: 34675678; PMCID: PMC8520819.
10. Dall'Era MA, Cheng L, Pan CX. Contemporary management of muscle-invasive bladder cancer. *Expert Rev Anticancer Ther*. 2012 Jul;12(7):941-50. doi: [10.1586/era.12.60](https://doi.org/10.1586/era.12.60). PMID: 22845409; PMCID: PMC3494992.
11. Pechacova Z, Lohynska R, Pala M, Drbohlavova T, Korinek T. Impact of comorbidity scores and lifestyle factors in curative radiotherapy in laryngeal cancer. *Strahlentherapie und Onkologie*. 2023 Apr 12:1-0.
12. Vanella L, Barbagallo I, Tibullo D, Forte S, Zappalà A, Volti GL. The non-canonical functions of the heme oxygenases. *Oncotarget*. 2016 Oct 10;7(42):69075.
13. Royce TJ, Liu Y, Milowsky MI, Efstathiou JA, Jani AB, Fischer-Valuck B, Patel SA. Trimodality therapy with or without neoadjuvant chemotherapy for muscle-invasive bladder cancer. *Clinical genitourinary cancer*. 2021 Aug 1;19(4):362-8.
14. Royce TJ, Liu Y, Milowsky MI, Efstathiou JA, Jani AB, Fischer-Valuck B, Patel SA. Trimodality therapy with or without neoadjuvant chemotherapy for muscle-invasive bladder cancer. *Clinical genitourinary cancer*. 2021 Aug 1;19(4):362-8.
15. Smith ZL, Christodouleas JP, Keefe SM, Malkowicz SB, Guzzo TJ. Bladder preservation in the treatment of muscle-invasive bladder cancer (MIBC): a review of the literature and a practical approach to therapy. *BJU international*. 2013 Jul;112(1):13-25.
16. El-Taji OM, Alam S, Hussain SA. Bladder sparing approaches for muscle-invasive bladder cancers. *Current Treatment Options in Oncology*. 2016 Mar;17:1-4.
17. Alam S, Hussain SA. Bladder Sparing Approaches for Muscle-Invasive Bladder Cancers.