

Case report

GIANT PROSTATE CANCER – A CLINICAL ENIGMA

ABSTRACT

Prostate is an accessory male sexual organ, which can produce clinical illnesses in the elderly, in the form of benign enlargement, cancers or infections. Although giant prostatic hyperplasia has been described as an entity in literature, prostate cancers reaching such giant proportions without producing local symptoms or metastases is a rarity. We present reports of three cases of giant prostate cancers managed in our centre.

KEY WORDS

Giant Prostate Cancer, Androgen Deprivation Therapy, Benign Prostatic Enlargement, Urinary Outflow Obstruction

INTRODUCTION

There are two main diseases in the prostate gland that are clinically relevant – benign prostatic enlargement (BPE) and prostate cancer (PC). The more prevalent BPE becomes symptomatic only when prostate has enlarged to a degree sufficient to restrict the outflow of urine from urinary bladder. When the size of the prostate in BPE is more than 500 gms, it is called as giant prostatic hyperplasia and the largest prostate described in literature was weighing 2410 gms [1,2]. PC, which is the second most common cancer in men worldwide, can either produce symptoms related to obstruction of urinary flow or metastases. Sometimes the disease is picked up only when the serum Prostate Specific Antigen (PSA) levels are found elevated. As the size of primary tumour increases, there is high change of obstruction to outflow of urine from urinary bladder in varying degrees, later leading to metastases. However it is extremely rare to find PC attaining giant sizes without producing any local symptoms or causing metastases. We present three case reports of such asymptomatic 'giant prostate cancers' of volume more than 1000 ml occurring in otherwise healthy patients, which were diagnosed during regular evaluation for other unrelated symptoms.

Comment [C.G.1]: Incorrect statement. Prostatitis is a significant disease of the prostate.

CASE REPORT 1

A 65 year old man presented with progressive lower abdominal swelling of 6 yrs duration with no other complaints. On palpation, the hard mass was occupying almost the entire of lower abdomen (Fig 1, Panel A). The mass persisted even after catheterisation done to rule out urinary retention. Digital rectal examination (DRE) showed a very large hard mass in the region of prostate, with no separate anatomical planes made out around the mass. CT scan abdomen showed that the pelvic mass was a giant prostatic mass of volume more than 2000 ml, with the urinary bladder compressed and pushed up to a level above the umbilicus (Fig 1, Panels B,C). There were no lymph node enlargement and no involvement of any ~~other~~ intra-

abdominal organs. His PSA was 188 ng/ml. Trans-rectal trucut biopsy taken from the mass was suggestive of adenocarcinoma of prostate, Gleason's Grade 4+3=7. A whole body bone scan did not show evidence of bony metastases. Since the mass was anatomically very large, surgical removal or local radiotherapy was not attempted. The patient was treated by total androgen blockade (bilateral orchiectomy + bicalutamide). The patient has been doing well on regular follow up for the last 3 yrs with a reduction in the size of primary tumour and PSA levels.

Comment [C.G.2]: Blind or ultrasound-guided?

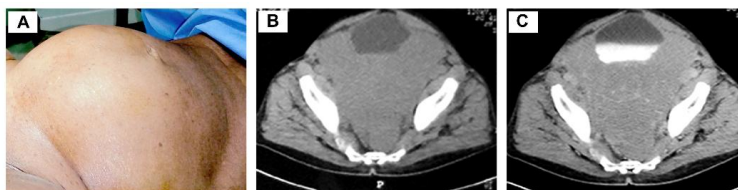


Figure 1. Panel A: clinical picture of the patient with giant prostate cancer showing lower abdominal swelling caused by the tumour

Panel B: plain CT image coronal view showing giant prostate cancer with urinary bladder compressed and pushed up

Panel C: contrast CT coronal image showing the urinary bladder filled with contrast pushed up by the giant prostate cancer

CASE REPORT 2

A 62 year old man presented with progressive swelling in his right thigh since the last 2 years with no other complaints. On palpation, there was a hard mass occupying the upper medial part of right thigh deep to the muscles, extending almost upto the mid-thigh. DRE showed a very large hard mass in the region of prostate, infiltrating the right lateral pelvic walls and extending down into the thigh. CT scan abdomen showed that the patient had a giant prostatic mass of volume more than 1500 ml, with infiltration of right pelvic bones and extending into the right thigh, eroding the femur (Fig 2, Panels A,B,C,D). There were no lymph node enlargement and no involvement of any other intra-abdominal organs. His PSA was more than 1000 ng/ml. A whole body bone scan did not show evidence of bony metastases elsewhere. Transrectal trucut biopsy taken from the mass was suggestive of adenocarcinoma prostate Gleason's Grade 4+4=8. Since the mass was anatomically very large with involvement of pelvic bones and femur, the patient was treated by total androgen blockade (bilateral orchiectomy + bicalutamide) and local radiotherapy. Unfortunately, the patient died of cardiac arrest in 4 months' time, while on treatment.

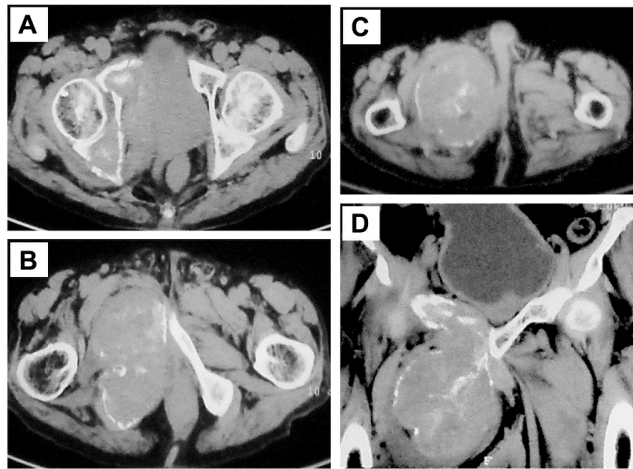


Figure 2. Panel A,B,C: Contrast CT axial images showing giant prostate cancer infiltrating the right lateral pelvic wall, femur and extending up to up to the mid-thigh deep to the muscle planes

Panel D: Contrast CT coronal image showing the extent of giant prostate cancer

CASE REPORT 3

A 76 year old man presented with chronic constipation of 6 months' duration. He had no other symptoms and had well controlled diabetes mellitus on oral medications. DRE was suggestive of a very large hard mass in the region of prostate infiltrating almost entire of rectum reaching extending almost up to the anal opening. His serum PSA was 223 ng/ml. CT scan abdomen showed a giant prostatic mass of more than 1000 ml volume, infiltrating the entire lower part of urinary bladder and the anterior wall of rectum (Fig 3, Panels A,B). There were no enlarged lymph nodes or involvement of any other intra-abdominal organs. Transrectal trucut biopsy of the mass was conclusive of adenocarcinoma of prostate Gleason's Grade 4+4=8. The whole body bone scan was negative for metastases. Bilateral surgical orchiectomy followed by brachytherapy was done. The patient is doing well on 1 year of follow up follow-up with reduction in PSA levels and size of primary tumour.

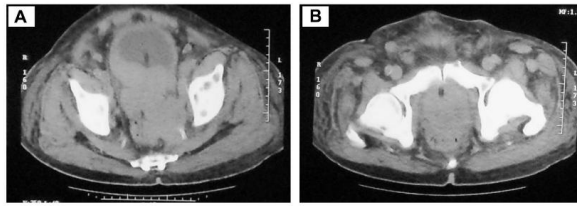


Figure 3. Panel A: Plain CT axial image showing giant prostate cancer infiltrating the anterior rectal wall

Panel B: Plain CT coronal image showing giant prostate cancer extending almost up to the anal verge

DISCUSSION

Prostate cancer arises from the peripheral zone of prostate gland and later involves all other zones and extends to the organs around. The staging of prostate cancer relies upon the extent of involvement of the gland, surrounding organs, lymph nodes and distant metastases. Although PC commonly metastasize to bone, lymph nodes, lungs, liver, adrenals and pelvic organs, rare metastatic spread to brain and breast has also been reported [3]. The diagnosis of early prostate cancer is based on the biopsy taken from the primary tumour when the patient presents with symptoms of urinary outflow obstruction or by assessing serum PSA levels, when the patient is asymptomatic. The treatment of primary PC is based on the local stage of the tumour.

Though BPE has been reported to present in massive sizes, there is paucity of literature on case reports of PC attaining very large sizes, without producing urinary symptoms or distant metastases. However, rarer forms of prostate cancer namely adeno-squamous carcinoma or neuroendocrine tumours which constitute only less than 1% of prostate malignancies, have been reported to rapidly spread locally in an aggressive manner and even leading to early metastases [4,5,6].

It is very difficult to manage primary giant prostate cancers, due to their large sizes which make them not amenable either to surgery or radiotherapy. The largest BPE managed by robotic surgery reported in literature has been weighing 560 gms [7]. In view of the technical difficulties, all three cases of giant prostate cancers in our series were managed by endocrine therapy with or without radiotherapy. Though one patient died of cardiac problem, the other two patients are doing well on follow up.

CONCLUSIONS

Asymptomatic giant prostate cancer with no distant metastases is a clinical enigma and management of this condition could vary with clinical situations. Systemic endocrine therapy would be the ideal primary treatment in these patients.

Comment [C.G.3]: Diagnosis is confirmed by prostate biopsy. Clinical and pathological staging determines whether the disease is early or late.

Comment [C.G.4]: Treatment is based on the stage of the disease.

PATIENT CONSENT

The patients have given necessary informed consent for analysis, reporting and medically publishing the images, as per the protocol of the treating institution. A copy of the written consent is available for review by the Editorial office/Chief Editor/Editorial Board members of this journal.

REFERENCES

1. Maliakal J, Mousa EE, Menon V. Giant Prostatic Hyperplasia: Fourth largest prostate reported in medical literature. *Sultan Qaboos Univ Med J* 2014;14:e253–e256
2. Wadstein T. The largest surgically removed hypertrophied prostate. *J Am Med Assoc* 1938;110:509.
3. Mandaliya H, Sung J, Hill J, Samali R, George M. Prostate Cancer: Cases of Rare Presentation and Rare Metastasis. *Case Rep Oncol.* 2015; 8 (3): 526–29. <https://doi.org/10.1159/000442045>
4. Azzi P, Bossé D, Cagiannos I, Borowy-Borowski P, Tiberi D. Primary Adenosquamous Carcinoma of the Prostate with Rectal Invasion. *Case Reports in Urology.* Volume 2022; Article ID 7613482: <https://doi.org/10.1155/2022/7613482>
5. Alane S, Moore A, Nutt M, Holland B, Dynda D, El-Zawahry A, et al. Contemporary Incidence and Mortality Rates of Neuroendocrine Prostate Cancer. *Anticancer Res.* 2015;35:4145–4150.
6. Basatac C, Sağlam S, Aktepe F, Akpınar H. Primary large cell prostate neuroendocrine carcinoma with central and nephrogenic diabetes insipidus. *Int Braz J Urol.* 2020; 46(5): 859–63. doi: 10.1590/S1677-5538.IBJU.2019.0180
7. Gupta SS, Martini A, Wagaskar VG, Tewari AK. Prostate cancer in a patient with giant prostatic hyperplasia: the robotic approach to a difficult problem. *J Endourol Case Rep.* 2019; 5(3): 99–101.