

Successful salvage of a mutilated hand injury in a developing country: A case report

Abstract

Mutilating hand injuries are rare in developed countries but it is not uncommon in developing countries. The ultimate goal of management is salvaging the injured hand with adequate functional status. Early radical debridement with intravenous antibiotics, good soft tissue handling and good rehabilitation is key to success for the management. We describe here a case of management of a mutilated hand injury in a resource constrained setting.

Introduction

The hand is a complicated structure made up of various tissues that are tightly packed in a short area (skin, nerves, blood vessels, tendons, bones joints, and intrinsic muscles)(1).

Injuries to the hands and wrists are one of the leading causes of functional disability worldwide. Hand injuries compose up to 30% of all injuries in emergency care(2).

Hand mutilation may be defined as injuries that cause severe damage to several tissues (3). It is sometimes impossible to salvage the elements necessary for proper hand function after the severe destruction of parts associated with mutilating injuries to the hand. The major goal of therapy is to restore circulation to the devitalized area, straighten the residual skeletal components, and restore skin cover to the denuded areas(3). The definitive treatment must be postponed until the survivability of the hand is confirmed. Complex surgeries are often required to turn the remaining part of the hand into a functioning unit(3).

The complex hand injuries is usually managed by hand surgeons with micro-surgical skills in developing country(4)A. However, it is handled by the general orthopaedic surgeons in Bhutan. There are no microscopes or special hand instruments for the management.

There are no established data about the prevalence of such injuries in Bhutan till date. Since, 80% of the population in the country is involved in agricultural activities, the incidence of such cases is on a rise. In this paper, we will describe a case of mutilated hand injuries.

Case Presentation

A 19 year old male, right hand dominant, got his left hand accidentally stuck into the grass cutter machine while trying to clear the debris. He was immediately taken to a local district hospital. The wound irrigation and dressing, tetanus toxoid injection, IV antibiotics, splinting and basic laboratory investigations were done from hospital there and referred to our hospital. Eastern Regional Hospital is one of the only regional referral center which foster orthopedic surgical services to six eastern districts in the country.

On reaching our center, patient's vitals were stable. Basic laboratory reports such as Complete blood count, viral markers, grouping and cross match were sent along with the x ray of hand.IV

fluid maintenance were started from hospital there with patient nil per mouth. Emergency Operation theatre activation was done. Detailed explanation of the injury and need for immediate debridement with exploration were discussed with patient and accompanying attendant. An informed written consent was taken. Injection Cefazolin 2g stat along injection Gentamycin 240mg stat and injection metronidazole were given at emergency room.

The foreign materials/debris were removed from the skin and soft tissues while washing. Radical debridement was done removing all the devitalized tissues and contaminations. Flexor tendons were exposed and tagged with sutures. Fractures of the bone were cleaned of debris and fixed with k wire. Ulnar artery was completely transected and was repaired along with the median nerve .With multiple carpal bone fractures and tendon injuries, a decision of applying external fixator was implemented, in order to protect the soft tissues, bones and tendons.

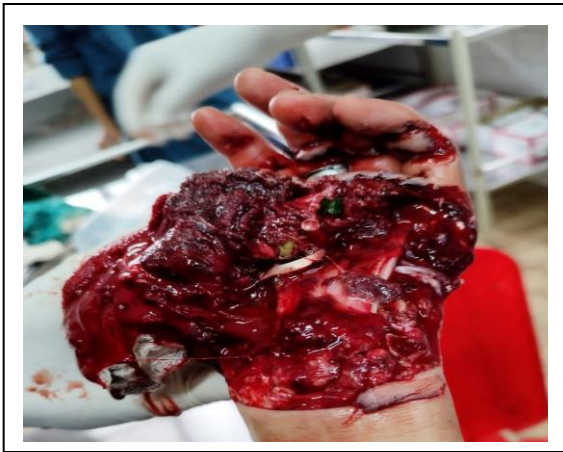

Fig 1. Shows extensive de gloving injury involving multiple flexor tendons, bones, nerves and vessels with high degree of contamination.

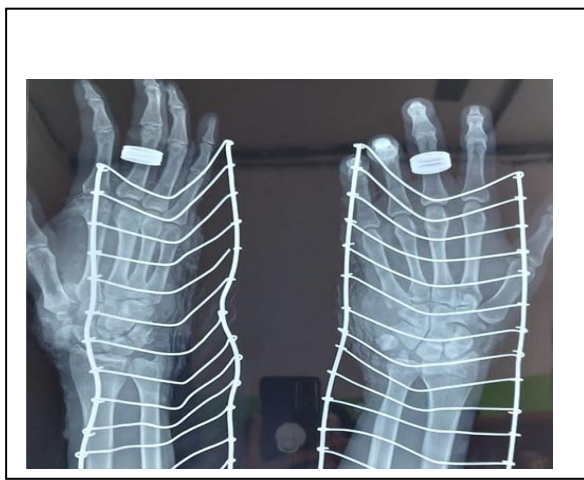


Fig 2: X rays shows the fracture of trapezium bone with subluxation of 1st carpometacarpal joint of left hand.

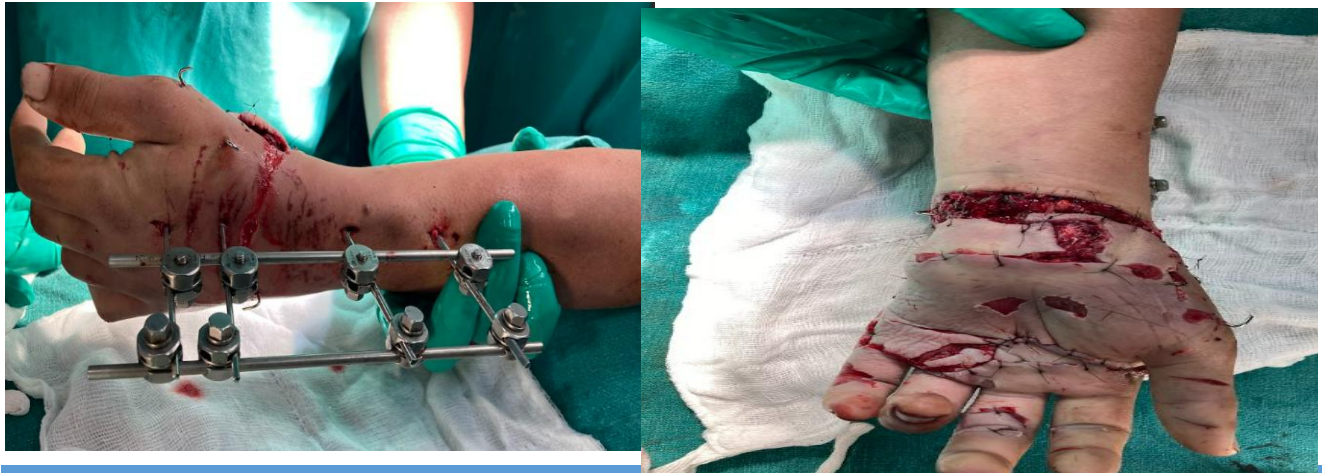

Fig 3: Immediate post-operative image showing loosely tagged skin sutures with external fixator

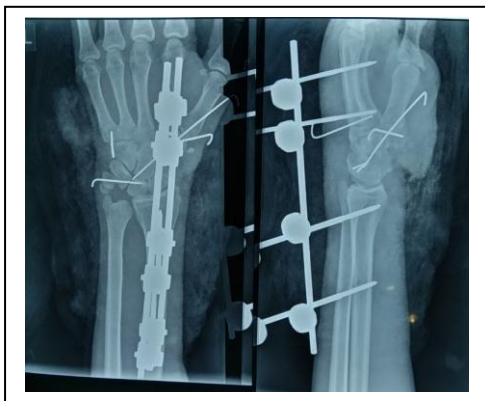

Fig 4: Post op x ray showing temporary fixation of 1st CMC joint with k wires and external fixator.

Second look surgery was done with wound debridement and closure after 72 hours and daily dressing of wound were done. Antibiotics were continued for 10 days and external fixator was removed on 10th post-operative day. Short arm splint was applied after removal of the external fixator. Passive range of motion were done by the physiotherapy team along with electrical stimulation of tissues for rapid healing. High protein diet were given to the patient for quick wound healing. Active range of motion were started at 4 weeks of surgery with intermittent hand splints.

Split thickness skin graft was done over the volar wrist at 3rd week postoperatively.

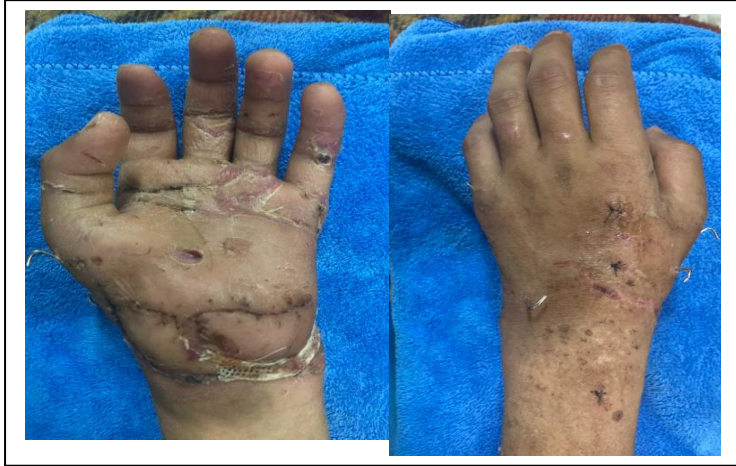

Fig 5: Wound status at 4 weeks

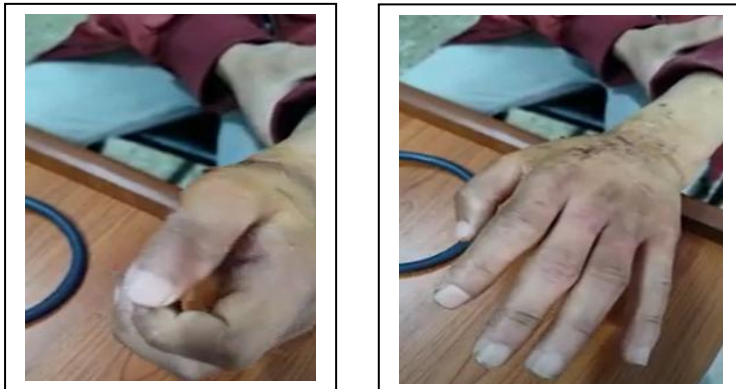

Fig 6: Functional status at 2 months

Discussion

Managing the mutilating injuries to the hands are very much complex. We have to balance between the time for wound healing and its predisposition for high degree of stiffness. The priority is much given to save the hand tissues as much as possible with good functional status. Most often, patients refuse for amputation even if it's beyond the possibility of salvaging. Good communication with patient and counseling are required to overcome such complex situations.

A holistic approach with debridement of wound, meticulous soft tissue handling and IV antibiotics along with optimizing nutritional status of patient is crucial to avoid early complications of wound infections and delayed wound healing. Multidisciplinary approach involving hand therapist, nutritionist and wound specialist nurses are required for the successful outcome(5). Early and aggressive physiotherapy is critical for swiftly regaining hand function and range of motion. It aids in the reduction of edema and hand stiffness following injury(6).

Conclusion

The successful outcome in this case was due to meticulous debridement with early physiotherapy which contributes to rapid recovery without hand stiffness. Wound dressing and antibiotics to prevent infections. Salvaging the hand with good function should be the goal with mutilated hand injury.

Ethical Approval:

As per international standards or university standards written ethical approval has been collected and preserved by the author(s).

Consent

As per international standards or university standards, patient(s) written consent has been collected and preserved by the author(s).

References:

1. Lahiri A. Guidelines for management of crush injuries of the hand. *J Clin Orthop Trauma*. 2020;11(4):517–22.
2. Moellhoff N, Throner V, Frank K, Benne A, Coenen M, Giunta RE, et al. Epidemiology of hand injuries that presented to a tertiary care facility in Germany: a study including 435 patients. *Arch Orthop Trauma Surg*. 2023;143(3):1715–24.
3. Midgley RD, Entin MA. Management of mutilating injuries of the hand. *Clin Plast Surg*. 1976;3(1):99–109.
4. Keller MM, Jordaan PW. Traumatic hand injury management and outcomes: A case report. *South Afr Fam Pract*. 2022;64(1):5479.

5. Lim JX, Le LAT, Yeh JZY, Boey JJJ, Rajaratnam V. The epidemiology and distribution of hand fractures in Singapore. *Singapore Med J.* 2023;
6. Agarwal R, Agarwal D, Agarwal M. Approach to mutilating hand injuries. *J Clin Orthop Trauma.* 2019;10(5):849–52.
7. Alphonsus CK. Principles in the management of a mangled hand. *Indian J Plast Surg Off Publ Assoc Plast Surg India.* 2011;44(2):219.
8. Del Pinal F. Severe mutilating injuries to the hand: guidelines for organizing the chaos. *J Plast Reconstr Aesthet Surg.* 2007;60(7):816–27.