

Diagnostic Value of Transcranial Ultrasound in Preterm Infants

Abstract

Background: Prematurity is a term refers to neonates born at < 37 weeks of gestation. Cranial ultrasound (CUS) and magnetic resonance imaging are the two primary imaging methods for predicting neurodevelopmental outcomes in the neonatal duration era.

Aim: To verify the role of transcranial ultrasound (TCUS) as a screening tool in preterm infants to assess various cerebral lesions.

Patients and Methods: This trial was performed on 150 preterm neonates delivered before 37 weeks of gestation. They underwent TCUS scan just after admission, after three and seven days.

Results: A significant variation was found among neonates with normal CUS findings and those with abnormal US findings regarding gestational weight. A significant variation was found among neonates with normal CUS findings and those with abnormal US findings in neonates with respiratory distress. A significant variation was found among preterm with normal CUS findings and those with abnormal US findings regarding the outcome of the studied neonates.

Conclusion: CUS remains the rapid, accurate imaging tool of choice in preterm neonates for detecting brain injuries.

Keywords: Transcranial Ultrasound, Preterm Infants, Haemorrhage, Hypoxic Ischaemic Injury.

Introduction:

Premature infants (neonates born at < 37 weeks' gestation) are at high risk for brain injury^[1]. Cranial ultrasound (CUS) can detect ischaemic and cystic brain lesions, intracranial haemorrhage, calcifications, cerebral oedema, cerebral infections, major structural abnormalities in critically ill neonates, and monitor the progress of hypoxic-ischaemic brain injury^[2].

Resistive index (RI) is an important parameter that should be measured in newborn infants. Power Doppler imaging can detect signs of ischaemia^[3].

The trial aimed to verify the role of trans-cranial ultrasound (TCUS) as a screening tool in preterm infants to assess various cerebral lesions.

Methods:

This prospective trial was performed on 150 preterm neonates delivered before 37 weeks of gestation, and referred to the Special Care Baby Unit at Local Teaching Hospital from November 2020 to November 2021 after obtaining institutional review board approval (Approval code: 34285/11/20) from our hospital and informed consent from the parents before the study. No sex predilection.

The neonates underwent TCUS scan just after admission, after three and seven days.

Exclusion criteria were infants whose parents did not give consent for the study.

Patients underwent the following:

Full clinical history taking; personal data such as patient's name, age, weight and sex, gestational age at time of labour, and mode of delivery (spontaneous, elective, or emergency caesarean section), history of any hereditary disease, history of maternal risk factors as PROM, multiple pregnancies, infections and using drugs during gestation, history of perinatal risk factors as birth asphyxia and neonatal sepsis, and neonate clinical presentation.

Patient preparation

The following antiseptic measures were taken:

The examiner's hands are washed with an antiseptic solution, and the probe of the ultrasound apparatus is properly disinfected. The examined infants were adequately covered to keep away from hypothermia, only the examined part was exposed (infant's head).

Examination technique

Transcranial grey scale Ultrasound for all preterm neonates utilizing (SONOSITE M-Turbo) using convex probe of 5-8 MH ultrasound machine.

As the principal acoustic window, the anterior fontanelle was utilized, and the scanning process included:

Six standard coronal planes through frontal lobes, occipital lobes, frontal horns of the lateral ventricles, body of the lateral ventricles, foramen of Monro and the third ventricle, and trigone of the lateral ventricle.

Five standard sagittal planes at midsagittal plane, right and left parasagittal planes through lateral ventricles, right and left parasagittal planes through insula.

Posterior fontanelle as well as the mastoid and temporal windows were additional windows that helped for viewing far sites such as brainstem, posterior fossa, fourth ventricle and basal cisterns.

Transcranial Doppler examination

Transcranial color-coded Doppler was used to evaluate vascular lesions in all neonates evaluated using a convex probe, by scanning through the AF to image flow in the circle of Willis in both sagittal and coronal scans. A linear probe through temporal approach was used for assessing the Middle cerebral artery (MCA) in its echogenic fissure in the axial plane. RI, which is the peak systolic flow velocity (PSV) minus end diastolic velocity (EDV) divided by PSV, was calculated for MCA. The overall mean RI of the major intracranial vessels

including internal carotid artery (ICA), anterior cerebral artery (ACA) and MCA in normal term newborns is above (0.7).

Statistical analysis

Statistical analysis was performed using SPSS v25 (IBM Inc., ARMONK, IL, USA). Qualitative variables were presented as frequency and percentage (%). Quantitative variables were presented as mean and standard deviation (SD) and were compared using paired Student's t- test for the same group. Mann-Whitney U test was utilized for comparing non-parametric quantitative variables, Chi-square (X^2) test was utilized for comparing proportions between two qualitative variables, Monte Carlo Exact test was utilized instead of Chi-square test in table more than two by two, especially with small samples, Spearman correlation was done between non-parametric variables. A two tailed P value < 0.05 was deemed significant.

Case presentation:

Case (1)

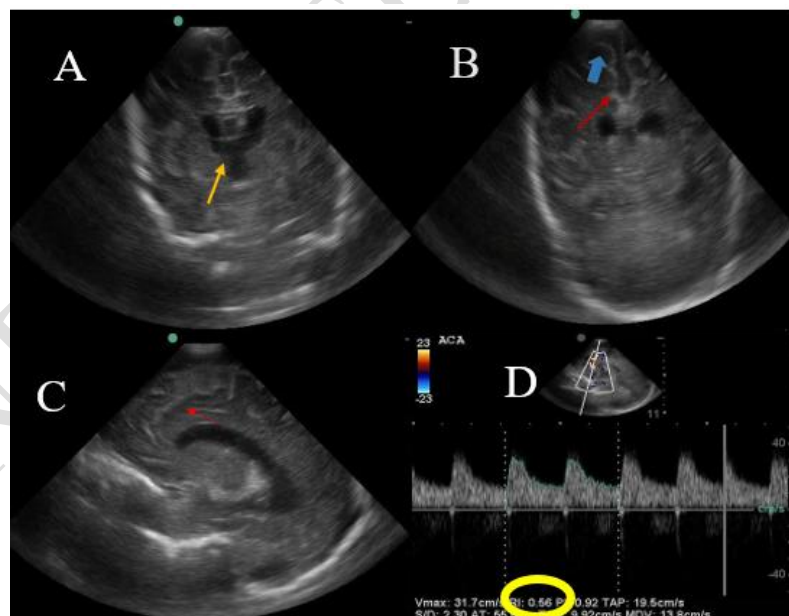


Figure (1): (A-D images): coronal scan through (A) thalami, and (B) foramen of Monro show enlarged subarachnoidal space (blue arrow head), widening interhemispheric fissure (red arrow), and prominent ventricles (yellow arrow). (C): sagittal scan through the caudothalamic groove shows reduced complexity of gyral fold (red arrow). (D): color Doppler image shows low RI of ACA (yellow circle)

A 36-week preterm neonate presented with hypotonia. TCUS examination was performed at day one. The case was diagnosed as brain atrophy. **Figure 1**

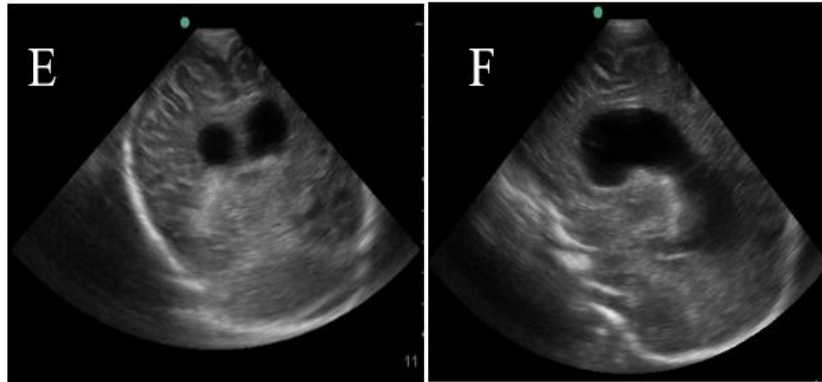


Figure (2): (E & F images): (E): coronal scan through quadrigeminal cistern, and (F): sagittal scan through the caudothalamic groove show increased widening of interhemispheric fissure, enlarged subarachnoid space and dilated ventricles.

Follow-up ultrasound examination was performed at third day of life and revealed progressive course of the previously mentioned findings. **Figure 2**

Case (2)

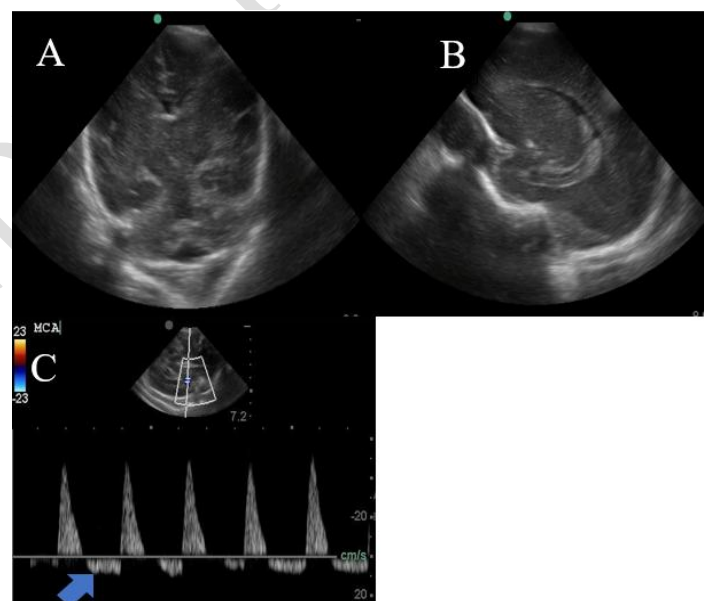


Figure (3): (A-C images): (A): coronal scan through the quadrigeminal cistern, and (B): sagittal scan through the body of lateral ventricle show normal ultrasound

findings. (C): color Doppler image shows high MCA RI (blue arrow head) denoting increase intracranial pressure.

A 27 weeks' preterm neonate presented with convulsions and hypotonia. TCUS examination was performed at day one. **Figure 3**

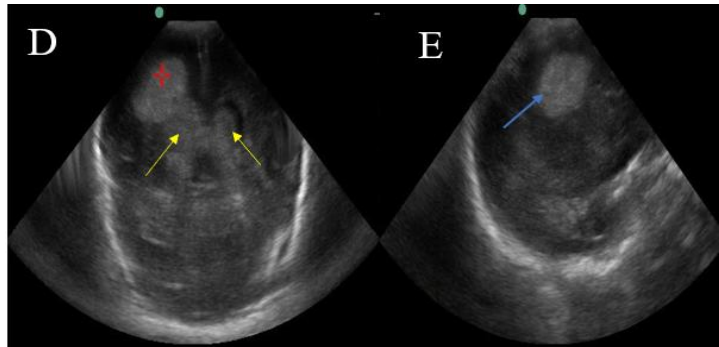


Figure (4): (D&E images): (D): coronal scan through trigones of the lateral ventricles shows bilateral prominent ventricle with echogenic material seen inside (yellow arrow) and right homogenous echogenic mass extended to the parenchyma at right side (red star), (E): sagittal scan through cerebral cortex shows the same right side echogenic mass (blue arrow).

Follow-up ultrasound examination was performed at third day of life and revealed newly developed intra ventricular haemorrhage with cerebral extension. The case was diagnosed as right grade IV and left grade III intraventricular haemorrhage (IVH), the baby died few days later. **Figure 4**

Results:

This prospective study included 150 preterm neonates born at gestational age ranging from 26 to 37 weeks with a mean age of 34 weeks.

One hundred and eighteen (78.6%) were moderate to late preterm of gestational age between 33 to 37 weeks, 28 (18.7%) were very preterm of gestational age from 28 weeks and less than 33 weeks and 4 (2.7%) were extreme preterm of gestational age less than 28 weeks. 91 (60.7%) were males and 59 (39.3%) were females. The gestational weight in the studied 150 neonates ranged from 1000 to 3100 gm with a mean weight of 2300 gm; 123 (82%) were of gestational weight more than 2000 gm and 27 (18%) were of gestational weight between 1000 to 2000 gm. 115 of the studied neonates (76.7%) were born with CS and 35 (23.3%)

were born with normal delivery. The most common perinatal risk factor for brain affection is neonatal seizures (NS) as found in 17 neonates (11.3%), followed by sepsis in eight neonates (5.3%), and birth asphyxia in five neonates representing (3.3%). **Table (1)**

Table (1): Demographic data of the studied neonates and Distribution of studied neonates according to perinatal risk factors (n=150)

Demographic data		Studied neonates
Gestational age (weeks)	Mean ± SD	34.2 ± 2.45
	Range	26 – 36
	Median (IQR)	35 (34 – 36)
Gestational age	Extreme preterm (< 28 weeks)	4 (2.7%)
	Very preterm (28<33 weeks)	28 (18.7%)
	Moderate to late (33-37 weeks)	118 (78.6%)
Sex	Male	91 (60.7%)
	Female	59 (39.3%)
Gestational weight	Mean ± SD	2303.3 ± 477.05
	Range	1000 – 3100
	Median (IQR)	2400 (2100 – 2600)
	1000-2000 gm	27 (18.0%)
	> 2000 gm	123 (82.0%)
Risk factors	Birth asphyxia	5 (3.3%)
	Sepsis	8 (5.3%)
	Neonatal seizures	17 (11.3%)
	IUGR	1 (0.7%)
	Obstructed labour	3 (2.0%)
	Meconium aspiration	3 (2.0%)

Data is presented as mean ± SD, range, median (IQR), or number (%). IUGR: Intrauterine growth restriction.

According to the clinical presentation of the studied neonates, 82 (54.7%) presented with RD; 52 presented with respiratory distress (RD) II and 30 presented with RD III. 37 (24.7%) presented with jaundice. After TCUS examination of all studied neonates, 106 neonates (70.7%) had normal US findings and 44 neonates (29.3%) had abnormal US findings; 16

(10.7%) had hypoxic ischaemic injury, 13 (8.7%) had haemorrhage, and eight (5.3%) had hydrocephalus.

A significant difference was found among neonates with normal CUS findings and those with abnormal US findings regarding gestational weight; however, there was insignificant difference regarding gestational age, gender and mode of delivery. **Table (2)**

Table (2): Association of CUS findings and abnormalities, and basic data, perinatal risk factors, respiratory distress and other clinical data in the studied neonates (n=150)

		Normal	Abnormal	Test	P value
Gestational age (weeks)	Mean \pm SD	34.2 \pm 2.47	34.1 \pm 2.43	U= 2252.5	0.732 NS
	Range	26 – 36	27 - 36		
	Median (IQR)	35 (34 – 36)	35 (33 – 36)		
Gestational age: N (%)	Extreme preterm (n = 4)	3 (2.8%)	1 (2.2%)	MC= 0.158	0.920 NS
	Very preterm (n=28)	19 (17.9%)	9 (20.5%)		
	Moderate to late (n=118)	84 (79.3%)	34 (77.3%)		
Gestational weight (gm)	Mean \pm SD	2385.9 \pm 413.22	2104.6 \pm 560.71	U= 1677.0	0.007* S
	Range	1000-3100	1100-3000		
	Median (IQR)	2400 (2175-2700)	2200 (1800-2500)		
Gestational weight	1000-2000 gm	11 (10.4%)	16 (36.4%)	χ^2 = 14.226	<0.001* HS
	>2000 gm	95 (89.6%)	28 (63.6%)		
Sex	Male (n=91)	64 (60.4%)	27 (61.4%)	χ^2 = 0.013	0.910 NS
	Female (n=59)	42 (39.6%)	17 (38.6%)		
Mode of delivery	Normal	29 (27.4%)	6 (13.6%)	χ^2 = 3.273	0.070 NS
	CS	77 (72.6%)	38 (86.4%)		
Perinatal risk factors	Birth asphyxia	4 (15.4%)	1 (9.1%)	MC= 4.110	0.597 NS
	Sepsis	5 (19.2%)	3 (27.3%)		
	Neonatal seizures	12 (46.2%)	5 (45.5%)		
	IUGR	1 (3.8%)	0 (0.0%)		
	Obstructed labor	1 (3.8%)	2 (18.1%)		
	Meconium aspiration	3 (11.6%)	0 (0.0%)		
Respiratory distress	RD II	44 (72.1%)	8 (38.1%)	MC= 7.8	0.005* S
	RD III	17 (27.9%)	13 (61.9%)		
Clinical data	Jaundice	31 (72.1%)	6 (42.9%)	MC= 0.186	

	Poor suckling	3 (7.0%)	2 (14.3%)	7.202	NS
	Hypotonia	4 (9.3%)	4 (28.6%)		
	DCL	3 (7.0%)	0 (0.0%)		
	Metabolic disorder	1 (2.3%)	1 (7.1%)		
	Coma	1 (2.3%)	1 (7.1%)		

U: Mann Whitney test, χ^2 : (Chi square test). MC: (Monte Carlo Exact test). P- value: probability. *: significant p value (< 0.05). NS: P-value > 0.05 is not significant. S: P-value < 0.05 is significant. HS: P-value < 0.001 is highly significant. CS: Caesarian section, IUGR: Intrauterine growth restriction, RD: Respiratory distress.

There was insignificant difference among neonates with normal CUS findings and those with abnormal US findings regarding the perinatal risk factors. A significant difference was found among neonates with normal CUS findings and those with abnormal US findings in neonates with respiratory distress, however there was insignificant difference in neonates with other clinical presentations. **Table (2)**

According to haemorrhage, it was restricted to germinal matrix (grade I) in nine neonates (69.2%), extending into intra ventricular regions (grade II) in one neonate (7.7%), associated with dilated ventricles (grade III) in two neonates (15.4%) and associated with intra parenchymal haemorrhage (grade IV) in one neonate (7.7%). After Doppler examination of the studied neonates, 130 (86.7%) showed normal ACA and MCA RI, 18 (12%) showed low ACA or MCA RI, and two (1.3 %) showed high ACA or MCA RI.

By the third day follow up of the studied neonates by ultrasound, 102 (68%) were normal, while 33 neonates (22%) showed stationary course of abnormal ultrasound findings, six neonates (4%) showed progressive course of abnormal ultrasound findings. By seventh day follow up of the studied neonates by ultrasound, 100 (66.7%) were normal, while 33 neonates (22%) showed stationary course of abnormal ultrasound findings, eight neonates (5.3%) showed progressive course of abnormal ultrasound findings. According to the neonates with progressive course, two neonates showed newly developed sub ependymal haemorrhage (grade I), one neonate showed newly developed sub ependymal haemorrhage (grade I) and

low ACA RI by Doppler examination (early hypoxic ischaemic injury), one neonate showed progressive course of right grade IV and left grade III intra cranial haemorrhage with inverted diastolic component of ACA, one neonate showed progressive course of turbid hydrocephalus with internal septations, one neonate showed progressive course of reduced brain volume, and two neonates showed progressive course of hydrocephalus and reduced brain volume. **Table (3)**

Table (3): Third day US follow-up of the studied neonates (n=141)

		Neonates
Follow-up US findings at third day	Normal	102 (68%)
	Stationary course	33 (22.0%)
	Progressive course	6 (4%)
Follow-up US findings at seventh day	Normal	100 (66.7%)
	Stationary course	33 (22.0%)
	Progressive course	8 (5.3%)

Data is presented as number (%).

There was significant difference among preterm with normal CUS findings and those with abnormal findings regarding the outcome of the studied neonates. **Table (4)**

Table (4): Association of CUS abnormalities and outcome in the studied neonates (n=150)

Neonates' outcome	Normal No.=106	Abnormal No.=44	MC	P value
Normal follow up US findings	99 (93.4%)	1 (2.2%)	125.458	<0.001* HS
Stationary course of abnormal US findings	0 (0.0%)	33 (75.0%)		
Progressive course of abnormal US findings	3 (2.8%)	5 (11.4%)		
Died	4 (3.8%)	5 (11.4%)		

Data is presented as number (%), MC: Monte Carlo Exact test. HS: highly significant P-value<0.001.

By Spearman correlation test, there was weak correlation between CUS abnormal findings with gender, gestational age, gestational weight, mode of delivery, perinatal risk factors and clinical presentations, otherwise there was strong correlation between CUS abnormal findings with the outcome of the studied neonates. **Table (5)**

Table (5): Correlation between CUS abnormal findings and different parameters in the studied neonates (n=150)

Variables	CUS	
	r_s	P
Sex	- 0.009	0.911
Age at birth (weeks)	- 0.028	0.733
Gestational weight (gm)	-0.222	0.006*
Mode of delivery	0.148	0.071
Perinatal risk factors	- 0.009	0.959
Respiratory distress	0.308	0.005*
Other clinical data	0.248	0.063
Outcome	0.746	<0.001*

r_s (Spearman correlation). 0.0 - < 0.4 (Weak correlation). 0.4 - < 0.7 (Moderate correlation). 0.7 - 1 (Strong correlation). *P value < 0.05 (Statistically significant), < 0.001 (Highly significant).

Discussion:

CUS is regarded as the easily repeated and most accessible method for imaging the newborn brain in both preterm and full-term neonates. It is a well-established diagnostic method utilized for evaluating intracranial anatomy and pathology in neonates including Intracerebral haemorrhage (ICH), SEH, PVL, cerebral oedema and cysts^[4, 5].

Serial neurosonography was performed in the high-risk premature neonate in neonatal intensive care unit (NICU) as there is generally poor concordance between clinical status and intracranial pathology^[5].

There are limited number published research assessing the necessity for cerebral ultrasonography in newborns delivered late or relatively prematurely.^[6]

Meijler^[7] stated that CUS should be conducted in all neonates admitted to a neonatal unit. According to De Vries, et al.^[8], magnetic resonance imaging (MRI) and neurosonogram are complementary modalities. In the early days, CUS was considered a useful modality especially when the neonate is unstable for transport, and its findings were considered adequate for major clinical decisions.

In a trial comparing between MRI and TCUS, Genedi, et al. ^[9] reported that TCUS detected 100% of germinal matrix haemorrhage lesions.

Regarding gestational age of preterm neonates in this study, 2.7% of them were extreme preterm neonates below 28 weeks, 18.7% of them were very preterm neonates from 28 and less than 33 weeks and 78.6% of them were moderate to late preterm neonates from 33 to 37 weeks.

In Ballardini, et al. ^[10] trial, all the studied neonates were of gestational age between 33 and 36 weeks, while in the study of Nazparveen, et al. ^[11], there were 21.52% of the studied neonates of gestational age less than 32 weeks and 78.75% of them of gestational age more than 32 weeks.

Regarding gestational weight of this study, 18% of the studied neonates were of gestational weight < two kg and 82% of them were of gestational weight > two Kg. In the study of Nazparveen, et al. ^[11], there were 56.25% of studied neonates weighed < two kg and 43.75% weighed > two kg.

In the current trial, the most common perinatal risk factor for brain affection was NS at 11.3%, followed by sepsis at 5.3%, and then birth asphyxia at 3.3% of the studied neonates. This came in agreement with a trial by Shehata, et al. ^[12] in which the most common risk factor reported among the studied newborns was NS (12.2%), followed by sepsis (6%) and then birth asphyxia among 3% of studied neonates.

In this study, the most common clinical data was RD II at 34.7% of the studied neonates, followed by jaundice at 24.7% of them, and then RD III at 20% of them. This matches with the study of Shehata, et al. ^[12] in which the most common clinical finding was RD II (32.7%), followed by jaundice (22.4%) and then RD III (18.8%) of the studied neonates.

In the present study, 28.8 % of moderate to late preterm neonates (between 33-36 weeks of gestational age) had positive CUS. This came in agreement with Ballardini, et al. ^[10] trial, in

which 30% of the neonates (between 33-36 weeks of gestational age) had positive CUS that would have been overlooked if screening was confined to neonates under the gestational age of 32 weeks.

The current study showed 29.3% of the studied neonates with abnormal ultrasound findings. This matches with the studies published by Prithviraj, et al. ^[13] with 36%, Nazparveen, et al. ^[11] with 28.75%, Jha, et al. ^[14] with 25.4%, Nagaraj, et al. ^[15] with 38% and Shehata, et al. ^[12] with 30.9% of the studied neonates with abnormal ultrasound findings.

Otherwise in the study of Ahmed, et al. ^[6], there were 75% of the studied neonates with abnormal US findings, in the study of Rupprecht ^[16], there were 47% of the studied neonates with abnormal ultrasound findings.

The most common CUS abnormality reported in this trial was hypoxic ischaemic injury at 10.7%, followed by haemorrhage at 8.7% of the studied neonates. This matches with the trial by Jha, et al. ^[14] which revealed that the most common ultrasound abnormality was hypoxic ischaemic injury at 10.6%, followed by haemorrhage at 8% of the studied neonates, the trial by Ahmed, et al. ^[6] which revealed that the most common ultrasound abnormality was hypoxic ischaemic injury at 25%, followed by haemorrhage at 15% of the studied neonates.

Otherwise, according to the study of Ziaul et al. ^[17], the most common CUS abnormality was cerebral edema at 21.4% of neonates with abnormal US findings, followed by IVH at 16.5% and then ventricular dilatation at 7.8%. In other research by Prithviraj, et al. ^[13], Shehata, et al. ^[12] and Kinikar et al. ^[18], the most common CUS abnormality was ICH at 43%, 47% and 40.4% of neonates with abnormal US findings accordingly.

While in the study of Nazparveen, et al. ^[11], the most common CUS abnormalities were cerebral oedema and IVH with 30.43% of neonates with abnormal US findings each.

According to grading of haemorrhage at the present study, the most noted subtype was grade I subependymal haemorrhage at 69.2% of neonates with ICH, followed by grade III IVH with

ventricular dilatation at 15.4%, then grade II IVH and grade IV IVH with intra parenchymal haemorrhage at 7.7% each. This agrees with Ahmed, et al. ^[6], and Ballardini, et al. ^[10] trials, they showed that grade I IVH is the most common type of IVH at 50% and 60% of neonates with ICH accordingly.

The current study showed significant relationship between abnormal US findings and gestational weight. This matched Jha, et al. ^[14] and Kinikar, et al. ^[18] trials, however it didn't agree with Ballardini, et al. ^[10] trial, that showed there was no relationship between abnormal US findings and gestational weight.

In the present study, among neonates with abnormal ultrasound findings, there were 2.2% of extreme preterm, 20.5 % of very preterm and 37.3% of moderate to late preterm. This study showed insignificant relationship between abnormal US findings and gestational age, in contrast with Jha, et al. ^[14] and Kinikar, et al. ^[18] trials that showed a significant relationship between abnormal US findings and gestational age.

Malloy ^[19] research mentioned an increased risk for neonatal morbidity and mortality among neonates delivered by caesarean section compared to vaginal delivery when delivered at 32 to 36 weeks gestation.

The current study showed no significant association between abnormal CUS and the mode of delivery. This agreed with Ballardini, et al. ^[10] trial, however, it was in contrast with Ahmed, et al. ^[6] trial which revealed significant association between abnormal CUS and mode of delivery.

Ballardini, et al. ^[10] reported that the presence of at least one risk factor increased the probability of CUS abnormalities of 4.76 times.

In this study, there was insignificant association between abnormal US findings and perinatal risk factors. This result was against Jha, et al. ^[14] and Kinikar, et al. ^[18] trials, who reported a significant relation between abnormal CUS and birth asphyxia. Another study conducted by

Prithviraj, et al. ^[13] revealed that presence of significant relation between CUS abnormalities and PIH only, but no significant relation with other perinatal risk factors.

In the current research, a significant association was found between abnormal CUS and respiratory distress (specially grade II and III), otherwise there was insignificant difference in neonates with other clinical presentations. This matches with the studies of Fumagalli, et al. ^[20] and Kinikar, et al. ^[18] that also revealed a significant relation between abnormal ultrasound findings and respiratory distress.

Additional Doppler scan in this study showed no abnormality at 86.7%, low RI of anterior or middle cerebral arteries at 12% and high RI of anterior or middle cerebral arteries at 1.3%. While in the study of Ahmed, et al. ^[6], there were 65% of studied neonates with no abnormality, 15% with low RI and 20% with high RI of ACA.

In the current study, neonatal mortality was 6% of the studied neonates, while in the study of Diwakar, et al. ^[21] neonatal mortality was 16% of the studied neonates, and in the study of Kinikar, et al. ^[18], neonatal mortality was 36.1% of the studied neonates.

According to this trial, a significant relationship was found between abnormal CUS findings and the outcome of the studied neonates, while the study by Prithviraj, et al. ^[13] reported no significant relationship between abnormal CUS findings and the outcome of the studied neonates.

Limitations: Relatively small size in extreme and very preterm neonates and short follow-up duration due to early discharge from NICU or mortality; these neonates requires necessary follow-up to assess the neurological outcome of neonates with both normal and abnormal CUS findings.

Conclusions: CUS remains the rapid, accurate imaging tool of choice in preterm neonates for detecting brain injuries. It is a crucial investigatory tool in NICU and effectively documents brain damage morphology, allows for early intervention and treatment and may improve

clinical outcome. It has proven diagnostic value in detecting the most prevalent brain lesions in premature newborns; such as white matter disease and those due to IVH. We recommend screening for all preterm neonates by TCUS.

Ethical Approval:

As per international standard or university standard written ethical approval has been collected and preserved by the author(s).

Consent

As per international standard or university standard, patient(s) written consent has been collected and preserved by the author(s).

References:

1. Austin T, O'Reilly H. Advances in imaging the neonatal brain. *Expert Opin Med Diagn.* 2011;5:95-107.
2. Mercuri E, Ricci D, Cowan FM, Lessing D, Frisone MF, Haataja L, et al. Head growth in infants with hypoxic-ischemic encephalopathy: correlation with neonatal magnetic resonance imaging. *Pediatrics.* 2000;106:235-43.
3. Epelman M, Daneman A, Kellenberger CJ, Aziz A, Konen O, Moineddin R, et al. Neonatal encephalopathy: a prospective comparison of head US and MRI. *Pediatr Radiol.* 2010;40:1640-50.
4. Leijser LM, de Vries LS, Cowan FM. Using cerebral ultrasound effectively in the newborn infant. *Early Hum Dev.* 2006;82:827-35.
5. Pryds O. Control of cerebral circulation in the high-risk neonate. *Ann Neurol.* 1991;30:321-9.
6. Ahmed SH, Mohamed S, Soliman MMA. Accuracy of transcranial ultrasound and color duplex in diagnosis of neonatal brain pathologies. *EJMR.* 2020;1:65-78.

7. Meijler VG BA, Leijser LM. Timing of ultrasound examination. In: G M, editor. Neonatal Cranial Ultrasonography Guidelines for the Procedure and Atlas of Normal Ultrasound Anatomy. 5. 2 ed: Springer-Verlag Heidelberg; 2012. p. 57-73.
8. de Vries LS, Groenendaal F. Neuroimaging in the preterm infant. Ment Retard Dev Disabil Res Rev. 2002;8:273-80.
9. Genedi EAS, Osman NM, El-deeb MT. Magnetic resonance imaging versus transcranial ultrasound in early identification of cerebral injuries in neonatal encephalopathy. Egypt J Radiol Nucl Med. 2016;47:297-304.
10. Ballardini E, Tarocco A, Baldan A, Antoniazzi E, Garani G, Borgna-Pignatti C. Universal cranial ultrasound screening in preterm infants with gestational age 33-36 weeks. A retrospective analysis of 724 newborns. Pediatr Neurol. 2014;51:790-4.
11. Nazparveen L, Phirke DS. Cranial ultrasound in critically ill neonates. J Med Res. 2017;3:290-3.
12. Shehata S, Taema M, Omar Gamal Abdelaziz TAE, Abd El-Halim SA, Mohammed A. Study of cranial ultrasound findings in preterm infants admitted to neonatal intensive care unit and correlation with perinatal risk factors. Turk J Physiother Rehabil.32:3-14.
13. Prithviraj D, Reddy B, Reddy R, Shruthi B. Neurosonogram in critically ill neonates in neonatal intensive care unit. Int J Sci Stud. 2016;4:124-28.
14. Jha R, Singh A, Jha R. Cranial ultrasound in high risk preterm. New Indian Journal of Pediatrics. 2017;6:26-32.
15. Nagaraj N, Berwal PK, Srinivas A, Sehra R, Swami S, Jeevaji P, et al. A study of neurosonogram abnormalities, clinical correlation with neurosonogram findings, and immediate outcome of high-risk neonates in Neonatal Intensive Care Unit. J Pediatr Neurosci. 2016;11:200-5.

16. Deeg K-H, Rupprecht T, Hofbeck M, Rupprecht T. Transcranial Colour Doppler Sonography (TCDI). *Doppler Sonography in Infancy and Childhood*. 2015:195-227.
17. Ziaul IMM, Atiqul M, Islam MA, Hossain MM, Khan NZ. Cranial ultrasound in preterm neonates: screening of at risk infants for long term neurodevelopmental impairments. *J Enam Med Coll*. 2016;6:28-32.
18. Kinikar U, Dhanawade S. Study of cranial ultrasound its correlation with perinatal risk factors and its outcome in preterm neonates admitted to Neonatal intensive care unit. *Int J Pediatr Res*. 2018;5:169-74.
19. Malloy MH. Impact of cesarean section on intermediate and late preterm births: United States, 2000-2003. *Birth*. 2009;36:26-33.
20. Fumagalli M, Ramenghi LA, De Carli A, Bassi L, Farè P, Dessimone F, et al. Cranial ultrasound findings in late preterm infants and correlation with perinatal risk factors. *Ital J Pediatr*. 2015;41:65-70.
21. Diwakar RK, Khurana O. Cranial Sonography in Preterm Infants with Short Review of Literature. *J Pediatr Neurosci*. 2018;13:141-9.