

Case study

A RARE ASSOCIATION BETWEEN AN ULCERATIVE COLITIS AND NUT CRACKER SYNDROME

Abstract:

The nutcracker syndrome is a clinico-radiological entity that can be the cause of atypical pain. Long described by urologists and nephrologists, it encompasses all manifestations associated with venous stasis induced by stricture of the left renal vein: either between the aorta and the superior mesenteric artery, or between the aorta and the spine. The discovery of this syndrome during inflammatory bowel disease is an uncommon cause of abdominal pain. We report the case of a 21-year-old female patient whose aetiological investigation of diarrhea and abdominal pain revealed haemorrhagicrectocolitis and the discovery of a nutcracker syndrome on radiological examination. This case highlights the importance of investigating other causes of abdominal pain in inflammatory bowel disease.

Key words: nutcracker syndrome, ulcerative colitis, abdominal scanner

INTRODUCTION:

Nutcracker syndrome is a rare entity with variable clinical presentation, the diagnostic confirmation of which is based on radiological description. It is defined by compression of the left renal vein (LRV) generally in the fork formed by the abdominal aorta and the superior mesenteric artery (SMA) leading to stenosis of the aorto-mesenteric portion of the left renal vein and dilatation of its distal portion (1).

Therapeutic management requires a collegial decision involving the clinical practitioner, the visceral surgeon and the radiologist.

We report a rare association of this syndrome with IBD.

Is it an epiphenomenon or an established nosological entity?

PRESENTATION OF CASE:

The patient was 21 years old, with no previous history of any particular complaint. She was admitted with acute bloody diarrhea and a rectal syndrome associated with periumbilical pain, left pelvic pain and low back pain. Clinical examination revealed a lean patient with a BMI of 13, with hypogastric tenderness.

Comment [R-1]: HOW MANY CASES REPORTED IN LITERATURE TILL DATE?

Comment [R-2]: ANSWER TO THIS QUESTION HAS NOT BEEN GIVEN IN CONCLUSION

Biological examination revealed an inflammatory syndrome with hyperleukocytosis and microscopic haematuria. Endoscopic examination showed an ulcerated pancolitis that progressed in one piece, suggesting hemorrhagic rectocolitis.

Abdominal CT showed narrowing of the mesoaortic angle to 8.7°, responsible for dilatation of the left renal vein, gonadal vein and homolateral pelvic veins, associated with a fusiform left latero-uterine formation and an oval formation in the right ovary, as well as a left retroperitoneal incidentalloma possibly related to an adrenal cyst, as well as grade II sacroiliitis.

DISCUSSION:

Nutcracker syndrome is a rare entity, the first case of which was described in 1937 by the pathologist GRANT (2).

It can occur at any age from childhood to 70, with peaks before the age of 10 and between the ages of 20 and 30 (3), as in the case of our patient. It is also predominantly female. The female predominance of nutcracker syndrome in adults could be explained by the fact that pregnancy-related venous overpressure can alter the valves of the gonadal veins (4).

Anatomically, nutcracker syndrome can present in 3 types: anterior, posterior and mixed (5). Anterior nutcracker syndrome is the most common and corresponds to compression of the left renal vein, located by the aorta and AMS. The posterior variant involves the retro-aortic left renal vein in a small space between the abdominal aorta and the vertebral column (6).

Certain factors have also been incriminated in the occurrence of this syndrome, in particular anatomical variations of the kidney (ectopic kidney, horseshoe shape, renal duplicity), constitutional thinness or weight loss, hyper lordosis or any situation of overload and hyper pressure of the venous network may contribute to the increase or appearance of signs (7). This was the case for our patient, who was thin with a BMI of 13. No correlation between UC and nutcracker syndrome has been reported in the literature, although this may be circumstantial, as in the case of our patient, favoured by her weight loss.

However, other etiologies of extrinsic compression of the renal vein can induce secondary nutcrackers, including pancreatic cancer, retroperitoneal tumours and para-aortic adenopathies (8).

This syndrome is more often described by urologists and nephrologists because of its impact on the renal vein and its manifestations in relation to the urinary system. In the first instance, microscopic or even macroscopic haematuria has been described, as in the case of our patient in whom the examination found microscopic haematuria. It can also present with abdominal or left flank pain of a heavy, non-specific nature, which can be confused with a multitude of digestive pathologies. Our patient also reported abdominal pain in her left flank, as well as low back pain which was attributed to her hyper lordosis.

Nutcracker syndrome is diagnosed radiologically. Renal Doppler ultrasound is one of the diagnostic methods, with good sensitivity, but requires a certain amount of experience on the part of the operator.

The injected CT scan also provides a good characterisation of this compression of the RVG and of the nutcracker syndrome, describing the haemodynamic consequences, i.e. dilatation of the renal and gonadal veins, as well as pelvic varicose veins. The pathognomonic sign described on CT is the beak sign on sagittal slices, which corresponds to compression of the RVG in the aorto-mesenteric fork. The normal angle between the aorta and the AMS is 35-50°. When this angle is between 7° and 22°, compression occurs. The distance between the AMS and the aorta is reduced and measures 2-8 mm for a normal of 10 to 28 mm (9).

MRI also offers the same diagnostic contrast as CT, but this time with the added advantage of being less irradiating.

However, lumbar phlebography remains the gold standard, although it is still an invasive test and is used for therapeutic rather than diagnostic purposes. Lumbar phlebography measures the pressure gradient between the left renal vein and the IVC; in the case of a nutcracker, this pressure is 1mm or more (8). In our patient, the CT scan was the key element in establishing our diagnosis; the beak was measured at 8°.

To date, there is no consensus on the management of nutcracker syndrome. Therapeutic abstention seems to be the most commonly adopted approach, given the low impact of compression of the renal artery compared with the possible therapeutic morbidity, especially as regression of this syndrome has been noted in some patients (children, weight regain in the case of anorexia). However, in case of severe nutcracker syndrome, renal vein thrombosis, chronic glomerulopathy or permanent dilatation of the gonadal vein may occur (10). Another complication in women, although rare, is

persistent genital arousal syndrome due to severe pelvic stasis, which is often a source of stress and can even lead to suicide (7). Interventional surgery and radiology are reserved for severe symptomatic cases. Nephropexy and renal auto-transplantation with reimplantation of the renal vein are practised less and less, and nephrectomy a fortiori. More recently, the laparoscopic placement of extravascular stents around the renal vein has developed, particularly via retroperitoneal routes. Migration of extravascular stents can be corrected by endovascular stenting (7). In our patient's case, after consultation, it was decided to withhold treatment and to have her case monitored by the vascular surgeons.

CONCLUSION:

Nutcracker syndrome is a fairly rare phenomenon in common practice associated with UC, however there is no direct link between the two. This case illustrates the importance of considering other explanations for abdominal pain apart from complications associated with underlying IBD.

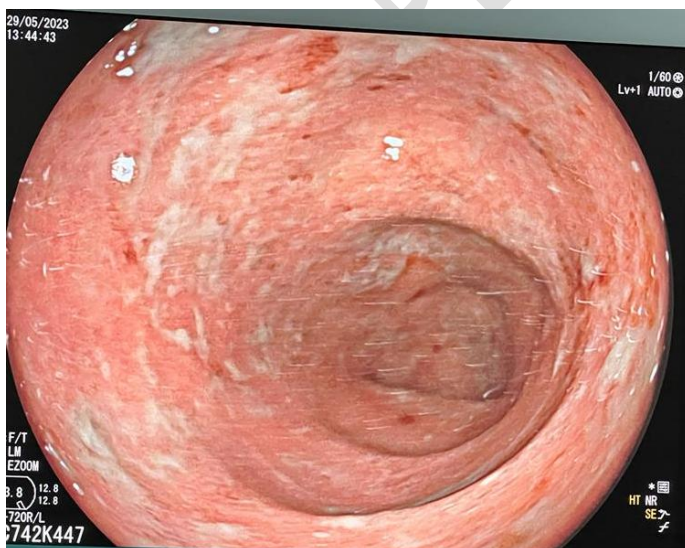


Figure 1: Exulceratedulcerativecolitis

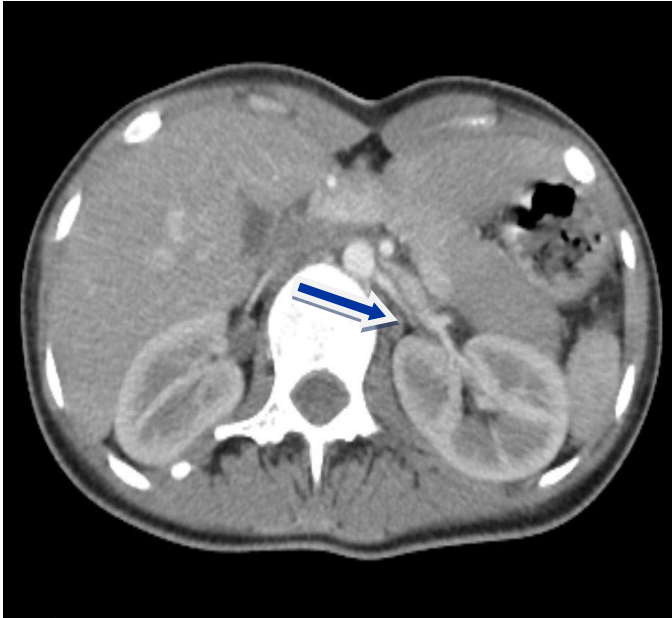

Figure 2: Abdominal CT scan after injection in axial section
Reduction in the calibre of the interaortic mesenteric passage

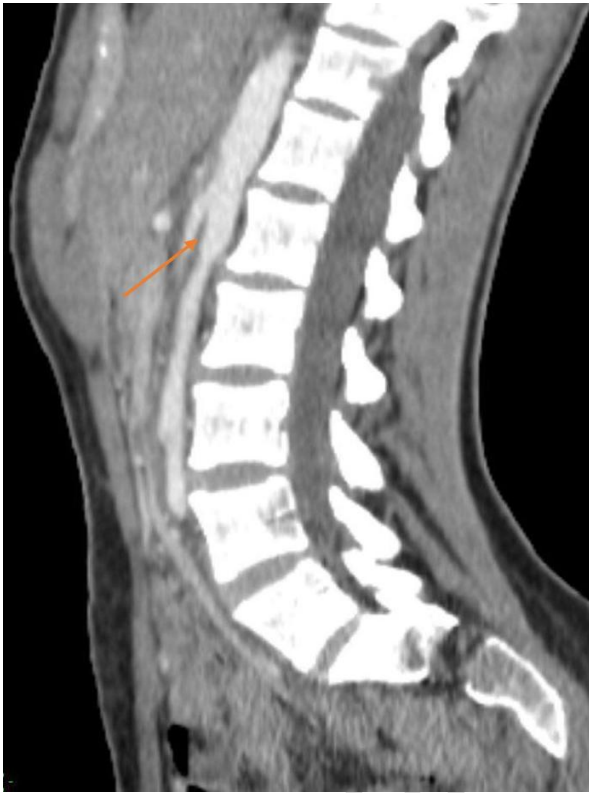

Figure 3: Sagittal section of abdominal CT scan with PDC injection showing pinching of the superior mesenteric aorta-arterial angle.

REFERENCES

1. Takezawa K, Nakazawa S, Yoneda S, Tanigawa G, Fujita K, Okumi M et al. Renal autotransplantation for the treatment of nutcracker phenomenon which caused varicocele rupture : a case report. *Hinyokika Kyo*. 2011 ; 57(4) : 213-6. Pubmed| Google Scholar
2. Karima K, Ernest B, Sofia J, Fatima Zahra Fdili A, Hekmat C, Moulay Abdelilah M. Nutcracker syndrome of incidental finding: About 2 cases. *Int J Med Rev Case Rep* 2020;4:28. doi:10.5455/IJMRCR.syndrome-nutcracker

3. Rudloff U, Holmes RJ, Prem JT, et al. Meso-aortic compression of the left renal vein (nutcracker syndrome): case reports and review of the literature. *Ann Vasc Surg* 2006;20:120–9
4. Yih ND, Chen LH, Cunli Y, et al. Renosplenic shunting in the nutcracker phenomenon: a discussion and paradigm shift in options? A novel approach to treating nutcracker syndrome. *Int J Angiol* 2014;23:71–6.
5. Orczyk k, wysiadecki g, majos a, stefañczyk I, topol m, polguy m. What each clinical anatomist has to know about left renal vein entrapment syndrome (nutcracker syndrome): a review of the most important findings. *Biomedresint*. 2017;2017:1746570. [[article](#) [PMC gratuit](#)] [[PubMed](#)] [[google scholar](#)]
6. Menard MT. Nutcracker syndrome: when should it be treated and how. *Perspect Vasc Surg Endovasc Ther*. 2009;21(2):117–24. [[PubMed](#)] [[Google Scholar](#)]
7. Jean-Marie Berthelot, Frédéric Douane, Yves Maugarsa, Eric Frampas
nutcracker syndrome : a rare cause of left flank pain that can also manifest as unexplained pelvic pain
Doi : 10.1016/j.rhum.2016.09.005
8. Nutcracker syndrome: a rare cause of abdominal pain in adults that shouldn't be ignored: a case report. *Pan Afr Med J*. 2021 Mar 19;38:288. French. doi: 10.11604/pamj.2021.38.288.28387. PMID: 34122715; PMCID: PMC8180005.
9. Tidjane A, Tabeti B, Benmaarouf N, Boudjenan N, Bouziane C, Kessai N. Superior mesenteric artery syndrome: rare, but think about it. *Pan Afr Med J* 2014;17:47. doi:10.11604/pamj.2014.17.47.3879.
10. Macedo gld , Santos mad , AB Sarris , RZ. Gomes
Venous revascularisation via left gonadal vein transposition in posterior nutcracker syndrome: case report
Brazilian Vascular Journal , 18 (2019) ,10.1590/1677-5449.190037