

## Abdominal Cocoon, A Surgical challenge : A report of 6 Cases

### Abstract

Abdominal Cocoon is an uncommon cause of intestinal obstruction characterized by the complete or partial encapsulation of the small bowel due to the formation of a fibro-collagenous membrane. This condition is predominantly observed in young adolescent girls. It is also known by various terms such as Peritoneal Fibrosis, Peritoneal Sclerosis, Calcified Peritonitis, Encapsulating Peritoneal Sclerosis, or Sclerosing Encapsulated Peritonitis. Abdominal Cocoon can be categorized into two distinct entities:

1. Idiopathic or Primary Sclerosing Encapsulating Peritonitis.
2. Secondary Sclerosing Encapsulating Peritonitis, which is the more common type.

**Key words-** Abdominal Cocoon, Intestinal obstruction

### Introduction

Abdominal cocoon, previously known as sclerosing encapsulating peritonitis (SEP), is a rare condition that can cause intestinal obstruction. It was originally named "Abdominal Cocoon" by Foo et al. in 1978 and is more commonly found in adolescent girls in tropical and subtropical regions. It used to be referred to as primary or idiopathic encapsulating peritoneal sclerosis. [1,2,]

This condition is thought to result from the formation of fibrous tissue sheets that cover, anchor, and eventually constrict the intestines, limiting their normal movement. This leads to the development of a tough, thickened, and leathery fibro-connective tissue sheath, resembling a cocoon, around the small intestine. Abdominal Cocoon can also be associated with underdeveloped or absent omentum. It is sometimes called primary or idiopathic abdominal cocoon.[2,3,4]

Secondary abdominal cocoon can be triggered by various factors, including peritoneal dialysis, tuberculosis, bacterial or viral infections, sterile chemical peritonitis, ventriculo-peritoneal shunts, sarcoidosis, beta-blocker medications, renal and liver transplant surgeries, postoperative adhesions, and the use of Povidone iodine. In all cases, surgical intervention is required. Treatment typically involves the partial or complete removal of the thick fibrotic membrane and the release of adhesions. [4,5]

Aim – To study the clinical manifestation, imaging features and surgical treatment.

### Case presentation

In our current study, conducted retrospectively from March 1992 to September 2023, we analysed the clinical presentations, radiological diagnoses, and treatments of six cases. Prior to

surgery, all patients underwent both CT scans and contrast-enhanced CT scans, as well as routine

abdominal X-rays and ultrasonography. Among the six patients in our series, four were females, and two were males. Open surgery was performed in all five cases, while one case underwent laparoscopic surgery.

The current study involved a total of six patients, including four females and two males, resulting in a gender ratio of 2:1. The clinical manifestations primarily included partial or complete intestinal obstruction in five patients, and three cases exhibited a palpable abdominal mass caused by abdominal cocoon.

Among these cases, three were preoperatively diagnosed through abdominal CT scans, while the other three were identified through abdominal ultrasonography and abdominal plain X-rays, all of which indicated bowel obstruction. During laparotomy, five patients underwent open surgery, while one patient was diagnosed with acute appendicitis via ultrasonography, leading to laparoscopic adhesiolysis of the terminal small bowel along with an appendectomy.

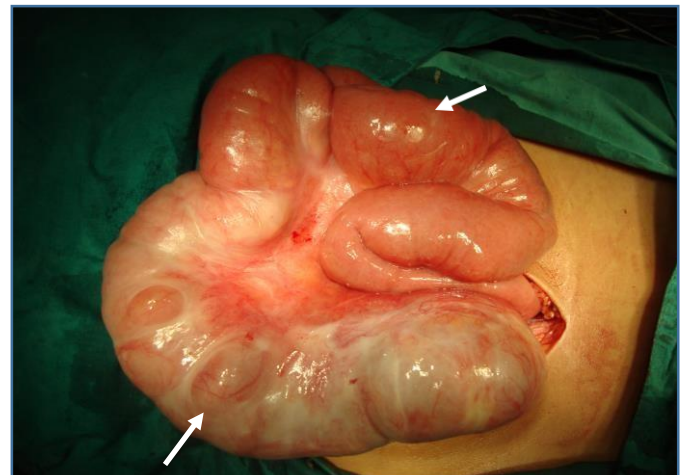
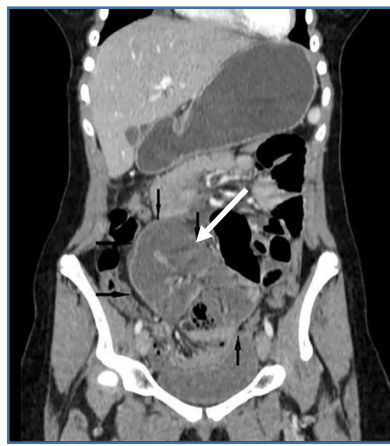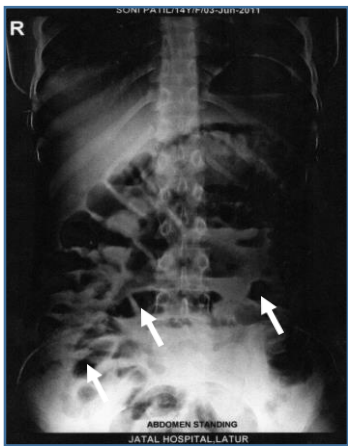
In two patients, only partial encapsulation of the small bowel was observed, while in three patients, the entire small bowel was encased within a dense, white, thick fibrous cocoon-like membrane. Surgical procedures involved the careful excision of the thick membrane and adhesiolysis to release the small intestine. All patients in our series experienced a smooth post-surgical recovery, with no reported recurrence during the follow-up study.

### **Case 1**

On June 3, 2011, a 14-year-old girl was admitted to our medical centre due to complaints of abdominal pain, abdominal distension, and vomiting, which had been occurring for three days. Upon physical examination, abdominal distension and the presence of a lump in the abdomen were noted. An abdominal plain X-ray showed the presence of multiple air-fluid levels, indicating acute intestinal obstruction. Ultrasonography revealed clustered bowel loops, resembling a "cauliflower" in shape, with proximal jejunal dilations, suggesting a blockage in the small intestine. All laboratory and biochemical test results were within normal ranges.

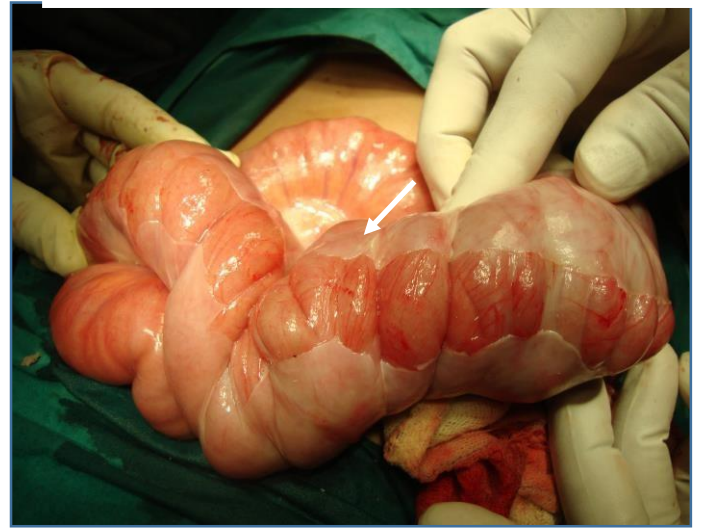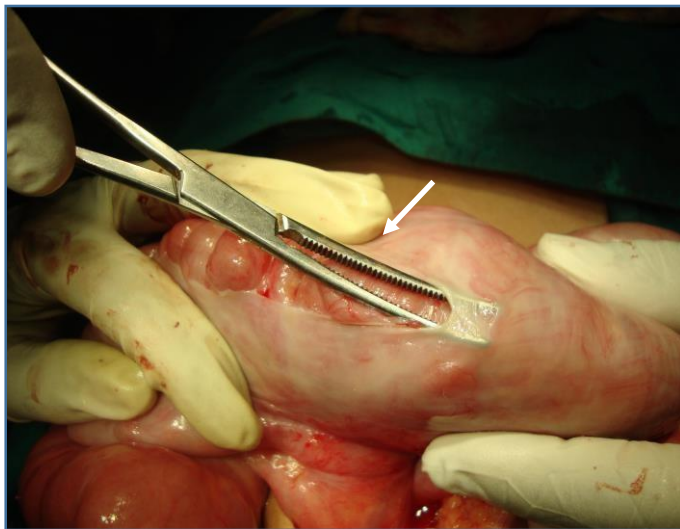
An open exploratory laparotomy was performed, revealing that a substantial portion of the terminal bowel, extending up to the cecum, was enclosed within a thickened, white, cocoon-like fibrous membrane. Notably, the appendix was not enveloped by this membrane but appeared congested. Careful dissection was carried out using blunt and sharp instruments, including scissors, to excise the dense membrane and release severe adhesions between the bowel loops.

This surgical procedure ensured the viability of the small intestine without any injury during the dissection. Additionally, an appendectomy was performed during the surgery. The post-operative course was free of complications, and the patient was discharged on the eighth day after surgery. Histopathological examination of the excised tissue revealed the presence of a fibro-collagenous membrane with areas of chronic inflammation. **(Fig 1-6)**



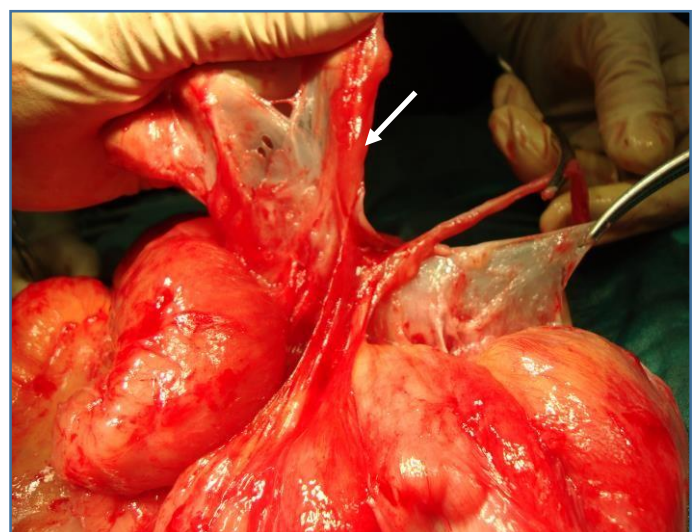
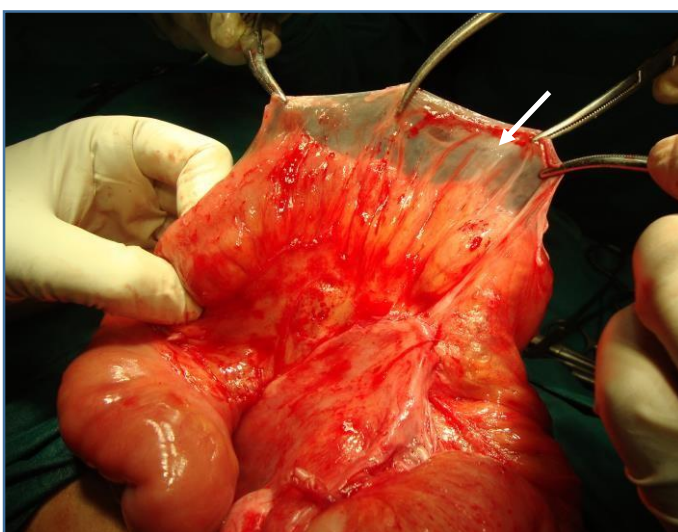
**Fig-1** X-ray abdomen showing dilated small bowel with multiple air fluid levels & CT abdomen showing "Cauliflower sign"

**Fig-2** Intraoperative photograph showing abdominal cocoon with thick fibrous membrane with dilated proximal bowel loops



**Fig-3** Intraoperative photograph showing dissection of membranous layer on the small bowel

**Fig-4** Intraoperative photograph showing dissection of membranous layer on the small bowel



**Fig-5-6** Intraoperative photograph showing complete excision of thick membrane with adhesiolysis procedure

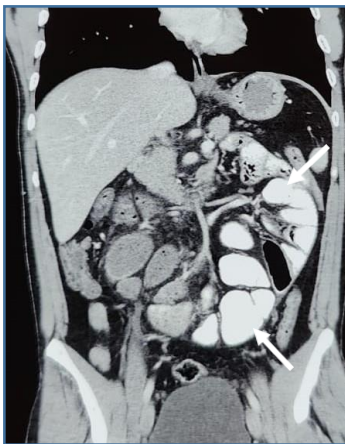## Case No. 2

On September 16, 2023, a 35-year-old male patient was admitted to our hospital due to complaints of vomiting over the past two days, abdominal distension, and the presence of a lump in his abdomen. He reported experiencing these symptoms for the past two years. During the physical examination, a large lump in the abdomen was observed, extending from the epigastric region to the central umbilicus and from the right iliac fossa to the right hypochondrium.

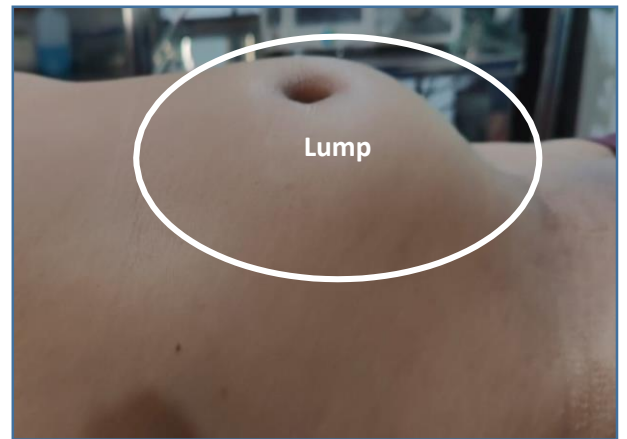
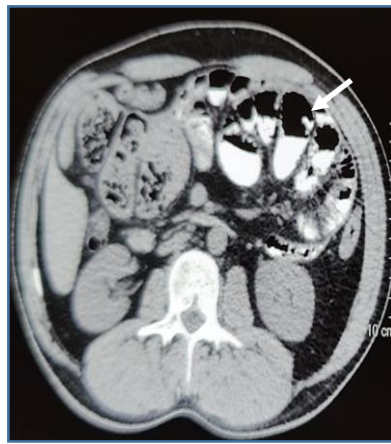
An abdominal X-ray revealed dilated small bowel loops with multiple air-fluid levels and clustering of bowel loops in the central abdomen. A contrast-enhanced abdominal CT scan depicted a large cauliflower-like structure, with congested small bowel loops on the left side of the abdomen. In the centre of the abdomen, a helical pattern of small bowel loops was visible, along with peritoneal encapsulation, which strongly suggested a diagnosis of a large abdominal cocoon. All laboratory and biochemical investigations returned normal results.

The patient underwent a laparotomy through a midline incision. Upon entering the abdominal cavity, a thick and dense membrane was discovered, encapsulating the entire small bowel, extending from the jejunum to complete small bowel and cecum. A substantial membrane was stretched out in front of both the ascending and descending colon. The entire thick membrane was excised, and extensive adhesiolysis was performed using blunt and sharp dissection techniques, including the use of sharp scissors. This meticulous procedure successfully released all small bowel loops, and the entire small intestine was found to be viable without any serosal tears or perforations and we performed appendectomy.

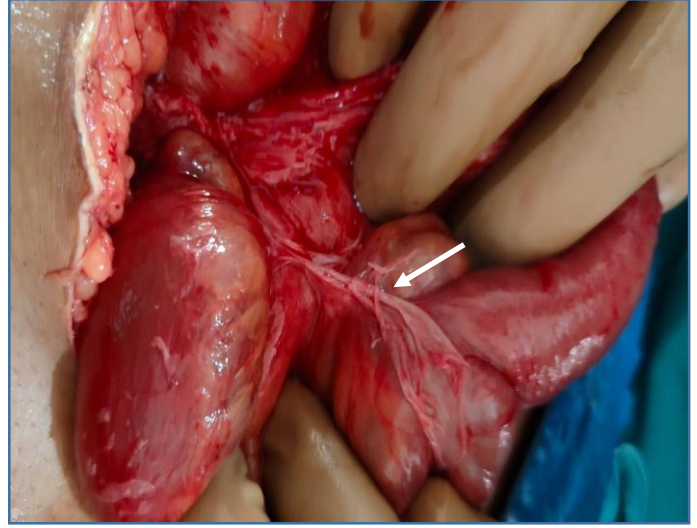
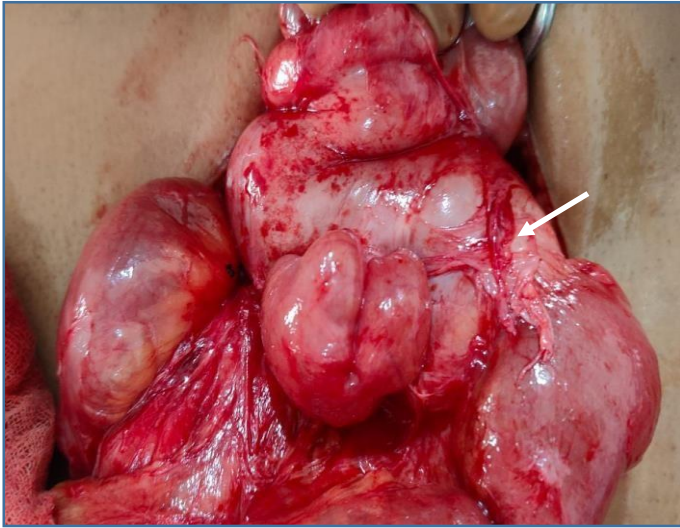
The patient experienced a delayed paralytic ileus but had an uncomplicated postoperative period. He was discharged on the 15th day after surgery. The excised membrane was sent for histopathological examination, which revealed connective tissue with the presence of inflammatory cells, confirming the diagnosis of primary or idiopathic abdominal cocoon, also known as encapsulating peritoneal sclerosis. **(Fig 7 - 12)**



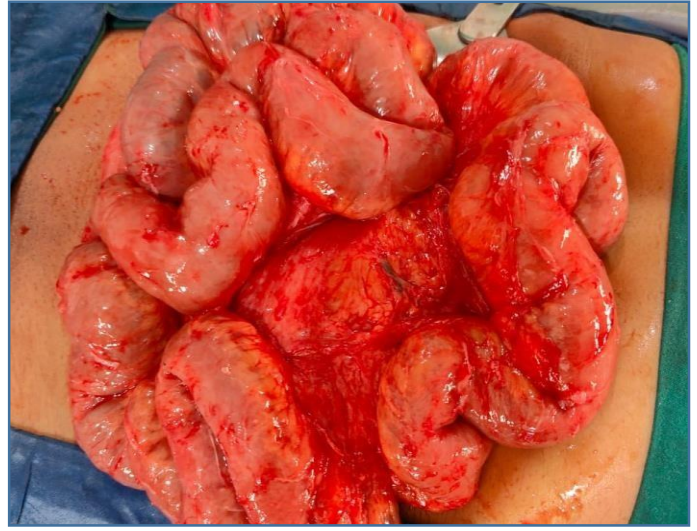
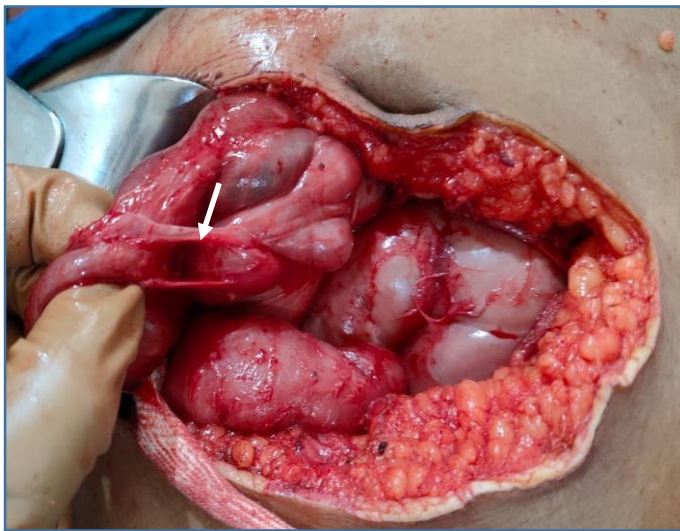
**Fig-7** Contrast enhanced CT abdomen showing clustering of small bowel loops inside the thick cocoon sac & "Cauliflower sign" positive



**Fig-8** Photograph showing palpable lump in abdomen around the umbilicus

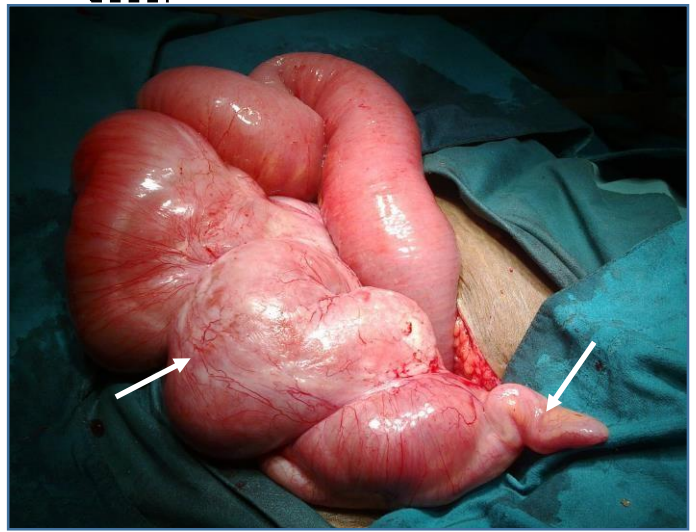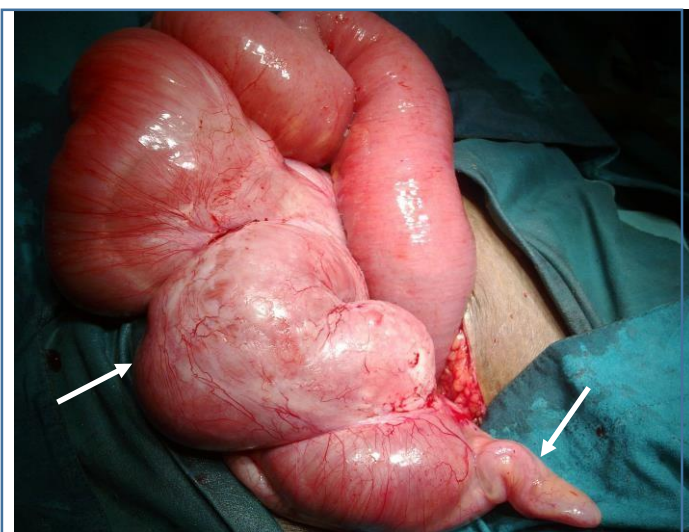


**Fig-9,10** Intraoperative photograph showing thick fibrous membrane with abdomen cocoon



**Fig-11, 12** Intraoperative photograph excision of thick fibrous membrane with complete adhesiolysis

**Case 3- Images (Fig 13,14)**



**Fig-13, 14** Intraoperative photograph showing abdomen cocoon involving small bowel cecum with normal appendix

Case 4- Images (Fig 15,16)

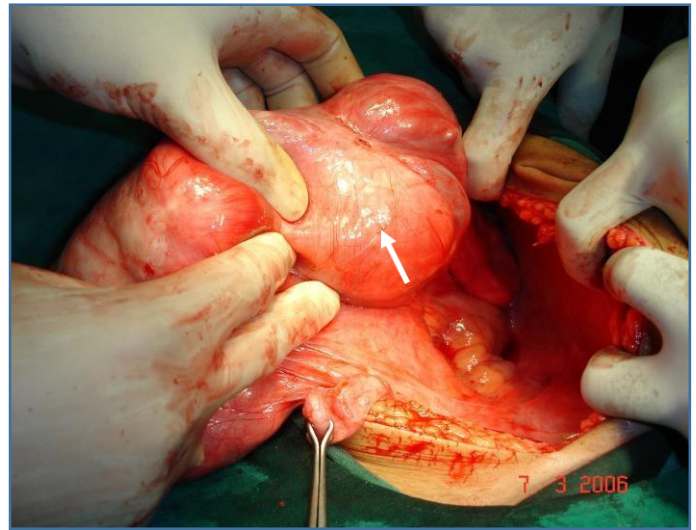
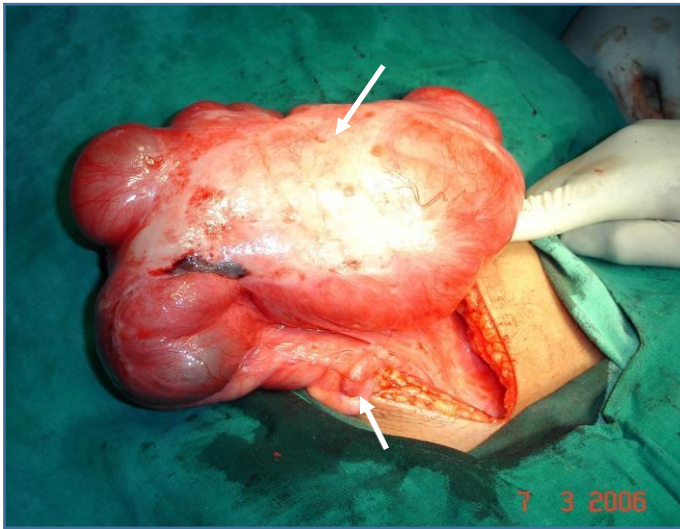


Fig-15 ,16 Intraoperative photograph showing abdomen cocoon involving small bowel cecum with normal appendix

Case 5- Images (Fig 17, 18)

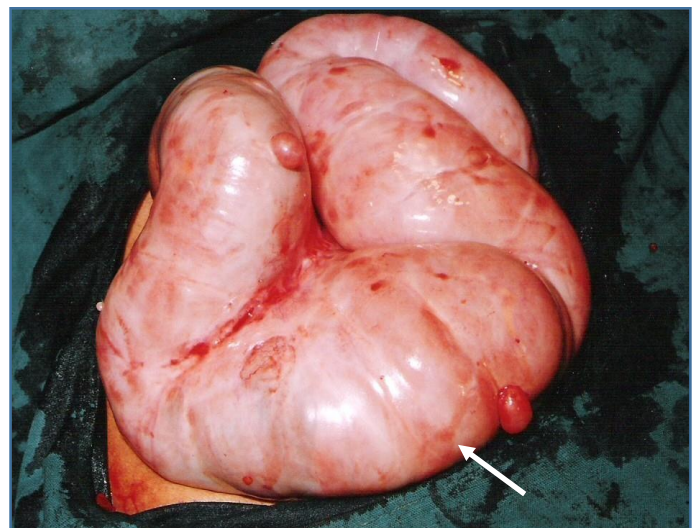
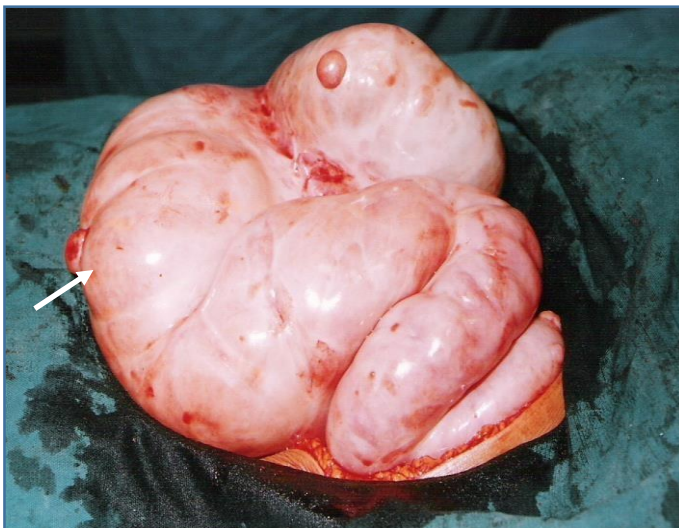


Fig-17 ,18 Intraoperative photograph showing abdominal cocoon with thick fibrous membrane

**Discussion**

The term "abdominal cocoon" was coined in 1978 by Foo et al. This condition is a rare peritoneal disease that is classified into two main categories:

1. Idiopathic or Primary Abdominal Cocoon.
2. Secondary Abdominal Cocoon.

Primary or idiopathic, encapsulating peritoneal sclerosis is a condition with an obscure etiology and is more commonly observed in adolescent girls from tropical and subtropical regions. It has been proposed to be linked to retrograde peritonitis from the fallopian tubes and retrograde migration of bacterial or viral inflammation from pelvic inflammatory disease. [2,3,4]

Causes of secondary abdominal cocoon include chronic peritoneal dialysis, chronic peritonitis, autoimmune diseases, the use of beta-blocker drugs, liver transplants, tuberculosis inflammation,

vertical peritoneal shunts, and carcinoid syndrome. Repeated infections can lead to peritoneal damage, impairing its normal physiological function, and progressing through stages of turbidity, deformation, and fibrosis. [4,5,6]

Abdominal cocoon can be categorized into three types based on the extent of involvement of the small intestine or other organs:

1. Type 1: Involves only a part of the small intestine.
2. Type 2: Involves the entire small intestine.
3. Type 3: Involves the entire small intestine, colon, stomach, or other visceral organs.

Clinical presentation commonly includes abdominal pain (72%), followed by abdominal distension (45%) and the presence of an abdominal mass (30%). Complete or partial obstruction occurs in 88-90% of patients with abdominal cocoon, making correct pre-surgical diagnosis challenging. [2,4,5]

Radiological imaging plays a crucial role in diagnosis. Abdominal X-rays often show dilated small bowel loops with multiple air-fluid levels and clustering of bowel loops in the centre of the abdomen. Ultrasonography may reveal dilated small bowel loops and clumped bowel loops toward the centre of the abdomen, resembling a "cauliflower" shape. However, a CT abdomen or contrast-enhanced CT scan is the most important tool for diagnosing abdominal cocoon. CT findings typically show clustered bowel loops enclosed in a sac-like structure in a typical cocoon pattern, with features such as the "bottle gourd sign" or "cauliflower sign" being important radiological findings. Enhanced CT scans can effectively assess bowel mesenteric ischemia and necrosis. [1,2,5,6]

Surgical intervention is the primary treatment, especially for those with intestinal obstruction or an abdominal mass. Laparoscopy is a valuable tool for both diagnosis and treatment. Surgical treatment involves excising the thickened cocoon-like membrane, releasing intestinal adhesions, and freeing bowel loops. Careful attention is paid to avoid injuring the small intestine during adhesiolysis. [5,7,8]

## Conclusion

Abdominal cocoon is an uncommon condition characterized by intestinal obstruction caused by the small intestine being enveloped by a fibro-collagenous membrane. Preoperative diagnosis can be aided by a contrast-enhanced CT scan, which may reveal the characteristic "cauliflower sign" and clumping of bowel loops. The primary treatment for abdominal cocoon is open surgery. The surgical procedure involves the complete removal of the membrane and adhesiolysis. Careful attention is given to ensure that this is done without causing any injury to the bowel.

### Ethical Approval:

As per international standard or university standards written ethical approval has been collected and preserved by the author(s).

### Consent

As per international standards or university standards, patient as well as parental written consent has been collected and preserved by the author(s).

## References

1. Yu R, Ya Y, Ni X, Fan G. Imaging and treatment of idiopathic abdominal cocoon in 9 patients. *Exp Ther Med*. 2020 Jan;19(1):651-657. doi: 10.3892/etm.2019.8258. Epub 2019 Nov 29. PMID: 31885704; PMCID: PMC6913277.
2. Wei B, Wei HB, Guo WP, Zheng ZH, Huang Y, Hu BG, Huang JL. Diagnosis and treatment of abdominal cocoon: a report of 24 cases. *Am J Surg*. 2009 Sep;198(3):348-53. doi:

10.1016/j.amjsurg.2008.07.054. Epub 2009 Feb 13. PMID: 19217609.

3. Schauki Mahmoud, Abdurrahman Hashi Salad, Aisha Abdirahman Abdullahi, Abdominal cocoon syndrome, a diagnostic challenge affecting the treatment. A rare case report from

Somalia, *Journal of Surgical Case Reports*, Volume 2023, Issue 3, March 2023, rjad107, <https://doi.org/10.1093/jscr/rjad107>

4. Aziz W, Malik Y, Haseeb S, et al. (July 31, 2021) Abdominal Cocoon Syndrome: A Laparoscopic Approach. *Cureus* 13(7): e16787. doi:10.7759/cureus.16787
5. **Harshal S Mandavdhare, Amit Kumar, Vishal Sharma, Surinder S Rana**, Abdominal cocoon: An enigmatic entity, tropical gastroenterology , <http://dx.doi.org/10.7869/tg.349>
6. Karona P, Blevrakis E, Kastanaki P, Tzouganakis A, Kastanakis M. Abdominal Cocoon Syndrome: An Extremely Rare Cause of Small Bowel Obstruction. *Cureus*. 2021 Apr 7;13(4):e14351. doi: 10.7759/cureus.14351. PMID: 33972908; PMCID: PMC8105234.
7. Ketan Ketan Vagholkar, Khizer Doctor-Ganju, Abdominal cocoon: a surgical challenge, *International surgery journal*, DOI: <https://doi.org/10.18203/2349-2902.isj20184713>
8. Hameed FM, Ahmed SM. Acute intestinal Obstruction with a palpable mass: 'Abdominal Cocoon Syndrome'. *Clin Surg J*. 2022;3(4):1–6
9. Julius A. A. Awe, "Abdominal Cocoon Syndrome (Idiopathic Sclerosing Encapsulating Peritonitis): How Easy Is Its Diagnosis Preoperatively? A Case Report", *Case Reports in Surgery*, vol. 2013, Article ID 604061, 3 pages, 2013. <https://doi.org/10.1155/2013/604061>
10. Manphool Singhal, Satheesh Krishna, Anupam Lal, Sabarish Narayanasamy, Amanjit Bal, Thakur D. Yadav, Rakesh Kochhar, Saroj K. Sinha, Niranjana Khandelwal, and Adnan M. Sheikh  
*RadioGraphics* 2019 39:1, 62-77