

## Original Research Article

# Prevalence and Morphological characterization of *Hysterothylacium* sp. (Nematoda: Raphidascarididae) Recovered from Infected Organs of Lizardfish (*Saurida undosquamis*)

### ABSTRACT

**Aims:** This study was aimed to determine the prevalence and morphological features of *Hysterothylacium* species from different infected organs in lizardfish in Misurata, Libya.

**Place and Duration of Study:**

The study was carried out at Misurata University, Misurata, Libya, between June 2018 and May 2019.

**Methodology:** 192 specimens of the *Saurida undosquamis* were collected from the local market of Misurata city in Libya. Lizardfishes were examined only for *Hysterothylacium* species. After collection, Nematodes were identified by the naked eye or by using the lens, were isolated in a sterile container containing normal saline, and were washed several times with normal saline to remove any attached mucus.

**Results:** The prevalence rate of Nematoda helminths in examined fish *Saurida undosquamis*, was high. Based on the morphological and morphometric characterization, only one Nematode species (*Hysterothylacium* sp.) was isolated. Of the total fish examined, 189 (98.4%) were infected with *Hysterothylacium* sp. The density of *Hysterothylacium* sp. was around 2557, and they were collected from the stomach, anterior and posterior parts of the intestine, liver, and muscles in all seasons, but gills only in autumn and winter. The high-density rate in spring (823), followed by winter (757), with non-significant differences between density rates in all seasons ( $P > 0.05$ ).

**Conclusion:** This study found a high infection rate with *Hysterothylacium* sp. in the examined *Saurida undosquamis*. This nematode species is commonly recovered in marine fish and is probably negligible concern for public health.

**Keywords:** Endoparasites, Lizardfishes, *Hysterothylacium* sp , Prevalence, Identification, Nematodes, *Saurida undosquamis*.

## 1. INTRODUCTION

Parasitic nematodes constitute one of the earliest known groups of helminths in fishes. Nematodes are considered the most economically important helminth parasites infecting fishes in the world; they infect freshwater, marine, and brackish-water fish species and sometimes cause substantial damage to the host. Although parasitic nematodes can infect almost

all organs in a fish, most currently known species have been described from the intestine. Most nematodes infect fish as adults, but many of them occur in larval stages. These are usually parasites of piscivorous birds, mammals, or reptiles, or less frequently of predatory fishes, the majority of nematodes reach sexual maturity through a complicated developmental cycle involving an intermediate or possibly paratenic host. [1].

Few previous studies have been done on *Saurida undosquamis*, to diagnose infection by nematodes. From previous studies, many parasites affect the internal organs of *S. undosquamis* such as intestines, muscles, liver, and kidney, and often show symptoms of infection of these parasites, In the Mediterranean and northeast Atlantic regions, *Hysterothylacium* species is the most frequently reported in a wide range of fish different species can have similar larval morphology. Moreover, larvae can exhibit rather uniform morphology, which is completely different from their adult forms. Adult and larval stages of the genus *Hysterothylacium* are common parasites of marine fishes, usually the larvae are located in visceral cavity [2], and this zoonosis caused by fish is classified as gastric (GA), intestinal (IA), or extra-gastrointestinal anisakiasis, depending on the location of the larvae in the host's body, [3]. Although *Hysterothylacium* spp. is present in a variety of fish species, there is still debate regarding its potential for causing harm to humans. Furthermore, there are other marine parasitic nematodes, from *Anisakis*, whose pathogenic potential has yet to be thoroughly studied, [4,5].

The previous studies were recorded by El-Atabany obtained (5.08%) from Egypt [6]. In contrast, the previous study by [7] did not report any infection with nematode species. Several previous studies have focused on *Hysterothylacium* spp. in various marine fish species, [8,9], Few previous studies in Libya determined the prevalence of infection rates from different organs of some fish, like Atlantic chub mackerels recorded by [8]. This study was aimed to determine the prevalence and identify some nematode species from different infected organs in lizardfish in Misurata, Libya.

## 2. MATERIAL AND METHODS

**Fish sampling:** The study included 192 lizardfish *Saurida undosquamis*, the current study was conducted from June 2018 to May 2019, and 15 to 20 fish were collected from the local market of Misurata, Libya. They were transferred in an ice box to the laboratory of the Zoology Department, Faculty of Science. The year was divided into four seasons: Winter (December-February), spring (March-May), summer (June-August), and autumn (September-November).

Lizardfishes were examined only for internal parasites. Fish were dissected, and the whole body cavity, muscles, liver, and digestive system were carefully examined by the naked eye for the presence of helminths. On the other hand, the organs (gills, liver, stomach, anterior intestines, and posterior intestines) were separated by dissecting scissors and forceps and placed in Petri dishes containing the normal saline. Then, a scalpel and forceps were used to scrape fish contents gently. All petri dishes were carefully examined for the presence of nematodes by dissecting and light microscopes. Finally, the Nematodes were isolated in a sterile container containing normal saline, [10] (Hoffman, 1967).

After collection, Nematodes were identified by the naked eye or by using the lens, were isolated in a sterile container containing normal saline were washed several times with normal saline to remove any attached mucus. The isolated Nematodes were placed in lactophenol, and the retention period in lactophenol varied depending on the size of the worm. to elucidate the structures such as the oesophagus and oral spicules for species identifications besides the body shape and dimensions the characteristics such as the body cuticle, existence of spines the structure of the anterior and posterior body are important. It is also necessary to know the host and location of the nematode. They were then examined under the microscope to ensure the internal organs were visible and loaded onto the slide using the DPX and were labeled with all details regarding each sample. [11] (Rasheed, 1989).

The data analysis compared helminth abundance between the different parasite species using one-way ANOVA at a 5% significance level. The relationship between lengths and weights of Lizardfish with parasite density was determined using linear correlation at a 5% significance level. The comparisons of parasite abundance with seasonal variations were carried out using one-way ANOVA. This test was performed using the SPSS computer software.

## 3. RESULTS AND DISCUSSION

The examined fish were infected with Nematodes (*Hysterothylacium* sp.) 189 (98.4%). Figure (1) shows that the stomach showed the highest infection rate (78.6%), followed by the anterior part of the intestine (72.9%) and liver (64%). The gills and posterior parts of the intestine and muscles had the lowest infection rates (2.6%, 47.9%, and 49.5%, respectively). On the other hand, the stomach demonstrated the highest infection rate in winter (30%), followed by autumn (24%). Moreover, the anterior part of the intestine showed the highest infection in winter (28%), as illustrated in Table (1). Based on the statistical analysis, a slightly significant difference ( $P=0.01$ ) was found in gills, but insignificant differences ( $P> 0.05$ ) were in other infected organs. Otherwise, a moderate relationship was determined among the anterior and posterior parts of the intestines according to the correlation coefficient ( $r$ ), ( $r= 0.661^*$ ,  $P\leq 0.05$ ).

Table (1): Total prevalence rate of *Hysterothylacium* sp. with the seasonal variations of different organs.

Seasons	Stomach	Anterior intestine	Posterior intestine	Liver	Gills	Muscles	Total
Winter	45 (30%)	42 (28%)	30 (20%)	20 (13.3%)	3 (2%)	10 (6.6%)	150
Spring	36 (23%)	35 (22%)	19 (12%)	38 (24%)	0	28 (17.9%)	156
Summer	32 (22.5%)	32 (22.5%)	23 (16%)	32 (22.5%)	0	23 (16%)	142
Autumn	38 (24%)	31 (19.6%)	20 (12.6%)	33 (20.8%)	2 (1.2%)	34 (21.5%)	158

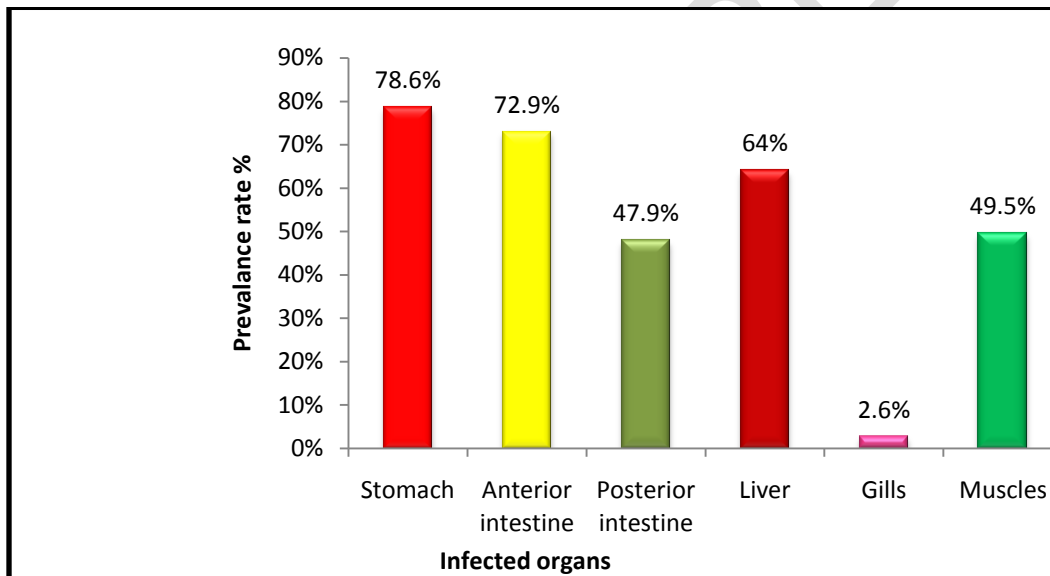


Figure 1: The prevalence rates of *Hysterothylacium* sp. infection based on the infected organs

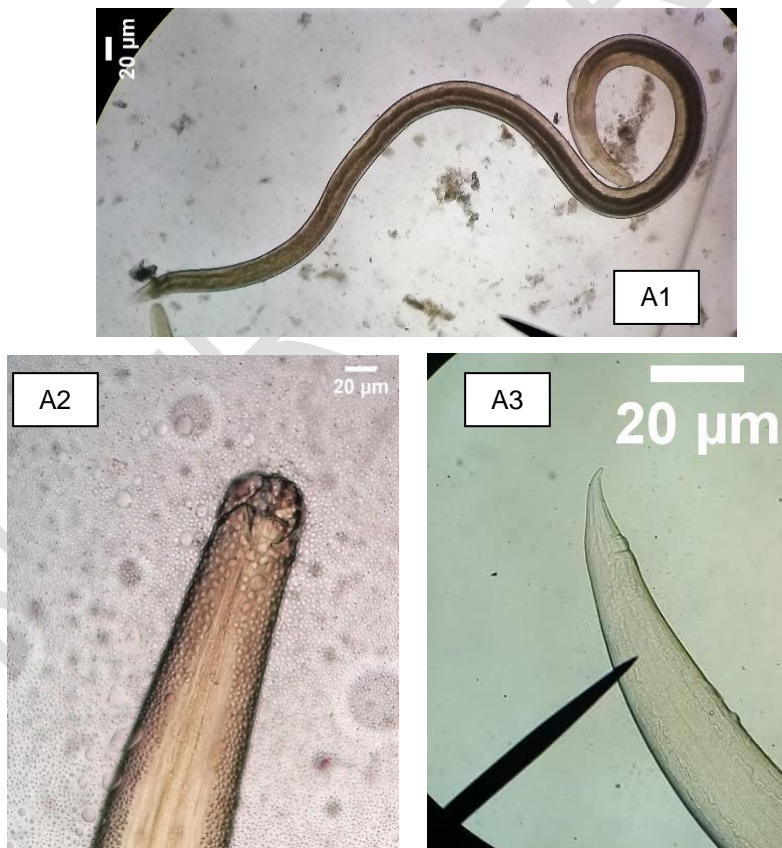
According to the density of infection in different infected organs, the anterior part of the intestine had the highest density of infection (27.4%), followed by the liver (27.3%). In contrast, the lowest Nematode density infection was in the posterior part of the intestine and gills (7.7%, and 0.2%, respectively, these results corresponding with the result by Ueam *et al* [9]. In contrast, Table 2 showed that spring reported the highest density (32.1%), followed by winter (30%), while there was the lowest density in summer (15%). Moreover, based on the one-way ANOVA, a significant difference ( $P \leq 0.05$ ) was found in Nematode density infection in gills. In contrast, a non-significant difference ( $P > 0.05$ ) was between other infected organs. A strong relationship was found between the abundance of Nematode in the posterior part and liver ( $r = 0.734^{**}$ ). In addition, a correlation was found between the spread of Nematode in the anterior region and the posterior part ( $r = 0.687^*$ ) and the abundance of Nematode in the liver and muscles ( $r = 0.604^*$ ). In contrast, no correlation was observed between gills and other organs.

**Table (2): Density infection rates of *Hysterothylacium* sp. in *Saurida undosquamis* according to infected organs.**

Seasons	Gills	Stomach	Anterior intestine	Posterior intestine	Liver	Muscles	Total Density rate
Winter	4 (0.52%)	127 (16.7%)	201 (26.5%)	64 (8.4%)	253 (33.4%)	108 (14.2%)	757 (29.6%)
Spring	0	130 (15.7%)	295 (35.8%)	55 (6.6%)	220 (26.7%)	123 (14.9%)	823 (32.1%)
Summer	0	98 (26.2%)	91 (24.3%)	37 (9.9%)	91 (24.3%)	56 (15%)	373 (14.6%)
Autumn	2 (0.33%)	161 (26.6%)	115 (19%)	41 (6.7%)	136 (22.5%)	149 (24.6%)	604 (23.7%)

To identify the nematodes present and classify them correctly, we consulted various sources and considered the morphological and morphometric characteristics of *Hysterothylacium* sp. These included the Phylum: Nematoda, Class: Chromadorea, Order: Ascaridia, Suborder: Hemiurata, Family: Raphidascarididae, Subfamily: Hemiuroidea Faust, 1929, Genus: *Hysterothylacium*, and Species: *Hysterothylacium* sp. We referred to publications by Yamaguti and Ward & Magath [12,13] for further information.

According to the morphological characteristics, the body colour of the recovered larvae stage (L1) was yellowish to brownish, and the body was small and elongated, thin cylindrical, and had a smooth tegument. Moreover, the mouth had smooth lips, and the oesophagus was simple. The lengths of the anterior and posterior ends were 26.57  $\mu\text{m}$  and 31.59  $\mu\text{m}$ , respectively) (Figure 2 A1, A2, A3).



**Figure 2 (A1, A2, A3): A general view of the Larval stage (L1) of *Hysterothylacium* sp. from *Saurida undosquamis*. A1 shows the whole body of larvae, A2 demonstrates the anterior end of larvae, and A3 demonstrates the posterior.**

The recovered larvae stage (L2) body was yellowish to brownish, medium-sized, with a white body wall covered with a slightly zigzag casing. The mouth had lips, and the oesophagus was simple. The tail was conical and relatively short, and the lengths of the anterior and posterior ends were 34.96  $\mu\text{m}$  and 59.76  $\mu\text{m}$ , respectively (Figure 3 B1, B2, B3).

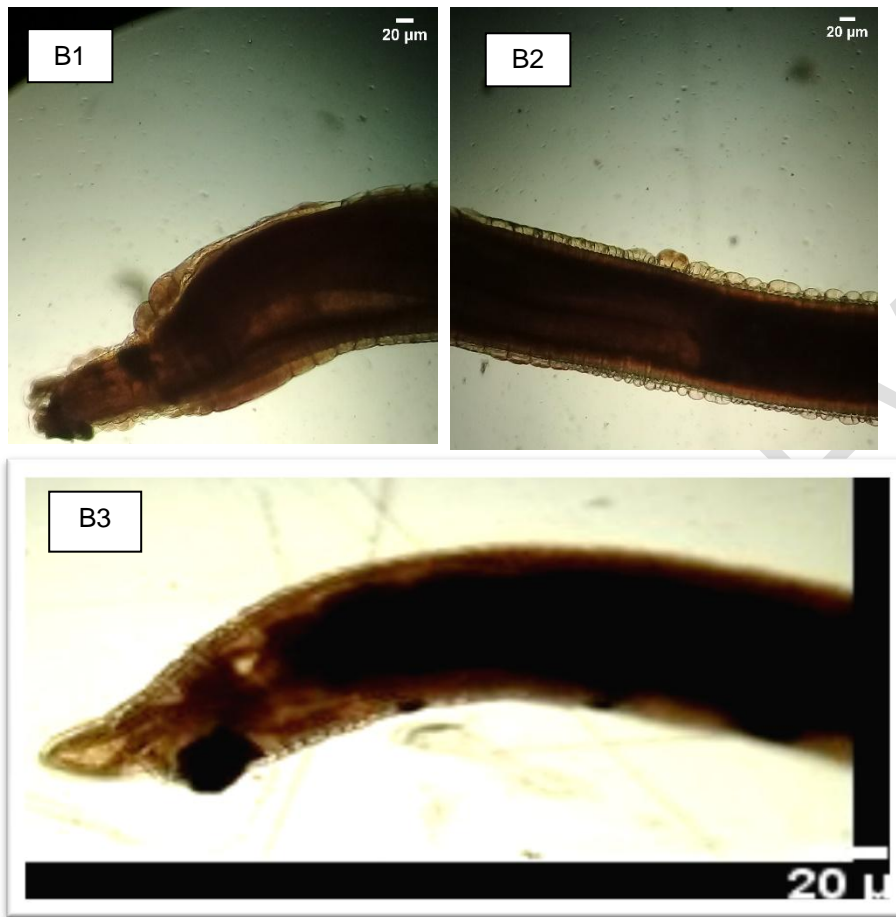


Figure 3 (B1, B2, B3): A general view of the Larval stage (L2) of *Hysterothylacium* sp. from *Saurida undosquamis*. B1 illustrates the curved sheet on the tegument, B2 shows the anterior end of larvae, and B3 represents the posterior end.

Furthermore, the final stage of the recovered larvae (L3) was yellowish to brownish, small-sized, and elongated, with a white body wall covered with a slightly zigzag casing. The mouth had smooth lips, and the oesophagus was simple. The tail was conical, with numerous terminal short spines arranged in a circle. The lengths of the anterior and posterior ends were 84.87 and 48.82  $\mu\text{m}$ , respectively (Figure 4 C1, C2, C3).

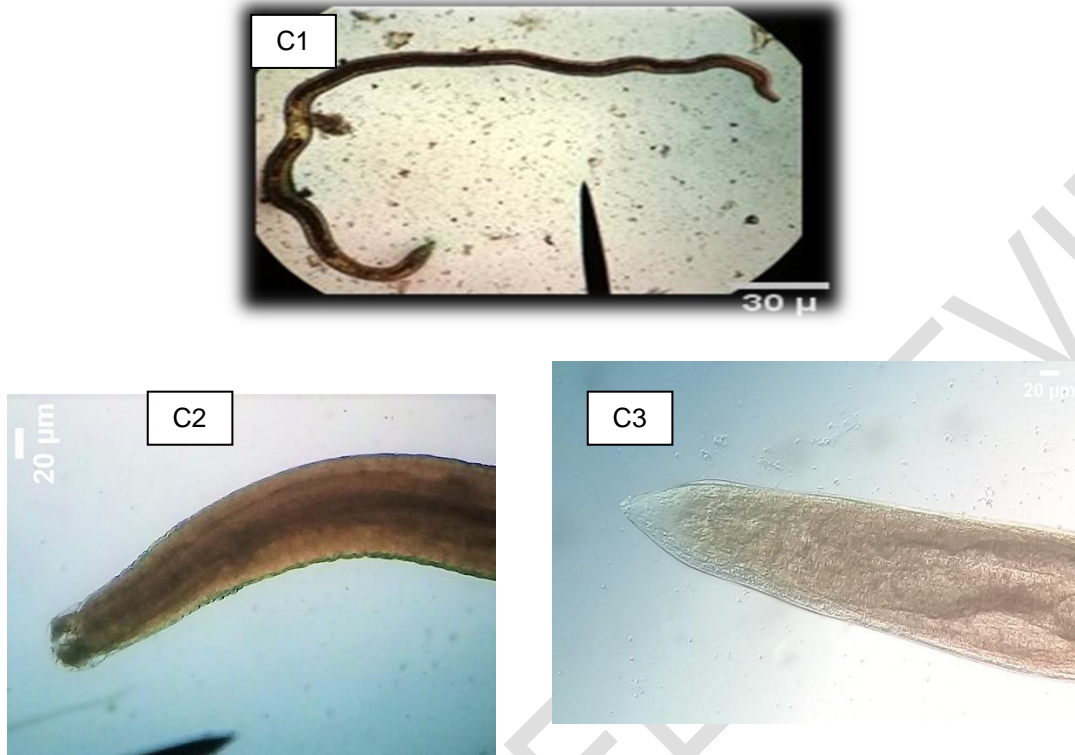


Figure 4 (C1, C2, C3): A general view of the Larval stage (L3) of *Hysterothylacium* sp. from *Saurida undosquamis*. C1 demonstrates the whole body of the larvae, C2 represents the anterior end of the larvae, and C3 demonstrates the posterior end.

Regarding the adult worms, the female body was medium and had a smooth tegument and a brownish colour. The mouth had lips. The oesophagus was simple. The posterior ends were straight, and the lengths of the anterior and posterior ends were 47.07  $\mu\text{m}$  and 23.12  $\mu\text{m}$ , respectively) (Figure 5 D1, D2, D3).

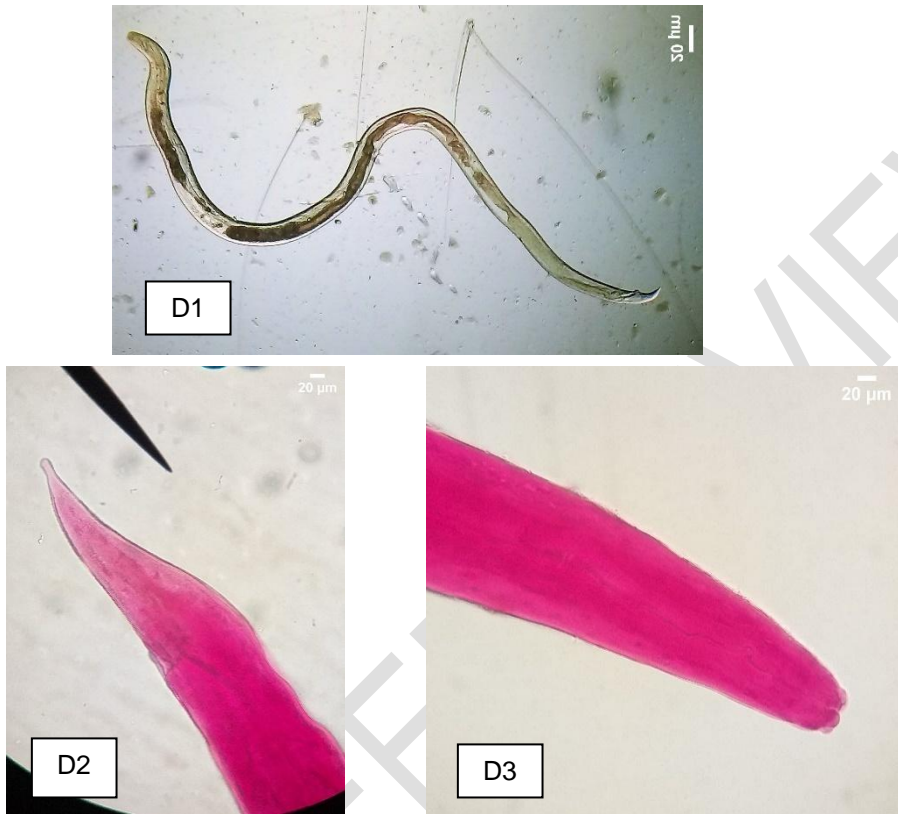

Figure 5 (D1, D2, D3): A general view of the female of *Hysterothylacium* sp. from *Saurida undosquamis* D1 represents the whole female body, D2 demonstrates the female anterior end, and D3 shows the posterior end.

The male body was medium, with a brownish colour and a finely trans- versify striated cuticle. The anterior end had three lips and two slender spicules of equal length. The lengths of the anterior and posterior ends were 54  $\mu\text{m}$  and 50.23  $\mu\text{m}$ , respectively) (Figure 6 E1, E2).




Figure 6 (E1, E2): A general view of the male of *Hysterothylacium* sp. from *Saurida undosquamis*. E1 demonstrates the male anterior end, and E2 shows the male posterior end and the spicules (arrow)

During this study, we encountered great difficulty in distinguishing between types of parasitic worms based on morphological and standard characteristics only, especially with the presence of high infection, as well as the lack of studies in Libya that can be referred to and relied upon in the classification of types of worms isolated from *Saurida undosquamis* from Misurata, Libya.

The present study reported a nematode, *Hysterothylacium* sp. They demonstrated no pathognomonic clinical signs and were in good health except in the liver and muscles. However, all the fish examined were infected with Nematodes in all seasons (100%). Few previous studies illustrated the prevalence of infection rates of *Hysterothylacium* species from different organs of *Saurida undosquamis*. In this study, about 98.4% of examined fishes were infected with *Hysterothylacium* sp., which were collected from different organs such as gills, stomach, anterior and posterior intestine, liver, and muscles, suggesting that the distribution of this species within the fish tissue was related to the availability of nutrients. Meanwhile, it was higher than what [6] El-Atabany obtained (5.08%). In contrast, the previous study by [7] did not report any infection with nematode species. And Morsy *et al.* [14] showed 42.5% and 35% infection rates of *Hysterothylacium* sp., respectively. Sulgostowska *et al.* [15] reported the *Hysterothylacium* sp., the common species in flounders from the Baltic Sea in various seasons. Other studies [16, 17] reported that this parasite was not very host-specific in either the larval or the adult stages. Abundance levels can vary due to factors such as parasite species, the age of fish, the species of infected fish, and environmental conditions. The adult stage of the *Hysterothylacium* genus resides in the digestive tract of marine fish, while the larval stage typically infects invertebrates and marine fish in the body cavity, [9, 18]. Intraspecific genetic differences may arise due to host variation and environmental changes. The Anisakidae and Raphidascaridae families have varying intermediate hosts and low host specificity, resulting in a broad geographical range, [19].

#### 4. CONCLUSION

The Conclusion of this study, these findings revealed the highest infection with all stages of *Hysterothylacium* sp. in *Saurida undosquamis*. Also, the study enhances understanding of the host/parasite relationship between *Hysterothylacium* sp. and *Saurida undosquamis* with updates on parasite localization and development in Lizardfish.

#### ETHICAL APPROVAL

The studies were reviewed and approved by Zoology Departmental, Science College Misurata University, Libya

#### REFERENCES

1. Molnár, K., Buchmann, K., & Székely, C. (2006). 12 Phylum Nematoda. Fish diseases and disorders, 417.
2. Cipriani P., Smaldone G., Acerra V., D'Angelo L., Anastasio A., Bellisario B., Palma G., Nascetti G., Mattiucci S. (2015). Genetic identification and distribution of the parasitic larvae of *Anisakis pegreffii* and *Anisakis simplex* s.s. in European hake *Merluccius merluccius* from the Tyrrhenian Sea and Spanish Atlantic coast: Implications for food safety. *Int. J. Food Microbiol.* 198:1–8. doi: 10.1016/j.ijfoodmicro.2014.11.019.
3. Nieuwenhuizen N.E. (2016). *Anisakis* - immunology of a foodborne parasitosis. *Parasite Immunol.* 38:548–557. doi: 10.1111/pim.12349.
4. González-Amores Y., Clavijo-Frutos E., Salas-Casanova C., Alcain-Martínez G. (2015). Direct parasitological diagnosis of infection with *Hysterothylacium aduncum* in a patient with epigastralgia. *Rev. Esp. Enferm. Dig.* 107:699–700.
5. Panel EFSA On biological hazards (BIOHAZ) scientific opinion on risk assessment of parasites in fishery products. (2010). *EFSA J.* 8:1543. doi: 10.2903/j.efsa.2010.1543.

6. El-Atabany, A. I., Mahmoud, A. F. A. and Abd, A. M. (2019): Prevalence and public health importance of anisakid nematode in lizardfish collected from Sharkia Governorate, Egypt. Fifth International Food Safety Conference, Damamhur University, Saturday, 13th October 2018, 576-582.
7. Eissa, I.A.M., Gaafar, R., Abdelwahab, M., Dessouki, A., and El-Lamie, M. (2020): Insights on the Prevailing Digeneasis and Nematodiasis in Some Marine Fish in Ismailia Governorate. SCVMJ, XXV (2):222-234.
8. Cavallero, S., El Sherif, R. A., Pizzarelli, A., El Fituri, A. A., El Showhdi, M., Benmosa, F., & D'Amelio, S. (2019): Occurrence of Anisakis and Hysterothylacium nematodes in Atlantic chub mackerels from Libyan coasts. Helminthologia, 56(4), 347-352.
9. UTAMI, A. M., MURWANTOKO, I. and TRIYANTO, E. S. (2022). *Hysterothylacium amoyense* (Nematoda: Raphidascarididae) infecting *Trichiurus lepturus* (Scombriformes: Trichiuridae) from Demak, Central Java, Indonesia. BIODIVERSITAS ISSN: 1412-033X Volume 23, Number 2, E-ISSN: 2085-4722 Pages: 1030-1037.
10. Hoffman G. L. (1967): Parasite of North American fresh water fisher, Univ. Galifornin Press, London, 486 pp.
11. Rasheed, A. R. A. M. (1989): First record of Diplozoon barbi Reichenbach-Klinke, 1951 from some freshwater fishes from Tigris River, Baghdad, Iraq. Zanco, 2(3), 5-15.
12. YAMAGOTI, S. (1961): Systema helminthum III. The nematodes of vertebrates. Interscience Publ., New York, 1261 s.
13. Ward, H.B., Magth, T.B. 1917. Notes on some nematodes from freshwater fishes. Journal of Parasitology, 3: 57-64.
14. Morsy, K., Bashtar, A. R., Mostafa, N., El Deeb, S. and Thabet, S. (2015): New host records of three juvenile nematodes in Egypt: Anisakis sp. (Type II), Hysterothylacium patagonense (Anisakidae), and Echinocephalus overstreeti (Gnathostomatidae) from the greater lizard fish Saurida undosquamis of the Red Sea. Parasitology research, 114(3), 1119-1128.
15. Sulgostowska T., Banaczyk G. and Grabda-Kazubska B., (1987): Helminth fauna of flatfish (Pleuronectiformes) from Gdansk Bay and adjacent areas (southeast Baltic), Acta Parasitologica Polonica, 31(26), 231-240.
16. Chibani, M and Rokicki, J., (2004): Seasonal occurrence of parasites of Flounder Platichthys flesus (L.) from the Gulf of Gdansk. Oceanological and Hydrobiological Studies, 33(3), 17-30.
17. Heba, I., & Abdel-Mawla, N. Y. (2019). Investigation of digenesis in some marine fishes in Red Sea. Animal Health Research Journal, 7(1), 160-171.
18. Koie M. (1993). Aspects of the life cycle and morphology of Hysterothylacium aduncum (Rudolphi, 1802) (Nematoda, Ascaridoidea, Anisakidae). Can J Zool 71: 1289-1296. DOI: 10.1139/z93-178.
19. Simsek E, Ciloglu A, Yildirim A, Pekmezci GZ. (2018). Identification and molecular characterization of Hysterothylacium (Nematoda: Raphidascarididae) larvae in bogue (Boops boops L.) from the Aegean Sea, Turkey. Kafkas Univ Vet Fak Derg 24 (4): 525-530. DOI: 10.9775/kvfd.2018.19482.