STUDY OF THE HISTOLOGICAL AND HISTOPATHOLOGICAL EFFECTS OF GARLIC EXTRACT (ALLIUM SATIVUM) ON CISPLATIN-INDUCED KIDNEY DAMAGE IN RABBITS

ABSTRACT

Cisplatin (cis-diammine-dichlorido-platinum II) is a chemotherapeutic agent used for treating different cancers types. However, its usage is limited because it induces harmful toxicities in multiple organs, including nephrotoxicity. Garlic extract has several pharmacological activities, including antioxidant activity. The aim of the study is to alleviative effects of garlic extract (*Allium sativum*) cisplatin-induced kidney damage in rabbits. Twenty-seven healthy domestic male rabbits were used in this work were randomly divided into three groups, each comprising of nine rabbits.The first group (Co) served as control and received a single intraperitoneal injection of normal saline solution, once per week, for six weeks, the second group (Cp) were treated with (7mg/ kg of body weight) therapeutic dose of cisplatin intraperitoneally once per week for six weeks and the third group (Cp+ Ga) received a dose of 250mg/kg body weightof garlic extract by oral gavages, starting from the first day of the experiment for 6 consecutive days before and 6 consecutive days after the cisplatin injection and continued daily for 6 weeks. In addition, this group was treated with (**7** mg / kg of body weight) therapeutic dose of cisplatin intraperitoneally once per week for six weeks.After six weeks of experiment, the animals of the experimental and control groups were anaesthetized by ether inhalation, laparotomized. From the renal histological sections of Cp-treated group displayed pronounced histopathological lesions, destruction of the renal tubules, slogging of almost entire epithelium due to desquamation of tubular epithelium, with pyknosis of their nuclei and swelling with multi-vacuolations of the cytoplasm with obliteration of their lumina, remarkable necrosis, and hyaline casts in renal tubules and focal area of severe haemorrhage compared with those of control (Co) group. While sections from the kidneys of animals received a therapeutic dose of cisplatin and were treated by garlic extract, group (Cp+Ga) revealed less to no distinct pathological damage in renal corpuscles and renal tubules were restored nearly to the control ones. It is concluded that garlic (*Allium sativum*) extract has a powerful alleviative effectagainst CP-induced nephrotoxicity in rabbits.

Keywords

Cisplatin, nephrotoxicity, histopathology, garlic extract.

Introduction:

"The kidney being an essential organ of metabolism and elimination of most of the toxic components, it serves as very important site of attack by various chemical agents including cisplatin, in the form of its activated metabolite**.** Most anticancer agents cause toxicity in various organs, including the kidney, by disturbing theoxidant/antioxidant balance" [(1)].

"Cisplatin[Cis-diamminedichloroplatinum II (CDDP)] is a highly efficient antineoplastic drug commonly used as a first-line therapy for many solid cancers, such as stomach cancer, ovarian cancer, lung cancer, bladder cancer, and germ cell tumors"[(2,3)]. "The experimental cisplatin-induced nephrotoxicity was first reported in 1971"[(4)]. "Since then, numerous studies have been published. Over the past years, researchers have demonstrated that cisplatin nephrotoxicity is dose-dependent and cumulative. Nephrotoxicity can be induced by single or multiple applications of cisplatin. Depending on the dosage, frequency of cisplatin injection, and cumulative dose of cisplatin, animals may develop different severity of acute (early) and chronic (advanced) kidney injury. In rodents cisplatin is usually injected intraperitoneally (ip) and less frequently intravenously (iv) or subcutaneously (sc)" [(5)]. "Previous studied indicated that cisplatin produced animal behavioral and morphological changes, as well as cellular and subcellular changes in kidneys" [(6)].

"The primary manifestations are impairment in the functioning of renal tubular epithelial cells, including inhibition of protein synthesis, oxidative stress, mitochondrial dysfunction, cytoskeleton remodeling, changes of intercellular adhesion, and apoptosis of tubular epithelial cells"[(7)].

"The anticancer effect of cisplatin is mediated by apoptosis and DNA-cross links with subsequent cytotoxic lesions in malignant cells"[(8)].

"Experimental studies on rats and mice revealed that cisplatin leads to nephrotoxicity through formation of glutathione conjugates in blood stream"[(9)]. "Other studies showed that cisplatin binds to DNA leading to arrest of DNA synthesis and replication resulting in cell apoptosis"[(10)].

"Cisplatin is one ofthe most potent and widely used chemotherapeutic antitumour agents. Various agents, including antioxidants,attenuate the nephrotoxicity of this compound"[(11)]. "Natural products from plants and animals have been widely utilized all over the world either in the pure forms or crude extracts for protection from or treatment of various diseases"[(12)]. "Garlic (*Allium sativum Liliaceae*) is used widely as a spice and medicinal herb not only in its native region but also all around the world. *Allium sativum* (Garlic) is rich in antioxidants which help destroy free radicals

UNDER PEER REVIEW

particles that can damage cell membranes and DNA. It has been found to contain a large number of potent bioactive compounds with anticancer properties"[13].

"Allium sativum (Garlic)is one of the most famous plants that is widely used to combat several diseases because it contains more than 33 sulfur compounds, enzymes, minerals, amino acids, vitamins including A, B1 and C as well as fibers"[13]. "Garlic has a higher concentration of sulphur-containing compounds than any other memberof the Allium species. This feature underlies the pungent odour of garlic and conveys the antioxidant properties of garlic preparations and many of its medicinal effects"[14]. "The sulphur compounds found in fresh garlic appear to be almost 1000 times more potent as antioxidants than those found in aged garlic extracts"[15]. "The most vital active sulfur compounds in *Allium sativum* are allicin and alliin which are considered the main antioxidants and scavenging free radical compounds"[16].

" In addition, garlic has abundance chemical compounds such as S-allylcysteines, thiacremonone, diallyl-disulfide, diallylsulfide and others. This medicinal plant and its constituents offer a lot of benefits including anti-inflammatory, anti-cholesterolemic, anti-gastric ulcer, antimicrobial, anticancer, and antioxidant properties. Garlic also modulates the activity of several metabolizing enzymes"[17].

"Previous studies established the protective and antioxidant effects of garlic against cisplatin - induced acute liver and kidney injuries in male rats"[18]. "Aged garlic extract (20% aqueous ethanol) exerts an ameliorative effect against cisplatin induced oxidative stress and renal damage by exerting antioxidant, anti-inflammatory, and antiapoptotic effects"[19].

"Treatment with an ethanolic extract of garlic might reduce cisplatin-induced nephrotoxicity in rats by decreasing serum levels of kidney biomarkers such as urea, uric acid and creatinine by increasing the activities of antioxidant enzymes"[20].

Razo-Rodriguez et al., 2008 were found that "the garlic powder feeding was able to prevent by 40–59% the alterations in the markers of renal injury studied, by 33% the histological damage, and by 38–75% the increase in markers of oxidative and nitrosative stress". "It concluded that the ability of garlic powder to ameliorate cisplatin-induced renal injury is associated with its antioxidant properties"[21]. Consequently, the current investigation was designed to evaluate the role of garlic extract on the nephrotoxicity induced by therapeutic dose of cisplatin in rabbits.

Methods:

UNDER PEER

The present experiment was conducted twenty-seven healthy domestic male rabbits (Oryctolaguscuniculusdomesticus), weighing 1.5– 2kg, and were housed in the animal house of the Histology Department, Faculty of Medicine, University of Benghazi. They were acclimatized for 2 weeks prior to experimentation. This was done to enable adaptation to the surroundings and enforce a daily routine with 12 to 13 h of light to maintain the colony's circadian biorhythms. The animals were allowed unrestricted access to food and water ad libitum. The rabbits were examined daily for possible behavioral and gross morphological or physical changes.The rabbits were randomly divided into three groups, each comprising of nine rabbits.

The first group (Co) served as control and received a single intraperitoneal injection of normal saline solution (once per week, for six weeks) for the duration of the experiment to simulate the effect of injection.

The second group (Cp) were treated with a single (**7**mg/ kg of body weight) therapeutic dose of cisplatin intraperitoneally once per week for six weeks.

The third group (Cp+Ga) animals of this group received a dose of 250 mg/kg body weightof garlic extract by oral gavages, starting from the first day of the experiment for 6 consecutive days before and 6 consecutive days after the cisplatin injection and continued daily for 6 weeks.

In addition, this group was treated with a single (7 mg / kg of body weight) therapeutic dose of cisplatin intraperitoneally once per week for six weeks.

The concentration of cisplatin dose and garlic extract was selected based on previous studies [19,22,23,24].

For histological analysis, after six weeks of experiment, the animals of the experimental and control groups were anaesthetized by ether inhalation, laparotomized, the kidney samples were removed and divided into segments. Segments from all groups were placed in 10% formal saline for 48 hours for histopathological assessment. After a period of 48 hours fixation, tissue processing was done by using paraffin technique, the slides were stained with Hematoxylin and Eosin (H&E). Then sections were examined under a light microscope[25].

Result:

UNDER PEER REVIEW

Clinical observations:

All the following observations were seen, 60 to 120 minutes after injection of the treated rabbits with therapeutic dose of cisplatin, group (Cp): The animals exhibited excessive sleeping, diarrhea, abdominal swelling, loss of appetite, fearless behavior, decreased movement, rapid breathing, and finally we noticed some animals died after second and \ or third doses of drug.

The dead animals were replaced by additional rabbits, injected with the same dose of cisplatin for the desired duration. While the treatment with garlic extract (Cp+Ga) group ameliorated all the above-mentioned signs, but they did not return to normalcy.No clinical signs were seen in control (Co) group.There was no mortality among the animals of control group (Co) andprotective group (Cp+Ga).

Histological and histopathological findings:

Control animals group (Co group):

Histological examination of the kidney sections of rabbit in the control group (Co) revealed normal morphological characteristics in terms of preserved architecture of the renal tissue.The kidney was covered by thin superficial fibrous connective tissue capsule composed of fine collagen and reticular fibers, outer cortex and inner medulla.The outer cortex was highly vascular; the inner medulla was slightly thick and less vascular.

The nephron was the functional unit of the kidney; each nephron was consisting of renal corpuscles, proximal convoluted tubules, loop of Henle, distal convoluted tubules and collecting tubules.

The sections was extended from the capsule to the medulla showing variations in distribution of renal corpuscle from the superficial which had little renal corpuscles to the mid-cortical region which had more renal corpuscle and the juxtamedullary region had less renal corpuscles than the mid cortical and cortical region **(Fig. 1a).**

The renal corpuscle was consisting of a tuft of capillaries, the glomerulus, surrounded by a double layered cup - shaped Bowman's capsule. The proximal convoluted tubules (PCT) had narrow lumen, were lined with darkly acidophilic high cuboidal epithelium with rounded nuclei and a brush border. The distal convoluted tubules (DCT) were lined with faint acidophilic cubical epithelial cells with rounded nuclei, and their lumen apparently wider than proximal convoluted tubules (PCT).

UNDER PEER REVIEW

The Henle loop (nephron loop), was consisting of the thin and thick segments that are more evident in medulla. The thin segment of Henle loop is lined by simple squamous epithelium tissue, while the thick segment is lined by cuboidal epithelium.

The collecting tubules werecontinuing from terminal part of distal tubule and converged in the renal cortex to form bundles of tubules called medullary rays. The collecting tubules lined by cuboidal epithelial tissue with relatively large nucleus occupy the entire cell and reset on visible basement membrane. The cytoplasm of cuboidal cells was pale and has dark oval nucleus **(Fig.1b,c).**

Treated animals group (Cp group):

Sections from the kidney tissues the of rabbits treated with therapeutic dose of cisplatin group (Cp) were showing extensive disruption of tissue architecture, which was leading to complete destruction of the normal pattern of the renal tissue.Kidney tissue sections revealed marked morphological disturbances at the cortico-medullary zone, glomerular congestion and atrophy, and desquamation with shedding of the tubular epithelial lining cells.There were extensive multifocal-to-diffuse cortical tubular degeneration and acute necrosis**(Fig.2).**

These damages were encountered by the presence of atrophy of glomerular tuft, wide capsular space, thickening of parietal layer of Bowman's capsule as well as focal interstitial nephritis. There was excessive accumulation of homogenous exudates casts in both proximal convoluted tubules (PCT) and distal convoluted tubules (DCT). Intertubular hemorrhage was also observed **(Fig.3).**

The degenerative changes in the proximal tubules that consisted of hydropic degeneration, pyknotic nuclei, cytoplasmic vacuolization, evident loss of the brush border, necrosis and apoptosis of tubular cells, and desquamation of necrotic epithelial cells filling the tubular lumens and forming hyaline casts. These morphological changes were more pronounced in the proximal tubules but were also induced in distal and collecting tubules as well **(Fig.4).**

High magnification cross sections in structure of rabbit kidney treated with therapeutic dose of Cisplatin of (Cp) group were showed a severe atrophy of glomerulus, which was apparent due to the reduction in its size withdistension of Bowman's space.Shrunken renal corpuscle and degeneration of the parietal epithelial cells of Bowman's capsule and some glomeruli exhibiting thickening of the basement membrane was also observed.Cellular debris in the tubular lumen and increased tissue in the interstium was also an indicationof Cisplatin-induced renal necrosis.

UNDER PEER REVIEW

Congestion of blood vessel, necrosis of renal tubular epithelium with pyknosis of their nuclei and swelling with multi vacuolations of the cytoplasm with obliteration of their lumina and focal area of severe haemorrhage was observed **(Fig.5).**

There was destruction of the renal tubules, slogging of almost entire epithelium due to desquamation of tubular epithelium. The lumina of distal and proximal convoluted tubules contain hyaline casts of dead cells and congested blood vessels can be also detected. The renal medulla showed dilated collecting tubules stuffed with R.B.Cs.Sever interstitial inflammation and edema in renal cortex and outer medulla **(Fig.6).**

Protective animals group (Cp+Ga):

Sections from the kidneys of animals received therapeutic dose of cisplatin and treated by garlic extract, (Cp+Ga) group, revealed less histological damages in renal corpuscles and renal tubules compared with that of rabbits in the (Cp) group.There was reduced the nephrotoxic effect of Cisplatin and no distinct pathological changes except mild glomerular congestion and turbidity of the epithelial cells of the proximal convoluted tubules. Mild tubular degeneration with luminal dilatation and inflammation were seen within the renal cortex **(Fig.7).**

There were slight atrophy and vacuolation of glomerular tuft with slight distension of Bowman's capsule, also the lumen of the proximal convoluted tubules appeared filled with debris **(Fig.8).**

In some area within renal cortex, there were slight tubular necrosis and moderate tubular degeneration was observed in proximal and distal convoluted tubules of the renal parenchymal structure. Extensive congestion with in loop of Henle and collecting tubules was also noticed **(Fig.9).**

In some tubules in rabbit kidneys that received a therapeutic dose of cisplatin that received a garlic extract; (Cp+Ga) group showed apparent normal renal parenchyma, but still some glomeruli appeared with slight atrophy. Transparent hyaline casts can also be noticed in the lumen of renal tubules in decreased accumulation with occasional degenerative changes when compared to cisplatin treated rabbits of (Cp) group**(Fig.10).**

Discussion:

"Cisplatin (cis-dichlorodiammine-platinum(II)) plays a highly effective role in a diverse spectrum of malignancies and yet is one of the most potent agents in resisting tumors. It is widely used to treat malignancies of various solid tumors such as head and neck, esophageal, bladder, testicular, ovarian, and small cell lung cancer"[(26)]. "Despite the positive effects of platinum compounds, they

UNDER PEER REVIEW

are poisons. Patients receiving these agents experience severe side effects that limit the dose that can be administered. However, it has been reported that the use of cisplatin is often limited because of a number of adverse effects, including nausea, vomiting, sensitivity reactions, ototoxicity, neurotoxicity, and bone marrow suppression. Among these adverse effects, nephrotoxicity is the most important limiting factor in cancer treatment using cisplatin"[27].

"The kidney plays a major role in the maintenance of constant volume and composition of the extra-cellular fluid hence does the basic functions of glomerular filtration, tubular reabsorption and tubular secretion. The kidney being an essential organ of metabolism and elimination of most of the toxic components, it serves as very important site of attack by various chemical agents including cisplatin, in the form of its activated metabolite and thus drug-induced nephrotoxicity is a frequent entity in clinical medicine"[28].

"The nephrotoxicity of cisplatin has been recognized since its introduction over 25 years ago. Once cisplatin enters the cell, it exerts its cytotoxic effect by losing one chloride ligand, binding to DNA to form intra-strand DNA adducts, and inhibiting DNA synthesis and cell growth. The DNA lesions formed from cisplatin-induced DNA damage activate DNA repair response via NER (nuclear excision repair system) by halting cisplatin-induced cell death by activation of ATM (ataxia telangiectasia mutated) pathway. However, because cisplatin-induced DNA damage activate several signal transduction pathways that can facilitate or prevent apoptosis"[29].

"Cisplatin produces reactive oxygen species such as hydroxyl radicals, hydrogen peroxide and singlet oxygen and superoxide ions, compromises natural anti-oxidant defense by inhibiting anti-oxidant enzymes and increasing reactive oxygen species, and also leads to lipid peroxidation in membranes and a decrease in protective enzyme activities against peroxidation. This increased oxidative stress, which results in DNA injury, is responsible for the resulting nephrotoxicity"[30].

"Cisplatin causes damage to nuclear and mitochondrial DNA and production of reactive oxygen species (ROS) which lead to activation of both mitochondrial and non-mitochondrial pathways of apoptosis and necrosis. Mitochondrial energetics are also disrupted by cisplatin and may contribute to nephrotoxicity"[31]. "Previous reports also demonstrate that cisplatin interferes with mitochondrial function and causes injury because it plays an important role in maintaining calcium homeostasis, Na+ - K+ - ATPase activity and ATP synthesis"[32]. "The cellular pathways of cisplatin injury to

UNDER PEER REVIEW

kidney cells have been examined primarily *in vitro* using freshly isolated or cultured renal tubular epithelial cells. *In vitro*, low concentrations of cisplatin preferentially result in apoptotic cell death, while at higher concentrations necrosis ensues"[33]. "*In vivo* administration of nephrotoxic doses of cisplatin produces a large increase in both necrosis and apoptosis in the kidney"[34].

"The primary manifestations are impairment in the functioning of renal tubular epithelial cells, including inhibition of protein synthesis, oxidative stress, mitochondrial dysfunction, cytoskeleton remodeling, changes of intercellular adhesion, and apoptosis of tubular epithelial cells. It has been suggested that oxidative damage related to oxidative stress may also be one of the causes of cisplatin-induced nephrotoxicity. Therefore, it is important to prevent nephrotoxicity of cisplatin"[35].

"The result of current study were shown several clinical signs appear in group of animals treated intrapretonially by therapeutic dose of cisplatin (Cp group) as excessive sleeping, diarrhea, loss in ability to taste food and decreased movement compared to the control group. These signs might be attributed to the direct damage of cisplatin on renal tubular cells resulting in decreased water and sodium reabsorption with subsequent polyuria and dehydration" [36, 37]. "Another study postulated that the decreased body weight in cisplatin injected rats might be attributed to gastrointestinal toxicity resulting in lost appetite, ingestion and assimilation of food"[9].

Glinsukon et al., 1986 were suggested that "it could in turn be attributed to drug-induced toxicity, psychological pressures and the necrotizing effects of the drug on the digestive system". "Furthermore, the drug also affects the mucous lining of the gastro-intestinal tractand increased metabolic rate, which are considered side effects of the chemotherapy"[38]. The clinical observations seen in our study corroborate the findings of previous researchers; King and Berry 2001[39];Leite et al., 2009[40];Rickenbacher et al. 2011[41];Hesham and Ghobara, 2013[42]; Aboraya et al., 2022[43] andElbeltagy et al., 2022[23].

The results of the present investigation showed that cisplatin toxicity produced significant structural changes in the kidney of group Cp, cisplatin treated group, in the form ofextensive disruption of tissue architecture that was leading to complete destruction of the normal pattern of the renal tissue.

There was glomerular congestion and atrophy with wide capsular space, thickening of parietal layer of Bowman's capsule, desquamation with shedding of the tubular epithelial lining cells, extensive multifocal-to-diffuse cortical tubular degeneration and acute necrosis, excessive accumulation of homogenous exudates casts in both proximal and distal convoluted tubules with hydropic

UNDER PEER REVIEW

degenerative changes in their cells, pyknotic nuclei and cytoplasmic vacuolization, evident loss of the brush border, necrosis and apoptosis of tubular cells. Intertubular hemorrhage and sever interstitial inflammation and edema in renal cortex and outer medulla also been noticed.

The changes obtained in the present study run parallel with the report documented by many authors who reported the toxicity of cisplatin on the kidney;Shirwaikar et al., 2003[44]; Ravindra et al., 2010[45]; Perše and VeIeriT-Haler, 2018[46]; Aboraya et al., 2022[43];Elbeltagy et al., 2022[23] .

Cornelison and Reed, 1993[47]; Meyer and Madias, 1994[48]and Vickers et al., 2004[49]were mentioned that, the site of injury inkidneys involves either (the distal tubules andcollecting ducts or the proximal and distal tubules butthe glomerulus has no obvious morphologic changes. However, in the current study, the glomerular damage, including atrophy, shrinkage, and degeneration of the parietal epithelial cells of Bowman's capsule and some glomeruli exhibiting thickening of the basement membrane was clearly appear in rabbit kidneys of cisplatin treated group.The sites affected probably depend on dose and time duration of drug administration.

In the present work, sections of rabbit kidney treated with therapeutic dose of cisplatin, were observed destruction of the renal tubules, slogging of almost entire epithelium due to desquamation of tubular epithelium. These changes in the present study are in agreement with the prior observations made by Kim et al.,1995[50] using electron microscopy, wherein it was reported that cisplatin treatment in rabbits caused nephrotoxicity, which was evidenced by significant loss of brush-border microvilli of the renal tubules which is supposed to be responsible for reducing the area for active glucose reabsorption. Furthermore, Vickers et al., 2004 showed acute nephrosis of the tubular epithelium induced by cisplatin *in vivo* and reproduced it in both human and rat kidney slices[49].

Our study found that the histology of renal sections exhibited remarkable vacuolation, necrosis, desquamation of epithelial cells, and hyaline casts in renal tubules after intraperitoneal treatment with therapeutic doses of cisplatin The toxic effects of cisplatin in the present study were similar to those discovered by Badary et al.,2005 who found that intravenous cisplatin administration caused abnormal kidney function in male wistar albino rats, as evidenced by markedly increased levels of serum blood urea nitrogen (BUN) and creatinine, which are associated with pathologies of the kidney, compared with a control group[26].

UNDER PEER REVIEW

The results of the present investigation showed necrosis of renal tubular epithelium with pyknosis of their nuclei and swelling with multi-vacuolations of the cytoplasm with obliteration of their lumina and focal area of severe haemorrhage. These findings are in agreement with Erkurt et al., 2009 who reported acute tubular necrosis has been seen in 30% of patients after even the first course of cisplatin therapy[51]. "It had been reported that the nephrotoxicity induced by cisplatin in childhood cancer therapy is accompanied with renal tubular damage, excess elimination of low molecular weight peptides and decreased excretion of some glycoproteins"[52]. "Another study on cisplatin revealed that about 25% of patients have a significant increase in the levels of blood nitrogen following 1-2 weeks of treatment which is considered as a main cause for glomerular and tubular damage[181].Pinta and Lippard suggested that the accumulation of platinum metabolites of cisplatin inside the renal tubule is implicated in induction of nephrotoxicity"[53]. Moreover, frequent doses of cisplatin can directly induce oxidative stress renal tubular and glomerular cells resulting in inflammation and apoptosis[54].
"However, studies suggest that inflammation, oxidative stress injury and apoptosis probably explain

part of cisplatin injury. Oxidative stress has been recognised as a major pathway of cisplatin nephrotoxicity. Antioxidant enzymes are inhibited by cisplatin and renal activities are reduced significantly. The reactive oxygen species (ROS) produced directly act on cell components including lipids, proteins and DNA and destroy their structure. The consequence of this is oxidative stress and cell death. The involvement of oxidative stress in cisplatin-induced toxicity may be further supported by the fact that many antioxidants have been reported to prevent cisplatin-induced nephrotoxicity"[55].
The disturbance in renal functions by cisplatin is mainly due to its ability to suppress protein synthesis by the renal tubular cells[56] or to promote lipid peroxidation and liberation free radicals in renal tubular cells[57].

"Lipid peroxidation (LPO) is a key process in many pathological events and it is induced by oxidative stress. It is regarded as one of the fundamental mechanisms of cellular damage caused by free radicals having reacted with lipids causing peroxidation that eventually results in the release of products such as malondialdehyde (MDA), hydrogen peroxide (H2O2) and hydroxyl radicals. All cellular components are susceptible to attack by ROS, particularly by hydroxyl radicals"[58].

UNDER PEER REVIEW

“The free radical theory is based on the evidence that living organisms (aerobes) produce oxygen-centered free radicals, capable of inducing irreversible damage to biological structures. These are formed inside body cells when oxygen is used in metabolic processes in order to produce energy. Mitochondrial respiration produces reactive oxygen species (ROS) through the leakage of intermediates from the electron transport chain. These molecules are highly unstable because they have an unpaired electron; they therefore seek to achieve a stable state by appropriating electrons from nearby molecules, which in turn become unstable and so on, thus creating an instability chain reaction”[59].Usually, the harmful activity of a small percentage of these free radicals is inhibited by the natural antioxidants occurring in the cell , such as enzymatic group (superoxide dismutase, catalase, glutathione peroxidase) or by non-enzymatic groups, such as (vitamins E, C, A and natural herbal plants). When, however, the amount of free radical increases (due to chemical toxic, chemotherapeutic drugs, radiation exposure, persistent chronic inflammation, etc.) the pool of antioxidants is saturated and the excess of free radicals damages biological structures. At first the damage is evident in mitochondria, which have the potential to affect the DNA and the RNA causing cell mutations and destruction, but also on proteins and lipids. Endothelial cells and tissue cells are the most affected by oxidative stress. Fortunately, organisms utilize both enzymatic and nonenzymatic antioxidant defenses to minimize cell injury[13]. Further studies explained that cisplatin can induce apoptosis with progressive accumulation of DNA and inhibition of DNA repair pathways through the generation of reactive oxygen species[56].

Aydogan et al., 2008 added that the significant elevation in the renal biomarkers is mainly attributed to the direct cytotoxic effect of cisplatin on the glomerular and tubular structures through the excessive liberation of ROS[60].Serum creatinine and urea levels are considered the major biomarkers that efficiently mark the glomerular filtration rate. A significant elevation of renal biomarkers was recorded in cisplatin-treated animals[37].

Elbeltagy et al., 2022 reported that the renal damage of cisplatin was apparent from the increased levels of serum urea and creatinine[23].The elevation in the serum levels of renal biomarkers might be in part due to impaired renal function, tubular obstruction with back-leakage of the renal tubules, inhibition of protein synthesis in the tubular cells or the direct toxic effect of cisplatin on the glomerular and tubular structures through the generation of ROS and enhancement of lipid peroxidation in renal tubules[57].

UNDER PEER REVIEW

An early study by Daugaard et al., 1988 confirmed that, cisplatin metabolites can inhibit the mechanism involving electrolytes reabsorption especially in the distal segment of the nephron[61].
Furthermore, cisplatin can induce disturbance in renal tubular reabsorption of potassium[62].
Another study clarified that cisplatin can inhibit the activity of antidiurtic hormone leading to hypernatremia[63].
Antioxidants, or free radical scavengers, have the ability to protect cells and tissues exposed to cisplatin from toxicity. Several natural products from plants have been widely utilized all over the world either in the pure forms or crude extracts. Antioxidants were able to improve cisplatin-induced nephrotoxicity via significant enhancement of enzymatic antioxidant activities[64].
Garlic (Allium sativum L.) is one of the World's oldest medicines and has been employed as antioxidant agent. It is the most famous plant that is widely used to combat several diseases because it contains more than 33 sulfur compounds, enzymes, minerals, amino acids, vitamins including A, B1 and C as well as fibers. The most vital active sulfur compounds in Allium sativum are allicin and alliin which are considered the main antioxidants and scavenging free radical compounds[65].Biochemical studies have demonstrated that garlic extract acts as antioxidants to protect cells against reactive oxygen species (ROS). Garlic extract exerts antioxidant action by scavenging reactive oxygen species, enhancing the cellular antioxidant enzymes, and protects DNA against free radical-mediated cell damage and mutations[66].
The results of the current study, sections from the kidney of animals received therapeutic dose of cisplatin and treated by garlic extract, group (Cp+Ga) revealed less histological damages in renal corpuscles and renal tubules compared with that of rabbits in the (Cp) group. There was reduced the nephrotoxic effect of cisplatin and no distinct pathological changes, except mild glomerular congestion and turbidity of the epithelial cells of the proximal convoluted tubules. Mild tubular degeneration with luminal dilatation and inflammation were seen within the renal cortex. There were slight atrophy and vacuolations of glomerular tuft with slight distension of Bowman's capsule.
These findings are following other previous investigators; Nasr and Saleh, 2014[19]; Essam et al., 2014[22]; Nasr and Ibrahim, 2015[24]Abdel-Daim et al., 2020[18] and El-Beltagy et al.,
2022 [23].Previous reports have demonstrated that garlic extract can prevent the oxidative stress and exerts amelioartive effect against various toxic agents through its vital antioxidant and free radical scavenger constituennts.Other studies revealed that garlic has a powerful cytoprotective effects on the cells of vital body organs[67].

UNDER PEER REVIEW

Razo-Rodriguez et al., 2008 were found that "the garlic powder feeding was able to prevent by 40–59% the alterations in the markers of renal injury studied, by 33% the histological damage, and by 38–75% the increase in markers of oxidative and nitrosative stress". "They concluded that the ability of garlic powder to ameliorate cisplatin-induced renal injury is associated with its antioxidant properties"[21].

While Dorrigiv et al., 2020 stated that "the garlic and its major components can ameliorate the toxicity of different agents in brain, kidney, blood, liver, embryo, spleen, pancreas, heart, reproductive system in part through radical scavenging, antioxidant effect, reducing lipid peroxidation, anti-inflammatory, cytoprotective activities, increase protein synthesis in damaged tissues and suppressing apoptosis". "It is rich in antioxidants which help, destroy free radicals that can damage cell membranes and DNA"[17].

Anusuya et al., 2013, reported that "the protective effect of garlic extract could be attributed to its anti-inflammatory effect, which decreased the renal edema induced by cisplatin. These denotes that the mild tubular degeneration with luminal dilatation and inflammation that were seen in current study".

In the animals pretreated with garlic extract, a remarkable improvement in the serum level of the renal biomarkers was recorded. These results confirm the ability of garlic extract to improve the renal functions through its antioxidant and free radical scavenger activities[20].

Nasr and Ibrahim, 2015 stated that "the significant increase in lipid peroxidation accompanied with marked reduction in level and activity of the antioxidant enzymes in the cisplatin -treated animals, whereas pretreatment with garlic extract produced a remarkable improvement in level and activity of renal antioxidant enzymes, with a reduction in lipid peroxidation". "These findings provide evidence about the antioxidant effect of garlic extract against cisplatin -induced oxidative stress and lipid peroxidation"[24]. "Concomitant with the results of our work, the ultrastructure study of Nasr and Ibrahim, 2015 of renal tissues in garlic extract -pretreated rats revealed normal glomeruli, preserved apical microvilli,and restoration of nuclear structure of the proximaltubular epithelial cells. Also, no evidence of inflammatory cells infiltration was observed in garlic extract -pretreated animals. This could be considered a proof of the anti-inflammatory effect of garlic extract. Thus, the inflammation could be considered as a mechanism in cisplatin-induced nephrotoxicity"[24].

"The authors added that different nuclear apoptotic changes, in the form of membrane budding, cell shrinkage, and marginal condensation of chromatin were observed in cisplatin -treated renal tissue.

UNDER PEER REVIEW

The disappearance of such morphological changes in the renal tissues of garlic extract -pretreated rats gives clues to the antiapoptotic properties of garlic extract[24].

A number of health benefits of garlic depend on its antioxidant activity. Garlic extracts and components obtained from garlic bulbs were shown to prevent oxidative modification of DNA, protein and lipids by scavenging reactive oxygen species (ROS), increasing the cellular antioxidant enzymes and enhancing glutathione levels inside the cells"[68].

The anticancer mechanisms of action of these garlic-derived nontoxic organosulfur -containing compounds include altering mitochondrial permeability, inhibiting angiogenesis, enhancing antioxidative and proapoptotic properties, and regulating cell proliferation. All these effects of garlic's sulfur-compounds have been demonstrated in various human cancers[69].It was found that the protective mechanism of garlic extract on cisplatin nephrotoxicity may be associated with its scavenging activity, antioxidant potential, anti-inflammatory, andantiapoptotic properties thereby enhancing the activity of antioxidant enzymes, reducing mitochondrial oxidative stress, restoring mitochondrial respiratory enzyme activities and attenuating expressions of apoptosis and inflammation-related proteins, thus forming the molecular basis for protective mechanism of garlic extract against cisplatin-induced nephrotoxicity.

Conclusion:

According to current study, we conclude that the cisplatin which is a chemotherapeutic drug used in the treatment of various cancer types was determined to cause renal toxicity in domestic rabbits received intrapritoneal dose equivalentto human therapeutic dose. This toxicity manifested by extensive disruption of tissue architecture that led to complete destruction of the normal pattern of the renal tissue. There was glomerular congestion and atrophy with wide capsular space, thickening of parietal layer of Bowman's capsule, desquamation with shedding of the tubular epithelial lining cells, extensive multifocal-to-diffuse cortical tubular degeneration and acute necrosis, excessive accumulation of homogenous exudates casts in both proximal and distal convoluted tubules with hydropic degenerative changes in their cells, pyknotic nuclei and cytoplasmic vacuolization, evident loss of the brush border, necrosis and apoptosis of tubular cells. Intertubular hemorrhage and sever interstitial inflammation and edema in renal cortex and outer medulla. It seems that cisplatin can weaken the antioxidant defense systems in tissue of the kidney and to increase oxidative stress together with inflammation induces apoptosis and, on the other hand, the possibility of recovery.It was also determined that garlic extract co-treatment was

UNDER PEER REVIEW

markedly efficient in reducing reactive oxygen spaces accumulation and strengthening endogenous antioxidant systems leading to a considerable attenuation of the renal toxicity as evidenced by histopathological examinations.

Recommendation:

It was concluded that garlic extract application can be considered a supportive adjuvant therapy able to reduce or prevent the nephrotoxic effects ofcisplatin by inhibiting oxidative stress. Therefore, we recommend the patients to using the garlic as antiapoptotic and antioxidant supporter against cancer drugs.

References:

1. Fadillioglu E., Oztas E., Erdogan H., Yagmurca M., Sogut S., UcarM.,Irmak M. Protective effects of caffeic acid phenethyl ester on doxorubicin induced cardiotoxicityin rats. J App Toxicol. 2004; 24:47-52.
2. Bergs J.W., Franken N.A., Haveman J.,Geijsen E.D., Crezee J., Van Bree C. Hyperthermia, cisplatin and radiation trimodalitytreatment. A promising cancer treatment? A review from preclinical studies to clinicalapplication. Int J Hyperthermia.2007; 23:329–341.
3. Kodama., H. Watanabe., R. Tanaka et al."Albumin fusion renders thioredoxin an effective anti-oxidative and anti-inflammatory agentfor preventing cisplatin-induced nephrotoxicity" Biochimica et Biophysica Acta.2014; 1840: 1152–1162.
4. Kociba R. J. andSleight S. D.Acutetoxicologic and pathologic effects of cis-diamminedichloroplatinum(NSC-119875) in the male rat. Cancer Chemotherapy Reports.1971; 55 (1): 1–8.
5. S´anchezGonz´alez P.D., L´opez-Hern´andez F. J., L´opez- Novoa J. M., and Morales A. I. Anintegrative view of the pathophysiological events leading to cisplatin nephrotoxicity. CriticalReviews in Toxicology. 2011 ; 41(10):803–821.
6. Kintzel, P.E., Anticancer drug-induced kidney disorders. Incidence, prevention and management. Drug Safety., 2001; 24: 19-38
7. Sastry J., Kellie SJ. Severe neurotoxicity. ototoxicity and nephrotoxicity following high-dose cisplatin and amifostine. PediatrHematolOncol 2005;22:441-5.
8. Benedetti G., Fredriksson L., Herpers B., Meerman J., van deWater B., de Graauw M. TNF-a-mediated NF-jB survival signaling impairment by cisplatinenhances JNK activation

UNDER PEER REVIEW

allowing synergistic apoptosis of renal proximal tubular cells. BiochemPharmacol.2013; 85:274–286.

9. Arhoghro E.M., Kpomah D.E., Uwakwe A.A. Ocimumgratissimum aqueous extract enhances recovery in cisplatin – inducednephrotoxicity in albino wistar rats. Indian J Drugs & Diseases.2012;1(5):129–142.
10. Arunkumar P.A. , Viswanatha G.L., Radheshyam N.,Mukund H., Belliyappa M.S . Science behind cisplatin-induced nephrotoxicity in humans. aclinical study. Asian Pac J Trop Biomed.2012;2(8):640-4.
11. Ray S., Roy K., Sengupta C. In vitro evaluation of protective effects of ascorbic acid and water extract ofSpirulinaplantesis (blue green algae) on 5-fluorouracil-induced lipid peroxidation. Acta PolPharm. 2007;64:335-344.
12. BongiornoP.B., Fratellone P.M., LoGiudice P. Potential health benefits of garlic (allium sativum): anarrative review. J Complement Integr Med.2008; 5(1):1–26.
13. Capasso A. Antioxidant action andtherapeutic efficacy of allium sativum L. Molecules.2013; 18(1):690–700.
14. Siegers C., Robke A., Pentz R. Effect of garlic preparations on superoxide production by phorbol ester activatedgranulocytes. Phytomed. 1999; 6(1):13-6.
15. Al-Astal Z. Effect of storage andtemperature of aqous garlic Extract on the growth of certain Pathogenic bacteria. J Al AzharUniv-Gaza. 2003;6(2):2-11.
16. Capraz M., Dilek M., Akpolat T .Garlic Hypertension and patient education. Int. J. Cardiol. 2006; 3:15- 19.
17. Dorrigiv M., Zareiyan A. and HosseinZadeh H.. Garlic (Alliumsativum) as an antidote or a protective agent against natural or chemical toxicities: Phytother.2014; 34(8):1770-1797.
18. Abdel-Daim M., Haidy G., AbdelRahman, Dessouki A. A., El-Far A.H., Khodeer D.M., Bin-Jumah M., Alhader M. S., Alkahtani S. and Aleya L. Impact of garlic (Allium sativum) oil on cisplatin induced hepatorenal biochemical and histopathological alterations in rats. Science of the TotalEnvironment.2020; 710: 1-9.
19. Nasr A.Y.andSaleh H.A.M . Aged garlic extractprotects against oxidative stress and renal changes in cisplatin-treated adult male rats. CancerCell Int.2014; 14: 92.

UNDER PEER REVIEW

20. Anusuya, N., Durgadevi, P., Dhinek, A.,Mythily, S. Nephroprotective effect of ethanolic extract of garlic (Allium sativum L.) oncisplatin induced nephrotoxicity in male wister rats. Asian J Pharm Clin Res.2013; 6, 97–100.
21. Razo-Rodriguez A.C., Chirino Y.I., Sanchez-Gonzalez D.J., Martinez Martinez C.M., Cruz C., Pedraza-Chaverri J. Garlic powder ameliorates cisplatin induced nephrotoxicity and oxidative stress. J. Med. Food 2008;11: 582–586.
22. Essam E., Yehia R., Toqa E.N., Yousif A.A. Possible protective effects of garlic, ginkobiloba and silymarin on cisplatin hepatotoxicity in protein-malnourished rats. British Journal of Medicine & Medical Research 4. 2014;5398–5414.
23. Elbeltagy A., Mohamed G., Akeel M., et al. Modulatory role of garlic (Allium sativum) extract against cisplatin-induced nephrotoxicity in female albino rats and their offspring. Research square.2022; 11:504, 1-18.
24. Nasr A.Y. and Ibrahim A.A. Aged Garlic Extract Ameliorates the Oxidative Stress. Histomorphological, and Ultrastructural Changes of Cisplatin-Induced Nephrotoxicity in Adult Male Rats. Microsc. Res. Tech.2015; 78:452–461.
25. Suvarna S. K., Layton C. & Bancroft J.D. Bancroft's theory and practice of histological techniques. 2019; 8th Ed. Elsevier Limited.
26. Badary O.A., Abdel-Maksoud S., Ahmed W.A. and Owieda G.H. Naringenin attenuates cisplatin nephrotoxicity in rats. Life Sci. 2005 ;76: 2125–2135.
27. Mishima K., Baba A., Matsuo M., Itoh Y., Oishi R.Protective effect of cyclic AMP against cisplatin-induced nephrotoxicity. Free Radic Biol Med .2006;40:1564-77.
28. Skalova S. The diagnostic role of urinary N-acetyl-beta-D-glucosaminidase (NAG) activity in the detection of renal tubular impairment. ActaMedica (Hradec Kralove). 2005;48(2):75-80 .
29. Lin X., Howell S.B. DNA mismatch repair and p53 function are major determinants of the rate of development of cisplatin resistance. 2006; Mol Cancer Ther. 5: 1239-1247.
30. Nazıroglu M., Karaoglu A., Aksoy A.O. Selenium and high dose vitamin E administration protects cisplatin-induced oxidative damage to renal, liver and lens tissues in rats. Toxicology, 2004; 195(2):221–30.
31. Miller R.P., Tadagavadi R.K., Ramesh G., and Reeves W.M. Mechanisms of Cisplatin Nephrotoxicity. Toxins (Basel). 2010 Nov; 2(11): 2490–2518.

UNDER PEER REVIEW

32. Goldstein R.S. and Mayor G.H. The nephrotoxocity of cisplatin. Life Sciences,1982; 32: 685-690.

33. Lieberthal W., Triaca V. and Levine J. Mechanisms of death induced by cisplatin in proximal tubular eipthelial cells: Apoptosis *vs.* necrosis. Am. J. Physiol.1996; 270:F700–F708.

34. Ramesh G., Reeves W.B. Salicylate reduces cisplatin nephrotoxicity by inhibition of tumor necrosis factor-α Kidney Int. 2004;65:490–498.

35. Du Y., Liu Y., Hailian Z., Yanmeng Z. and GaoL..Protective Effect of GSPE on Kidney Injury Caused by Cisplatin. Pharmacognosy Magazine.2021; 460-466.

36. Yao X., Panichpisal K., Kurtzman N., Nugent K. Cisplatin nephrotoxicity: A review. Am. J. Med. Sci. 2007;334:115–124.

37. Azu O.O., Francis I.O.D., Abraham A.O., et al.: Protective Agent, Kigelia Africana Fruit Extract, Against Cisplatin-Induced Kidney Oxidant Injury in Sprague–Dawley Rats. Asian J. Pharm. Clin. Res. 2010; 3: 84–88.

38. Glinsukon T, Somjaree R, Piyachaturawat P, and Thebtaranonth Y. Acute toxicity of nimbolide and nimbic acid in mice, rats and hamsters. Toxicology Letters 1986; 30 (2): 159–166.

39. King, P.D. and Berry, M.C. Hepatotoxicity of chemotherapy. Oncologist 2001; 6:162-76.

40. Leite E.A., Giuberti C. S., Wainstein A.J., Wainstein A.P., Coelho L.G., Lana A.M., Savassi R. R. and De Oliveira M.C. Acute toxicity of long-circulating and pH-sensitive liposomes containing cisplatin in mice after intraperitoneal administration. Life Sci. 2009 May 8;84(19- 20):641-9.

41. Rickenbacher A., et al.,. Arguments against toxic effects of chemotherapy on liver injury and regeneration in an experimental model of partial hepatectomy. Liver International 2011; 31 (3): 313–321.

42. Hesham, A. A. and Ghobara M. M. Histological Study of the Effect of Cisplatin on the Liver of Adult Male Albino Rat. International Journal of Academic and Scientific Research ISSN, 2013; 2272-6446 Volume 1, Issue 1, PP 22-33.

43. Aboraya D.M., El Baz A. ,Risha E.F. , Abdelhamid F.M. Hesperidin ameliorates cisplatin induced hepatotoxicity and attenuates oxidative damage, cell apoptosis, and inflammation in rats. Saudi Journal of Biological Sciences 2022; 29:3157–3166.

44. Shirwaikar A., Malini S., Kumari S.C. Protective effect of *Pongamiapinnata* flowers against cisplatin and gentamicin induced nephrotoxocity in rats. Int. J. Espt. Biol. 2003; 4: 58-62.

UNDER PEER REVIEW

45. Ravindra P., Bhiwgade D.A.,Kulkarni S., RataboliP.V.andDhume C.Y. Cisplatininduced histological changes in renal tissue of rat, Journal of Cell and Animal Biology. 2010;4(7):108-111.
46. Perše M. and Veceric-Haler Z. Cisplatin-Induced RodentModel of Kidney Injury: Characteristics and Challenges, BioMed ResearchInternational .2018 ;ID1462802: 29.
47. Cornelison T.L. and Reed E. Nephrotoxicity and hydration management for cisplatin, carboplatin, and ormaplatin. Gynecol Oncol, 1993; 50:147–58.
48. Meyer K.B. and Madias N.E. Cisplatin nephrotoxicity. Miner Electrolyte Metab, 1994; 20:201–13
49. Vickers A.E., Rose K., Fisher R., et al. Kidney slices of human and rat to characterize cisplatin induced injury on cellular pathways and morphology. ToxicolPathol., 2004; 32: 577–90.
50. Kim Y.K., Byun H.S., Kim Y.H., Woo J.S. and Lee S.H. Effect of cisplatin on renal function of rabbits: mechanism of reduced glucose reabsorption, Toxicol. Appl. Pharmacol., 1995; 130: 19-26.
51. Erkurt M.A., Kuku I., Kaya E. and Aydoğdu I.. Cancer Chemotherapy and Kidney. J. TOMC 2009; 16 (1): 63-68.
52. Takeda M., Komeyama T., Tsutsui T., et al. Changes in urinary excretion of enclothelin-I-like immunoreactivity in patients with testicular cancer receiving high-dose cisplatin therapy. Ara. J. Kidney Dis. 1994; 24: 12–16.
53. Kovach I.S., Moertel C.G., Schutt A.J., et al. Phase II study of cis-diarnminedichloro- platinum (NSC-119875) in advanced carcinoma of the large bowel. Cancer Chemother. Rep. 1973; 57: 357–359.
54. Pinta A.L., Lippard S.I. Binding of the antitumor drug cis-diamminedichloroplatinum (II) (cisplatin) to DNA. Biochim. Biophys. Acta. 1985; 780: 167–180.
55. Yao X., Panichpisal K., Kurtzman N., Nugent K. Cisplatin nephrotoxicity: A review. Am. J. Med. Sci. 2007;334:115–124.
56. Adejuwon A.S., Femi-Akinlosotu O., Omirinde J.O., et al. Launaeataraxacifolia ameliorates cisplatin- induced hepato-renal injury. Eur. J. Medicinal Plants. 2014; 4(5): 528–541.
57. Saad A.A., Youssef M.I., El-Shennawy L.K .Cisplatin induced damage in kidney genomic DNA and nephrotoxicity in male rats: Theprotective effect of grape seed proanthocyanidin extract. Food Chem Toxicol.2009; 47:1499–1506.

UNDER PEER REVIEW

58. Martins N.M., Santos N.A., Curti C., Bianchi M.L., Santos A.C., Cisplatin induces mitochondrial oxidative stress with resultant energetic metabolism impairment, membrane rigidification and apoptosis in rat liver. J. Appl. Toxicol. 2008; 28: 337−344.
59. Finkel T., Holbrook N.J. Oxidants, oxidative stress and the biology of ageing. Nature 2000, 408, 239–247.
60. Aydogan S., Yapislar H., Artis S., et al. Impaired erythrocytes deformability in H2O2- induced oxidative stress: Protective effect of L carnosine. Clin. Hemorheol. Microcirc. 2008; 39: 93–98.
61. Daugaard G., Rossing N., Rorth M. Effects of high-dose cisplatin on glomerular function in the human kidney. Cancer Chemother. Pharmacol. 1988; 21: 163–167.
62. Tamim H., Shadi L., Bassel J., et al. Cisplatin-induced renal salt wasting syndrome. South. Med. J. 2010; 10; 103(8): 793–799.
63. Surinder A., Balamurugan N., Gunaseelan K., et al. Adverse drug reaction profile of cisplatin-based chemotherapy regimen in a tertiary care hospital in India: An evaluative study.Indian J. Pharm. 2010; 42(1): 40–43.
64. Palipoch S. andPunsawad C. Biochemical and histological study of rat liver and kidneyinjury induced by Cisplatin. J ToxicolPathol. 2013; 26(3):293-9.
65. Nasr AY: Protective effect of aged garlic extract against the oxidative stress induced by cisplatin on blood cells parameters and hepatic antioxidant enzymes in rats. Toxicol. Rep. 2014; 1(1): 682–691.
66. Chung LY. The antioxidant properties of garlic compounds.allyl cysteine, alliin, allicin, and allyl disulfide. J Med Food.2006; 9:205-13.
67. Assayed M.E., Salem H.A., Khalaf A.A. Protective effects of garlic extract and vitamin C against cypermethrin reproductive toxicity in male rats. Res. J. Vet. Sci. 2008; 1: 1–15.
68. Kohda K., Goda H., Itoh K., Samejima K., Fukuuchi T., Aged garlic extract reduces ROS production and cell death induced by 6-hydroxydopamine through activation of the Nrf2-ARE pathway in SH-SY5Y cells. Pharmacol. Pharm., 2013, 4, 1, 31–40.
69. De Greef D., Barton E., Sandberg E., Croley C., Pumarol J., Lok Wong T., Das N. and Bishayee A.. Anticancer potential of garlic and its bioactive constituents: A systematic and comprehensive review. Semin Cancer Biol. 2021 Aug;73:219-264.

UNDER PEER REVIEW

Figures: in the following pages

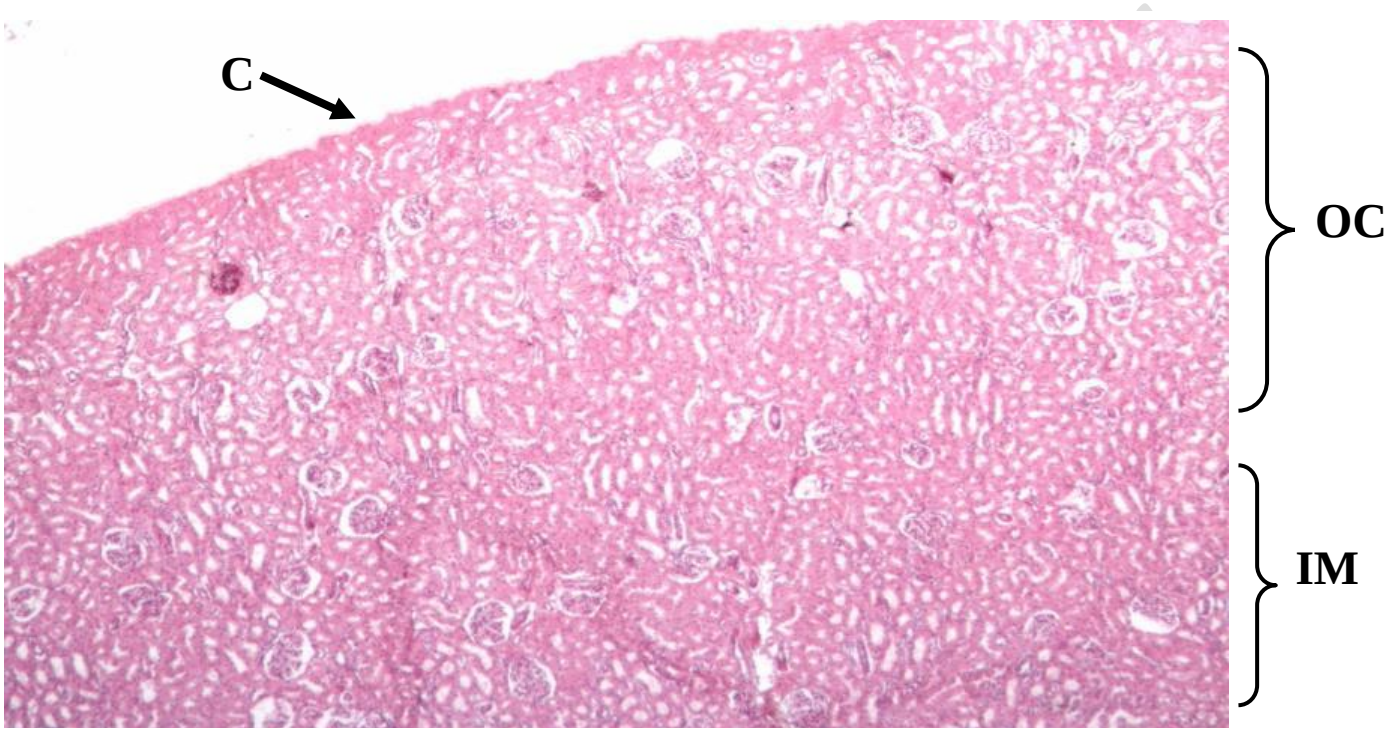

Figure 1a: Photomicrograph illustrates the normal structure of rabbit kidney of control (Co) group. Note, thin C.T. capsule (C), outer cortex (OC) and inner medulla (IM). H&E stain. X10.

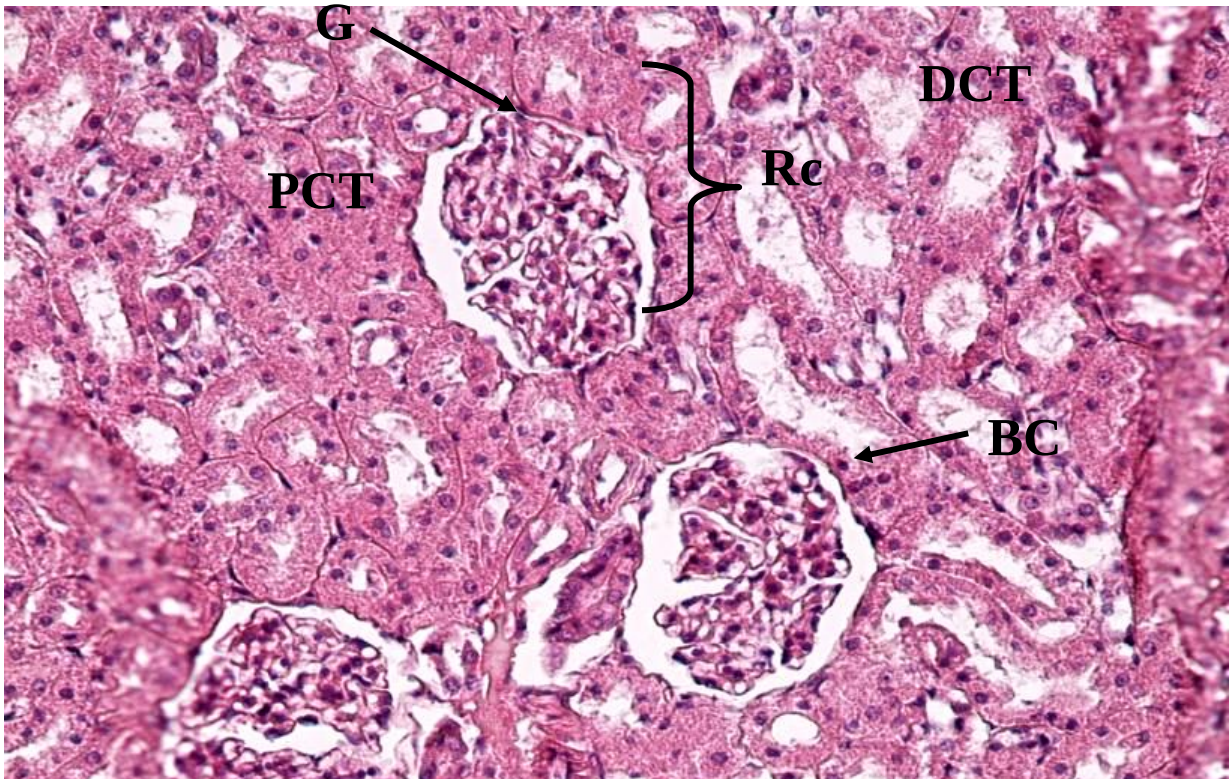

Figure 1b: Photomicrograph illustrates the normal structure of rabbit kidney of control (Co) group.Note, the renal corpuscle (Rc) consists of the glomerulus (G) , surrounded Bowman's capsule (BC). proximal convoluted tubules (PCT), distal convoluted tubules (DCT). H&E stain. X20.

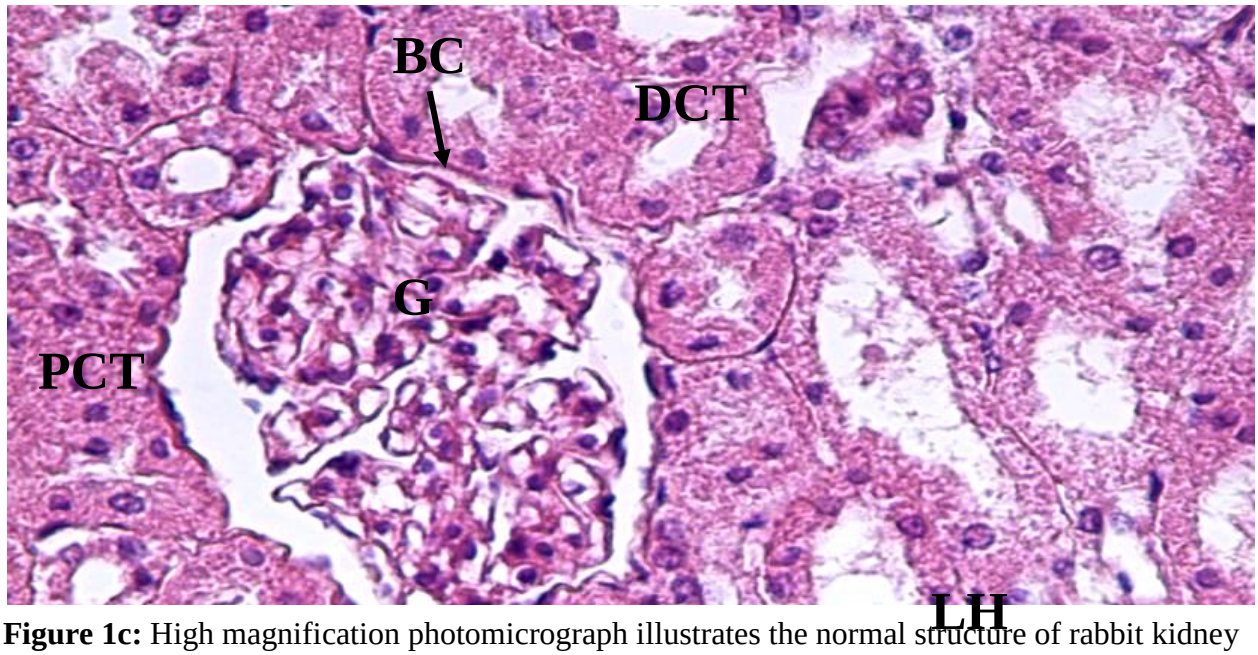

Figure 1c: High magnification photomicrograph illustrates the normal structure of rabbit kidney of control (Co) group. Renal corpuscle (Rc), the glomerulus (G), Bowman's capsule (BC). proximal convoluted tubules (PCT), distal convoluted tubules (DCT), loop of Henele (LH). H&E stain. X40.

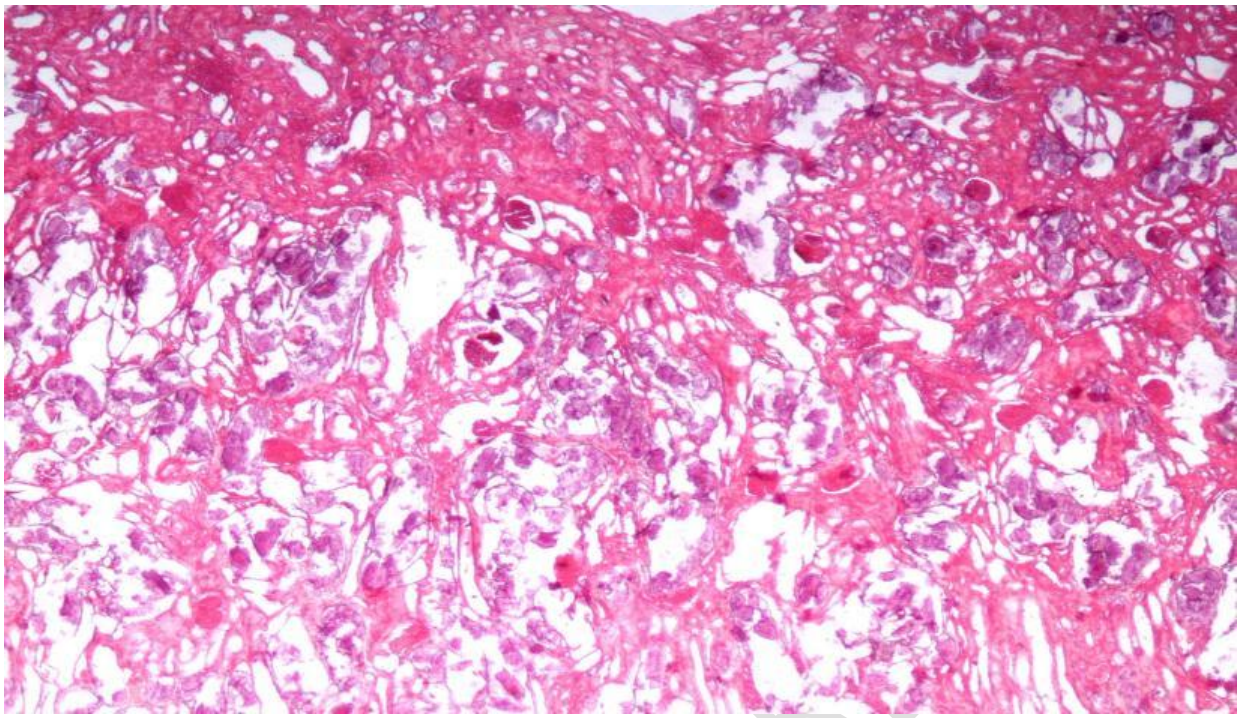

Figure 2: Photomicrograph illustrates structure of rabbit kidney treated with therapeutic dose of Cisplatin of (Cp) group. Note, extensive multifocal-to-diffuse cortical tubular degeneration and necrosis. Glomerular congestion and atrophy and desquamation. H&E stain. X10.

UNDER PEER REVIEW

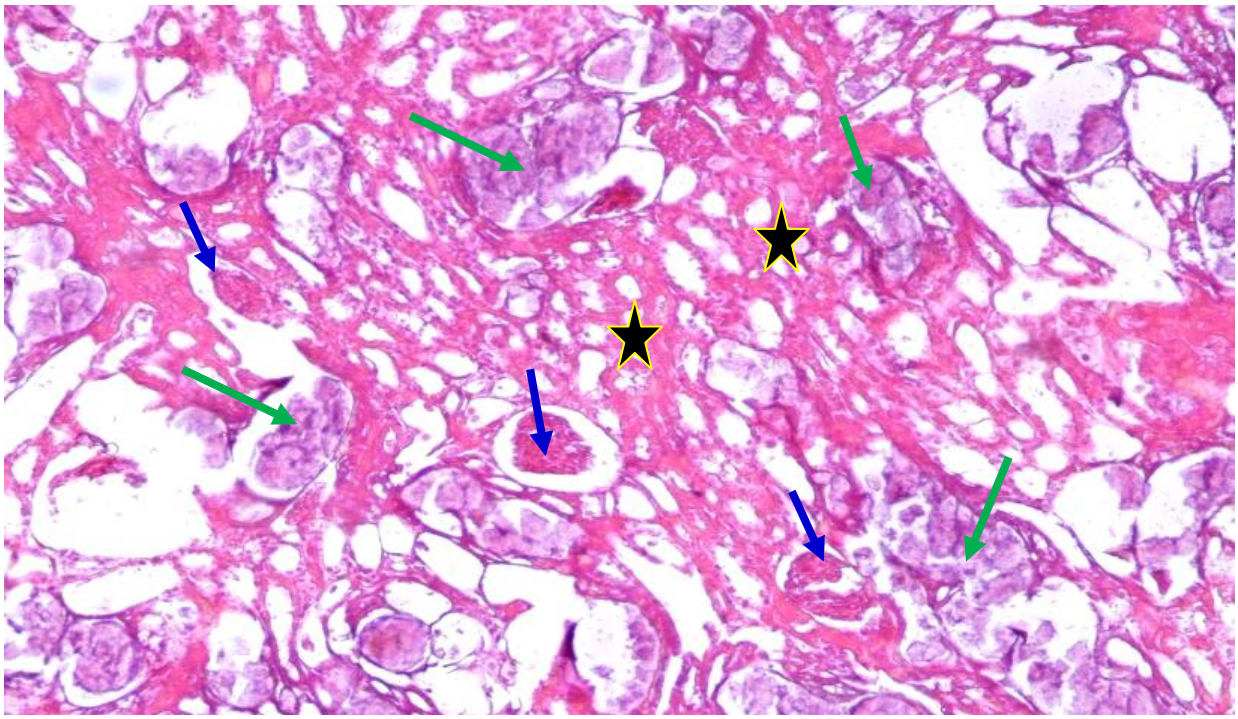

Figure 3: Photomicrograph illustrates structure of rabbit kidney treated with therapeutic dose of Cisplatin of (Cp) group. Note, atrophy of glomerular tuft (blue arrow), excessive accumulation of homogenous casts in both (PCT) and (DCT) (green arrow) and intertubular hemorrhage (stars). H&E stain. X20.

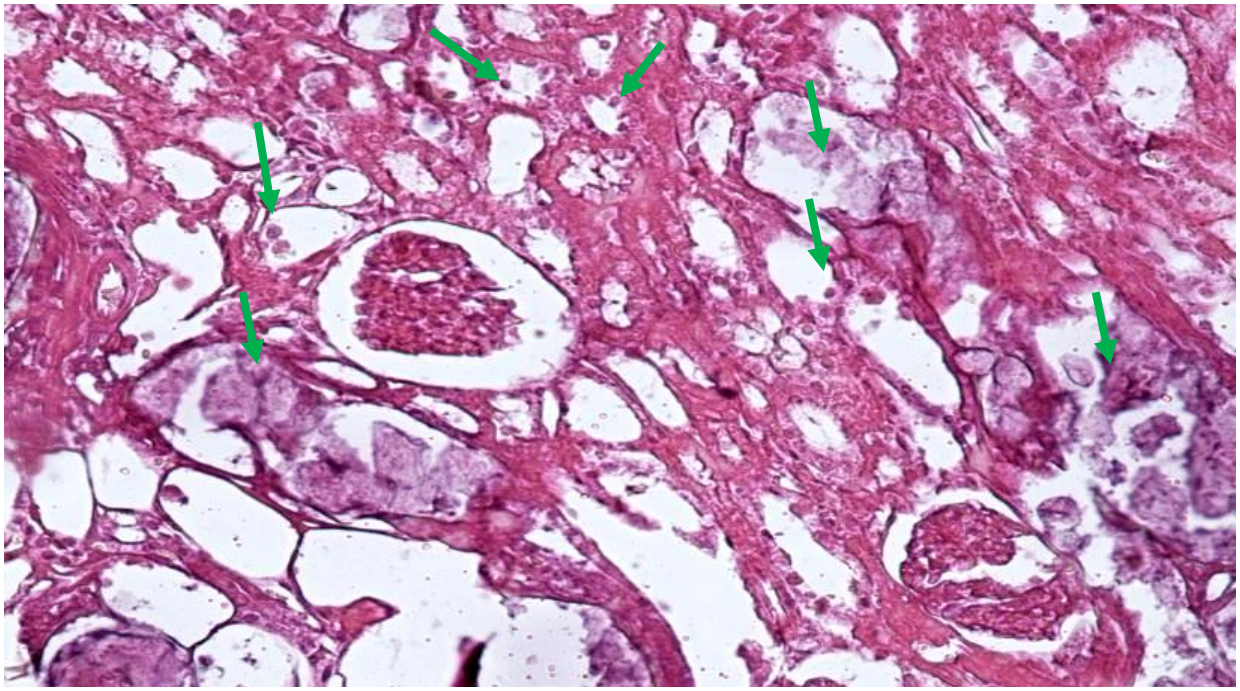

Figure 4: Photomicrograph illustrates structure of rabbit kidney treated with therapeutic dose of cisplatin of (Cp) group. Note, hydropic degeneration, pyknotic nuclei, cytoplasmic vacuolization, necrosis and apoptosis of tubular cells, and desquamation of necrotic epithelial cells with in both (PCT) and (DCT) (green arrow). H&E stain. X40.

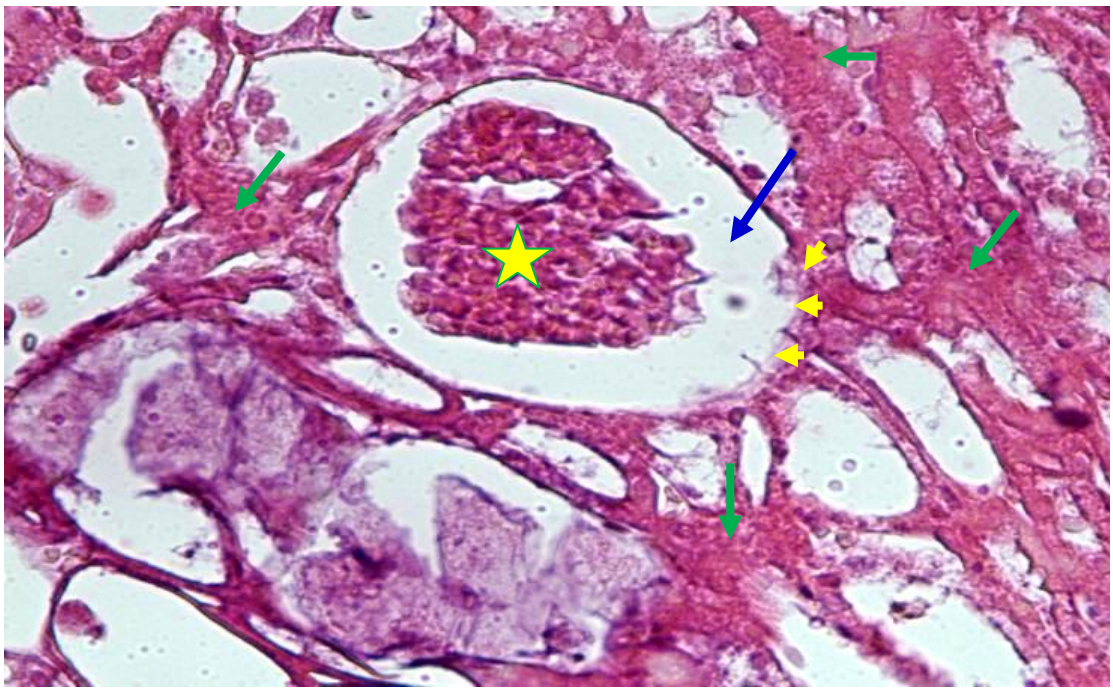

Figure 5: High magnification photomicrograph illustrates structure of rabbit kidney treated with therapeutic dose of cisplatin of (Cp) group. Note, glomerular atrophy (star), distension of Bowman's space(blue arrow). Degeneration of the parietal epithelial cells of Bowman's capsule (head arrow). Sever interstitial inflammation (green arrow). H&E stain. X100.

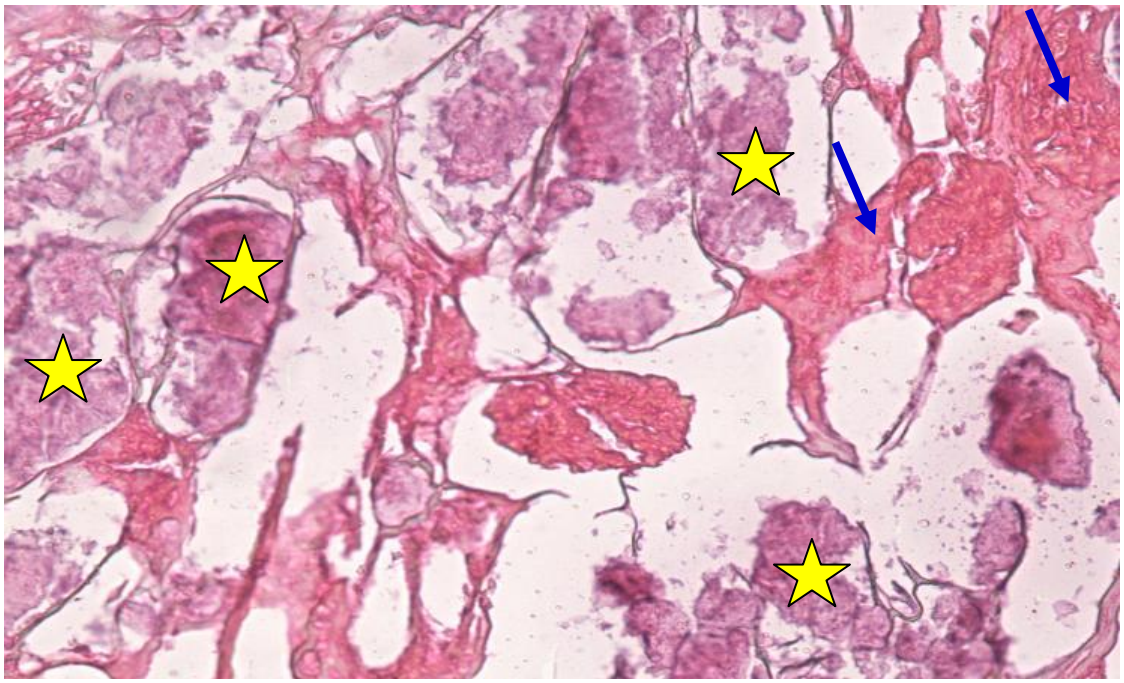

Figure 6: Photomicrograph illustrates structure of rabbit kidney treated with therapeutic dose of cisplatin of (Cp) group. Note, hyaline casts of dead cells can be detectedinboth PCT & DCT (stars), there was destruction of the renal tubules. The renal medulla showed dilated collecting tubules stuffed with R.B.Cs. (arrow) H&E.X20.

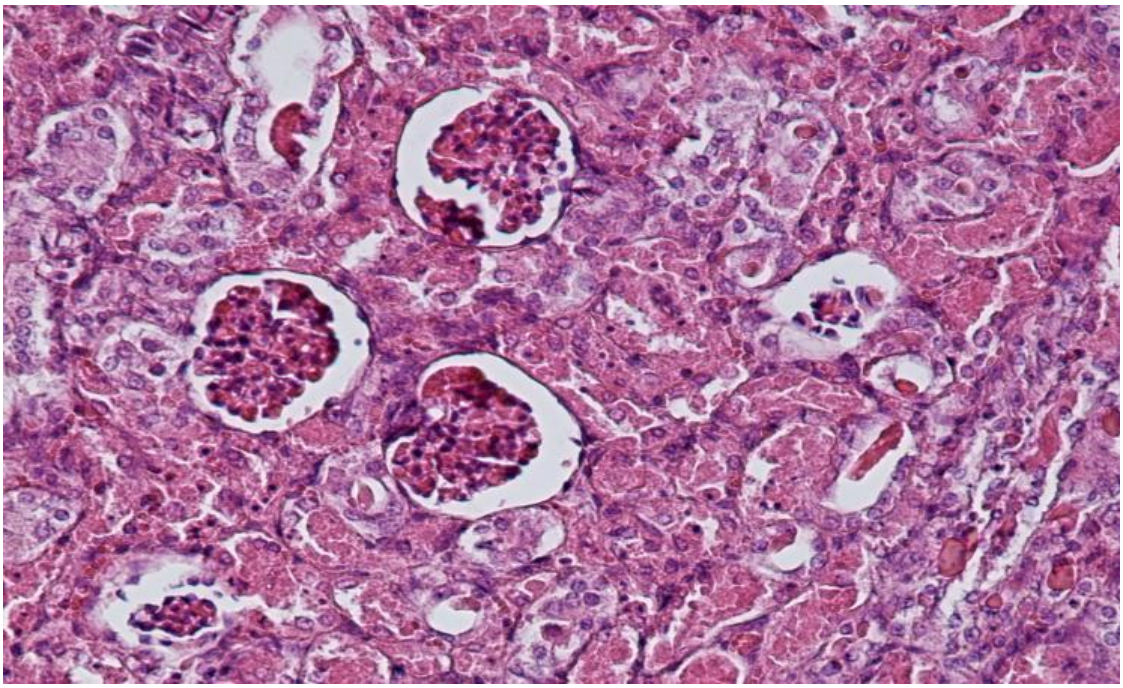

Figure 7: Photomicrograph illustrates cross section of rabbit kidney of group (Cp+Ga). Note, there was no distinct pathological changes except mild tubular degeneration with luminal dilatation and inflammation were seen within the renal cortex. H&E. X20.

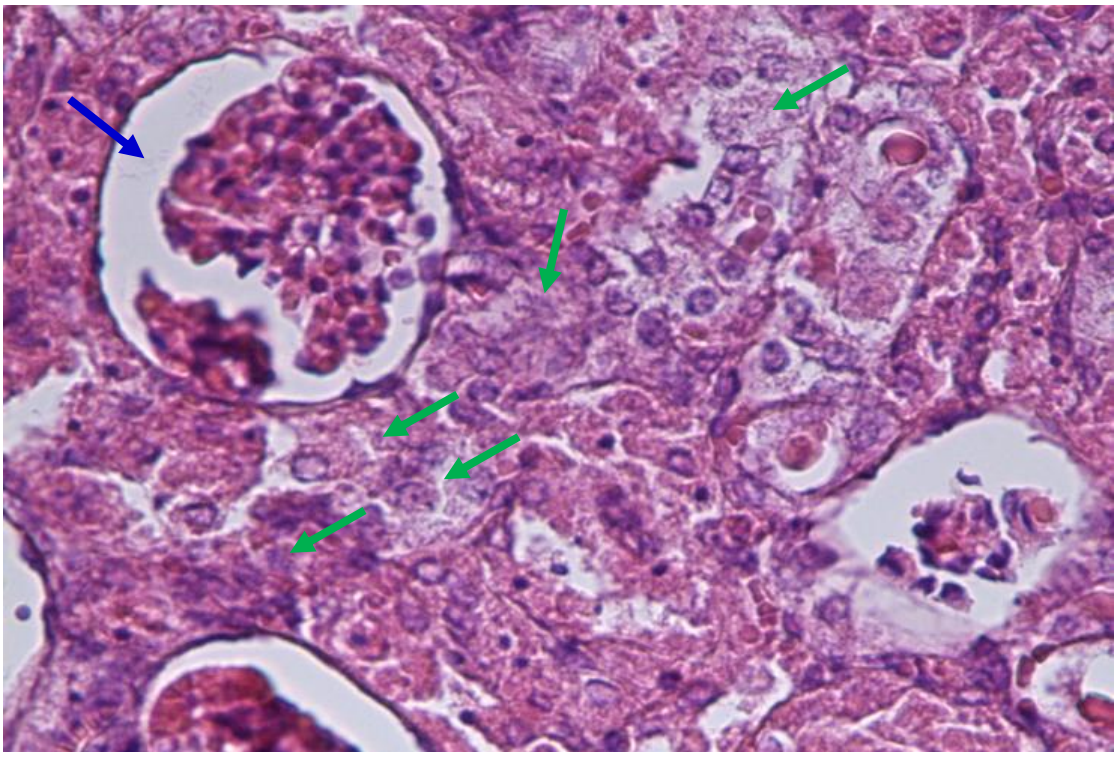

Figure 8: Photomicrograph illustrates cross section of rabbit kidney of group (Cp+Ga). Note, slight atrophy and vacuolation of glomerular tuft with slight distension of Bowman's capsule (blue arrow), the lumen of the proximal convoluted tubules appeared filled with debris (green arrow). H&E. X40.

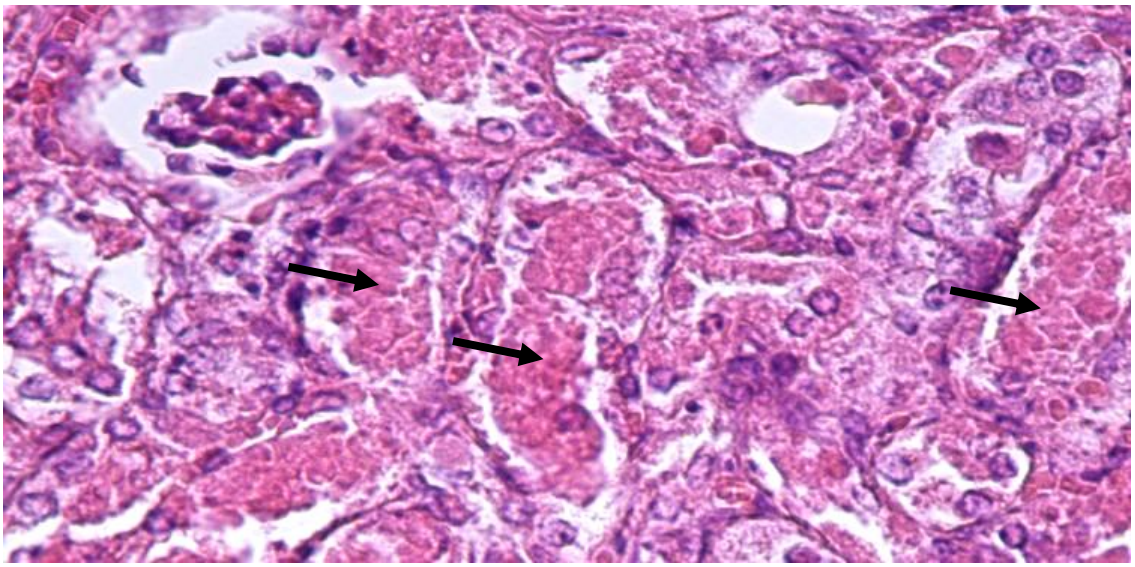

Figure 9: Photomicrograph illustrates cross section of rabbit kidney of group (Cp+Ga). Note, extensive congestion with in loop of Henele and collecting tubules (arrow). H&E. X20

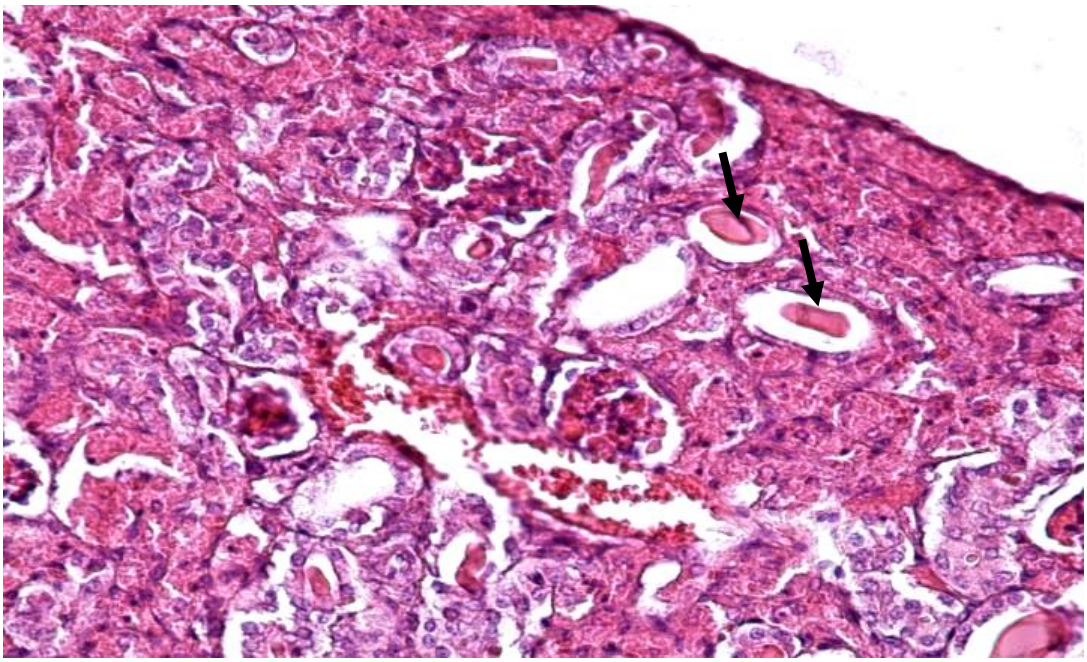

Figure 10: Photomicrograph illustrates cross section of rabbit kidney of group (Cp+Ga). Note, there were transparent hyaline casts in the lumen of renal tubules (arrow) with occasional degenerative changes. H&E. X20.

UNDER