

# Retrobulbar optic neuritis associated with certolizumab

## ABSTRACT

**Aims:** to report a case of retrobulbar optic neuritis (ON) associated with certolizumab.

**Case report:** A 22-year-old man presented with a 4 days history of decreased vision in the left eye accompanied by pain on extraocular movement. He had received an infusion of certolizumab for juvenile idiopathic arthritis 3 weeks before symptomatology. Ocular examination of the left eye revealed a left afferent pupillary defect. The best-corrected visual acuity was 1/10. Anterior segment and funduscopy were normal. Clinical presentation suggested ON. We performed visual evoked potentials (VEP) and optical coherence tomography (OCT) to confirm the diagnosis: VEP showed increase in latency of P100 wave in the left eye which was consistent with the diagnosis of ON, OCT was performed in order to follow-up the modifications in the optic nerve head. Magnetic resonance imaging (MRI) was performed to rule out multiple sclerosis or other demyelinating disease. Certolizumab-induced retrobulbar ON is diagnosed by elimination. Certolizumab was discontinued and the patient was treated with corticosteroids with good visual outcome.

**Discussion:** Occurrence of ON during treatment with anti-tumor necrosis factor  $\alpha$  was reported in the literature, mainly with etanercept, then infliximab and adalimumab. There are few cases of ON associated with certolizumab.

**Conclusion:** This case illustrates the possibility of ON during treatment with certolizumab. Careful monitoring of patients receiving this therapy is necessary to identify ophthalmological or neurological side effects.

*Keywords: biologic therapy, tumor necrosis factor-alpha, optic neuritis, adverse events.*

## 1. INTRODUCTION

The introduction of biological therapy has revolutionized the treatment of chronic immune-mediated diseases including inflammatory rheumatic diseases such as juvenile idiopathic arthritis (JIA). However, the increasing use of these biological agents can be associated with a variety of adverse events including intestinal, dermatological, neurologic and ophthalmic conditions such as uveitis, scleritis and optic neuritis (ON) [1,2]. ON, a condition characterized by inflammation of the optic nerve with diverse etiologies including auto-immune, infectious, toxic, demyelinating and others, has been previously reported as a rare complication of treatment with anti-tumor necrosis factor  $\alpha$  (anti-TNF  $\alpha$ ) [3-5]. We report here a case of ON in a patient with JIA following administration of certolizumab.

## 2. CASE REPORT

A 22-year-old men presented with decreased vision in the left eye for 4 days accompanied by pain on extraocular movement. He was known with a 6 years history of JIA, treated initially with non-steroidal anti-inflammatory drugs. Because of partial improvement, he was put on certolizumab pegol (Cimzia) six months ago. He received 200 mg of certolizumab every 2 weeks for 6 months, associated to sulfasalazine (3g/day). His loss of vision and pain with eye movement began 3 weeks after his last infusion of certolizumab. Ocular examination revealed a left afferent pupillary defect. The best-corrected visual acuity was 10/10 in the right eye and 1/10 in the left eye. Anterior segment and funduscopy of both eyes were normal. Clinical presentation suggested ON. We performed VEP and OCT to confirm the

diagnosis: VEP were normal in the right eye and showed a prolonged latency of the P100 wave in the left eye on flash and pattern stimulations 15' and 60' (fig 1). OCT was performed in order to follow-up the modifications in the optic nerve head and showed normal retinal nerve fiber layer thickness and macular ganglion cell complex in both eyes. A complete laboratory evaluation had excluded infectious or autoimmune etiologies. MRI of the brain was normal. **Certolizumab-induced retrobulbar ON is diagnosed by elimination.** Certolizumab was discontinued and the patient was treated with 1 g of intravenous methylprednisolone per day for 3 days, followed by oral prednisone over the next 11 days. The patient pain on eye movement resolved within 3 days of treatment, 10 days after, his left eye visual acuity has improved to 10/10.

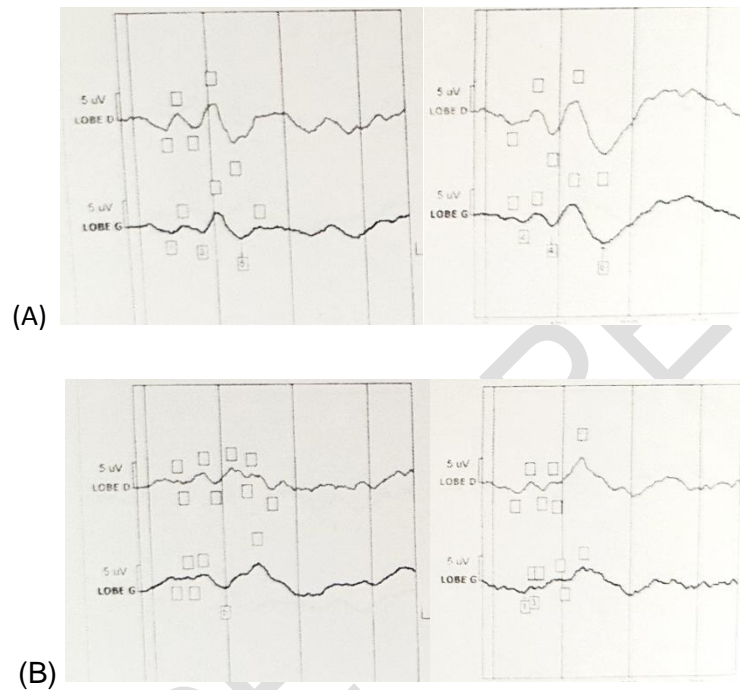


Fig 1: PEV results showed a prolonged latency of the P100 wave in the left eye on pattern stimulations 15' and 60'

(A) Right eye : P100:

- 60': - Latency: 108 ms
- Amplitude: 6,6  $\mu$ V
- 15': - Latency: 115 ms
- Amplitude: 6  $\mu$ V

(B) Left eye: P100:

- 60': - Latency: 133 ms
- Amplitude: 3,6  $\mu$ V
- 15': - Latency: 138 ms
- Amplitude: 4  $\mu$ V

### 3. DISCUSSION

In our case, the clinical presentation, the temporal sequence between the administration of the drug and symptoms onset, VEP results, the exclusion of infectious or autoimmune etiologies and the quick response to steroids treatment suggest ON associated with certolizumab.

Numerous papers showed occurrence of ON during treatment with anti-TNF $\alpha$ . Demyelination in the central nervous system seems to play a role in the physiopathology of the ON associated with anti-TNF  $\alpha$  agents. Although TNF $\alpha$  blockers are an effective therapy of a variety of autoimmune diseases, they can induce or exacerbate demyelination [5,6]. In most cases, ON was retrobulbar, bilateral, and has been observed in association with etanercept [1]. In a registry-based study conducted by Lim et al., the authors reported 50 cases of ON with etanercept, 40 with infliximab and 4 with adalimumab [7].

Compared to other anti-TNF monoclonal antibodies, certolizumab pegol is an antibody fragment attached to polyethylene glycol, which increases its half-life in the body and allows less frequent dosing while maintaining comparable efficacy [1,5]. However, like other anti-TNF- $\alpha$ , cases of ON with certolizumab were reported in the literature but with lower incidence. In the National Registry of Drug Induced Ocular Side Effects, the authors reported in 2013 cases of ON associated with a variety of anti-TNF  $\alpha$  including 5 cases with golimumab or certolizumab [8]. Alexandre et al reported a case of ON and concomitant multiple sclerosis in a patient under certolizumab [9]. Chen et al. reported another well documented case of certolizumab associated ON in a patient with pre-existing but asymptomatic multifocal demyelination [5]. Certolizumab was also associated with an oculomotor nerve demyelination [10].

The relationship between anti-TNF $\alpha$  and demyelinating disease is not fully understood but TNF  $\alpha$  seems to play a crucial role in immune homeostasis [3,6]. TNF  $\alpha$  has both pro-inflammatory and pro-regenerative properties in the central nervous system and can activate two types of receptors (TNFR1 and TNFR2). TNFR1 activation is associated with pro-inflammatory responses and can contribute to neuroinflammation and demyelination. TNFR2 activation has been associated with neuroprotection and promoting the proliferation and survival of oligodendrocyte precursor cells which play a crucial role in myelin repair and remyelination. Therefore, TNF $\alpha$  blockers might lead to a decrease in TNFR2 signaling, potentially impairing the ability of the central nervous system to repair myelin damage [11,12]. Another hypothesis is that an activation of latent infections may result in demyelination [12].

Our case developed ON 6 months after certolizumab was added. According to the literature, most cases developed this demyelinating phenomenon 1.5 years after starting treatment [5,12]. Treatment for ON includes intravenous corticosteroids therapy followed by oral steroids and discontinuation of the causative agent [1,9]. Most patients have favorable outcome with complete resolution after treatment [1,9]. However, the disease might persist in a few cases even after treatment cessation, suggesting that anti-TNF  $\alpha$  could trigger the demyelinating process, which subsequently progresses independently [1]. Thus, since certolizumab can induce or exacerbate demyelination, it should not be prescribed in patients with a personal or family history of demyelinating disease. Brain MRI is an important tool to identify preexisting asymptomatic demyelinating disease before proceeding with certolizumab therapy.

### 4. CONCLUSION

To summarize, ON is a serious complication that can cause irreversible vision loss. Therefore, careful monitoring of patients receiving biological agents is necessary to identify ophthalmological or neurological side effects. In addition, anti-TNF  $\alpha$  must be avoided in patients with a personal or family history of demyelinating diseases.

#### Ethical Approval:

As per international standard or university standard written ethical approval has been collected and preserved by the author(s).

### CONSENT

All authors declare that 'written informed consent was obtained from the patient for publication of this case report and accompanying images.

### REFERENCES

1. Nicolela Susanna F, Pavesio C. A review of ocular adverse events of biological anti-TNF drugs. J Ophthalmic Inflamm Infect.2020;10(1):11.
2. Lopetuso LR, Cuomo C, Mignini I, Gasbarrini A, Papa A. Focus on Anti-Tumour Necrosis Factor (TNF)- $\alpha$ -Related Autoimmune Diseases. Int J Mol Sci. 2023;24(9):8187.

3. Kaltsonoudis E, Zikou AK, Voulgari PV, et al. Neurological adverse events in patients receiving anti-TNF therapy: a prospective imaging and electrophysiological study. *Arthritis Res Ther.*2014;16(3):R125.
4. Uchio N, Yashita D, Hao A, Takahashi T, Matsumoto H. Intravenous Immunoglobulin in the Treatment of Adalimumab-associated Optic Neuritis. *Intern Med.* 2022;61(3):429-432.
5. Chen A, Miller NR, Bosley TM. Optic Neuritis Associated With Tumor Necrosis Factor-Alpha Inhibitor Certolizumab. *J Neuroophthalmol.*2021;41(4):e713-e714.
6. de Frutos-Lezaun M, Bidaguren A, de la Riva P, Meneses, CF, Olascoaga J. Bilateral Retrobulbar Optic Neuropathy Associated With Golimumab. *Clin Neuropharmacol.*2017;40(3):149-151.
7. Lim LL, Fraunfelder FW, Rosenbaum JT. Do tumor necrosis factor inhibitors cause uveitis? A registry-based study. *Arthritis Rheum.*2007; 56(10):3248–3252.
8. Winthrop KL, Chen L, Fraunfelder FW, Ku JH, Varley CD, Suhler E, et al. Initiation of anti-TNF therapy and the risk of optic neuritis: from the safety assessment of biologic ThERapy (SABER) study. *Am J Ophthalmol.*2013;155(1): 183–189.e1.
9. Alexandre B, Vandermeeren Y, Dewit O, Moreels T, de Boer N, Dhar A et al. Optic neuritis associated or not with TNF antagonists in patients with inflammatory bowel disease. *J Crohns Colitis.*2016;10:541–548.
10. Ban BH, Crowe JL. Oculomotor Nerve Demyelination Secondary to Certolizumab Pegol. *J Clin Rheumatol.*2018;24(4):234-236.
11. Iovino A, Aruta F, Dubbioso R, Ruggiero L, Tozza S, Spina E, et al. Primary Progressive Multiple Sclerosis Under Anti-TNF $\alpha$  Treatment: A Case Report. *J Cent Nerv Syst Dis.*2020;12:1179573520973820.
12. Yokoyama W, Takada K, Miyasaka N, et al. Myelitis and optic neuritis induced by a long course of etanercept in a patient with rheumatoid arthritis. *BMJ Case Rep.* 2014;2014:bcr-2014-205779.